

Assessment of life quality of a patient with ectodermal dysplasia rehabilitated with osseointegrated implants: Five years clinical and radiographic follow-up

Karina Leite Baía **FERNANDES***

Luis Rogério **DUARTE****

Carlos Eduardo **FRANCISCHONE*****

Bruno Sotto **MAIOR*****

Abstract

Ectodermal dysplasia is a genetic disorder associated with dental anomalies that severely affect function, aesthetics and quality of life. Patients with ectodermal dysplasia often have complete or partial anodontia, which affects normal jaw development. Dental implants have increasingly been used for the rehabilitation of these patients because their disease severity reduces treatment options. This report describes the pre- and postoperative quality of life of a 55-year old woman with ectodermal dysplasia that presented with hypodontia and severe atrophy of the jaws. She was treated with dental implants for immediate functional loading using the Novum® protocol for the mandible and the All-on-4® hybrid technique in the maxilla, together with zygomatic implants and 3 conventional implants. The patient was followed up for 5 years.

Keywords: Ectodermal dysplasia. Zygomatic fixtures. Quality of life.

How to cite this article: Fernandes KLB, Duarte LR, Francischone CE, Maior BS. Assessment of life quality of a patient with ectodermal dysplasia rehabilitated with osseointegrated implants: Five years clinical and radiographic follow-up. *Dental Press Implantol.* 2012 July-Sept;6(3):44-51.

» The authors inform that they have no associative, commercial, intellectual property, or financial interests representing a conflict of interest in products and companies described in this article.

Contact address:

Luis Rogério Duarte

Av. Prof. Magalhães Neto, 1541 – Centro Médico Hospital da Bahia – Sala 4006
Zip Code: 41.810-011 – Salvador/BA – Brazil
E-mail: luisrogerioduarte@mac.com

Submitted on: May 7, 2012

Reviewed and received on: May 15, 2012

* Specialist in Prosthodontics, Brazilian Association of Orthodontics, Bahia. PhD student in Implantology, São Leopoldo Mandic School of Dentistry.

** PhD in Implantology, São Leopoldo Mandic School of Dentistry. Professor, Specialization Course in Implantology, Federal University of Bahia.

*** Professor, MSc and PhD Program, São Leopoldo Mandic School of Dentistry.

Introduction

Ectodermal dysplasia (ED) describes a group of inherited diseases characterized by the defective development of tissues of ectodermal origin during embryogenesis. More than 170 different clinical conditions are currently known. They impair the development of ectodermal structures, such as hair, skin, nails, sweat glands and teeth.¹⁻⁵

Changes in oral epithelium may present as the congenital absence of deciduous and permanent dentition and hypoplasia of the alveolar bone. In ectodermal dysplasia, the highest incidence of hypodontia is found in the mandible. When teeth are present, they may have abnormalities, the most frequent of which are conoid teeth and taurodontism.^{1,4,8}

Congenital hypodontia in ectodermal dysplasia is responsible for the poor development of the alveolar bone, which results in mandibular and maxillary hypoplasia, occlusal collapse and narrowing of the alveolar ridge.^{1,3,9}

Hypodontia may affect the development of the mandibular angle and the transversal and sagittal growth of the maxilla and the mandible. Moreover, vertical growth may be affected by the reduced alveolar height.^{3,9} Growth abnormalities may lead to an occlusal collapse, which is responsible for a reduction of the height of the lower third of the face and retrognathism.¹ Together with hypodontia, the craniofacial abnormalities resulting from ectodermal dysplasia reduce masticatory capacity and lead to esthetic changes that may affect socioeconomic activities and quality of life. Therefore, patients with ectodermal dysplasia require prosthodontic rehabilitation.^{1,2,4,10} However, the instability and poor retention of conventional complete dentures and removable partial dentures in patients with a narrow alveolar ridge and

conoid teeth are frequent causes of patient dissatisfaction.^{1,7,11,12} Therefore, implant-supported dentures have become an alternative for the oral rehabilitation of individuals with ectodermal dysplasia.

This report describes the clinical case of a patient with ectodermal dysplasia rehabilitated with conventional and immediate-loading fixed dentures supported by conventional and zygomatic implants and followed up clinically and radiographically for five years.

Case report

A white 55-year-old woman searched for a private dental clinic for prosthodontic rehabilitation due to a root fracture in tooth #33 and aesthetic and functional disorders resulting from the fact that she had never had any maxillary teeth. Oral examination revealed multiple hypodontia; she had only the right and left maxillary canines, both with crown malformations (conoid teeth). Those teeth were fragile due to endodontic treatments and the various metal ceramic crowns received during the patient's adult life, used as support for removable dentures retained with clasps. The signs of ectodermal dysplasia was more severe in her right side, with sparse hair, smaller right cheekbone (less volume in the area of the right zygomatic bone), no right eyebrow, no right breast, mild hypohidrosis and dry skin, but normal nails.

Clinical examination revealed that she had a maxillary complete denture and that only the canines, both conoid, were present in the mandible (Fig 1A). The maxillary and mandibular alveolar ridges were severely hypoplastic and atrophic (Fig 1B).

During the first visit, a VAS and the OHIP questionnaire were used to obtain information about her baseline psychological status and the functional conditions of her removable dentures.

Radiographs showed reduced height of the alveolar bone in the region of the mandibular canines; a left canine root fracture was also identified.

The treatment plan was divided into two phases. In the first phase, the height of the lower third of the face, as well as labial support, was recovered by replacing the old dentures with a full removable maxillary denture.¹⁵ A CT scan of the lower arch was requested to evaluate and plan the surgery to extract the canines and immediately place the three osseointegrated implants using the Novum[®] Nobel Biocare approach and a multifunctional surgical guide, distributed according to the Roy polygon (Fig 2).^{16,17}

Immediately after implant placement using torque greater than 40 N/cm², the interocclusal wax record was obtained between the multifunctional guide and the complete denture using an acrylic resin (GC Pattern Resins, Alsip, IL) (Fig 3). After waxing and bonding the guide to the cylinders, the set was used as an individual tray for the impression of the implant-cylinder-gingiva relationship by the addition of condensation silicone (Clonage, DFL, Rio de Janeiro, Brazil) and manufacture of the working model using the mandibular multifunctional guide.

A metal cast bar was manufactured over the working model obtained by means of immediate postoperative molding, and Premium Heraeus Kulzer teeth (Hanau, Germany)

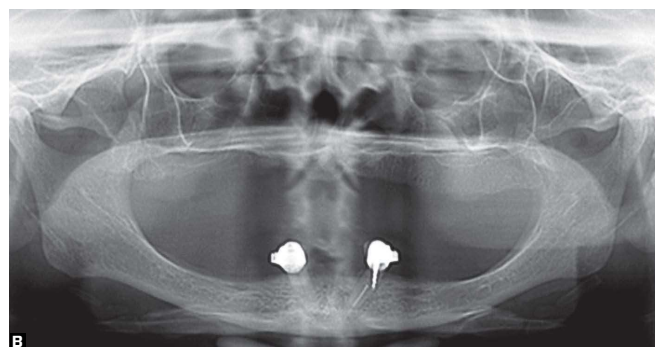
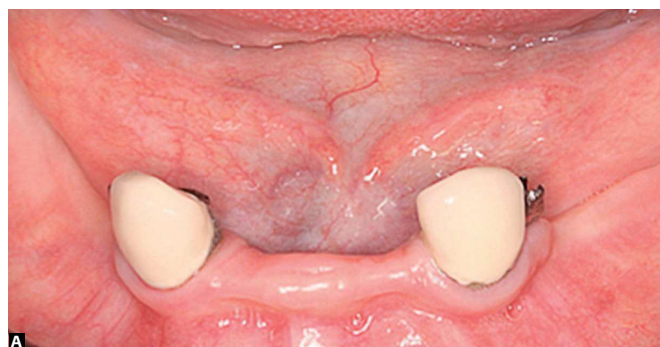

Figure 1 - Intraoral view at baseline; presence of mandibular canines; panoramic radiograph shows maxillary and mandibular atrophy.

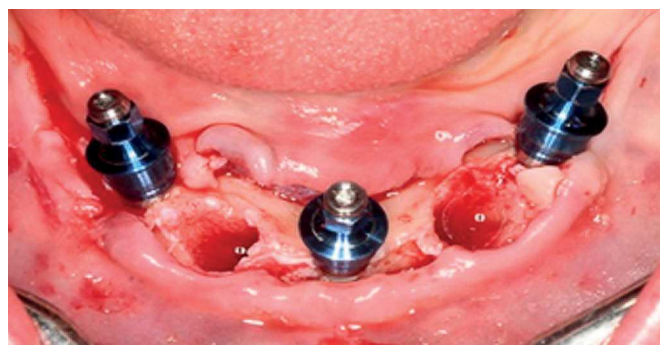


Figure 2 - Immediate postoperative appearance: 3 implants placed according to the Novum Branemark system.

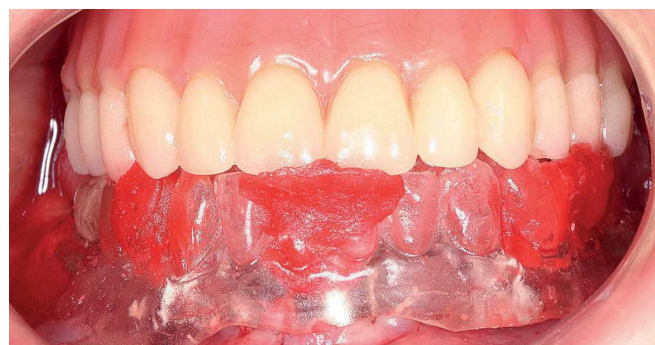

Figure 3 - Intraoral view of the interarch impression using a multifunctional guide.

were mounted on that bar using the model obtained by duplicating the maxillary complete denture as a reference.

After the try-in of the waxed teeth over the metal bar and the evaluation of the bar adjustment to the implants and of the position and occlusion between arches, the acrylic resin was activated and the denture was loaded onto the implants using a 20 N/cm² torque for the prosthetic screw and occlusal adjustment, respecting the principles of mutually protected occlusion (Fig 4).^{18,19}

After clinical and radiographic follow-up for 12 months, another CT scan of the maxilla was obtained and a model was produced to evaluate and plan the second

phase of the treatment and the placement of four immediate-loading zygomatic implants (Fig 5). Study models of the edentulous maxilla and the implant-supported denture were manufactured using Jeltrate Plus alginate (Dentsply, Caulk, Milford, USA) and the models based on the patient's maxillary denture were mounted on a semi-adjustable articulator.

Implant placement was performed in a hospital due to the complexity of the procedure and the severe bone resorption of the patient's maxilla. A single 3.75 x 25 mm P.I. Brånemark implant was placed in the proximal region of the left canine pillar. However, in the right side, which was more severely affected, a 42 mm zygomatic implant

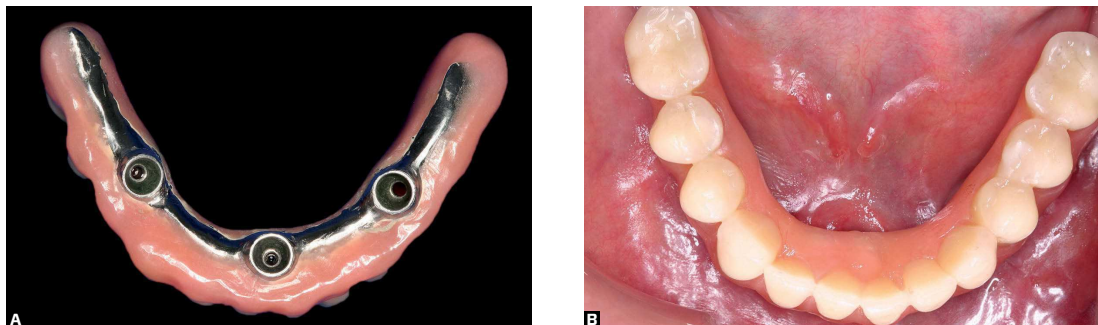


Figure 4 - Occlusal view of fixed mandibular denture 3 days postoperatively, and view of implant distribution and horizontal cantilever size.

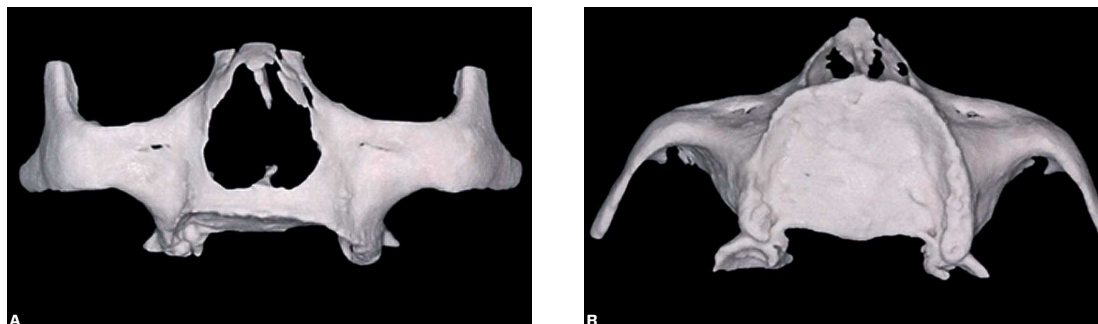


Figure 5 - 3D reconstruction of maxilla to demonstrate degree of atrophy and to plan and distribute zygomatic fixtures.

was placed, and two others, a right 40 mm and a left 42 mm implant, were positioned to emerge approximately in the region of the maxillary first molars.

Later, the patient was seen in the outpatient service and prosthetic rehabilitation of the mandible was performed using the same technique.

The metal bar united the four implants, and triple-compression acrylic resin teeth (Premium Heraeus Kulzer, Hanau, Germany) were mounted on wax for an aesthetic try-in and to check bar adaptation.

After acrylic polymerization, the maxillary denture was attached with screws to the implants using a torque of

20 N/cm² and occlusal adjustment (Fig 6) according to the principles of mutually protected occlusion.^{18,19}

One week after operation, panoramic and PA radiographs were obtained to evaluate implant position in relation to important craniofacial structures. The patient was seen for clinical and radiographic follow-up every six months for five years (Fig 7).

Evaluation of quality of life before and after fixed oral rehabilitation over osseointegrated implants

Quality of life was evaluated using the Oral Health Impact Profile (OHIP) questionnaire (Fig 8) and a visual analogue scale (VAS) (Fig 9). These instruments were used before

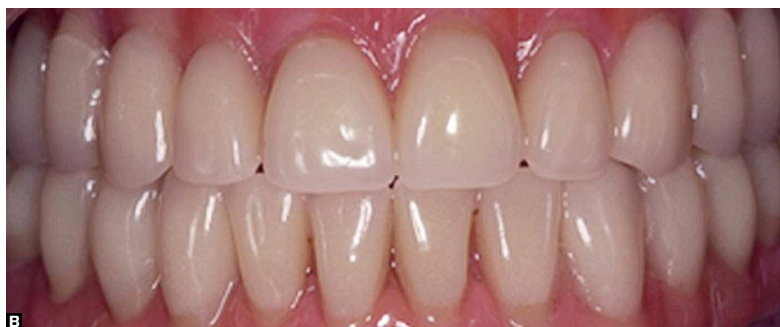
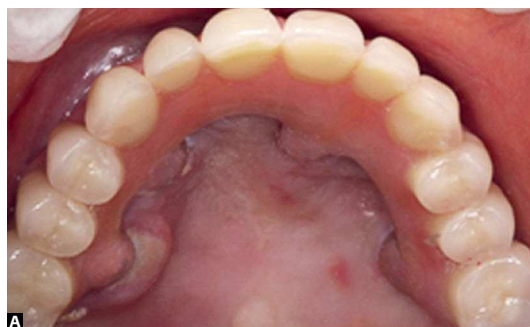
Figure 6 - Occlusal view of maxillary fixed denture 3 days postoperatively; final inter-arch relationship of maxillary and mandibular fixed dentures.

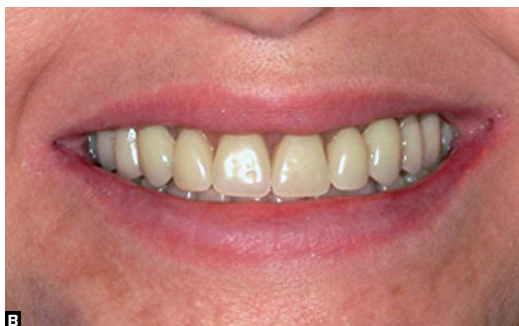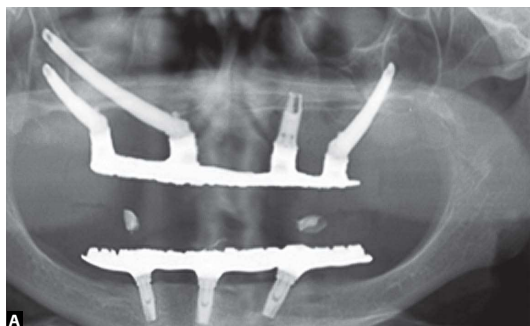


Figure 7 - Current clinical aspect and personal satisfaction with follow-up 5 years after fixed rehabilitation; control panoramic radiograph obtained every year after rehabilitation.

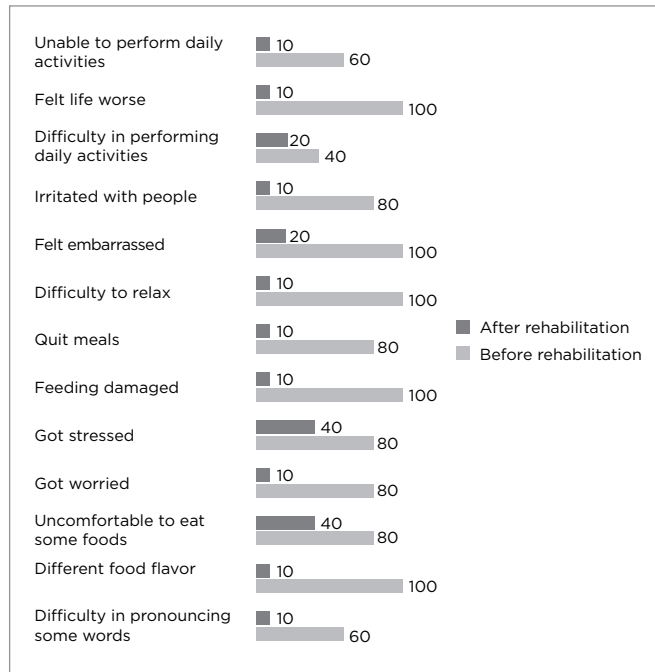


Figure 8 - Results of Oral Health Impact Profile (OHIP) questionnaire used to evaluate impact of fixed dentures on patient's quality of life.

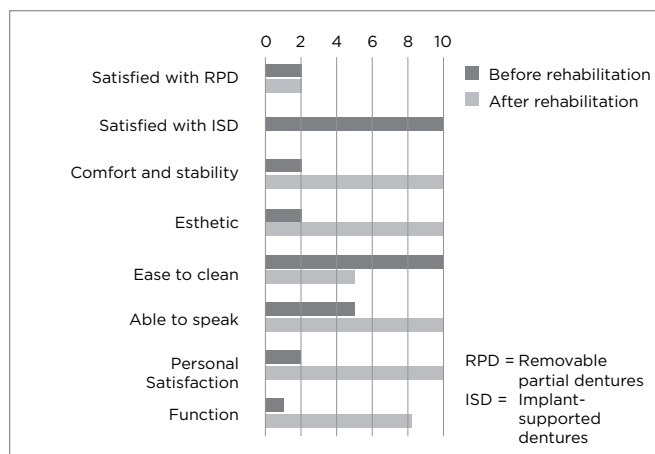


Figure 9 - Results of visual analog scale (VAS) used to evaluate impact of fixed dentures on patient's quality of life.

and 6 months after rehabilitation with immediate-loading osseointegrated implants to evaluate the patient's satisfaction with aesthetics, mastication and phonetics.

Discussion

Anodontia is a disabling functional and aesthetic condition for several people.⁷ Craniofacial abnormalities due to ectodermal dysplasia are, for many individuals, devastating psychological problems, because a compromised appearance associated with congenital defects may inhibit normal social interactions and result in deficient psychosocial development.¹

Some authors suggest that the treatment with implants should be delayed until skeletal growth is complete, and implant placement in growing patients is not recommended as a routine practice. Changes in implant position and height may result in complications, and factors such as growth variability between individuals and the difficulties in predicting the amount and direction of growth should be taken into consideration.^{3,7,20}

In a clinical study of individuals with ectodermal dysplasia, Lamazza et al³ did not find any changes in bone quality or bone healing, although a quantitative difference was found. However, radiographs taken at the time of definitive denture placement and 3 years later revealed that osseointegration was preserved, in agreement with the clinical results observed during the 5-year clinical and radiographic follow-up in our study.

Smith and Balshi,^{1,12} also reported that, at the time of the second surgical phase, implant fixation in patients with ectodermal dysplasia was similar to that of implants in edentulous patients without ectodermal dysplasia. Therefore, the oral rehabilitation of patients with ectodermal dysplasia should benefit from the modern concepts of treatment with osseointegrated implants, as well as from the use of bone grafting techniques, tissue engineering and advanced prosthodontics.

Peñarrocha-Diago et al²¹ described the oral rehabilitation of a patient with ectodermal dysplasia whose maxilla was severely atrophic. A fixed maxillary denture was placed over two zygomatic implants and three anterior implants in two surgical stages, and load was applied 6 months after implant placement.

The use of zygomatic fixtures and immediate-loading conventional implants for the rehabilitation of atrophic maxillae is a recent alternative, described in several studies in the literature.²²⁻²⁶

According to Duarte et al,²⁵ zygomatic fixtures have an excellent success rate, but attention should be paid to the basic concepts of this treatment, its correct indication and the experience of the dental surgeon.

The use of complete and removable partial dentures is closely associated with a low masticatory capacity and, consequently, a poor diet, which may lead to low weight and malnutrition, often found among elderly patients.

Implant-supported dentures play an important role in removing the psychological barriers created by the lack of teeth and in reestablishing aesthetics and function, which may lead to improvements in quality of life. The masticatory function of edentulous patients may be rehabilitated with implant-supported fixed dentures to a level similar to that of dentate patients.

Patients rehabilitated with implant-supported fixed dentures have a significant improvement in mastication, function, phonetics and aesthetic quality of the lower third of the face.

According to a study conducted by Duarte, patients rehabilitated with implant-supported fixed dentures had a high mean VAS result (close to 10) in the evaluation of satisfaction, which indicated an improvement in quality of life and made them feel more confident psychologically.

Quality of life should be fundamental in the choice of rehabilitation modality. The number of studies about quality of life and patient satisfaction has increased, and authors, have used questionnaires. The OHIP, which has objective questions about functional limitations, pain, psychological discomfort, physical disability, psychological disability, social disability and discomfort, has been used to evaluate changes resulting from the treatment with implant-supported fixed dentures.

In this study, quality of life was evaluated using the Oral Health Impact questionnaire (Graph 1) and a visual analogue scale (VAS). There were substantial improvements in mastication, word pronunciation and self-confidence. However, the patient also reported greater difficulty in oral hygiene when comparing the implant-supported fixed complete denture and the mandibular removable partial denture that she had before. This difficulty was eliminated by using a water flosser (Waterpik Inc., Fort Collins, CO) for complementary oral hygiene

Conclusion

Implant-supported dentures substantially improve quality of life of patients with ectodermal dysplasia and reestablish aesthetics and function. Further studies should follow up patients with this syndrome who received osseointegrated implants to evaluate long term results.

REFERENCES

1. Balshi TJ, Wolfinger GJ. Treatment of congenital ectodermal dysplasia with zygomatic implants: A case report. *Int J Oral Maxillofac Implants*. 2002 Mar-Apr;17(2):277-81.
2. Kim JH, Hoe YK, Oh JK. Interdisciplinary treatment for ectodermal dysplasia. *Korean J Orthod*. 2000 Dec;30(6):739-745.
3. Lamazza L, Cerulli GM, Favaretti F, De Biase A. Implant-prosthetic partial-arch restoration in a patient with ectodermal dysplasia characterized by oligodontia and localized bone deficiency: a case report. *Int J Oral Maxillofac Implants*. 2009 Jan-Feb;24(1):147-50.
4. Bal C, Bal BT, Tüfekçioğlu D. Treatment considerations for a patient with hypohidrotic ectodermal dysplasia: a case report. *J Contemp Dent Pract*. 2008 Mar 1;9(3):128-34.
5. Kaul S, Reddy R. Prosthetic rehabilitation of an adolescent with hypohidrotic ectodermal dysplasia with partial anodontia: case report. *J Indian Soc Pedod Prev Dent*. 2008 Dec;26(4):177-81.
6. Airene P. X-linked hypohidrotic ectodermal dysplasia in Finland. A clinical, radiographic and genetic study. *Proc Finn Dent Soc*. 1981;77 Suppl 1-3:1-107.
7. Becktor KB, Becktor JP, Keller EE. Growth analysis of a patient with ectodermal dysplasia treated with endosseous implants: a case report. *Int J Oral Maxillofac Implants*. 2001 Nov-Dec;16(6):864-74.
8. Freire-Maia N, Pinheiro M. Ectodermal dysplasias: Some recollections and a classification. *Birth Defects Orig Artic Ser*. 1988;24(2):3-14.
9. Guckes AD, Scurria MS, King TS, McCarthy GR, Brahim JS. Prospective clinical trial of dental implants in persons with ectodermal dysplasia. *J Prosthet Dent*. 2002 Jul;88(1):21-5.
10. Bolender CL, Law DB, Austin LB. Prosthodontic treatment of ectodermal dysplasia: A case report. *J Prosthet Dent* 1995;19:167-72.
11. Kearns G, Sharma A, Perrott D, Schmidt B, Kaban L, Vargervik K. Placement of endosseous implants in children and adolescents with hereditary ectodermal dysplasia. *Oral Surg Oral Med Oral Pathol Oral Radiol Endod*. 1999 Jul;88(1):5-10.
12. Smith RA, Vargervik K, Kearns G, Bosch C, Koumjian J. Placement of an endosseous implant in a growing child with ectodermal dysplasia. *Oral Surg Oral Med Oral Pathol*. 1993 Jun;75(6):669-73.
13. Duarte LR. Estabelecimento de protocolo para reabilitação de totais de maxilas atroficas empregando fixações zigomáticas em sistema de carga imediata [Dissertação]. Bauru (SP): Universidade Sagrado Coração; 2005
14. Nary Filho H, Padovan LEM. Fixação zigomática. São Paulo (SP): Ed. Santos; 2008.
15. Telles D, Hollweg H, Castellucci L. Prótese total convencional e sobre implantes. 2ª ed. São Paulo (SP): Ed. Santos; 2004.
16. Pegoraro L F. Organizador. Prótese fixa. São Paulo (SP): Artes Médicas; 2002. Cap. 1, p. 1-22.
17. Roy M. Pyorrhea alveolaris: Its nature, pathogeny and treatment. *Dent Cosmos*. 1930 Apr;1:390-9.
18. Kim Y, Oh TJ, Misch CE, Wang HL. Occlusal considerations in implant therapy: clinical guidelines with biomechanical rationale. *Clin Oral Implants Res*. 2005 Feb;16(1):26-35.
19. Sanita PV, Pinelli LAP, Silva RHBT, Segalla JCM. Aplicação clínica dos conceitos oclusais na Implantodontia. *RFO UPF*. 2009 Set-Dez;14(3):268-75.
20. Heij DG, Opdebeeck H, van Steenberghe D, Kokich VG, Belser U, Quirynen M. Facial development, continuous tooth eruption, and mesial drift as compromising factors for implant placement. *Int J Oral Maxillofac Implants*. 2006 Nov-Dec;21(6):867-78.
21. Peñarrocha-Diago M, Uribe-Origone R, Rambla-Ferrer J, Guarinos-Carbó J. Fixed rehabilitation of a patient with hypohidrotic ectodermal dysplasia using zygomatic implants. *Oral Surg Oral Med Oral Pathol Oral Radiol Endod*. 2004 Aug;98(2):161-5.
22. Lima HE, Bresaola MD, Nary Filho H. Estudo retrospectivo de reabilitação em maxilas atroficas usando fixações zigomáticas. *Rev. Dental Press Periodontia Implantol*. 2008 Abr-Jun;2(2):80-90.
23. Galán Gil S, Peñarrocha-Diago M, Balaguer Martínez J, Marti Bowen E. Rehabilitation of severely resorbed maxillae with zygomatic implants: an update. *Med Oral Patol Oral Cir Bucal*. 2007 May 1;12(3):e216-20.
24. Duarte LR, Peredo LG, Nary Filho H, Francischone CE, Brånemark PI. Reabilitação da maxila atrofica utilizando quatro fixações zigomáticas em sistema de carga imediata. *ImplantNews*. 2004 Jan-Fev;1(1):45-50.
25. Duarte LR, Peredo LG, Nary Filho H, Francischone Junior CE, Viana A. Fixações zigomáticas: uma excelente alternativa cirúrgica para maxila severamente reabsorvida. Revisão de literatura e estágio científico atual. *Implant News*. 2004 Nov-Dez;1(6):477-86.
26. Duarte LR, Filho HN, Francischone CE, Peredo LG, Brånemark PI. The establishment of a protocol for the total rehabilitation of atrophic maxillae employing four zygomatic fixtures in an immediate loading system — a 30-month clinical and radiographic follow-up. *Clin Implant Dent Relat Res*. 2007 Dec;9(4):186-96.
27. Branemark PI. The zygomaticus fixture: clinical procedures. Goteborg (Sw): Nobel Biocare AB; 1998.