

Treatment of vertical alveolar defects by means of osteogenic distraction technique

Bruno Botto de Barros da **SILVEIRA***
 Caetano Guilherme Carvalho **PONTES****
 Rodrigo Tavares **BOMFIM*****
 Maysa Nogueira Ferreira de **BARROS****
 Maurício Costa de **ARAÚJO******
 Dario Augusto Oliveira **MIRANDA*******

Abstract

Introduction: Alveolar reconstruction of vertical bone defects remains a daunting challenge in implant dentistry. Among the various techniques used to correct such defects is distraction osteogenesis (DO), which has been described as a technique used to gain bone and soft tissues, especially in surgeries for reconstruction of mandibular and maxillary alveolar ridges to allow the placement of dental implants in a favorable position and with greater success predictability when subjected to functional loads. **Objective:** The purpose of this study was to evaluate the effectiveness of DO in two patients treated with the technique of alveolar distraction osteogenesis. **Case report:** The clinical cases were evaluated for bone gain through clinical and radiographic examination, pre- and post-distraction. **Results:** At the end of treatment, both cases had gained sufficient bone as to enable subsequent rehabilitation with implants. **Conclusions:** The success rate reported in the literature and in the cases presented here prove the efficiency of the technique and its clinical feasibility.

Keywords: Distraction. Implant Dentistry.

How to cite this article: Silveira BBB, Pontes CGC, Bomfim RT, Barros MNF, Araújo MC, Miranda DAO. Treatment of vertical alveolar defects by means of osteogenic distraction technique. Dental Press Periodontol Implant Dent. 2012 July-Sept;6(3):52-9.

» The authors inform that they do not have no associative, commercial, intellectual property, or financial interests representing a conflict of interest in products and companies described in this article.

Contact address

Dario Augusto O. Miranda
 Av. Ademar de Barros, 58, Apt 309 - Ondina
 Zip code: 40.170-110 - Salvador/BA
 E-mail: darioperiodonto@hotmail.com

Submitted on: June 20, 2012.
 Reviewed and received on: June 23, 2012.

* MSc in Dentistry, UFBA. Resident in Oral and Maxillofacial Surgery, Santo Antônio Hospital, UFBA.

** Resident in Oral and Maxillofacial Surgery, Santo Antônio Hospital, UFBA.

*** Specialist in Oral and Maxillofacial Surgery, Santo Antônio Hospital, UFBA. MSc in Dentistry, UFBA.

**** Resident in Oral and Maxillofacial Surgery, Santo Antônio Hospital, UFBA.

***** Specialist in Periodontics, APCD. Implant Specialist, ABO-BA.

***** PhD in Implantology, São Leopoldo Mandic. MSc in Periodontics and Implant Dentistry, University of Illinois at Chicago. Professor, UEFS.

Introduction

Over the years, reconstructive bone surgeries for placing dental implants have been increasingly employed.¹⁻⁵ Several strategies in bone tissue engineering have been developed in the last decade.^{1,6} More recently, a technique called “distraction: osteogenesis” has enjoyed widespread acceptance.^{1,2,6,7,8}

Distraction osteogenesis (DO) is a technique whereby the gradual separation of surgically excised bony margins result in the growth of new bone structure.^{6,9,10} The advantages of this technique include the opportunity to obtain a natural bone formation between segments,⁶ the ability to achieve greater expansion than other techniques, and decreased likelihood of dehiscence due to a gradual expansion of the surrounding tissues, which promotes neo-histogenesis^{2,3,11} in the region.^{5,6,10}

Based on the presentation of two duly documented clinical cases in which patients with vertical alveolar bone defects underwent DO, the present study aims to evaluate the application of this technique in parallel to the analysis of clinical success and potential complications.

Cases reports

Two clinical cases were evaluated in terms of bone gain through clinical and radiographic examination be-

fore and after distraction to verify the effectiveness of DO technique.

Clinical case 1

The patient, a 31-year-old Afro-Brazilian male, was referred to the Brazilian Association of Dentistry/Bahia State section, with a view to undergoing rehabilitative treatment with implants in the anterior mandible.

After thorough clinical and radiographic examination, the absence of mandibular incisors was noted, as well as severe vertical bone loss, for which bone distraction surgery was indicated as a therapeutic option (Figs 1, 2 and 3).

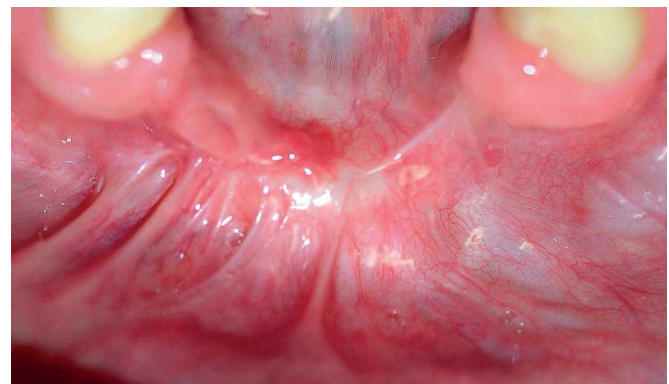


Figure 1 - Patient's initial condition.

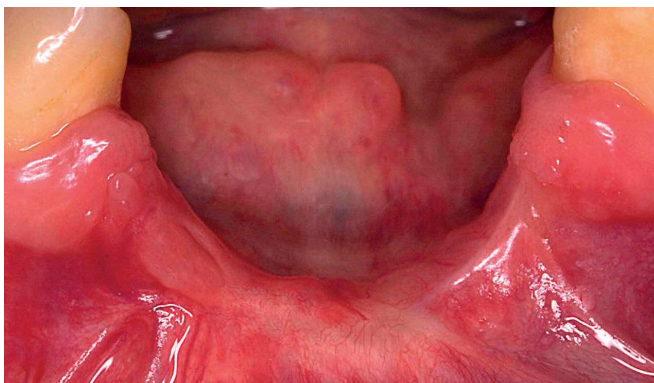


Figure 2 - Large vertical bone defect observed.

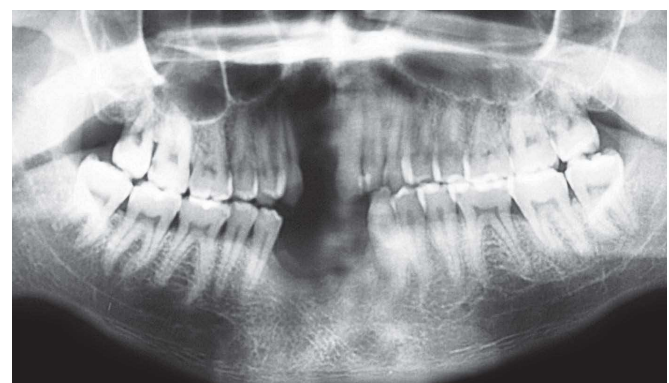


Figure 3 - Initial radiograph of the case.

Bone distraction involves a surgical phase, latency period, distraction phase, and a second latency period. The final, rehabilitative phase is then begun.

In the surgical phase, a horizontal incision was performed limited to 5 mm of the crest of the bone ridge located under the gum tissue (previously grafted), total flap detachment, followed by adjustment and screwing of intraoral distractor (Connection®) on the bone bed in order to delimit the area selected for osteotomy. Thereafter, the distractor was removed and osteotomy performed with surgical drills, imparting a trapezoidal, slightly expulsive shape to the bone block (osteotomy of the lingual cortex was also per-

formed with the aid of a chisel (Figs 4 to 7). After block preparation, the distractor was fully activated to test its functionality, eventually returning it to its original position (Fig 8). Finally, the soft tissues were sutured with 5-0 nylon (Fig 9) and then a temporary perforated denture was placed.

During the latency period, the distractor was kept immobile in the surgical region for 7 days, and the posterior distraction process involved an activation rate of 0.7 mm per day (two complete turns). During these stages, the surgery was monitored and controlled, which confirmed a sudden mobility of the distractor during activation on the fifth day following the surgery.

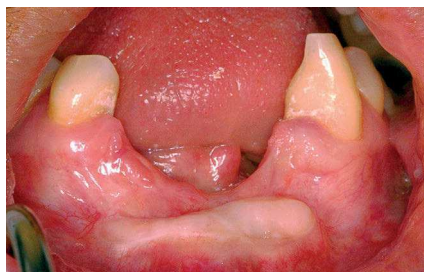

Figure 4 - Region after healing of free graft.

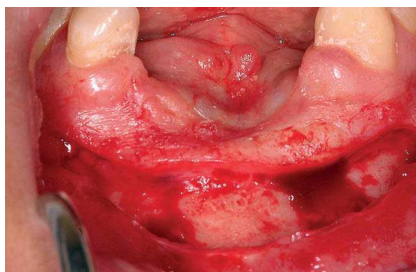


Figure 5 - Incision and initial detachment preserving lingual tissue and bone crest.

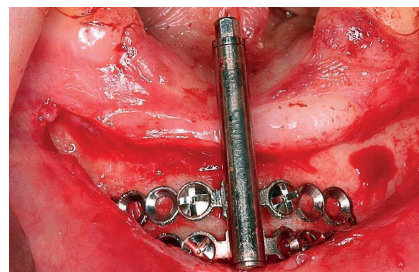


Figure 6 - Distractor fastened, delimiting the osteotomy area.

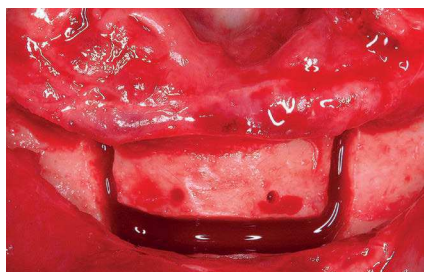


Figure 7 - After osteotomy.

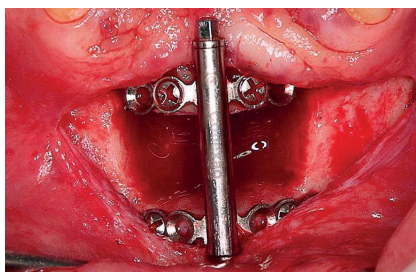


Figure 8 - Full activation of the distractor to eliminate potential interference.

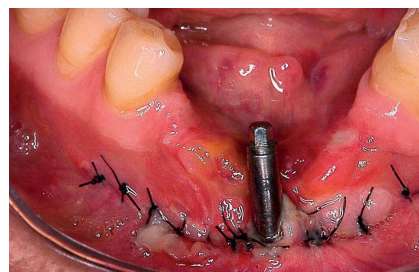


Figure 9 - Final suture.

The surgery site was explored, with a rupture being detected in the distractor, more specifically in the spot weld of the guiding rod (Fig 10). The distractor was removed, a new device was installed, and a new latency period (7 days) initiated with the device being activated 1.05 mm per day, in single movements, for 9 days.

The device was also immobilized for a period of 4 months (Fig 11), and it was recommended that the area be cleaned with chlorhexidine at 0.12%.

After this period, a panoramic radiograph was taken, which showed a satisfactory gain of bone tissue in the area between the distractor plates (Fig 12). In the rehabilitation phase, the site was reopened, the distractor removed and two 3.75 x 15mm implants (SIN[®], National Implant System) placed (Fig 13). Two months after implant placement, a temporary denture was screwed onto the implants (Fig 14). The patient is currently scheduled for placement of a permanent denture.

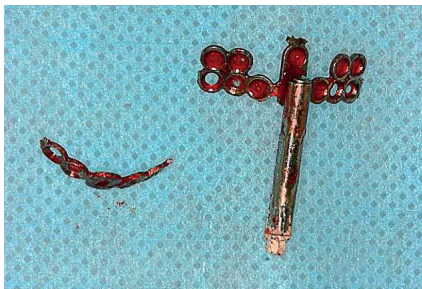

Figure 10 - Distractor fractured.

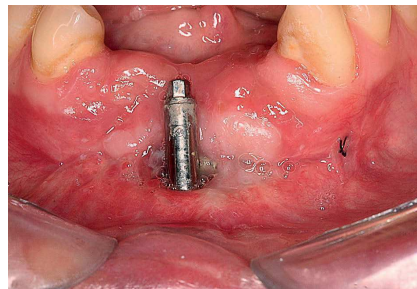


Figure 11 - View after completing distractor activation.

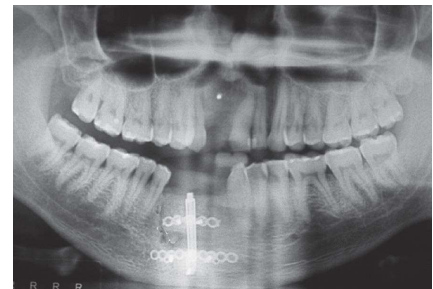


Figure 12 - Radiograph after latency period showing growth achieved with the technique.

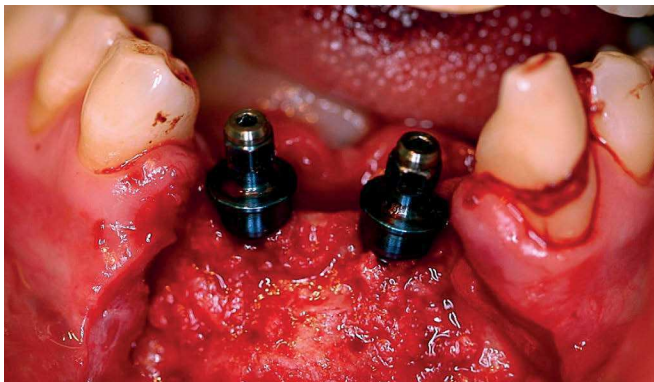

Figure 13 - Placement of implants.

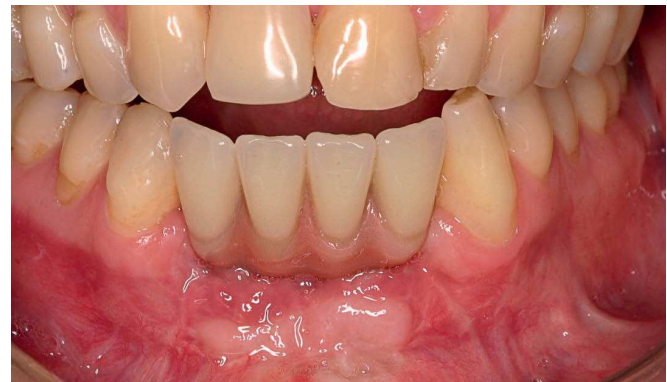

Figure 14 - Implant-supported temporary denture in place.

Clinical case 2

The patient was a 23-year-old Afro-Brazilian male, with a history of injury by firearm two years earlier, resulting in a mandible fracture. The fracture was treated by the oral and maxillofacial surgery and traumatology team of Santo Antônio Hospital, Bahia State Federal University (UFBA), and the patient's anterior mandible rehabilitation was planned for one year thereafter.

Clinical and radiographic examination (Figs 15 to 18) showed marked bone loss in the anterior mandible, a factor that precludes rehabilitation treatment with dentures. It was decided, therefore, to perform bone distraction surgery and subsequent implant rehabilitation at the Implant Dentistry clinic of the Bahia State Federal University.

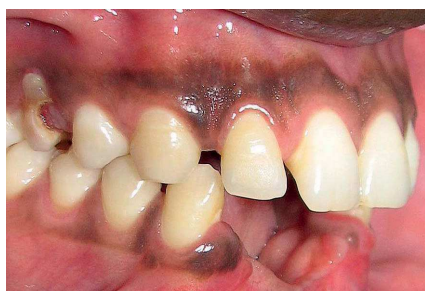

Figure 15 - Initial clinical condition (right side view).

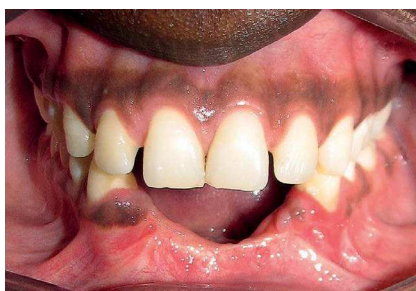

Figure 16 - Initial clinical condition (front view).

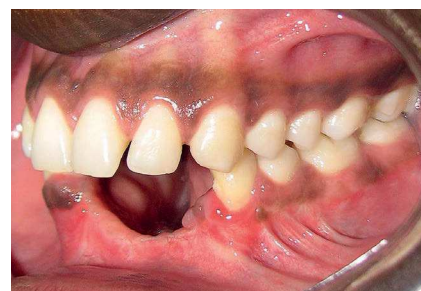

Figure 17 - Initial clinical condition (left side view).

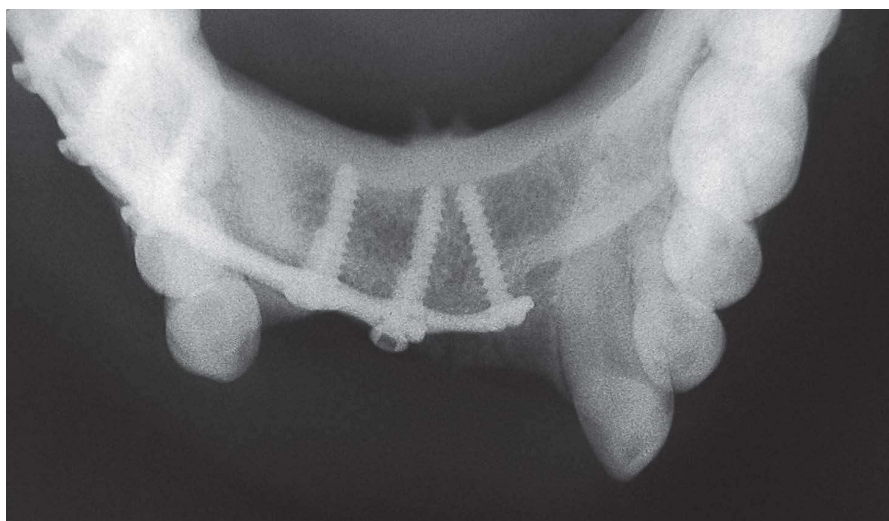


Figure 18 - Initial radiograph.

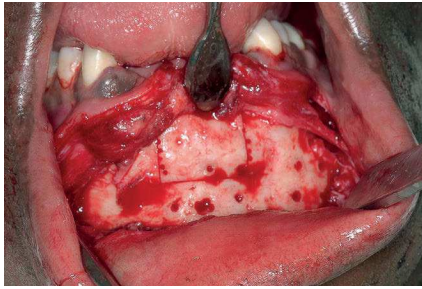


Figure 19 - Osteotomy.

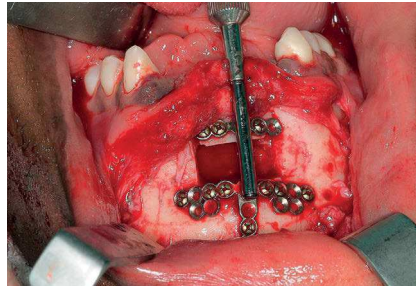


Figure 20 - Testing distractor in place.

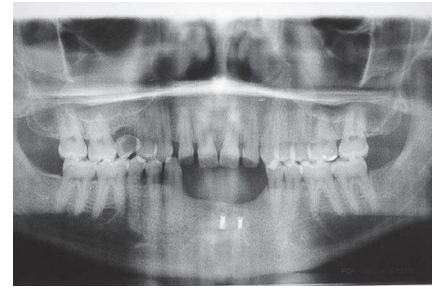


Figure 21 - Panoramic radiograph of jaws after distraction.

Performance of bone distraction involved the same phases mentioned in the previous clinical case, i.e., Surgical phase, latency period, distraction phase, second latency period and rehabilitation phase.

The surgical phase involved a horizontal incision in the crest of the bone ridge with two relaxants in the symphysis region, total flap detachment, followed by removal of rigid internal fixation, adjustment and screwing of intraoral distractor (Conexão®) onto the bone bed in order to delimit the area selected for the osteotomy. The distractor was then removed and osteotomy performed with surgical drills, imparting to the bone block a slightly expulsive, trapezoidal shape, (lingual cortex osteotomy was also carried out with a chisel) (Figs 4 and 7). The distractor was activated maximally and then returned to its original position (Fig 20). Finally, the soft tissues were sutured with 5-0 nylon.

The latency period lasted 7 days and the posterior distraction procedure involved activation at a rate of 0.7 mm per day (two complete turns) during 9 days. During these steps, the surgery was monitored and controlled. On the tenth day, the distractor was immobilized for a period of 4 months, with a recommendation to sanitize the area with chlorhexidine 0.12%.

After this period, the site was reopened to remove the distractor and onlay grafts removed from the jaw to thicken

the area where the distraction had been performed. Panoramic radiography revealed that there was satisfactory gain in bone tissue between the plates (Fig 21).

Currently, the patient is scheduled for placement of dental implants in that region.

Discussion

The stress generated by applying tensile strength to the tissues metabolically activates cells of the affected area, thus increasing the mitotic index and protein synthesis.¹² Preserving the tissues during osteotomy is essential for maintaining the vitality of the transport segment.^{6,13} In this study, an incision was performed over the alveolar bone crest, leaving a wide band of attached tissue on the bone crest, thus preserving the periosteum and tissue structure in the lingual area.⁴

Although the stability of the distraction device is critical in new bone synthesis processes,^{4,6} one cannot lose sight of the importance of a stable fixation, a condition that provides the intramembranous formation² of a bony callus within a short period of time^{6,12} due to high oxygen saturation in the surgical wound. It should be borne in mind that micromovements may be responsible for a decrease in oxygen concentration in the bony callus, leading to slower endochondral type ossification with prior formation of fibrocartilages and occasional bond failure of the segment.^{4,12}

The latency period is the period between osteotomy and early activation of the distractor.^{4,6,12} The histological sequence during the latency period is similar to fracture healing.⁶ Clinically, a latency period of seven days appears to be more efficient. However, the age of the patient as well as local conditions are factors that may determine postponement or curtailment of this time frame.^{4,12} Distraction rhythm is paramount for a successful procedure. Activations of less than 0.5 mm per day could lead to premature ossification of the fragment, while 2 mm activations can lead to fibrous filling of the regenerating area^{4,12} as well as ischemia in the tissue undergoing formation, which results in bone resorption, or else deficient fragment bonding.⁴ A range between 0.5 mm and 1 mm per day is ideal for both long bones and bones in the craniofacial complex.^{4,10,12} Finally, the consolidation period takes place between the end of the distraction and distractor removal, which must be held immobile in the region until removal.¹² The time length reported in the literature for consolidation ranges from 3 weeks to 3 months.⁴ In the cases reported here, a period of four months proved satisfactory in meeting the expected functional and aesthetic requirements.

A multicentric,² prospective study conducted with 34 patients who had undergone distraction surgery and placement of 138 implants showed a cumulative success rate of 94.2% four years after placing the dentures. However, in another prospective study with humans,¹³ after 5 years' intervention the researchers responsible for the study reported having achieved a 90.4% success rate of implants placed in the region subjected to distraction. In comparing alveolar bone distraction with the technique of guided bone regeneration, McAllister and Gaffaney¹³ found positive results for both techniques. However, bone resorption detected before and

after implantation was higher in the group treated by guided bone regeneration (GBR). This finding led the authors to attribute greater predictability and a better prognosis for patients treated by bone distraction.⁸

Although the incidence of complications in distraction osteogenesis is relatively low, important studies¹⁴ reported on the possibility of fracture occurring in the transport segment, handling difficulties due to the length of the activation rod, difficulties in finishing osteotomy in the lingual region, incorrect direction of the distraction vector,⁹ perforation of the mucosa on the distraction disc, suture¹⁵ dehiscence, infection and injury to the nerves and adjacent teeth.¹¹

However, another major retrospective study¹⁵ involving complications in 72 distraction cases indicate that 56.95% of cases were treated without complications, versus 43.05% of patients who had some type of complication when subjected to this technique. Most complications were classified as minor, such as edema, infection, small dehiscences, excessive inclination of the transport disc and paresthesia. The major complications surrounding the fracture of the device were scar tissue formation, fracture and resorption of the transport segment, fracture of bony structures or large dehiscences.¹⁵ In the present study there was a fracture in the distractor in the first case reported, necessitating further surgery to remove the fractured distractor and insertion of a new distractor.

In the case reports presented in this article, the performance of successive clinical and surgical procedures yielded successful results, with proven vertical gain of alveolar bone, although segment transport in a contaminated area such as the mouth can be considered critical.

Conclusions

Distraction osteogenesis as described in this article has proven a safe surgical alternative to the vertical reconstruction of alveolar bone ridges. However, mastery of a detailed technique and patient cooperation are key elements for a successful treatment. A careful evaluation

of each case should yield the benefits outlined in the proposed technique since the occasional loss of a transport segment can compromise rehabilitation. The high success rates described in the literature show that the technique is both effective and clinically viable, which is further attested by the cases presented in this article.

REFERENCES

1. Aragon CE, Bohay RN. The Application of alveolar osteogenesis following nonresorbable hidroxyapatite grafting in the anterior maxilla: a clinical report. *J Prosthet Dent.* 2005;93:518-21.
2. Chiapasco M, Consolo U, Bianchi A, Ronchi P. Alveolar distraction osteogenesis for the correction of vertically deficient edentulous ridges: a multicenter prospective study on humans. *Int J oral Maxillofac Implants.* 2004;19:399-407.
3. Chiapasco M, Romeo E, Casentini P, Rimondini L. Alveolar distraction osteogenesis vs. vertical guided bone regeneration for the correction of vertically deficient edentulous ridges: a 1-3 year prospective study on humans. *Clin Oral Impl Res.* 2004;15:82-95.
4. Ley J, Cranin NA. Distraction osteogenesis for augmenting the deficient alveolar ridge in preparation for dental implant placement: a case report. *J Oral Implantology.* 2004;30:14-22.
5. McAllister BS. Histologic and radiographic evidence of vertical ridge augmentation utilizing distraction osteogenesis: 10 consecutively placed distractors. *J Periodontol.* 2001;72:1767-79.
6. Garcia AG, Martin MS, Vila PG, Meceiras JL. Minor complications arising in alveolar distraction osteogenesis. *J Oral Maxillofac Surg.* 2002;60(5):496-501.
7. Zimmermann CE, Thurmuller P, Troulis MJ, Perrot DH, Rahn B, Kaban LB. Histology of the porcine mandibular distraction wound. *J Oral Maxillofac Surg.* 2005;34:411-9.
8. Garcia AG, Martin MS, Vila PG, Saulacic N, Rey JMG. Alveolar distraction before insertion of dental implants in posterior mandible. *Br J Oral Maxillofac Surg.* 2003;41:376-9.
9. Jensen OT, Cockrell R, Kuhlke L, Reed C. Anterior maxillary alveolar distraction osteogenesis: a prospective 5-years clinical study. *Int J Oral Maxillofac Implants.* 2002;17:52-68.
10. Mazzoneto R, Maurette MA, Torezan JFR. Avaliação das complicações presentes em 72 casos tratados com distração osteogênica alveolar. *ImplantNews.* 2005;2(3):245-9.
11. Samchukov ML, Cherkashin AM, Cope JB. Distraction osteogenesis: history and biologic basis of new bone formation. In: Linch SE, Genco RJ, Marx RE. *Tissue engineering applications in maxillofacial surgery and periodontics.* Hanover Park (IL): Quintessence; 1999. Cap 8, p. 131-46.
12. Pinto AVS, Miyagusko JM, Soares MM, Juazeiro PP, Yamada AT, Pereira LAV. Distração osteogênica. In: Dinato JC, Polido VD. *Implante osteointegrados: cirurgia e prótese.* São Paulo (SP): Artes Médicas; 2001. Cap. 19, p. 397-421.
13. McAllister BS, Gaffaney TE. Distraction osteogenesis for vertical bone augmentation prior to oral implant reconstruction. *Periodontol2000.* 2003;33:54-66.
14. Gellrich N, Suarez-Cunqueiro MM, Schon R, Hoffmann M, Schramm A. Distraction osteogenesis in an anterior mandibular bone defects utilizing lingual periosteal release: a case report. *Int J oral Maxillofac Implants.* 2004;19:753-7.
15. Robiony M, Toro C, Stucki-McCormick SU, Zerman N, Costa F, Politi M. The "FAD", Floating Alveolar Device: a bidirectional distraction osteogenesis of the alveolar process. *J oral Maxillofac Surg.* 2004 Sep;62(9 Suppl 2):136-42.