

# Surgical strategies for extraction sockets seal

Walter **MARTINS JUNIOR\***

The discovery of the biological phenomenon of osseointegration established treatment options that permanently modified the way to rehabilitate partially or totally edentulous patients. Thus, in this contemporary scenario of the profession, a situation of particular clinical interest is that in which the extraction of a dental element is necessary and the choice for actions to be taken for the most adequate solution of the case is decisive to the patient and to the professional.

Some aspects are very important for the decision to install an implant after extraction, generally determined, in clinical practice, by some characteristics presented by the alveolus mucosal and bone tissue.<sup>2</sup> For this reason, several ways have been suggested to classify the moment of installation of the implant in relation to the tooth extraction.<sup>3,4</sup> These proposals are based, mostly, on the repair stages of soft and hard tissues, decisive events to determine the most favorable treatment for each particular case. This way it is possible to establish

a protocol that standardize the conduct to be taken, optimizing the achieved results.<sup>5,6</sup>

The classification of Hammerle et al,<sup>7</sup> presented below, is today the most appropriate to define the moment of installation of the implant in relation to the stage of alveolar healing:

- Installation of the implant after tooth extraction, as part of the same surgical procedure — Immediate placement, type 1.
- Installation after the full coverage of soft tissue over the alveolus, generally between 4 and 8 weeks after the extraction — Early placement, type 2.
- Installation after the clinical and/or radiographic substantial fill up of the alveolus, generally between 12 and 16 weeks after the extraction — Late placement, type 3.
- Installation after the complete fill up of the alveolus, generally after 16 weeks - Late placement, type 4.

**How to cite this article:** Martins Junior W. Surgical strategies for extraction sockets seal. *Dental Press Implantol.* 2013 Jan-Mar;7(1):18-29.

» The author reports no commercial, proprietary or financial interest in the products or companies described in this article.

#### Contact address

**Walter Martins Junior**  
Rua Marechal Deodoro, 1408 - CEP: 14.025-210 - Ribeirão Preto/SP, Brazil  
E-mail: juniormartins3262@gmail.com

Submitted: March 04, 2013  
Revised and accepted: August 08, 2013

\*Full Professor of Periodontics, Ribeirão Preto University (UNAERP).

It is interesting to observe that in all four situations established in this classification,<sup>7</sup> additional procedures for the sealing of the alveolus are necessary when the prosthetic restoration is not performed immediately or in the initial periods after the implant installation. Although a recent work, assessing the alveolar healing in dogs, has shown excellent regeneration of the area with no action to occlude the alveolus,<sup>8</sup> the full alveolar sealing with soft tissue seems to favor the procedures of healing in humans. The physical interference that can occur during the alveolus tissue reparation, as well as a possible microbial contamination, can be minimized by these maneuvers,<sup>9,10</sup> providing adequate conditions for the period of osseointegration and/or guided bone regeneration and, in many cases, also favoring the aesthetics.<sup>11,12</sup>

Some characteristics are desirable for the adequate handling of the soft tissue on the procedures for alveolus sealing:<sup>13,14</sup>

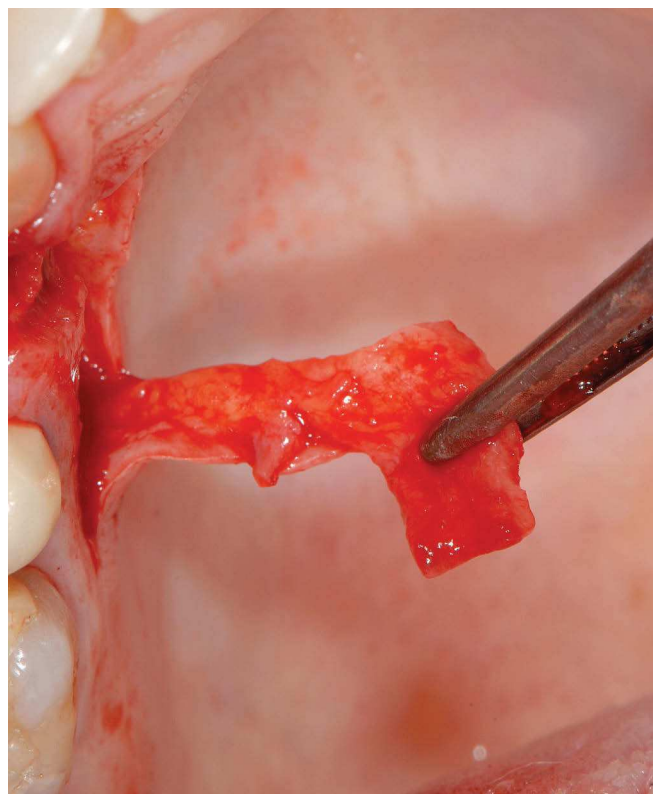
- The technique must be easy, quick and with high predictability.
- It must be minimally traumatic and invasive.
- Allow the full sealing of the alveolus without tension on the flap and adjacent tissues.
- Favor the aesthetics with maintenance of the vestibule shape, parabolic contour and depth.
- Applicable to unitary and multiple cases.
- Have applicability in guided regenerations.

Due to these considerations, it is interesting a more systematic analysis of the different surgical procedures that allow the alveolus sealing, always verifying that the remaining alveolar bone structures remain integrate or with little compromising in its buccal plate. Thus, the available surgical resources make use of flaps, grafts and barriers on the following described techniques.

## Flap

By definition, flap is a section of tissue separated of the adjacent tissues, except for its base<sup>15</sup> (Fig 1). The displaced tissue, for being nourished through a pedicle, presents, theoretically, a prognosis more favorable to the maintenance of its vitality.

Several surgical techniques using different types of flap were developed in the 90s,<sup>16</sup> aiming to promote the sealing of the alveolus and to cover the different membranes used for the procedures of guided bone regeneration developed in this period. These procedures passed through a long evolutionary process of improvement, creating the fundamentals for handling of soft tissues in the peri-implant areas, providing accurate esthetical and functional sophistication to these rehabilitator procedures.



**Figure 1** - Flap.

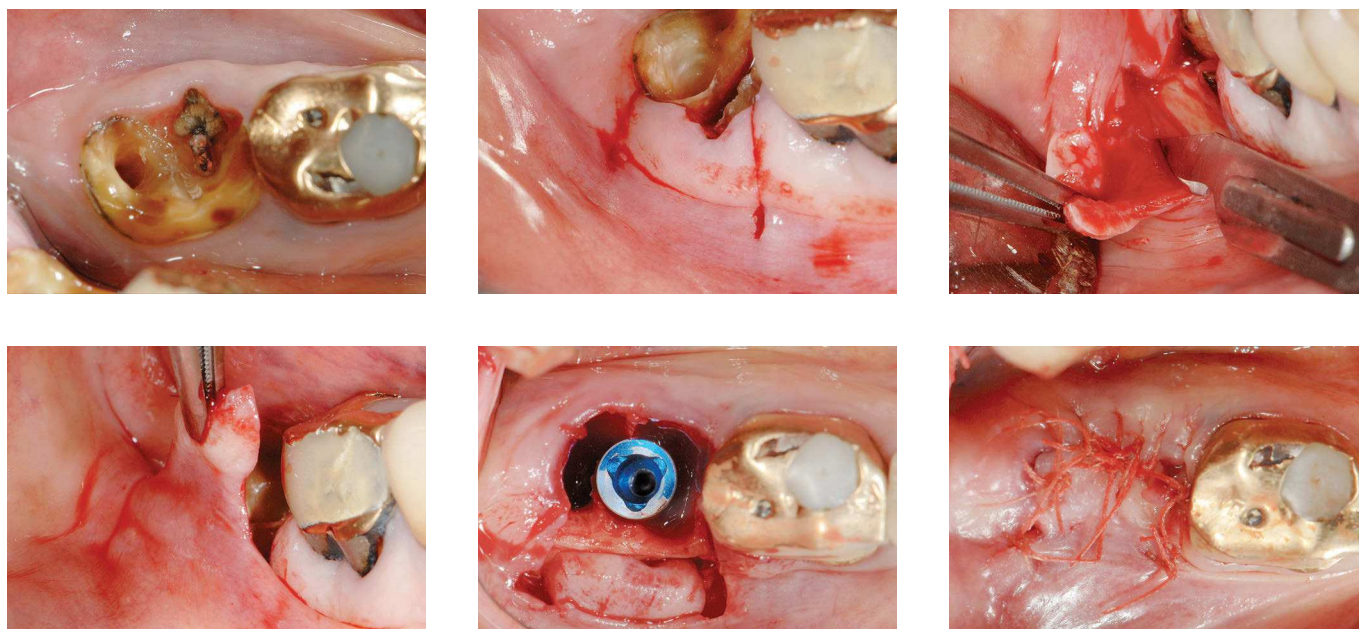
### Buccal flap

Becker and Becker<sup>17</sup> were the first to describe one of these reported techniques, which consists, basically, in two relaxing incisions, perpendicular and slightly divergent from the top of the flange to the bottom of the vestibule. Incisions in the periosteum provide a greater mobilization of the full-thickness flap, folded and slipped towards the alveolus for its sealing (Fig 2).

Changes were described soon after.<sup>18,19</sup> Buser et al<sup>20</sup> described a variant for the mandible, in which the flap is made with a epiperiosteal incision on the buccal wall, near to the top of the crest, which continues

coronally to the mucogingival junction. At this point, a mucoperiosteal full-flap is mobilized to lingual. The closure is achieved with mattress and interrupted suture techniques.

The main requirement of these procedures is the presence of an adequate keratinized mucosa zone. It must also be considered the aesthetic implication on the decrease of the vestibule depth and the discrepancy of the mucogingival junction in relation to the surrounding area. Its main recommendation must be in upper posterior areas, with little esthetic need, or in inferior areas where the palate is not available for rotation flaps.



**Figure 2** - Buccal flap.

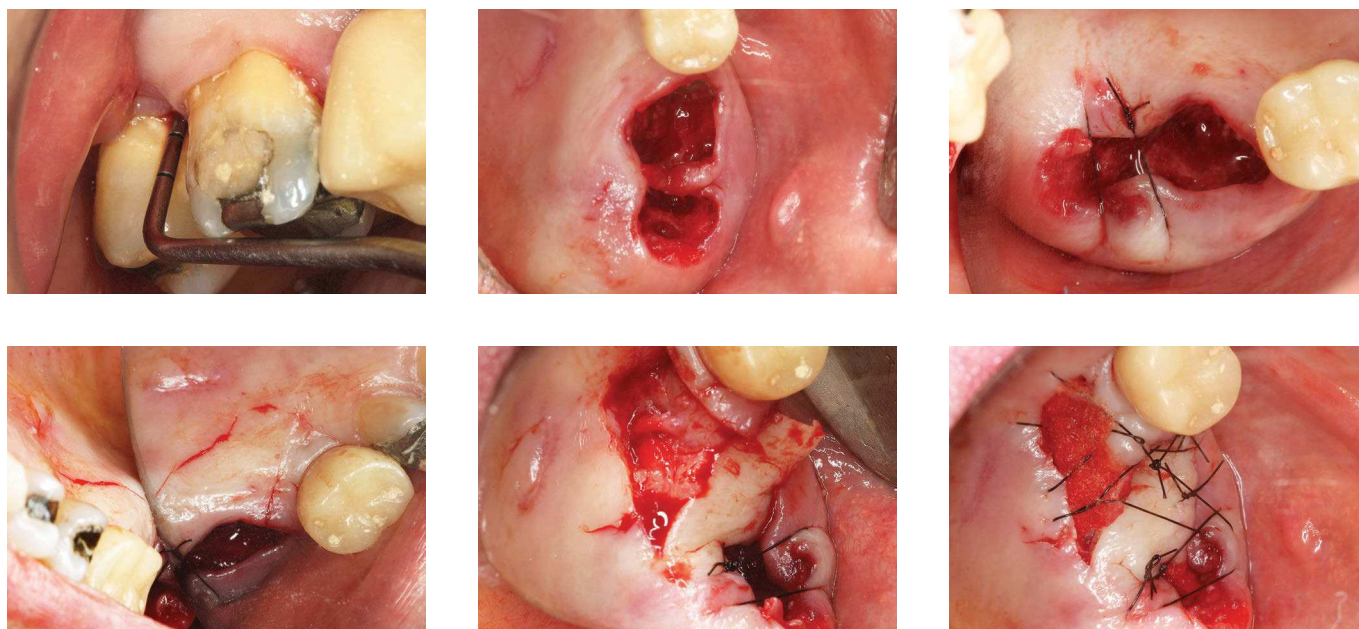
### Palatal flap

The possibility to obtain tissue from the palate for the alveolus sealing must be considered for being this a masticatory type mucosa, which is the ideal tissue for biological sealing of the peri-implant sulcus.<sup>21</sup>

This area also allows for the performance of partial or full-flaps. The great limitation of this technique is the presence of the palatine artery near the donor area, which occurs mainly in shallow palates. It must also be considered the possible postoperative discomfort.

### Epithelialized palatal flap

Nemcovsky, Artzi and Moses<sup>22</sup> were the first to propose the performance of a rotated epithelialized palatal flap for the closure of the alveolus on the upper arch (Fig 3). The development of this technique is probably originated on flaps for the closure of oroantral fistulas. It is mainly recommended for the molars area and has as main inconvenient the presence of large bloody area in the donor region.

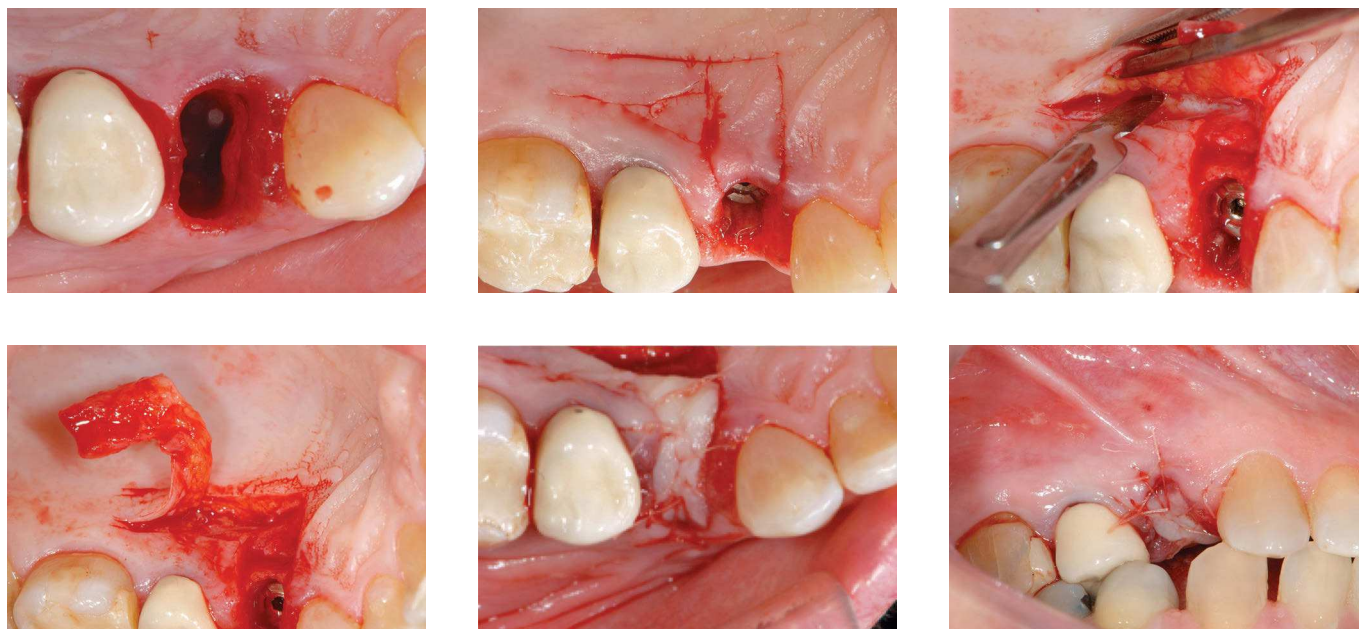


**Figure 3** - Epithelialized palatal flap.

### “L” shaped epithelialized palatal flap

A neater variation of this procedure was proposed by Neves et al,<sup>23</sup> in 2010, denominated “L” shaped pedicle flap, which allows, by the peculiarities of its design, a better accommodation of the tissue without generating stress on the mobilized tissues. The larger portion of the “L” must be transverse to the alveolus, while the smaller portion must be perpendicular to it. The distance of parallel and perpendicular incisions must have the same dimensions of the alveolus to be closed. A triangular area

is marked coronally to the incisions, on the region of the angle formed by the “L”. The base of this triangle is located on the smaller portion and the apex, on the distal of the larger portion — this is the technical detail that provide mobility to the flap. For the full sealing of the alveolus, it is necessary that the base of this triangle has the same vestibule-lingual measure of the alveolus. Then, the flap is positioned and stabilizing sutures are made (Fig 4). This procedure presents high predictability and is particularly interesting for the region of upper premolars.

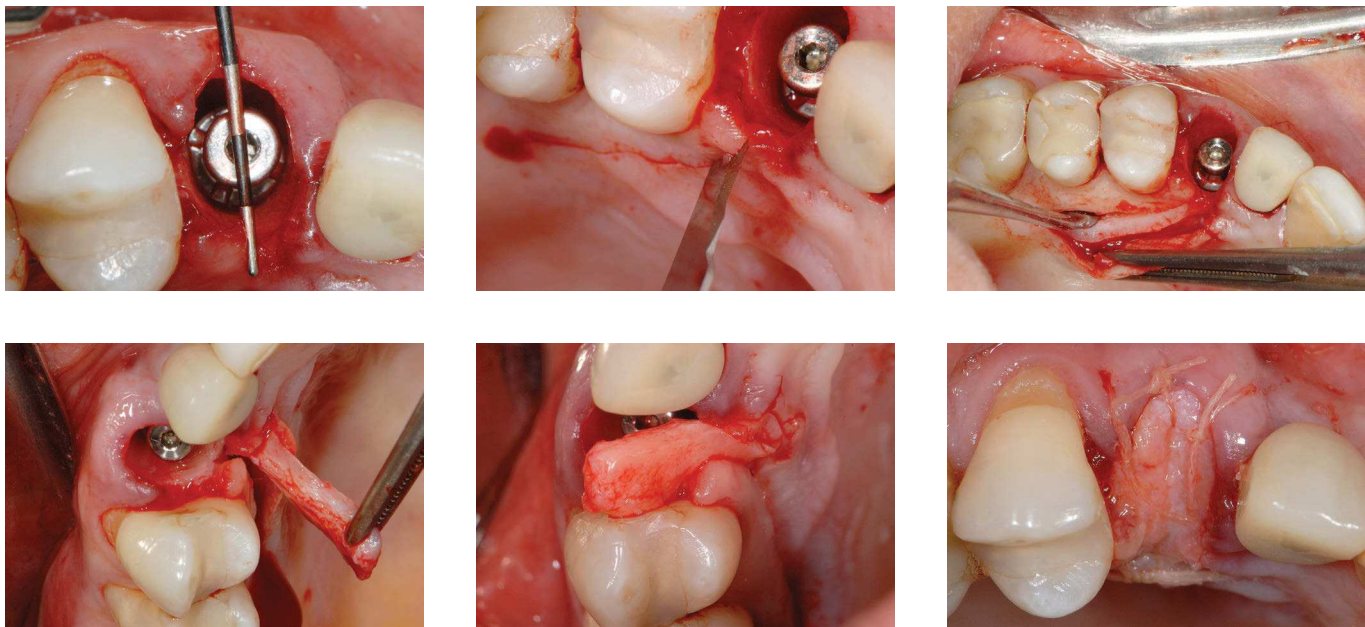


**Figure 4** - “L” shaped epithelialized palatal flap.

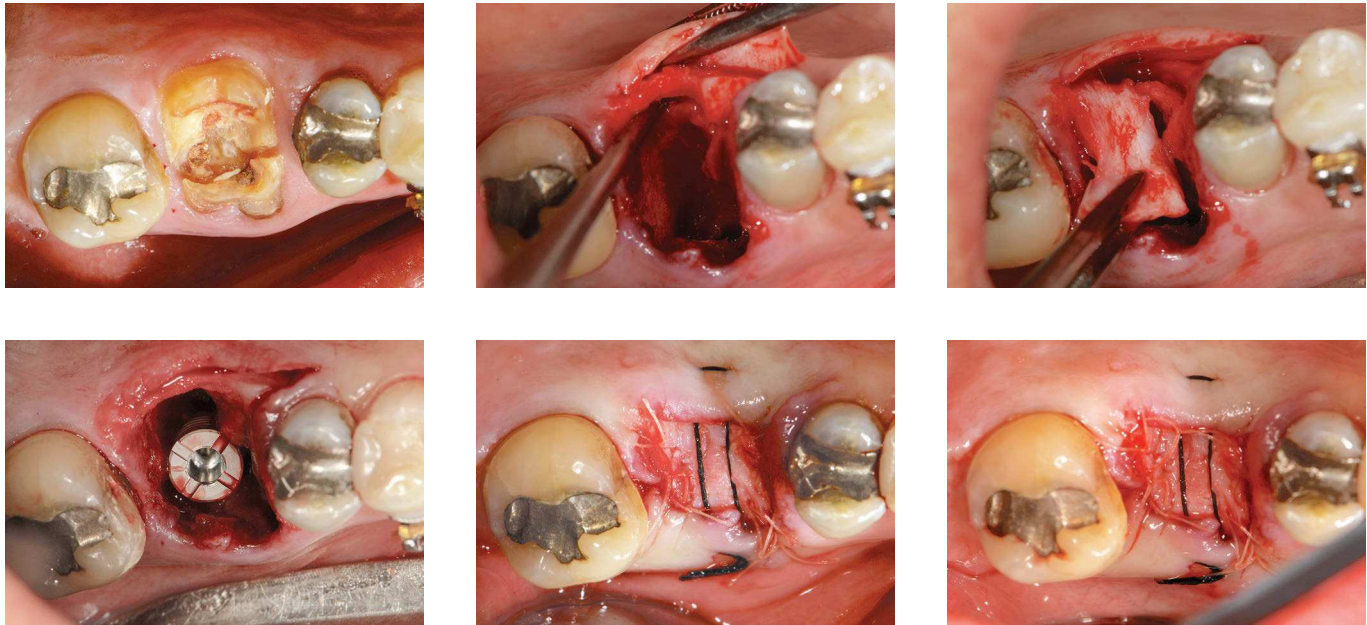
### Split palatal flap

For presenting unfavorable post-operative phase — due to the donor area remaining bloody in epithelized procedures —, Nemcovsky and Artzi<sup>24</sup> proposed a modification in its initial technique.<sup>22</sup> Thus, a full-thickness flap is obtained on the palatal region and split in two parts: an external, containing the epithelium and the superficial portion of the connective tissue; and an internal, containing the deep portion of connective tissue and the periosteum. The internal portion is used to overlay the alveolus, and the external protects the donor area, providing healing by first intention.<sup>9</sup> This technique varia-

tion can be used for anterior areas<sup>25</sup> (Fig 5) or posterior regions<sup>26</sup> (Fig 6), to cover alveoli in which implants were installed or in techniques of alveolar preservation. The split flap technique presents some initial degree of difficulty to be performed, overcome by a curve of the short term learning. In clinical practice, a possible criteria of selection among these techniques is based on the variable thickness of the palatal mucosa. In patients where the palatal tissue is thinner, the epithelialized flap is more recommended; while the split flap is recommended to those patients in which the palatal mucosa has thickness of at least 4 mm.<sup>27,28</sup>



**Figure 5** - Anterior split palatal flap.



**Figure 6** - Posterior split palatal flap.

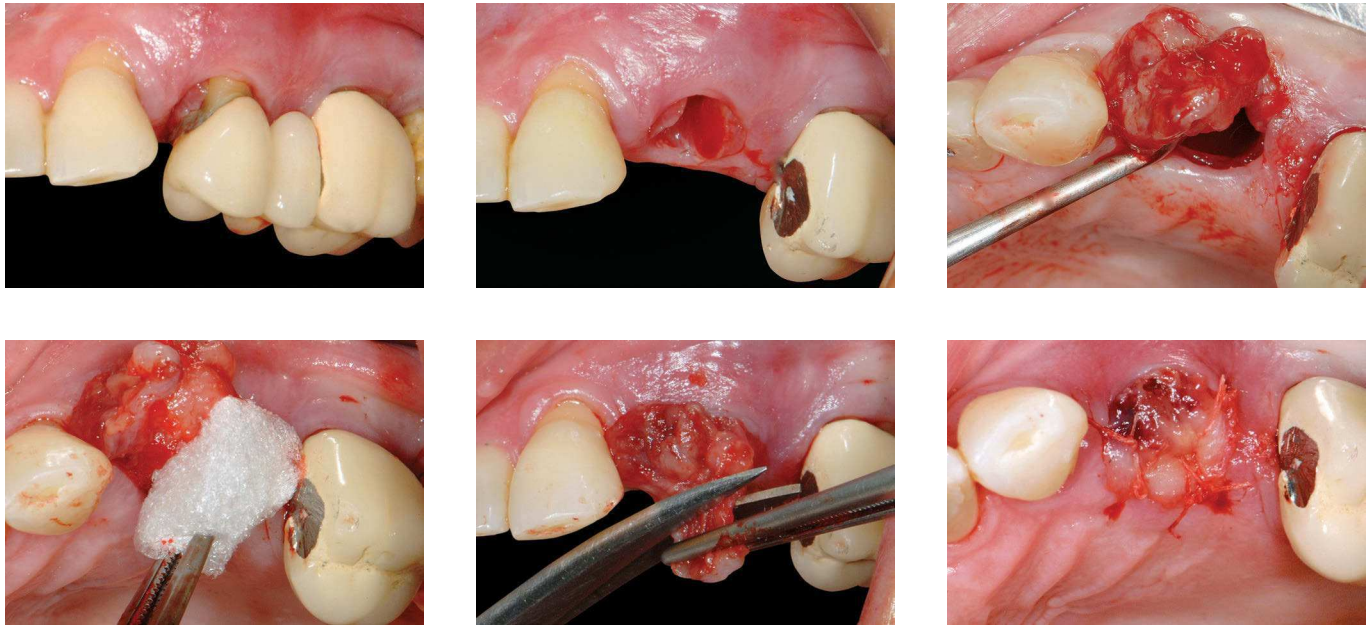
### Granulation tissue rotation

Vascular connective tissue formed on the surface of a wound on healing, of an ulcer or of inflamed tissue. It consists of new capillaries and of an infiltrate containing lymphoid, macrophages and plasma cells. It is possible that after tooth extraction with the elimination of the infectious component, this tissue favors the wound healing, assisting the maintenance or recovery of the gingival contour.<sup>9,29</sup> After the extraction, it must be performed, using a Molt curette, the careful displacement out of the alveolus, of the granulation tissue present on the root apex. This mobilization must not disrupt its connection to gingival tissues. Then it is performed the filling of the alveolar space with collagen matrix. The su-

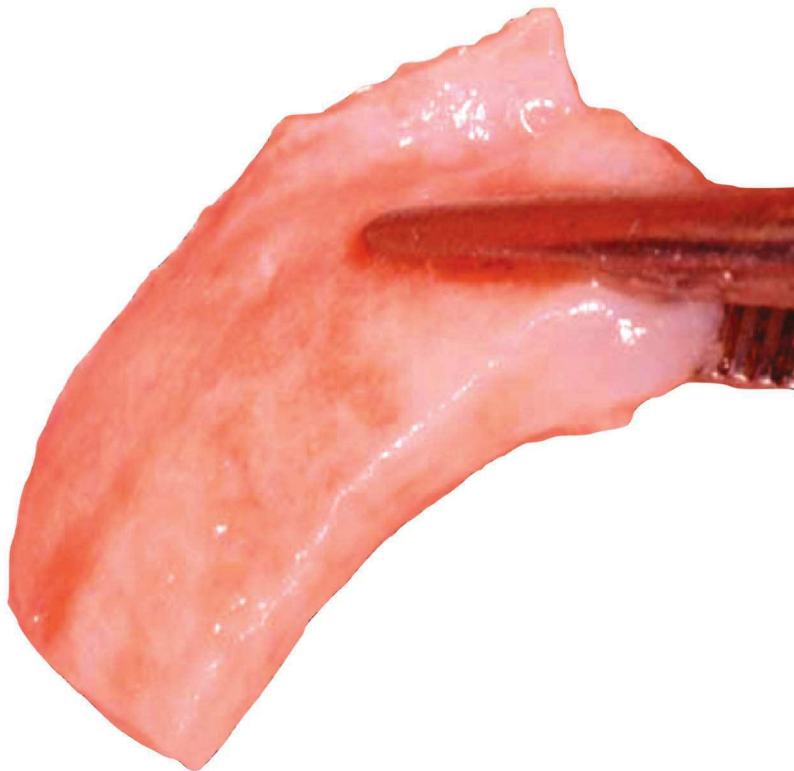
ture must provide the coaptation of this tissue to the edges of surrounding gingival tissue (Fig 7). Although its recommendation is referenced only in clinical reports,<sup>9,29</sup> the obtained results are promising, and it must be considered as a viable and safe option of alveolar sealing, when there is this possibility — given its low morbidity.

### Graft

Segment of tissue placed in contact with an injured area, to repair a flaw, correct a deficiency or to induce the bond between separated tissues (Fig 8).<sup>15</sup> The grafted tissue presents two basic requirements to become viable: to be properly nourished and not move during its incorporation.



**Figure 7** - Granulation tissue rotation.



**Figure 8** - Graft.



### Masticatory mucosal graft

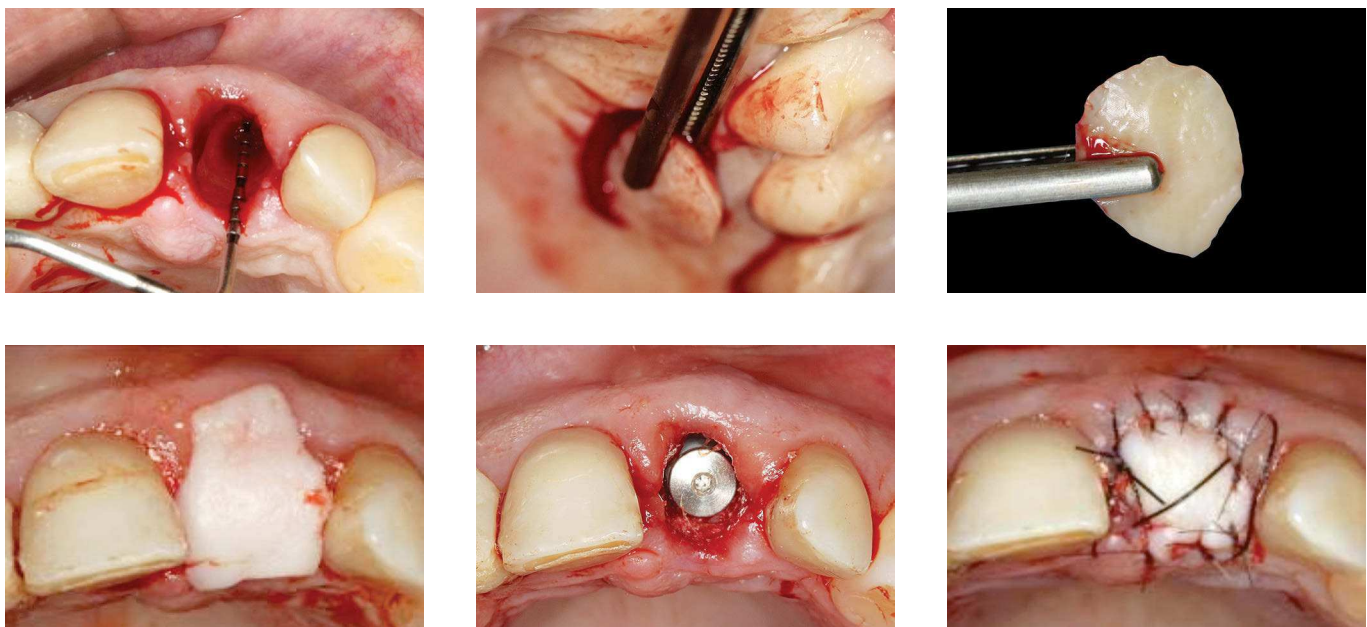
This terminology seems more appropriate than free gingival graft, because it is not the gingival tissue that is grafted, but part of the masticatory mucosa of the palate. It was proposed by Landsberg and Bichacho,<sup>30</sup> in 1994, as part of a technique of alveolus preservation and posterior installation of implant. Some changes were introduced by Landsberg, in 1997<sup>31</sup> and in 2008,<sup>32</sup> as part of the improvement of the original technique.

Thus, the graft dimension is determined by the alveolus perimeter and must be measured preferably on the region of molars and premolars with thickness between 2 and 3 mm, which allows the maintenance of a bone tissue coverage on the donor area. Different ways of stabilization by

means of a suture have been proposed (Fig 9).<sup>9</sup> This technique is preferably recommended in procedures of alveolar preservation with normal bone and gingiva architecture,<sup>9</sup> or when the installation of implants in alveolus did not allow the immediate provisionalization of the case.

### Barrier

Surgical techniques using barriers — such as the expanded polytetrafluoroethylene, polypropylene (Fig 10), polyglactin, polylactic acid, calcium sulfate and collagen — are used in the belief that the exclusion of the epithelium and of the gingival corium, from the root or existing bone surface, might favor the tissue regeneration.<sup>15</sup> Guided bone regeneration generally refers to bone increase or bone regenerative procedures.<sup>15</sup>



**Figure 9** - Masticatory mucosal graft.



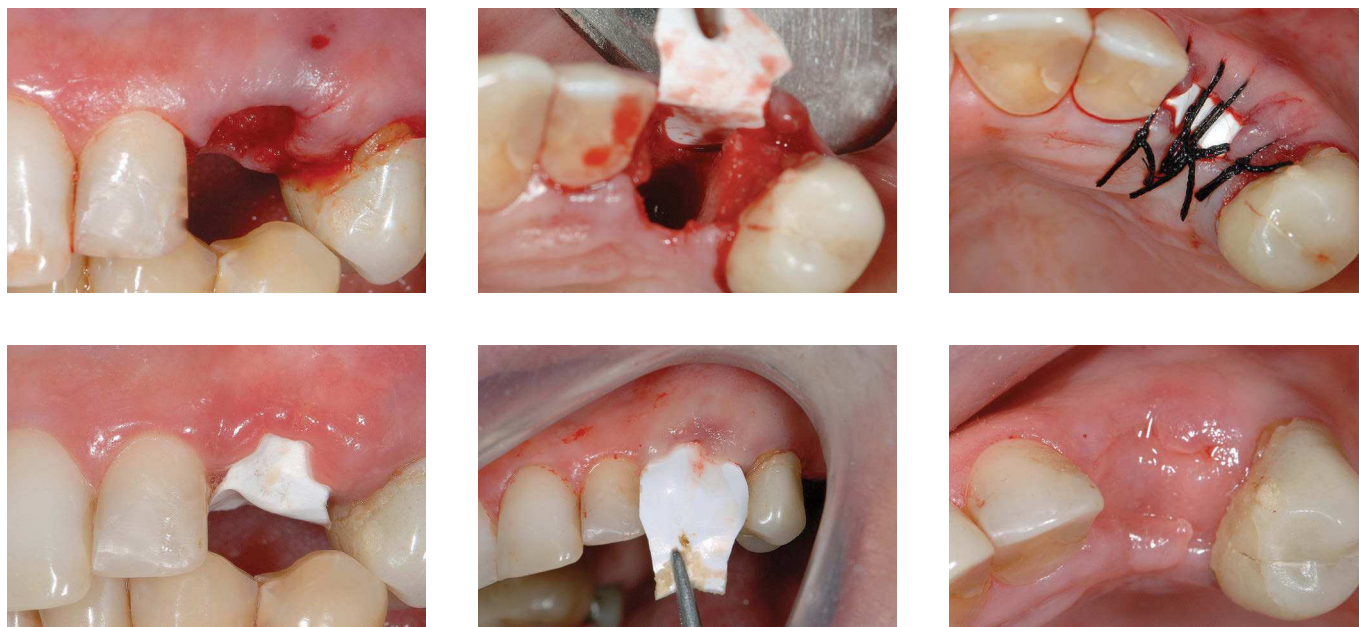**Figure 10** - Regeneration barrier.

### Alloplastic regeneration barrier

Only some of these materials can be exposed to the oral environment without contaminating and impairing the biological events that culminate with the alveolus bone regeneration.<sup>33</sup> Thus, it must be considered to be used only those materials that do not require mobilization of soft tissue.

### Polypropylene

Type of mechanical barrier projected to be intentionally exposed to the oral environment, isolating the area to be regenerated and allowing maintenance of the blood clot in the space comprised of integrate alveolus or bone defect, where pluripotent mesenchymal cells, capable of generating both bone tissue and fibrous tissue, exercise its activities.<sup>34</sup>



**Figure 11** - Polypropylene regeneration barrier.

Its installation requires minimal manipulation of tissues, just enough to allow the adaptation of the properly cropped barrier, enabling the coverage of the alveolus to be regenerated, which at this moment must be completely filled up with blood. Its use concomitantly to the installation of the implant must allow a space of at least 3 mm between barrier and implant. Its removal must be done between 7 and 10 days after the surgical action even without the complete tissue maturation (Fig 11).

### Conclusion

Facing the possibilities for sealing of extraction alveolus, when deciding which technique will be used for each one of the different areas of the mouth — considering the requirements mentioned as from the ideal technique —, the pros and cons must be carefully pondered for the final decision making.

### REFERENCES

1. Quirynen M, Van Assche N, Botticelli D, Berglundh T. How does the timing of implant placement to extraction affect outcome? *Int J Oral Maxillofac Implants.* 2007;22 Suppl:203-23.
2. Hämmerle CAM, Lindhe J. O momento da instalação do implante. In: *Tratado de Periodontia clínica e Implantologia oral.* 5ª ed. Rio de Janeiro: Guanabara Koogan; 2010. p. 1014-27.
3. Wilson TG Jr, Schenk R, Buser D, Cochran D. Implants placed in immediate extraction sites: a report of histologic and histometric analyses of human biopsies. *Int J Oral Maxillofac Implants.* 1998;13(3):333-41.
4. Grunder U, Polizzi G, Goene R, Hatano N, Henry P, Jackson WJ, et al. A 3-year prospective multicenter follow-up report on the immediate and delayed-immediate placement of implants. *Int J Oral Maxillofac Implants.* 1999;14(2):210-6.

5. Rosa MB, Ferreira SD, Leahy FM, Dutra RA. Implante imediato após extração. São Paulo: Artmed; Panamericana; agosto 2012. Biblioteca virtual; ciclo 5, módulo 3.
6. Chen ST, Wilson TG Jr, Hammerle CH. Immediate or early placement of implants following tooth extraction: review of biologic basis, clinical procedures, and outcomes. *Int J Oral Maxillofac Implants*. 2004;19 Suppl:12-25.
7. Hammerle CH, Chen ST, Wilson TG Jr. Consensus statements and recommended clinical procedures regarding the placement of implants in extraction sockets. *Int J Oral Maxillofac Implants*. 2004;19 Suppl:26-8.
8. Suaid FA, Novaes AB, Queiroz AC, Muglia VA, Almeida ALG, Grisi MFM. Buccal bone plate remodeling after immediate implants with or without synthetic bone grafting and flapless surgery: a histomorphometric and fluorescence study in dogs. *Clin Oral Impl Res*. 2012;00:1-12. doi: 10.1111/clr.12036.
9. Joly JC, Carvalho PFM, Silva RC. Reconstrução tecidual estética: procedimentos plásticos e regenerativos periodontais e peri-implantares. São Paulo: Artes Médicas; 2010.
10. Landsberg CJ. Socket seal surgery combined with immediate implant placement: a novel approach for single-tooth replacement. *Int J Periodontics Restorative Dent*. 1997;17(2):140-9.
11. Artzi Z, Nemcovsky C. Bone regeneration in extraction sites. Part 1: the simultaneous approach. *Implant Dent* 1997;6(3):175-81.
12. Gher ME, Quintero G, Assad D, Monaco E, Richardson AE. Bone grafting and guided bone regeneration for immediate implant in humans. *J Periodontol*. 1994;65(9):881-91.
13. Goldstein M, Boyan BD, Schwartz Z. The palatal advanced flap: a pedicle flap for primary coverage of immediately placed implants. *Clin Oral Implant Res*. 2002;13(6):644-50.
14. Pereira Neto ARL, Benfatti CAM, Sella GC, Cordero EB, Souza JGO, Magini RS. Previsibilidade na obtenção de estética e função com retalhos pediculados na Implantodontia. *ImplantNews*. 2010;7(3):353-9.
15. Glossary of Periodontal Terms. 4<sup>th</sup> ed. Chicago: American Academy of Periodontology; 2001.
16. Becker BE, Becker W, Ricci A, Geurs N. A prospective clinical trial of endosseous screw-shaped implants placed at the time of tooth extraction without augmentation. *J Periodontol*. 1998;69(8):920-6.
17. Becker W, Becker BE. Guided tissue regeneration for implant placed into extraction socket and for implant dehiscences: surgical techniques and case reports. *Int J Periodontics Restorative Dent*. 1990;10(5):376-91.
18. Buser D, Dula K, Belser U, Hirt H-P, Berthold H. Localized ridge augmentation using guided bone regeneration. I. Surgical procedure in the maxilla. *Int J Periodontics Restorative Dent*. 1993;13(1):29-45.
19. Langer B, Langer L. The overlapped flap: a surgical modification for implant fixture installation. *Int J Periodontics Restorative Dent*. 1990;10(3):208-15.
20. Buser D, Dula K, Belser U, Hirt H-P, Berthold H. Localized ridge augmentation using guided bone regeneration. I. Surgical procedure in the mandible. *Int J Periodontics Restorative Dent*. 1995;15:3-40.
21. Chung DM, Oh TJ, Shotwell JL, Misch CE, Wang HL. Significance of keratinized mucosa in maintenance of dental implants with different surfaces. *J Periodontol*. 2006;77(8):1410-20.
22. Nemcovsky CE, Artzi Z, Moses O. Rotated split palatal flap for soft tissue primary coverage over extraction sites with immediate implant placement. Description of the surgical procedure and clinical results. *J Periodontol*. 1999;70(8):926-34.
23. Neves AOM, Hochheim RN, Bez LV, Benfatti CAM. Manipulação de tecido mole com o objetivo de vedamento primário de alvéolo cirúrgico em implante. *ImplantNews* 2010;7(5):613-8.
24. Nemcovsky CE, Artzi Z. Split palatal flap: a surgical approach for primary soft tissue healing in ridge augmentation procedures: technique and clinical results. *Int J Periodontics Restorative Dent*. 1999(2);19:175-81.
25. Sclar AG. Vascularized interpositional periosteal-connective tissue (VIP-CT) flap. In: Sclar AG. Soft tissue and esthetic considerations in implant therapy. Chicago: Quintessence; 2003. p. 163-87.
26. Nemcovsky CE, Artzi Z, Moses O. Rotated palatal flap in immediate implant procedures: clinical evaluation of 26 consecutive cases. *Clin Oral Implants Res*. 2000;11(1):83-90.
27. Nemcovsky CE, Moses O, Gelernter MA. Clinical coverage of dehiscence defects in immediate implant procedures: three surgical modalities to achieve primary soft closure. *Int J Oral Maxillofac Implants*. 2000;15(6):843-52.
28. Paolantonio M, Dolci M, Scarano A, d'Archivio D, di Placido G, Tumini V, et al. Immediate implantation in fresh extraction sockets. A controlled clinical and histological study in man. *J Periodontol*. 2001;72(11):1560-71.
29. Ferreira Z, Martins W. Biomanipulação tecidual: procedimentos estéticos reconstrutivos em Periodontia e Implantodontia. 1<sup>ª</sup> ed. São Paulo: VM Cultural; 2011.
30. Landsberg CJ, Bichacho N. A modified surgical/prosthetic approach for optimal single implant supported crown. Part I. The socket seal surgery. *Pract Periodontics Aesthet Dent*. 1994;6(2 Pt 1):11-7; quiz 19.
31. Landsberg CJ. Socket seal surgery combined with immediate implant placement a novel approach for single-tooth replacement. *Int J Periodontics Restorative Dent*. 1997;17(2):140-9.
32. Landsberg CJ. Implementing socket seal surgery as a socket preservation technique for pontic site development: surgical steps revisited: a report of two cases. *J Periodontol*. 2008;79(5):945-54.
33. Salomão M, Siqueira JTT. Uso de barreira de polipropileno pós-exodontia. Relato de três casos clínicos. *Rev Bras Implant*. 2009;15(2):12-5.
34. Salomão M, Siqueira JTT. Regeneração óssea guiada através de barreira exposta ao meio bucal após exodontias. Relato de caso. *Rev Bras Implant*. 2010 jul-set;5-7. Disponível em: <http://boneheal.inpbiomedical.com/wp-content/uploads/2012/05/06-ROG-atrav%C3%AAs-de-barreira-exposta-ao-meio-bucal-ap%C3%B3s-exodontias.-Relato-de-caso-IBI-2010.pdf>