

The importance of keratinized mucosa and implant location on the bleeding on probing around osseointegrated dental implants

Bernardo Born **PASSONI***

Haline Renata **DALAGO***

Guenther **SCHULDT FILHO****

João Gustavo Oliveira de **SOUZA****

Marco Aurélio **BIANCHINI*****

Abstract

Objective: Our objective was to determine the association between the width of keratinized mucosa (KM) and implant location with the bleeding on probing (BOP) status of the soft tissue around osseointegrated implants. **Material and Methods:** A total of 172 patients, presenting 635 functioning dental implants was examined. The width of KM, the implant location and the associations of these analysis were divided into four groups. G1 - anterior area with $KM \geq 2$ mm, G2 - anterior area with $KM < 2$ mm, G3 - posterior area with $KM \geq 2$ mm and G4 - posterior area with $KM < 2$ mm. **Results:** There was no statistical significance in any assessment ($p > 0.05$). **Conclusion:** The width of KM and the location of an implant have no influence on bleeding on probing around dental implants.

Keywords: Dental implants. Dental plaque. Periodontal index. Mucositis.

How to cite this article: Passoni BB, Dalago HR, Schuldt Filho G, Souza JGO, Bianchini MA. The importance of keratinized mucosa and implant location on the bleeding on probing around osseointegrated dental implants. *Dental Press Implantol.* 2013 Jan-Mar;7(1):79-83.

Submitted: June 01, 2012

Revised and accepted: June 03, 2012

* Master student in Implantology, Federal University of Santa Catarina.

** PhD student in Implantology, Federal University of Santa Catarina.

*** Associate professor I, Federal University of Santa Catarina.

Contact address

Bernardo Born Passoni
Rua Esteves Jr., 463 - Apto 701 - Centro
CEP: 88015-130 - Florianópolis/SC, Brazil
E-mail: bpassoni@hotmail.com

Introduction

The presence of an adequate zone of keratinized mucosa was thought to be necessary for the maintenance of gingival health and prevention of periodontal disease progression. First, some authors suggested a width of at least 2 mm of keratinized mucosa, of which 1 mm should be attached gingiva.¹ Subsequently, several studies have challenged this concept and have shown that gingival health can be maintained with almost no attached gingiva.^{2,3}

The necessity of a zone of keratinized tissue adjacent to dental implants has been suggested.⁴ It is especially important because the implant-supported restoration is located beneath the oral mucosa. Furthermore, the implant-mucosa interface differs from the interface between the mucosa and natural teeth, and these differences are important to the understanding of the susceptibility of implants to infection.

When using osseointegrated implants, supracrestal collagen fibers are oriented in a parallel rather than a perpendicular configuration. This creates a much weaker mechanical attachment compared to natural teeth.^{5,6,7} In addition, it was suggested⁸ that the ability of the peri-implant mucosa to regenerate itself is limited by its compromised number of cells and poor vascularity.

The sign of bleeding on probing (BOP) has been implicated as a valuable parameter in the diagnostic process for peri-implant mucositis, while probing depth has been adapted from periodontal diagnosis to assess soft tissue pathology and loss of bony support around osseointegrated oral implants.^{9,10} Bleeding indicates the presence of an inflammatory cell infiltrate.^{11,12}

Furthermore, gingival bleeding is related to the persistent presence of plaque on the teeth and regarded as a sign of the associated inflammatory response. Subjects who refrain from normal oral hygiene procedures have a resul-

tant increase in plaque accumulation and demonstrate a concomitant increase in gingival bleeding as gingivitis develops over a 2-3 week period.¹³ It has also been shown that the development of gingival inflammation and the associated bleeding are increased in smokers.¹⁴

It is evident that probing forces, dimensions of the probes and soft tissue conditions will influence their penetration depth.¹⁵ In natural teeth, it has been established that the sign of BOP is related to the pressure applied on probing.¹⁶ One recent study demonstrated that the maximum pressure to be applied to avoid false positive BOP readings around implants should not exceed 0.15 N. Hence, probing around implants demonstrated a higher sensitivity compared with probing around teeth.¹⁷ It is also reported that at sites with healthy mucosa or mucositis, the tip of the probe may identify the location of the apical level of the epithelium barrier.¹⁸

Few studies have examined the relationship between the width of keratinized mucosa and the health of peri-implant tissues.^{4,19,20} Moreover, the results of these studies are contradictory. Therefore, the purpose of the present investigation was to assess whether the location of the implant and the width of keratinized mucosa influence the bleeding on probing status around osseointegrated implants.

Material and Methods

This study was initially approved by the ethic committee for human research and all participants signed an informed consent (which was previously approved by the committee) before the onset of the study.

The subjects eligible for this retrospective clinical trial were identified from a population of 223 patients, which received dental implants from 08/03/2000 to 08/03/2010. All the smokers and the patients presenting *diabetes mellitus* were excluded from the study. A total number of 635 restored dental implants of 172 patients (with the mean

age of $50,56 \pm 11,65$ (21 to 86 years-old)) was randomly selected. This study comprised 60 males and 112 females patients. The implants were evaluated regarding the width of KM, the location of the implant and the association of these two features, making 4 groups (Table 1).

Clinical measurements were obtained through the use of a periodontal chart. Probing around dental implants was conducted in six sites (mesio-buccal, mid-buccal, distal-buccal, mesial-lingual, mid-lingual, distal-lingual) by means of a Teflon probe (PCV12PT Hu-Friedy Inc., Chicago, IL). Prior to the exam, the implant-retained prosthesis was removed for better visualization in areas with difficult access. After the exam, prophylaxis was conducted and the prosthesis was readapted.

The width of peri-implant keratinized mucosa (KM) was measured in millimeters on the midfacial aspect and classified as ≥ 2 mm or < 2 mm. Differences in colour, texture and mobility between the keratinized mucosa and the lining mucosa served as markers for the detection of the mucogingival junction. The mucogingival junction was identified

by the rolling technique, wherein the probe was rolled until the nonmovable portion of the attached keratinized tissue was seen. KM was then measured with a periodontal probe (PCV12PT Hu-Friedy Inc., Chicago, IL) as the distance between the gingival margin and the mucogingival junction.

Anatomic location of the implant was classified as anterior or posterior. Patient examination and collection of all data were performed using blind method, by an independent and experienced clinician who had been calibrated before the start of patient enrollment. Chi-square test was used for comparison among groups in order to verify which groups present statistical significance ($p < 0.05$). Statistical analysis was conducted by using the software Action 1.1.

Results

Regarding bleeding on probing (BOP), the implants were divided by area (anterior and posterior) to evaluate the influence of the anatomic location of the implant on BOP. It was found that the implants placed in the anterior area presented 31.67% (76 implants) of the sites with BOP; meanwhile, the same evaluation for the posterior area presented 25.82% (102 implants) with BOP ($p = 0.1340$).

Regarding presence of BOP related to the width of KM, the data obtained showed no statistical difference in the group containing the implants surrounded by ≥ 2 mm of KM. Also, this group presented higher percentage of BOP (31.14% - 76 implants) if compared with the group with < 2 mm of KM (26.29% - 107 implants) ($p = 0.2250$).

Evaluating the presence of BOP in association with implant location and width of KM the results were divided into four groups for better analysis. Subsequently, it was found that the implants placed in the anterior area with ≥ 2 mm of KM (Group 1) presented the highest percentage of BOP (32.59% - 44 implants), followed by Group 2 (30.48% - 32 implants), Group 3 (29.03% - 27 implants) and Group 4 (24.83% - 75 implants), respectively (Fig 1) ($p = 0.3505$).

Table 1 - Sample description: Number and proportion of implants related to location, width of keratinized mucosa (KM) and the associations of these features.

Clinical features	Dental implants (n = 635)	(%)
Width of KM		
KM ≥ 2 mm	228	35.91
KM < 2 mm	407	64.09
Implant location		
Anterior area	240	37.80
Posterior area	395	62.20
Groups		
1: Anterior area with KM ≥ 2 mm	135	21.26
2: Anterior area with KM < 2 mm	105	16.53
3: Posterior area with KM ≥ 2 mm	93	14.65
4: Posterior area with KM < 2 mm	302	47.56

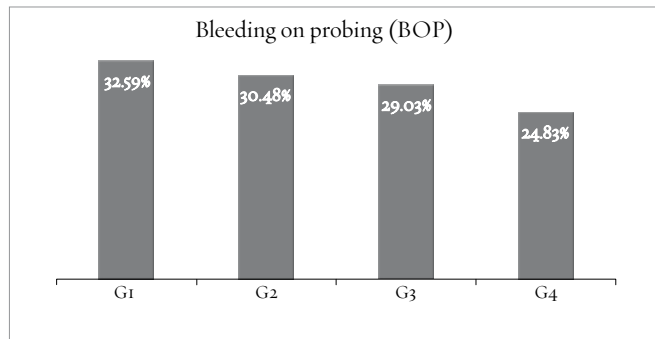


Figure 1 - BOP= bleeding on probing; G1=Anterior area with KM \geq 2 mm (135); G2= Anterior area with KM $<$ 2 mm (105); G3= Posterior area with KM \geq 2 mm (93); G4= Posterior area with KM $<$ 2 mm (302) ($p = 0.3505$).

Discussion

Evidence-based dentistry introduced studies and methodologies to improve the availability of information and new concepts. It allows us to choose a better treatment alternative to our patients. In the natural dentition, the keratinized mucosa includes the free and the attached gingiva and extends from the gingival margin to the mucogingival junction.²¹ The question of whether or not the amount of keratinized gingiva around natural teeth has an impact on periodontal health and whether areas diagnosed as having little or no attached gingiva should consequently be treated accordingly has been a matter of controversy until today.²²

An investigation confirmed that the lack of an adequate zone of attached gingiva did not result in an increased incidence of soft tissue recession in patients maintaining good oral hygiene.²³ In another study²⁴ was emphasized the importance of oral hygiene and demonstrated that minimal to zero attached gingiva could be maintained in a state of health, if adequate plaque control was provided.

In this context the results showed no statistical difference on bleeding sites of the implants located in the anterior area, compared with posterior implants.

There are varying opinions concerning the influence of a zone of keratinized attached mucosa surrounding dental implants. Several authors^{21,25,26} reported that, in good oral hygiene conditions, the marginal gingiva around implants was clinically healthy, even when no keratinized mucosa was present. On the other hand, other investigators^{5,27,28} reported a link between implant survival and width of keratinized gingiva. The results of the present study show that the width of KM and the anatomic location where the implant was installed do not have any influence on BOP levels.

Despite the fact that studies suggest an association between the width of KM and the health maintenance of the peri-implant tissues,^{29,30} the present study support the trend that even a deficient width of KM ($<$ 2 mm) is enough for the maintenance of a healthy soft tissue around dental implants.^{2,3,19,24} However this result should be interpreted with caution, especially in the anterior area, because the lack of an adequate zone of attached gingiva results in an increased incidence of marginal soft tissue recession.²⁷ For this reason we should bear in mind that this retrospective study only suggests explorative evidence; furthermore, it lacks data on the baseline KM width and thickness.

Conclusions

The width of KM or the implant position was not associated with bleeding on probing. Randomized controlled clinical trials are needed to confirm the results obtained in this retrospective clinical study.

REFERENCES

1. Lang NP, Loe H. The relationship between the width of keratinized gingiva and gingival health. *J Periodontol.* 1972;43:623-7.
2. Miyasato M, Crigger M, Egelberg J. Gingival condition in areas of minimal and appreciable width of keratinized gingiva. *J Clin Periodontol.* 1977;4(3):200-9.
3. Kennedy JE, Bird WC, Palcanis KG, Dorfman HS. A longitudinal evaluation of varying widths of attached gingiva. *J Clin Periodontol.* 1985;12(8):667-75.
4. Warrer K, Buser D, Lang NP, Karring T. Plaque induced peri-implantitis in the presence or absence of keratinized mucosa. An experimental study in monkeys. *Clin Oral Implants Res.* 1995;6(3):131-8.
5. Abrahamsson I, Berglundh T, Wennstrom J, Lindhe J. The peri-implant hard and soft tissues at different implant systems. A comparative study in the dog. *Clin Oral Implants Res.* 1996;7(3):212-9.
6. Listgarten MA, Lang NP, Schroeder HE, Schroeder A. Periodontal tissues and their counterparts around endosseous implants. *Clin Oral Implants Res.* 1991;2(3):1-19.
7. Chavrier C, Couble ML, Hartmann DJ. Qualitative study of collagenous and noncollagenous glycoproteins of the human healthy keratinized mucosa surrounding implants. *Clin Oral Implants Res.* 1994;5(3):117-24.
8. Lindhe J, Berglundh T. The interface between the mucosa and the implant. *Periodontol* 2000. 1998;17:47-54.
9. Isidor F. Clinical probing and radiographic assessment in relation to the bone level at oral implants in monkeys. *Clin Oral Implant Res.* 1997;8(4): 255-64.
10. Lang NP, Mombelli A, Tonetti MS, Brägger U, Hämmerle CH. Clinical trials on therapies for peri-implant infections. *Ann Periodontol.* 1997;2(1):343-56.
11. Greenstein G. The role of bleeding upon probing in the diagnosis of periodontal disease. A literature review. *J Periodontol.* 1984;55(12):684-8.
12. Lang NP, Corbet EF. Periodontal diagnosis in daily practice. *Int Dent J.* 1995;45(1):3-15.
13. Löe H, Theilade E, Jensen SB. Experimental gingivitis in man. *J Periodontol.* 1965;36:177-87.
14. Lie MA, Loos BG, Henskens YMC, Timmerman MF, Veerman ECI, Van der Velden U, et al. Salivary cystatin activity and cystatin C in natural and experimental gingivitis in smokers and non-smokers. *J Clin Periodontol.* 2001;28(10):979-84.
15. Abrahamsson I, Soldini C. Probe penetration in periodontal and peri-implant tissues. An experimental study in the beagle dog. *Clin Oral Implants Res.* 2006;17(6):601-5.
16. Lang NP, Nyman S, Senn C, Joss A. Bleeding on probing as it relates to probing pressure and gingival health. *J Clin Periodontol.* 1991;18(4):257-61.
17. Gerber JA, Tan WC, Balmer TE, Salvi GE, Lang NP. Bleeding on probing and pocket probing depth in relation to probing pressure and mucosal health around oral implants. *Clin Oral Implants Res.* 2009;20(1):75-8.
18. Schou S, Holmstrup P, Stolze K. Probing around implants and teeth with healthy or inflamed marginal tissues. A histologic comparison in cynomolgus monkeys (*Macaca fascicularis*). *Clin Oral Implants Res.* 2002;13(2):113-26.
19. Wennstrom JL, Bengazi F, Lekholm U. The influence of the masticatory mucosa on the peri-implant soft tissue condition. *Clin Oral Implants Res.* 1994;5(1):1-8.
20. Chung DM, Oh TJ, Shotwell JL, Misch CE, Wang HL. Significance of keratinized mucosa in maintenance of dental implants with different surfaces. *J Periodontol.* 2006;77(8):1410-20.
21. Ainamo J, Loe H. Anatomical characteristics of gingiva. A clinical and microscopic study of the free and attached gingiva. *J Periodontol.* 1966;37(1):5-13.
22. Hallmon WW, Carranza FA, Drisko CL, Rapley JW, Robinson P. Periodontal literature reviews: a summary of current knowledge. Chicago: The American Academy of Periodontology; 1996.
23. Wennstrom JL. Lack of association between width of attached gingiva and development of soft tissue recession. A 5-year longitudinal study. *J Clin Periodontol.* 1987;14(3):181-4.
24. Kennedy JE, Bird WC, Palcanis KG, Dorfman HS. A longitudinal evaluation of varying widths of attached gingiva. *J Clin Periodontol.* 1985;12(8):667-75.
25. Cox JF, Zarb GA. The longitudinal clinical efficacy of osseointegrated dental implants: a 3-year report. *Int J Oral Maxillofac Implants.* 1987;2(2):91-100.
26. Schou S, Holmstrup P, Hjørtting-Hansen E, Lang K. Plaque induced marginal tissue reactions of osseointegrated oral implants: a review of the literature. *Clin Oral Implants Res.* 1992;3(4):149-57.
27. Zigdon H, Machtei EE. The dimensions of keratinized mucosa around implants affect clinical and immunological parameters. *Clin Oral Implants Res.* 2008;19(4):387-92.
28. Bouri A, Bissada N, Mohammad S, Faddoul F, Nouneh I. Width of keratinized gingiva and the health status of the supporting tissues around dental implants. *Int J Oral Maxillofac Implants.* 2008;23(2):323-6.
29. Adibrad M, Shahabuei M, Sahabi M. Significance of the width of keratinized mucosa on the health status of the supporting tissue around implants supporting overdentures. *J Oral Implantol.* 2009;35(5):232-7.
30. Schrott AR, Jimenez M, Hwang JW, Fiorellini J, Weber HP. Five-year evaluation of the influence of keratinized mucosa on peri-implant soft-tissue health and stability around implants supporting full-arch mandibular fixed prostheses. *Clin Oral Implants Res.* 2009;20(10):1170-7.