

The Vermeulen implant-abutment suture or modified running suture*

Déborah HIMY
PhD in Dental Surgery .

Jacques VERMEULEN
PhD in Dental Surgery .

INTRODUCTION

Sutures play an important role in implant practice as they help determining the quality of healing at the surgical site.¹ Indeed, not only they are the only barrier against contamination in the oral cavity, but they also ensure a healthy gingival, esthetic and functional environment to be reestablished.

As a result, they allow complete gingival edge closure and perfect control of minimal tissue tension within limited time regardless of accessibility of the site.²

With a view to fulfilling our patients' interest, we should exhaustively respond

to such specifications. However, sutures are made at the end of the procedure when patient's blood pressure is low and both the clinician and the patient are already exhausted.

In view of these difficulties and as a result of daily surgical practice — especially in cases of complete rehabilitation of the maxilla and the mandible — review and reflection, a new technique of suture around contiguous implant has been developed. This technique strictly meets previously established requirements and results in precious gain of time.

Submitted: May 23, 2014 - **Revised and accepted:** June 02, 2014

Contact address: Jacques Vermeulen
E-mail: dr.vermeulen@wanadoo.fr

*Article originally published as: Himy D, Vermeulen J. Le point de suture pilier-implantaire Vermeulen ou surjet passé modifié. *Implantologie Revue*. 2014 fev.

* Drawings by: Jean-François GRIVET.

I) DIFFERENT STITCHES IN DIFFERENT TYPES OF SUTURE

» Criteria for suture success

» Preparation of gingival flap

Preparation of gingival flap is of paramount importance for effective suture. To this end, incision must be linear, precise and strategic.

Thus, a good surgeon thinks about closing the site even before performing the flap procedure. For a precise approach, it is preferable to use a new scalpel blade.⁵

Suture should not cause tension to the flap. The key to success relies on obtaining a passive flap. Indeed, the shorter the distance between the incision edges, the better the quality and the faster the healing.

With a view to bringing incision edges near, the flap must undergo minimal tension. To this end, eliminating frenum and cicatricial adhesions is indispensable to ensure absence of inflammatory tissue and, in some clinical situations, make an incision with partial thickness.

Furthermore, the following aspects must be taken into consideration:

- » Spaced sutures to avoid tissue ischemia;
- » Protection of blood clot;
- » Reduced colony of bacteria;
- » Quick procedure;
- » Simple procedure despite limited visibility;
- » Recovery within 8 to 10 days;
- » Type of suture.

The suture wire must not be too thin so as not to section the tissues. Suture material must meet the following criteria:

- » Minimal tissue reaction;
- » Ductility;
- » No capillarity;
- » Maximal tensile strength;
- » Easy handling;
- » Knot security;
- » Results stability and predictability;
- » Controlled expenses.

The aforementioned criteria¹ are necessary and enough to achieve first intention healing within two weeks. Suture removal should be atraumatic if performed before deadline.

» Different types of stitches:^{3,4}

The different types of stitches listed below are named according to the most widely and best known nomenclature; however, no consensus has been reached regarding this matter.

Surgeon's knot

Regardless of the type of stitch, the clinician must twist the long end of the wire around the needle holder twice so as to achieve suture success. The shortest end of the wire is pulled and tensioned through the longest end loop so as to tie the first knot that must be placed in horizontal position. Subsequently, the clinician repeats the same procedure in opposite direction so as to tie the knot. A third loop is then made in the same direction of the first knot. This technique is described by some authors as "surgeon's knot" (Fig 1).




Figure 1. Surgeon's knot.

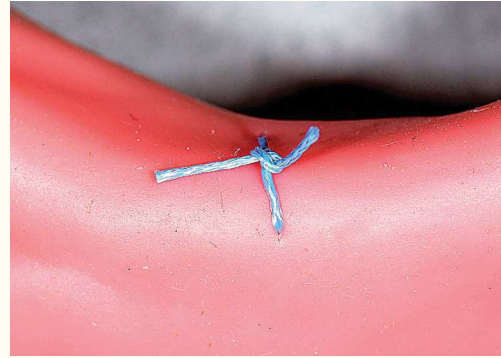


Figure 2. Simple or "O" stitch.

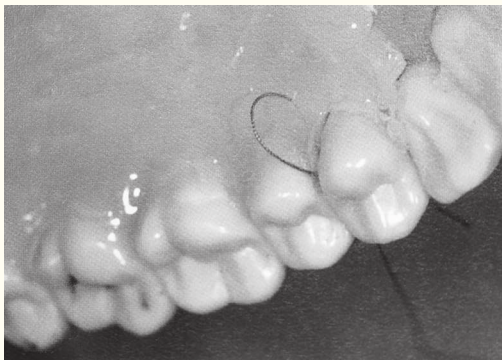

Figure 3. Figure-of-eight stitch.

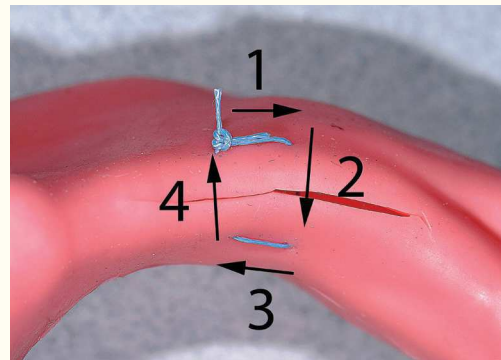


Figure 4. Horizontal U stitch.

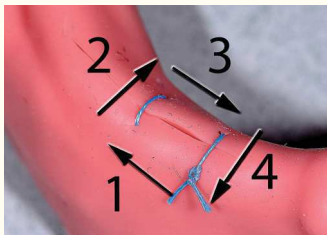


Figure 5. Simple horizontal mattress stitch.




Figure 6. Locking horizontal mattress stitch.

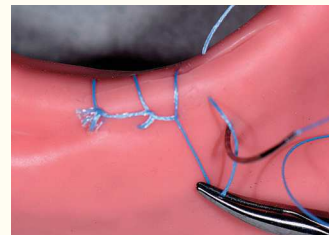


Figure 7. Running locking suture stitch.

Simple or “O” stitch

In the papillae level, the needle pierces the first edge and then the second by tracing an “O” and involving the vestibular papillae, the interdental zone and the palatal/lingual papillae. It returns through the interdental spaces and ends with a knot tied in the vestibular papillae. (Fig 2)

Figure-of-eight stitch

The needle pierces the vestibular papillae from outside in, followed by the lingual/palatal papillae from outside in. The knot is tied in the vestibular papillae. (Fig 3)

Horizontal U stitch

The needle pierces both edges. The wire follows the course of incision (a few millimeters) and once again pierces both edges, however, in opposite direction towards the smallest loop tying the knot. (Fig 4)

Simple horizontal mattress stitch

The needle goes under the mucosa and parallel to the incision nearly following the length of the curved needle.

Subsequently, it goes over the incision and under the mucosa on the other side, but in opposite direction. The knot is tied in vestibulo-mesial direction. (Fig 5)

Locking horizontal mattress stitch

The needle goes under the mucosa parallel to the incision. It goes over the incision and under the mucosa on the other side and in the same direction. The knot is tied in vestibulo-mesial direction. (Fig 6)

Vertical mattress stitch

The needle vertically pierces the gingiva on the vestibular surface. The wire goes through interdental spaces. The needle vertically pierces the palatal mucosa and the knot is tied in the vestibular flap level.

Simple interrupted stitch

The needle pierces the vestibular papillae from the outside, goes through the interdental space, contours the lingual/palatal surface and goes through the adjacent opening, going out the vestibular surface. Subsequently, it pierces the outer surface of the vestibular flap, contours the lingual/palatal surface in the opposite direction and goes through the initial interdental space where the knot is tied.

Simple running suture

Initially, a simple stitch is made. The wire is placed perpendicular to the incision; the needle pierces the opposite edge from the outside in. It goes out the other edge and, after following its course under the mucosa, pierces it from the inside out.

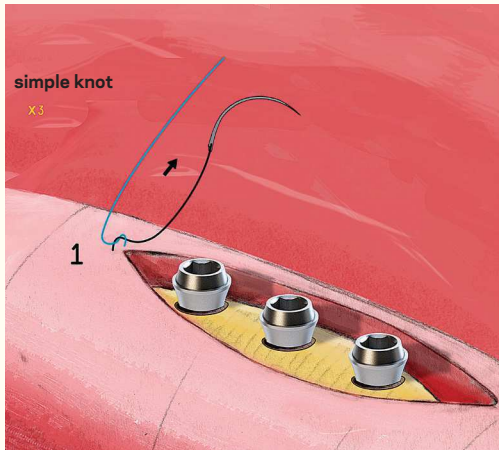
Subsequently, the wire traces a diagonal line above the incision, crossing the mucosa and continuing until the end of the incision.

A final loop is then made so as to allow a simple knot.

Running locking suture

Initially, a simple stitch is made. The suture sequence is identical to a simple running suture, but with the wire going through each loop before the needle pierces the flap on the side opposite to the first knot (Fig 7).

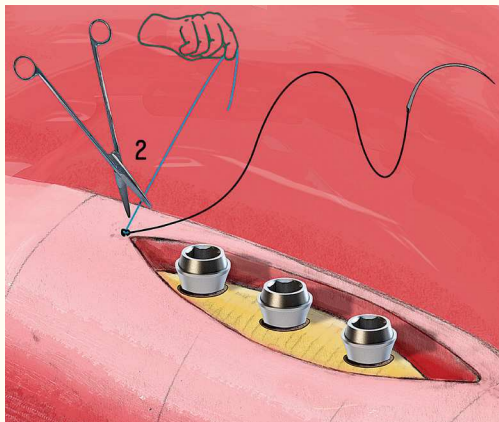
II) JACQUES VERMEULEN IMPLANT-ABUTMENT SUTURE or modified running suture.



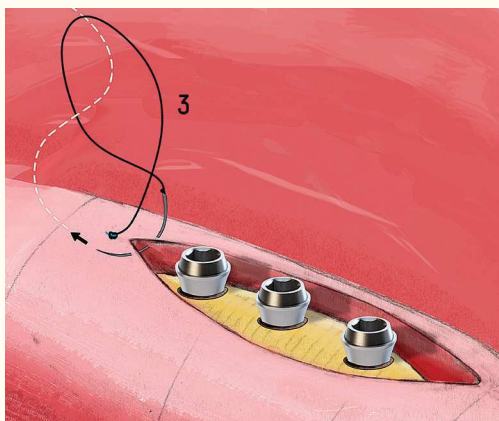
Step 1. In cases of maxillary or mandibular complete denture with immediate loading, good suture closure is of utmost importance. Indeed, we may opt for the following:

- » Immediate loading with previous bridge. The clinician must prevent the resin or the bonding element from flowing out to the edges. Despite using isolation with rubber dam, there is always a risk.
- » Post-surgical impression.

The clinician must prevent the opening between the edges from being contaminated by the impression material. Thus, in this case, we recommend a modified running suture that is self-attached around cone-shaped or multiple abutments. The suture must begin distally and end mesially. In cases of complete denture, the direction of the suture is chosen by the specialist. A coated braided polyester Ti-Cron 3/0 or 4/0 75-cm wire is recommended in association with a 3/8", 1.9-mm and 60-cm needle. Initially, a simple or "O" stitch must be distally tied 2 mm out from the limits of the incision.

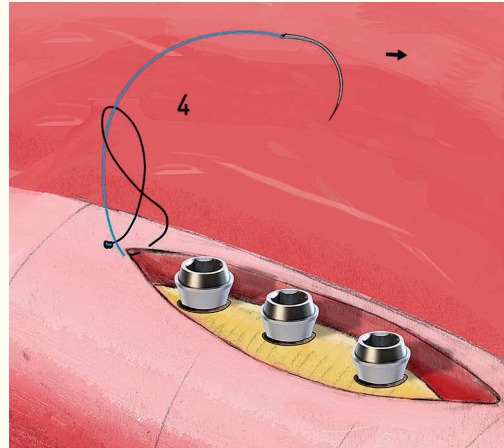


Step 2. The specialist tensions the free wire while his assistant cuts it. The depicted abutments are cone-shaped Anthogyr (ref. OPSCO20) used for Axiom Reg or Px. implants.

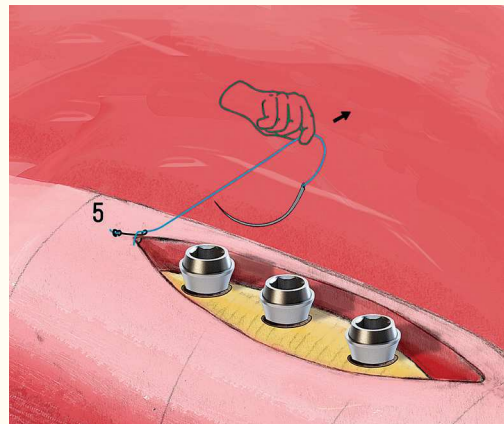


Step 3. The clinician must determine a direction to be respected during the suture procedure, except for when it goes above the abutments in which case the direction is changed. As in classic running suture, the needle goes through the loop formed between the fixed suture and the stitch where the needle was first pierced.

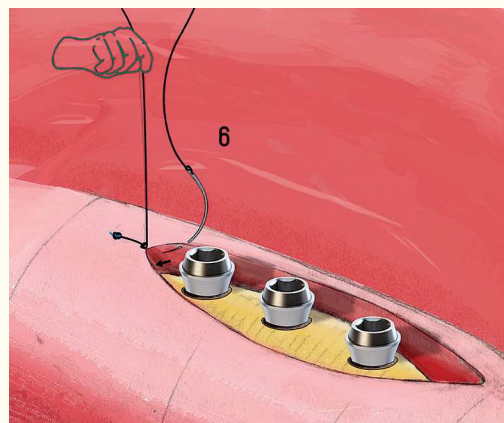
Step 4. With the aid of a needle, the clinician tightens the first stitch by pulling it up.




Step 5. The clinician's assistant tensions the wire, loosening it up a bit so as to allow the specialist to retrieve the needle.

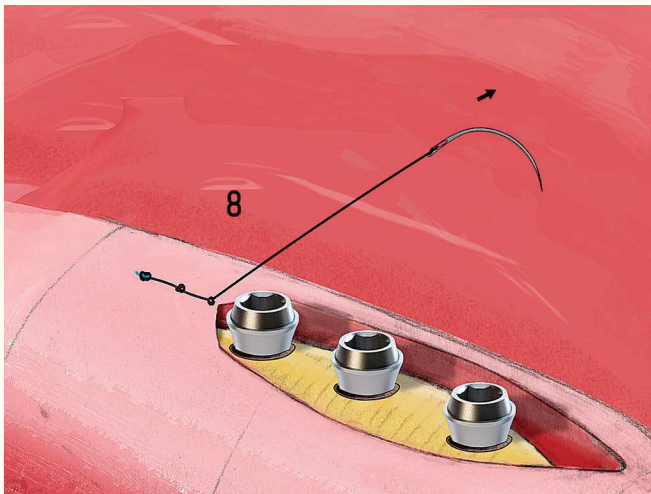


Step 6. Tension remains while the specialist pierces and crosses the edge (always respecting the direction chosen in the first place).

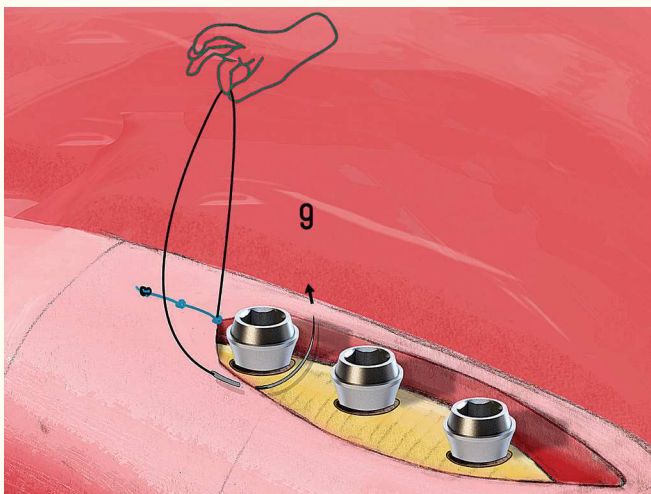




Step 7. Pull to tighten the first knot.

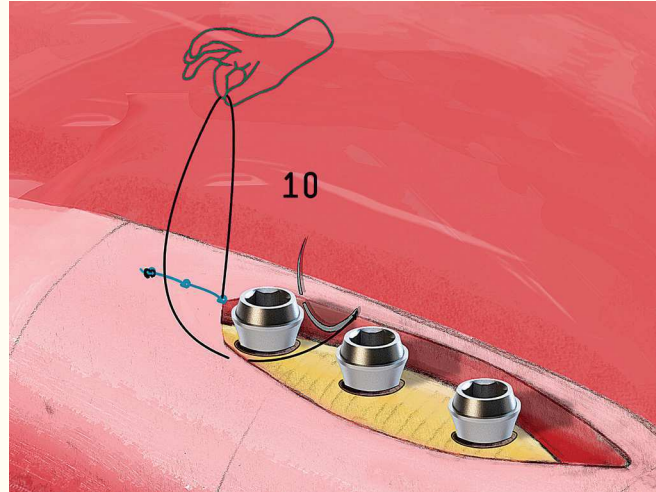


Step 8. Exerting tension over the wire compresses and closes the opening. Note that this stitch is at a distance not greater than 1 mm behind the abutment; however, it is best tied against the distal abutment wall.

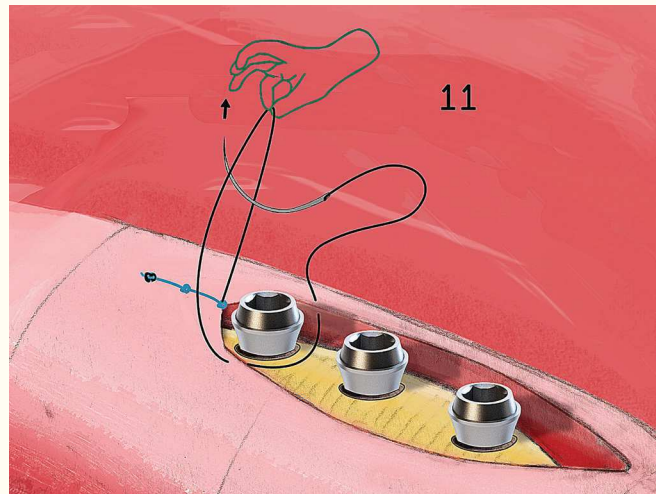


Step 9. The clinician's assistant tensions the edge while the specialist pierces the other edges nearer the mesial abutment wall in opposite direction.

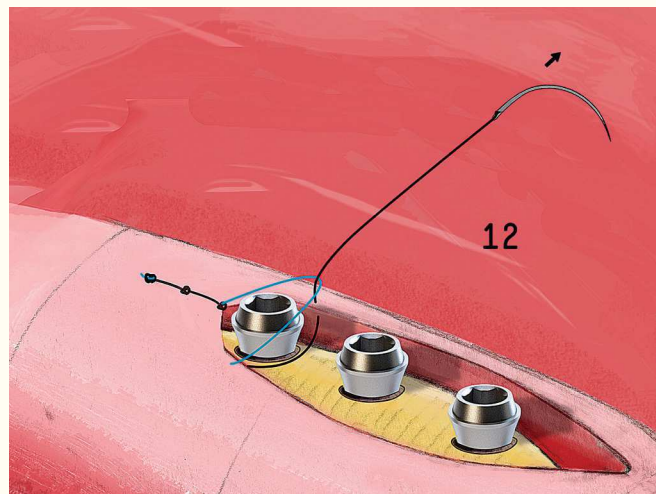
Step 10. It would be wiser to pierce the needle distally in relation to the mesial wall, especially when a concave abutment is used. As a result, the wire is naturally blocked in the lower section of the abutment.

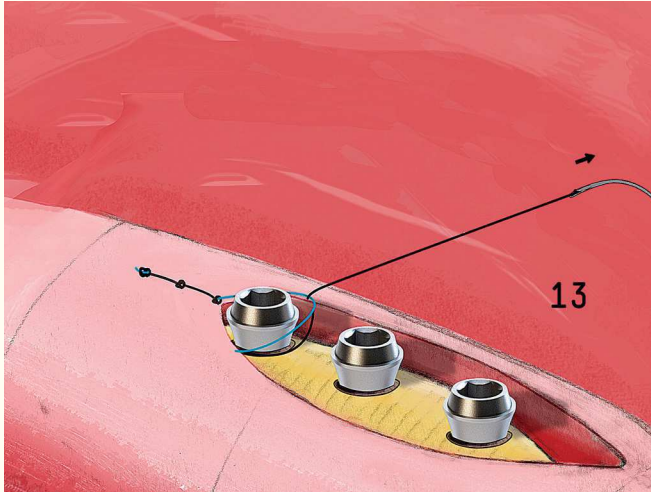


Step 11. The Vermeulen or modified running suture begins.

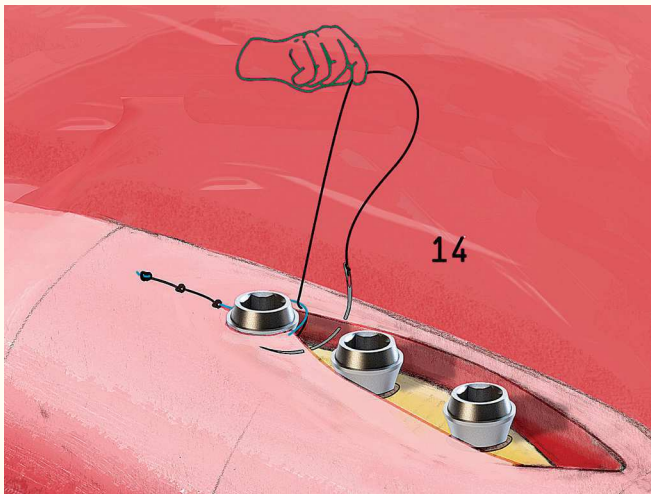


Step 12. To tighten the loop, the clinician must tension the wire passing the blue loop above the abutment. The loop naturally slides over the lower section of the abutment, thereby bringing tissues around the abutment together.






Step 13. Exerting tension over the wire not only tightens the loop, but also stabilizes it in the lower section of the abutment.

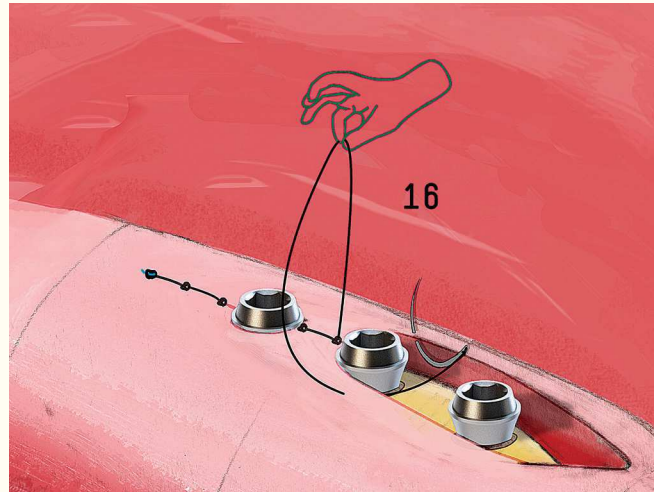


Step 14. The clinician's assistant tensions the wire while the specialist passes the needle in the initial direction, tying a new running suture.




Step 15. The stitch is tightened.

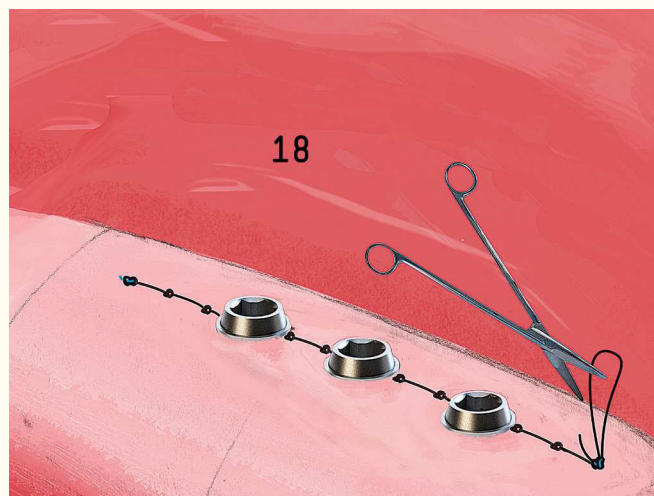
Step 16. Classic running suture is made once again as close as possible to the abutment. A Vermeulen or modified running suture is then carried out.




Step 17. The same procedure is repeated until the incision is complete.



Step 18. A stitch is made over the loop and outside the incision area so as to close the modified running suture.





Step 19. Vermeulen or modified running suture final outcome.

REFERENCES:

1. Gaudy JF, et al. Incisions et sutures. Paris: Editions CdP; 2007.
2. Davarpanah M, Szmukler- Moncler S. Manuel d'implantologie clinique. Paris: Editions CdP; 1999.
3. Teysseres N, Fossat S. Incisions et sutures en chirurgie maxillo-faciale et stomatologie. 2008. Available from: <http://www.em-consulte.com/es/article/199080>.
4. Parant M. Petite chirurgie de la bouche. Paris: Expansion scientifique Francaise; 1991.
5. Perrin D, Ahossi V, Larras P, Lafon A, Gerard E, Manuel de chirurgie orale: technique de réalisation pratique, maîtrise et exercice raisonné au quotidien, collection JPIO, 2012.