

# Rehabilitation of atrophic maxilla without a reconstructive approach. A case report

**Abstract / Introduction:** Oral rehabilitation of edentulous patients using fixed prostheses commonly involves previous reconstructive procedures, since the residual ridge does not have the minimum dimensions required for installation of standard diameter implants in the planned site. Factors such as high cost and fear of additional surgical procedures make some elderly, even those who are dissatisfied with the instability of removable prosthesis, hesitant to treatment with dental implants.

**Objective:** This study aims to report a case of oral rehabilitation with fixed dentures supported by implants of reduced diameter (3.3 mm) in severely atrophic maxilla without the use of grafts or reconstructive approaches. The eight implants, installed with palatal approach at previously planned sites, remained submerged for 45 days when soft tissue adjustment and prosthetic procedures were started. The definitive prosthesis was installed 65 days after surgery. **Results:** No intercurrent was registered after 6 months of follow-up. Small diameter implants appear as a simple and fast alternative for horizontal bone augmentation procedures. Additionally, they can be safely used for retention of fixed prosthesis, and prove to be an efficient and low-cost solution for edentulous patients who wish to minimize problems related to the instability of removable dentures.

**Keywords:** Dental prosthesis. Dental implants. Maxilla. Atrophy.

Tércio Pessoa TABOSA E SILVA

Masters student in Implantodontics.

Caio César Leite MIRANDA

Masters student in Implantodontics.

Rodinei Luiz da Silva BUCCO JR

Masters student in Implantodontics.

doi: <http://dx.doi.org/10.14436/2237-650X.8.2.070-077.oar>

**How to cite this article:** Tabosa e Silva TP, Miranda CCL, Bucco Jr RLS. Rehabilitation of atrophic maxilla without a reconstructive approach. A case report. Dental Press Implantol. 2014 Apr-June;8(2):70-7.

**Submitted:** March 08, 2014 - **Revised and accepted:** April 23, 2014

**Contact address:** Tércio Pessoa Tabosa e Silva  
Rua Marcos Macedo, 1333 - Pátio Dom Luís - Torre 2 - Sala 1711 - Fortaleza/CE - Brazil  
E-mail: [terciopessoa@yahoo.com.br](mailto:terciopessoa@yahoo.com.br)

» The authors report no commercial, proprietary or financial interest in the products or companies described in this article.

» Patients displayed in this article previously approved the use of their facial and intraoral photographs.

## INTRODUCTION

The use of dental implants as a way of retention for fixed prosthesis is a predictable treatment option for rehabilitation of partially or fully edentulous patients. This clinical procedure has become common in the last decades and, associated to a prosthodontically driven treatment plan, is responsible for guaranteeing reliable esthetic and functional long-term results.<sup>1,2</sup>

Nonetheless, due to prolonged use of removable dentures, physiological resorption, periodontal disease, traumatic extractions or cysts and infections, the patient oftentimes does not have the minimum amount of bone width required for installation of standard diameter implants in the site preconized by the diagnostic wax-up and surgical template.<sup>3</sup>

Reconstructive approaches performed before surgery have been developed.<sup>4,5,6</sup> Nevertheless, these procedures frequently involve harvesting of autogenous bone, which is associated to possible risks, increased patient morbidity because of the second surgical site, additional costs and progressive bone resorption of the grafted bone.<sup>7-11</sup>

The use of reduced diameter implants (RDIs) can extend treatment options and reduce the need for invasive procedures of bone augmentation. Thus, there is an increased acceptance by the patient and a reduction in treatment cost and time.<sup>12</sup>

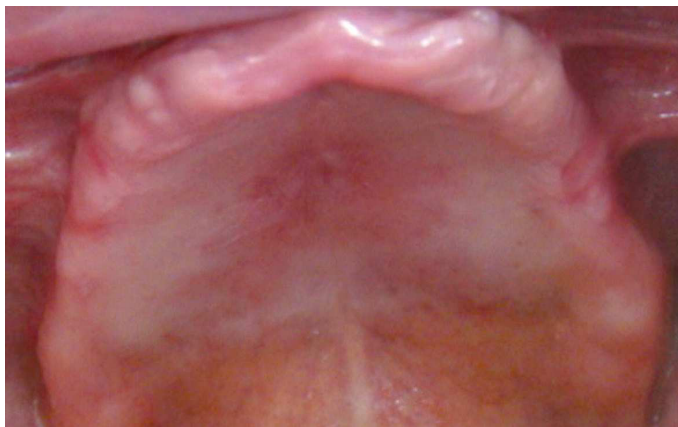The applicability of this treatment modality has been investigated not only to replace anterior teeth,<sup>13,14</sup> but also in the posterior region of the jaws and rehabilitation of fully edentulous patients.<sup>15-20</sup>

The present study aims to report a case of oral rehabilitation using a total prosthesis supported by RDIs of 3.3 mm diameter in a severely atrophic maxilla, without the use of grafts or reconstructive approaches.

## CASE REPORT

A 76 year-old white, edentulous man sought restorative treatment in a private dental clinic. He was complaining of instability of his superior complete denture (Fig 1).

The patient was already using a prosthesis supported by four implants in the mandible, and reported having undergone surgery before installation of five implants in the maxilla to support an upper



**Figure 1.** Edentulous maxilla.

complete denture. However, success was not achieved, since osseointegration of the five implants failed.

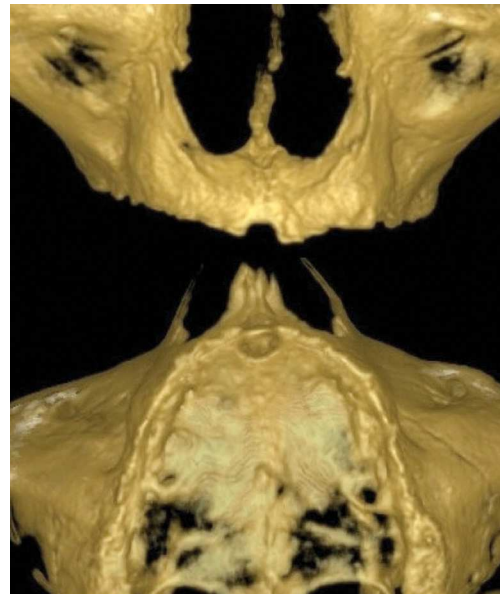Thorough review of patient's medical history and clinical examination did not reveal factors that would affect bone healing. The volume and quality of patient's alveolar bone was assessed by means of cone-beam computerized tomography (CBCT). The CBCT scan revealed severe maxillary horizontal atrophy (Figs 2 and 3).

Maxillary atrophy was significant enough so as to exclude the possibility of using implants of 4 mm or greater. Due to the increasing number of scientific evidences and predictability of the use of RDIs, the surgeon found feasible to install 8 RDIs (3.3 mm in diameter), with moderately rough and chemically modified surface so as to support a complete screw-retained denture. (5 implants 3.3 x 8.0 mm and 3 implants 3.3 x 10 mm SLActive, Straumann® AG, Basel, Switzerland) (Fig 4).

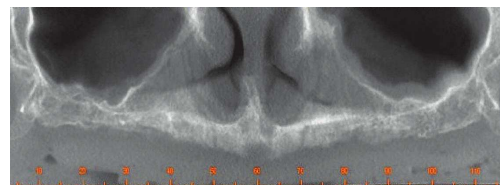
Surgery was performed under intravenous sedation and monitored by a physician. After local anesthesia, a linear incision was made in the maxillary alveolar crest, and distal releasing incisions were carried apically into the unattached gingiva to facilitate full thickness flap reflection. The palatal flap was stabilized with two simple sutures (nylon 4-0) (Fig 5). Posteriorly, the surgical template was positioned in the mouth to guide drilling with palatal approach for implant placement. The eight sites were prepared following the sequence of drills established by the manufacturer (Fig 6). The eight implants were installed with cover screws in the prosthetically planned sites and the flap was repositioned and stabilized with simple sutures, allowing a submerged healing. A removable

denture was provisionally used during the osseointegration period.

Amoxicillin (500 mg), four capsules, and one pill of dexamethasone (4 mg), were prescribed to be administered orally 1 hour before surgery. Scientific evidence suggests that 2 g of amoxicillin given orally, as a single administration one hour before surgery significantly reduces failure of dental implants.<sup>21</sup> After surgery, the following medications were



**Figure 2.** Three-dimensional models created from CBCT scan data. Anterior and inferior view.



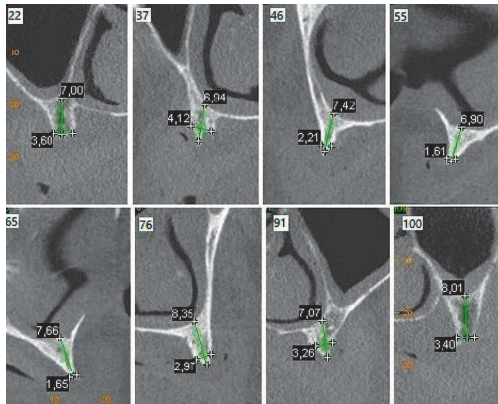
**Figure 3.** Panoramic radiograph.

prescribed: dexamethasone (4 mg), one pill every 12 hours for two days, dipyron (500 mg), every 6 hours for three days and mouth-wash with 0.12% chlorhexidine digluconate, twice a day for 10 days.

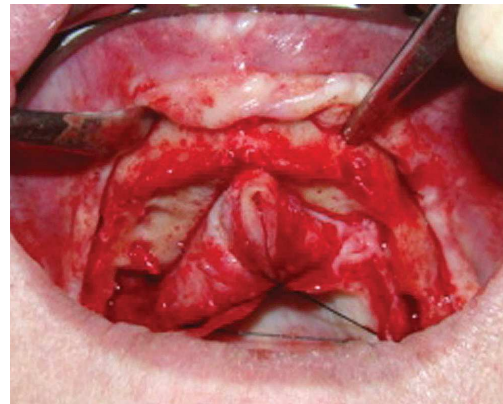
The implants were allowed to heal for 45 days, then, healing abutments were installed to start the prosthetic procedures (Fig 7). For this case, screwed pillars (Synocta 1.5 mm, Straumann® AG, Basel,

Switzerland) with calcinable cylinders for bridges were selected. After 20 days dedicated to resolution of prosthetic and laboratorial steps, the definitive implant-supported denture was installed and occlusal adjustments were performed (Figs 8–11).

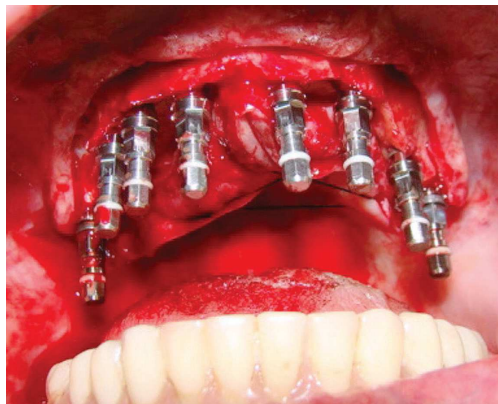Intercurrences such as suppuration, mobility, radiolucency around implants or prosthetic complications were not registered after 6 months of follow-up.



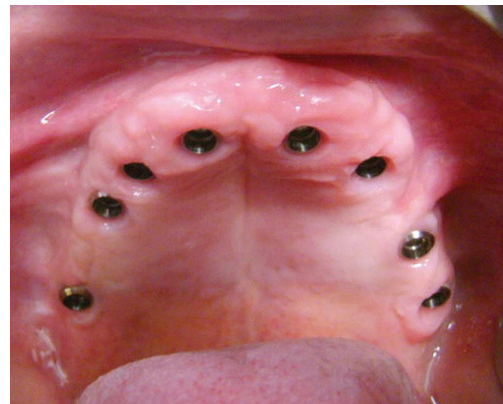
**Figure 4.** Cross-sectional views of previously selected sites for implant placement. Cross-sections 22, 37, 46 and 55, referring to the right side of the maxilla and sections 65, 76, 91 and 100, referring to the left side of the maxilla.



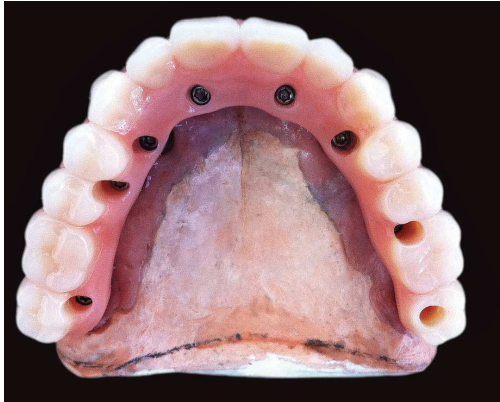
**Figure 5.** Full thickness flap reflected from palate and stabilized with two simple sutures.



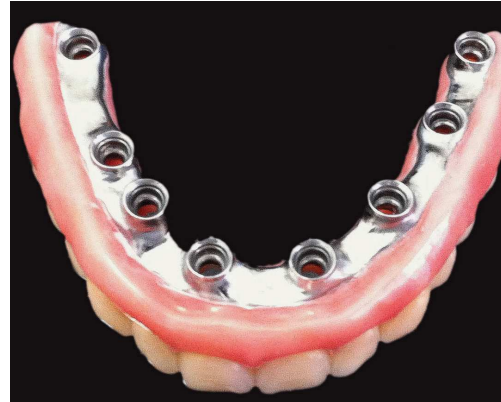**Figure 6.** Implants installed in the previously planned sites.



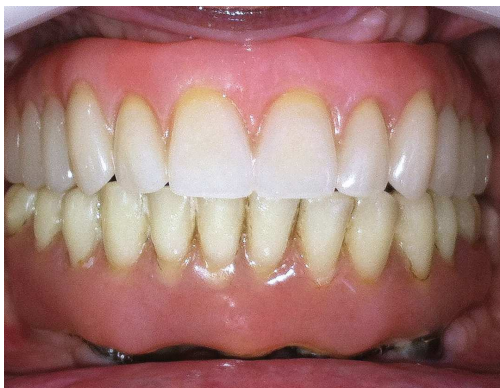**Figure 7.** Gingival contours conditioned by the use of healing abutments.



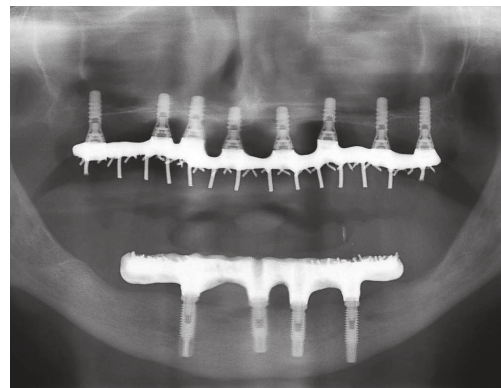
**Figure 8.** Definitive maxillary implant-supported denture. Lower view.



**Figure 9.** Definitive maxillary implant-supported denture. Upper view.



**Figure 10.** Definitive implant-supported denture installed.



**Figure 11.** Panoramic radiograph with definitive denture already installed. 65 days after surgery.

## DISCUSSION

Undoubtedly, rehabilitation of atrophic maxilla represents one of the biggest challenges of implant dentistry. Additionally, it is a topic that causes a lively debate about treatment guidelines, advantages and disadvantages of the different approaches available.<sup>22,23</sup>

In cases of sinus pneumatization and deficient subantral bone height, but with acceptable interarch relations, sinus floor elevation by means of the transcrestal technique or the lateral window technique is a well-documented procedure in which a variety of grafting material can be used

safely and predictably to achieve adequate bone height for implant placement in the posterior maxilla.<sup>22,24</sup>

Nonetheless, resorption of posterior maxilla will often occur in all three dimensions, and limited bone volume must be expected not only in vertical, but also in the horizontal plane. For these cases, in which bone width is insufficient for installation of standard diameter implants, autogenous onlay block graft, with intraoral or extraoral donor site, is a commonly adopted alternative depending on the extent of atrophy.<sup>22,23,24</sup>

In addition to the issues related to increased morbidity, complications and decreased sensibility in the harvesting area,<sup>7,8,9</sup> some studies report volumetric changes related to resorption of the autogenous grafted bone. By means of computerized tomography, Sbordone et al<sup>10</sup> assessed the long-term volume resorption of autogenous corticocancellous grafted bone harvested from the ilium and used in an alveolar augmentation procedure followed by endosseous dental implant placement. The 6-year survey for blocks grafted in the mandible revealed an average resorption rate of 87%; whereas for maxillary grafts, an average value of 105.5% was found. Despite the fact that large peri-implant osseous resorption was recorded in the maxillary buccal aspect of the grafted areas owing to the prevalence of horizontal bone augmentation (8 of 11 maxillary procedures) in this region, the survival rate of dental implants was 100%, thereby suggesting that bone graft resorption did not imply in loss of implant stability. This was most likely due to preservation of osseointegration, at least in its apical and palatal portions, where it is probable that only native bone was present.

Studies using two-dimensional radiographs to assess volumetric changes after bone graft in the mandible with a follow-up of 5 years estimate bone loss lower than in Vermeeren et al's study.<sup>25</sup>

Several researchers who compared two-dimensional standard dental radiographs with data obtained from CT scan analysis found widely varying results (under and overestimations of 21% and 18%, respectively)<sup>26</sup> mainly due to an association between bone height and total amount of potential resorption, in addition to enlargement and distortion of conventional

radiographic imaging.<sup>26</sup> Thus, for an overall analysis of grafted bone, a three-dimensional calculation is preferred.

Depending on residual bone width, guided bone regeneration<sup>27</sup> and ridge expansion techniques<sup>28</sup> are alternatives that allow simultaneous implant installation. Importantly, standard diameter implant placement in a horizontally deficient ridge involves potential risks of dehiscence defects formation, which increases coronal stress, especially in the buccal and lingual portions of the implant body.<sup>29</sup>

In the reported case, clinical examination and CT analysis revealed insufficient bone width for standard diameter implant placement due to alveolar ridge resorption. Taking future prosthetic rehabilitation into account, impressions were made to create a diagnostic waxing. Despite slight pseudopognathism due to atrophy of the maxilla, interarch relation was satisfactory for rehabilitation with fixed denture supported by RDIs, respecting prosthetic and biomechanical aspects in addition to restoring lip support without the need for reconstructive procedures. Therefore, priority was given to a simpler and less invasive treatment plan involving lower risk of complications reduced treatment time.

Thus, RDIs are an alternative to bone augmentation procedures prior to installation of standard diameter implants. In a systematic review, Sohrabi et al<sup>30</sup> selected 41 randomized clinical trials involving the use of implants with diameters ranging from 1.8 mm to 3.5 mm and a follow-up duration varying from 5 months to over 9 years. A total of 10,093 RDIs were inserted. The survival rate reported in all screened studies was over 90%, including eight studies in which a 100% survival rate was reported. In 22 studies,

the reported survival rate ranged from 95% to 99.9%. The authors concluded that the survival rate of RDIs appears to be comparable to that of regular diameter implants.

Importantly, regardless of the rehabilitative approach, the chronological indication for implant placement and prosthetic loading must respect the specific clinical variables of each case.<sup>22</sup>

In general, antibiotic prophylaxis is provided to patients with risk of endocarditis, in cases of surgery performed in infected sites, patients with reduced host immune response and cases of extensive and prolonged surgical procedures. The use of antibiotic prophylaxis in implant dentistry is controversial, with randomized controlled trials showing contradictory results.<sup>31-34</sup>

Hence, with a view to reaching a consensus, Esposito et al<sup>21</sup> conducted a systematic review in which they selected six randomized controlled trials. Three trials compared 2 g of preoperative amoxicillin *versus* placebo (927 participants), one compared 3 g of preoperative amoxicillin *versus* placebo (55 participants), one compared 1 g of preoperative amoxicillin plus 500 mg four times a day for two days *versus* no antibiotics (80 participants), and one compared four groups:

(1) 2 g of preoperative amoxicillin; (2) 2 g of preoperative amoxicillin plus 1 g twice a day for seven days; (3) 1 g of postoperative amoxicillin twice a day for seven days; and (4) no antibiotics (100 participants). The overall body of evidence was considered to be of moderate quality. Meta-analysis of the six trials showed a statistically significant higher number of participants experiencing implant failures in the group not receiving antibiotics. The authors concluded that, in general, antibiotics are beneficial at reducing failure of dental implants placed in ordinary conditions. More specifically, 2 g or 3 g of amoxicillin (oral single administration one hour before surgery) significantly reduces dental implant failure.

## CONCLUSION

According to the literature, as well as in the reported case, implants of reduced diameter represent a fast and simple alternative to procedures of horizontal bone augmentation. Additionally, they can be used with predictability as a way of retention for fixed denture, thereby proving an efficient and low-cost solution for edentulous patients who wish to minimize problems related to instability of removable dentures.

## REFERENCES:

- Albrektsson T, Zarb G, Worthington P, Eriksson AR. The long-term efficacy of currently used dental implants: a review and proposed criteria of success. *Int J Oral Maxillofac Implants.* 1986;1(1):11-25.
- Buser D, Mericske-Stern R, Bernard JP, Behneke A, Behneke N, Hirt HP, et al. Long-term evaluation of non-submerged ITI implants. Part 1: 8-year life table analysis of a prospective multi-center study with 2359 implants. *Clin Oral Implants Res.* 1997;8(3):161-72.
- Davarpanah M, Martinez H, Tecucianu JF, Celletti R, Lazzara R. Small-diameter implants: indications and contraindications. *J Esthet Dent.* 2000;12(4):186-94.
- Stellingsma K, Raghoebar GM, Meijer HJ, Stegenga B. The extremely resorbed mandible: a comparative prospective study of 2-year results with 3 treatment strategies. *Int J Oral Maxillofac Implants.* 2004;19(4):563-77.
- Nyström E, Ahlqvist J, Gunne J, Kahnberg KE. 10-year follow-up of onlay bone grafts and implants in severely resorbed maxillae. *Int J Oral Maxillofac Surg.* 2004;33(3):258-62.
- Aghaloo TL, Moy PK. Which hard tissue augmentation techniques are the most successful in furnishing bony support for implant placement? *Int J Oral Maxillofac Implants.* 2007;22 Suppl:49-70.
- Schwartz CE, Martho JF, Kowalski P, Wang DA, Bode R, Li L, et al. Prospective evaluation of chronic pain associated with posterior autologous iliac crest bone graft harvest and its effect on postoperative outcome. *Health Qual Life Outcomes.* 2009 May 29;7:49.
- Raghoebar GM, Louwse C, Kalk WW, Vissink A. Morbidity of chin bone harvesting. *Clin Oral Implants Res.* 2001;12(5):503-7.
- Silva FM, Cortez AL, Moreira RW, Mazzonetto R. Complications of intraoral donor site for bone grafting prior to implant placement. *Implant Dent.* 2006;15(4):420-6.
- Sbordone C, Toti P, Guidetti F, Califano L, Santoro A, Sbordone L. Volume changes of iliac crest autogenous bone grafts after vertical and horizontal alveolar ridge augmentation of atrophic maxillas and mandibles: a 6-year computerized tomographic follow-up. *J Oral Maxillofac Surg.* 2012;70(11):2559-65.
- Johansson B, Grepe A, Wannfors K, Hirsch JM. A clinical study of changes in the volume of bone grafts in the atrophic maxilla. *Dentomaxillofac Radiol.* 2001;30(3):157-61.
- Conceição APF, Tolentino LS, Garcez-Filho J, Araújo MG. Narrow-diameter implant installation: a systematic review. *Rev Dental Press Periodontia Implantol.* 2009;3(2):47-58.
- Polizzi G, Fabbro S, Furri M, Herrmann I, Squarzone S. Clinical application of narrow Brånemark System implants for single-tooth restorations. *Int J Oral Maxillofac Implants.* 1999;14(4):496-503.
- Cordaro L, Torsello F, Mirisola Di Torresanto V, Rossini C. Retrospective evaluation of mandibular incisor replacement with narrow neck implants. *Clin Oral Implants Res.* 2006;17(6):730-5.
- Garcez-Filho JA, Mendonça CG, Sukekava F, Conceição APF, Araújo MG. The use of reduced diameter implants in posterior maxillary region. Retrospective study until 8 years follow up. *Rev Dental Press Periodontia Implantol.* 2008;2(3):39-46.
- Tolentino L, Sukekava F, Seabra M, Lima LA, Garcez-Filho J, Araújo MG. Success and survival rates of narrow diameter implants made of titanium-zirconium alloy in the posterior region of the jaws - results from a 1-year follow-up. *Clin Oral Implants Res.* 2014;25(2):137-41.
- Degidi M, Nardi D, Piattelli A. Immediate restoration of small-diameter implants in cases of partial posterior edentulism: a 4-year case series. *J Periodontol.* 2009;80(6):1006-12.
- Chiapasco M, Casentini P, Zaniboni M, Corsi E, Anello T. Titanium-zirconium alloy narrow-diameter implants (Straumann Roxolid®) for the rehabilitation of horizontally deficient edentulous ridges: prospective study on 18 consecutive patients. *Clin Oral Implants Res.* 2012;23(10):1136-41.
- Cordaro L, Torsello F, Mirisola di Torresanto V, Baricevic M. Rehabilitation of an edentulous atrophic maxilla with four unsplinted narrow diameter titanium-zirconium implants supporting an overdenture. *Quintessence Int.* 2013;44(1):37-43.
- Al-Nawas B, Brägger U, Meijer HJ, Naert I, Persson R, Perucchi A, et al. A double-blind randomized controlled trial (RCT) of Titanium-13Zirconium versus Titanium Grade IV small-diameter bone level implants in edentulous mandibles: results from a 1-year observation period. *Clin Implant Dent Relat Res.* 2012;14(6):896-904.
- Esposito M, Grusovin MG, Worthington HV. Interventions for replacing missing teeth: antibiotics at dental implant placement to prevent complications. *Cochrane Database Syst Rev.* 2013 Jul 31;7:CD004152.
- Katsuyama H, Jensen SS. ITI treatment guide, sinus floor elevation procedures. Berlin: Quintessence; 2011.
- Chiapasco M, Casentini P, Zaniboni M. Bone augmentation procedures in implant dentistry. *Int J Oral Maxillofac Implants.* 2009;24 Suppl:237-59.
- Chiapasco M, Zaniboni M, Rimondini L. Dental implants placed in grafted maxillary sinuses: a retrospective analysis of clinical outcome according to the initial clinical situation and a proposal of defect classification. *Clin Oral Implants Res.* 2008;19(4):416-28.
- Vermeeren JI, Wismeijer D, van Waas MA. One-step reconstruction of the severely resorbed mandible with onlay bone grafts and endosteal implants. A 5-year follow-up. *Int J Oral Maxillofac Surg.* 1996;25(2):112-5.
- Waitzman AA, Posnick JC, Armstrong DC, Pron GE. Craniofacial skeletal measurements based on computed tomography: Part I. Accuracy and reproducibility. *Cleft Palate Craniofac J.* 1992;29(2):112-7.
- Buser D, Bornstein MM, Weber HP, Grütter L, Schmid B, Belser UC. Early implant placement with simultaneous guided bone regeneration following single-tooth extraction in the esthetic zone: a cross-sectional, retrospective study in 45 subjects with a 2- to 4-year follow-up. *J Periodontol.* 2008;79(9):1773-81.
- Garcez-Filho J, Araújo MG. Modification of edentulous ridge expansion technique with immediate installation of Straumann® implants: follow-up of 10 cases for a period of 1 year. *Rev Dental Press Periodontia Implantol.* 2007;1(2):84-97.
- Lang NP, Wilson TG, Corbet EF. Biological complications with dental implants: their prevention, diagnosis and treatment. *Clin Oral Implants Res.* 2000;11 Suppl 1:146-55.
- Sohrabi K, Mushantat A, Esfandiari S, Feine J. How successful are small-diameter implants? A literature review. *Clin Oral Implants Res.* 2012;23(5):515-25.
- Dent CD, Olson JW, Farish SE, Bellome J, Casino AJ, Morris HF, et al. The influence of preoperative antibiotics on success of endosseous implants up to and including stage II surgery: a study of 2,641 implants. *J Oral Maxillofac Surg.* 1997;55(Suppl 5):19-24.
- Gynther GW, Köndell PÅ, Moberg L-E, Heimdahl A. Dental implant installation without antibiotic prophylaxis. *Oral Surg Oral Med Oral Pathol Oral Radiol Endod.* 1998;85(5):509-11.
- Laskin DM, Dent CD, Morris HF, Ochi S, Olson JW. The influence of preoperative antibiotics on success of endosseous implants at 36 months. *Ann Periodontol.* 2000;5(1):166-74.
- Binahmed A, Stoykewych A, Peterson L. Single preoperative dose versus long-term prophylactic antibiotic regimens in dental implant surgery. *Int J Oral Maxillofac Implants.* 2005;20(1):115-7.