

# Immediate *versus* early implant placement



Washington SANTANA

MSc in Dentistry, Federal University of Goiás (UFG). Professor of Implantodontics, IKO-Goiânia.

## **Point:** *Immediate implant placement or not? The current dilemma for lost teeth*

### INTRODUCTION

One of the most common procedures performed by implant dentists consists in carrying out extraction followed by implant placement in the remaining socket. From the standpoint of survival, the high success rates described in the literature<sup>6</sup> confirm the efficacy of this therapy to solve issues concerning compromised natural teeth.

Nevertheless, there is evidence of the impact caused by changes in the dimensional alterations of the alveolar ridge,<sup>1,2,3</sup> the position of the implant inside the socket,<sup>4</sup> the tissue biotype and, especially, the surgical technique, whether flap or flapless, associated with regenerative procedures of hard and soft tissues.<sup>5</sup> All this evidence demonstrates the severity and multifactorial nature involved in this therapeutic option. I write “option” here because immediate implant placement should always be considered as an alternative for rehabilitation, not as an imperative. The advantages of treating tooth loss by means of immediate implant placement, which may even include the crown in many cases, are tempting. Most of

times, this treatment protocol fulfills patient’s expectations, since it reduces the number of necessary procedures and, most importantly, reduces the time interval between extraction and prosthetic crown installation.

On the other hand, as I have previously mentioned, a number of variables are responsible for determining whether immediate implant placement after extraction yields favorable results or not. For this reason, those clinicians who are prone to carry out the procedure need to be able to diagnose potential risk factors, in addition to having technical training and surgical experience to intervene in tissue deficiencies.

Since immediate implant placement involves a potential risk of complications, particularly in the esthetic zone, it is paramount that clinicians be able not only to identify risk factors, but also respond to them whenever the immediate approach is recommended. Furthermore, they have to be aware of the prognosis of the preservation and reconstruction techniques associated with immediate implant placement.

**How to cite this article:** Santana W, Nunes LS. Immediate *versus* early implant placement. Dental Press Implantol. 2014 July-Sept;8(3):34-55. doi: <http://dx.doi.org/10.14436/2237-650X.8.3.034-055.pec>

**Submitted:** September 10, 2014 - **Revised and accepted:** September 16, 2014

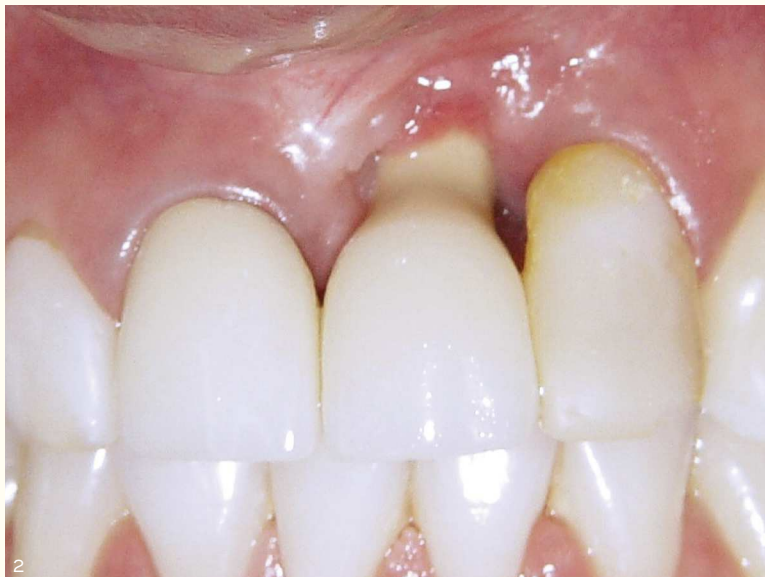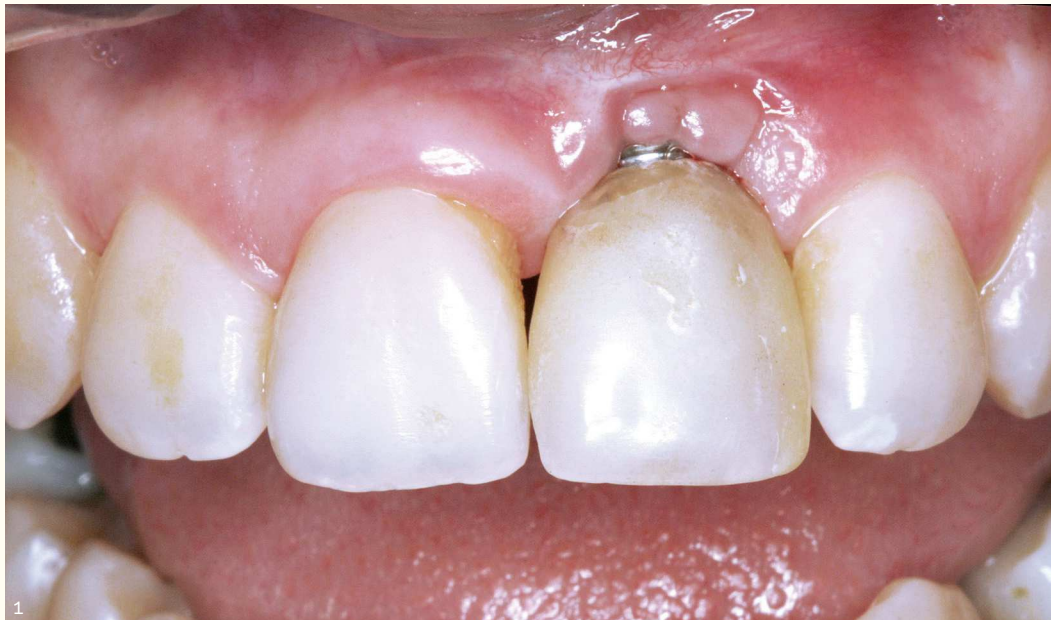**Contact address:** Washington Santana - INFACE Odontologia Cirúrgica e Estética  
Alameda Ricardo Paranhos, 799 - Ed. Prospere Office - salas 314-316 - Setor Marista - Goiânia/  
GO - Brazil - E-mail: [wmsantana1@gmail.com](mailto:wmsantana1@gmail.com)

» The authors report no commercial, proprietary or financial interest in the products or companies described in this article.

» Patients displayed in this article previously approved the use of their facial and intraoral photographs.

Patients involving rehabilitation of maxillary esthetic zone, especially those with a high smile line, require comparison with adjacent teeth, as well as proportion and balance of gingival margins, papillae and contour. All these factors play an important role in determining

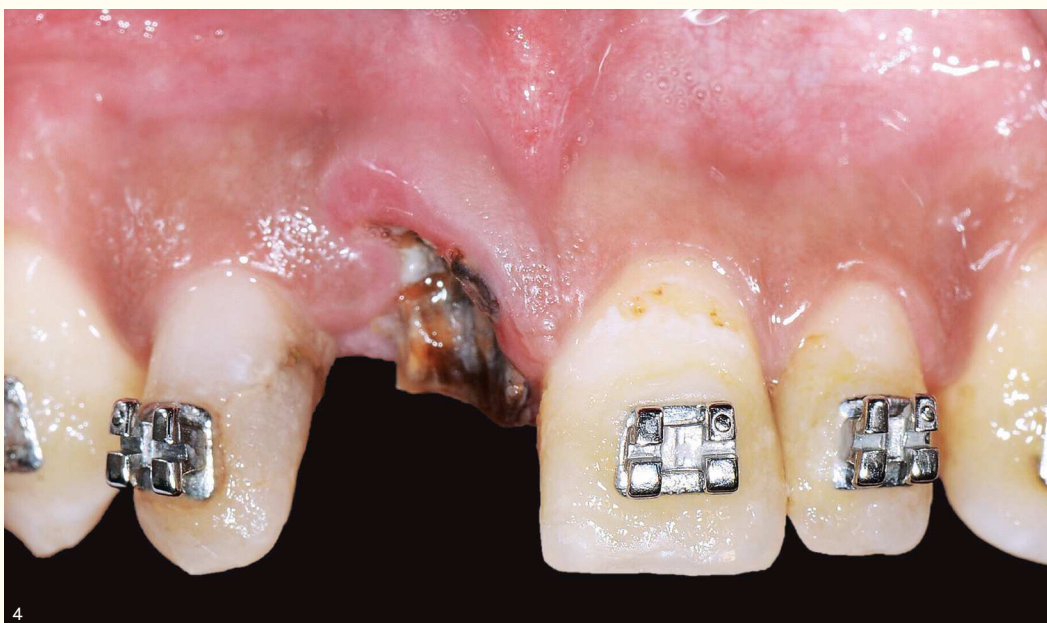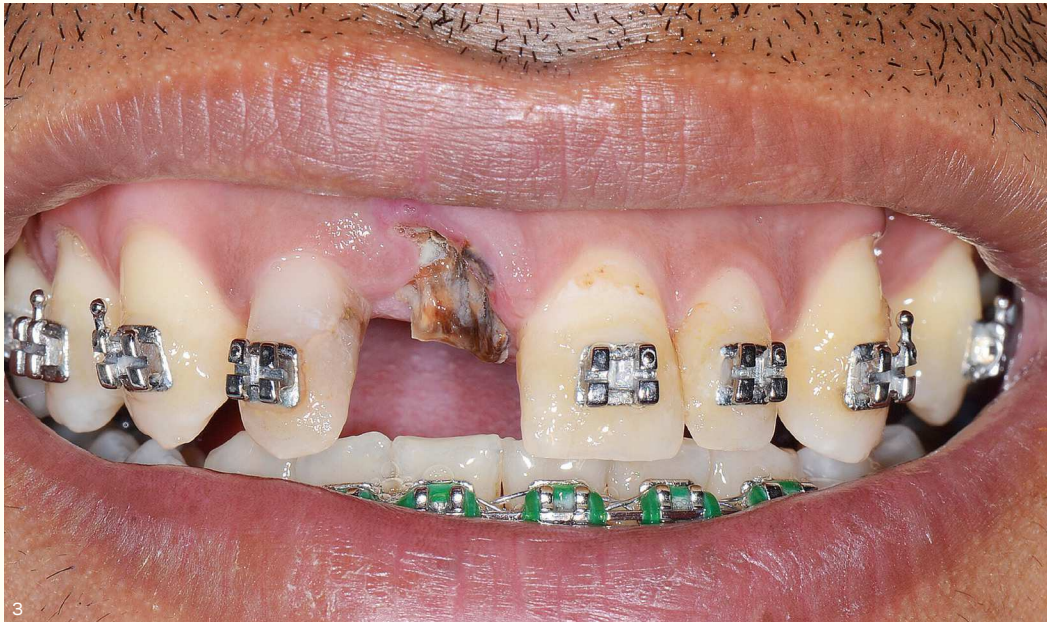
potential biological challenges the clinician might find in each case, thereby favoring the best results possible within the limits imposed by tissue repair. Should these needs not be considered, they might lead to catastrophic results in terms of final smile esthetics (Figs 1, 2).

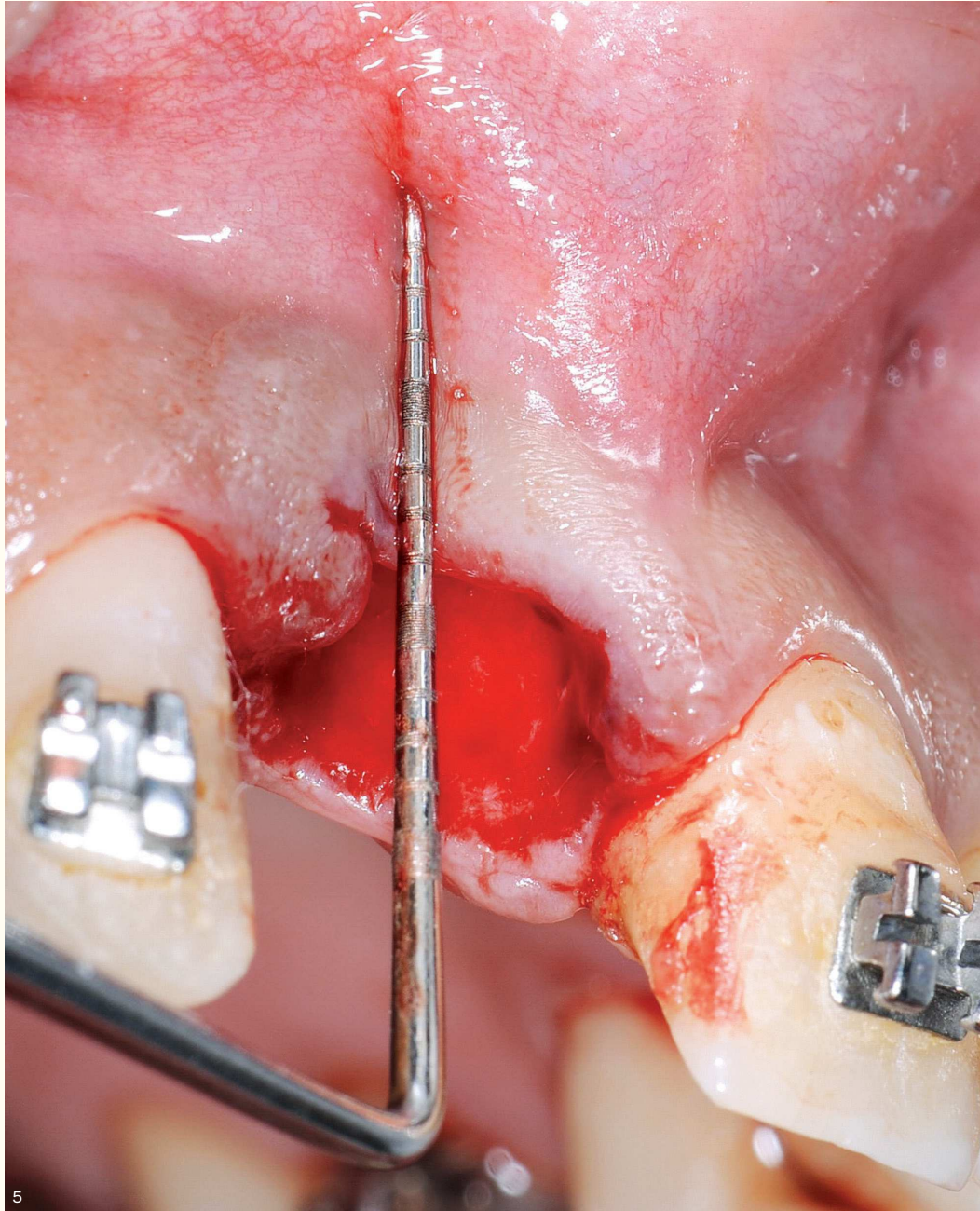


**Figures 1, 2.** Immediate implant-supported crowns with tissue deficiency and compromised esthetic outcomes.

Bone loss significant enough to make implant anchorage impracticable, as well as significant soft tissue defects, such as extremely challenging gingival recession, may represent

a potential drawback of immediate implant placement, particularly due to the vascular needs imposed by connective tissue grafting (Figs 3,4,5).

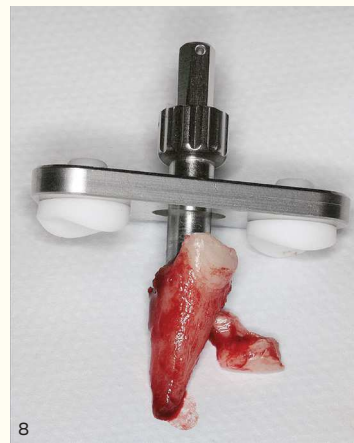
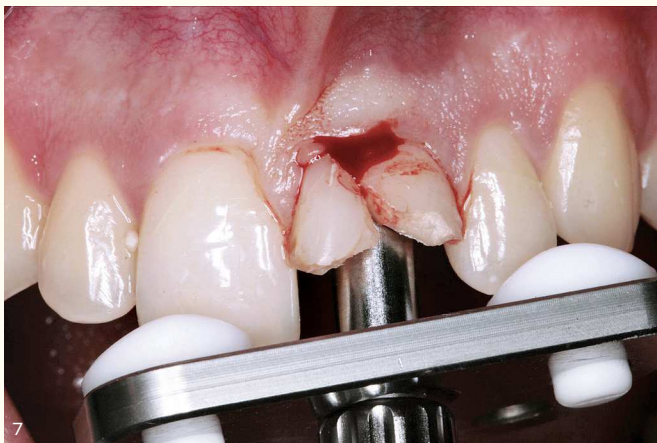
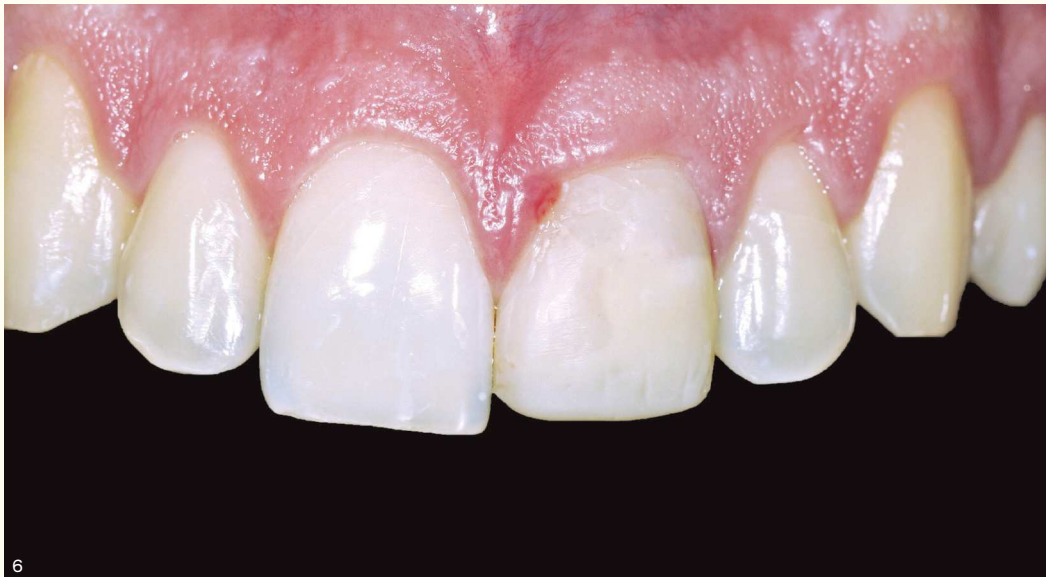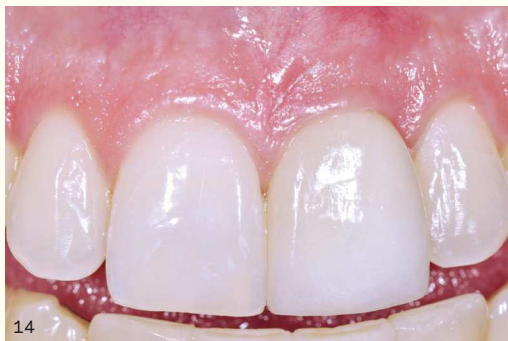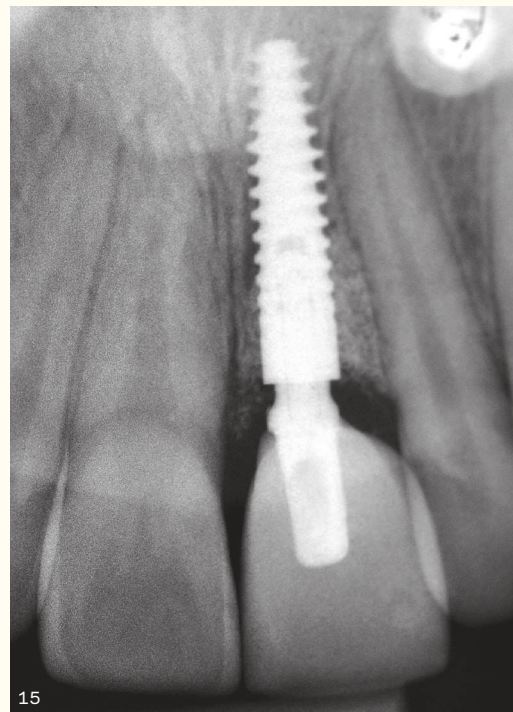
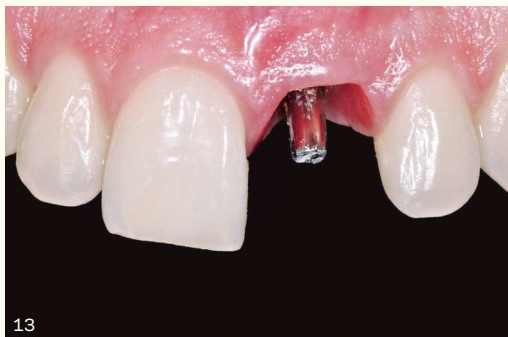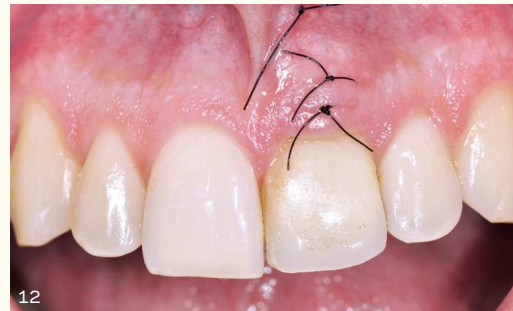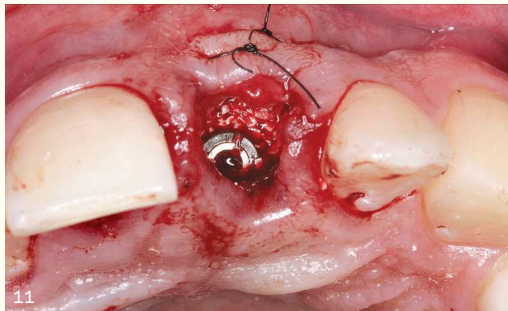
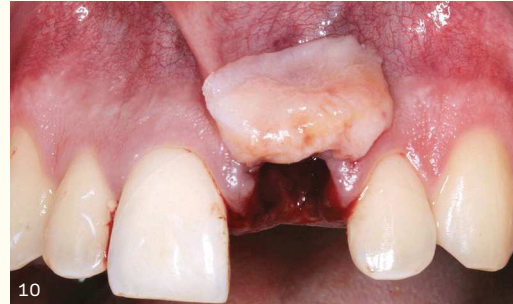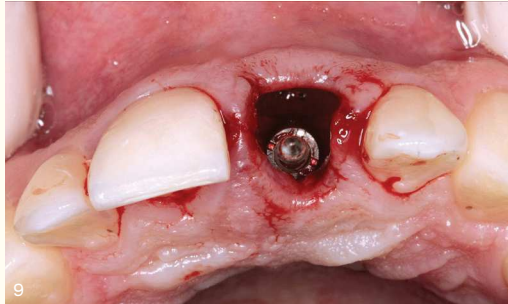


**Figures 3, 4, 5.** Patient with high smile line and tooth #11 with extensive crown and root loss, buccal and distal-proximal gingival recession, and compromised buccal bone. High risk for immediate implant placement.

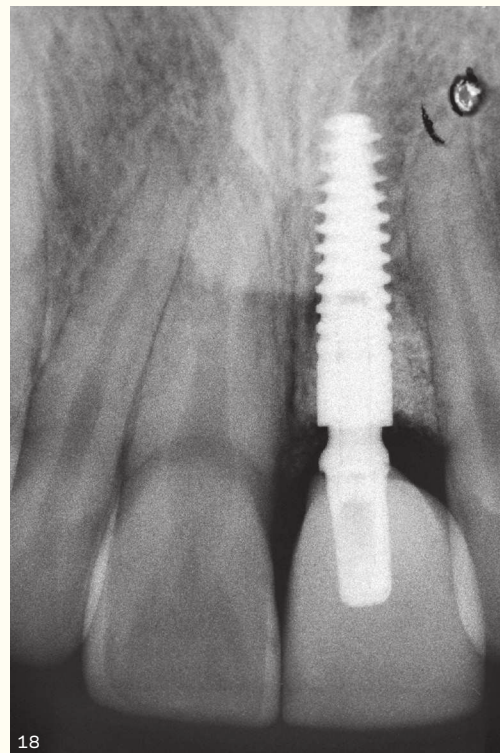
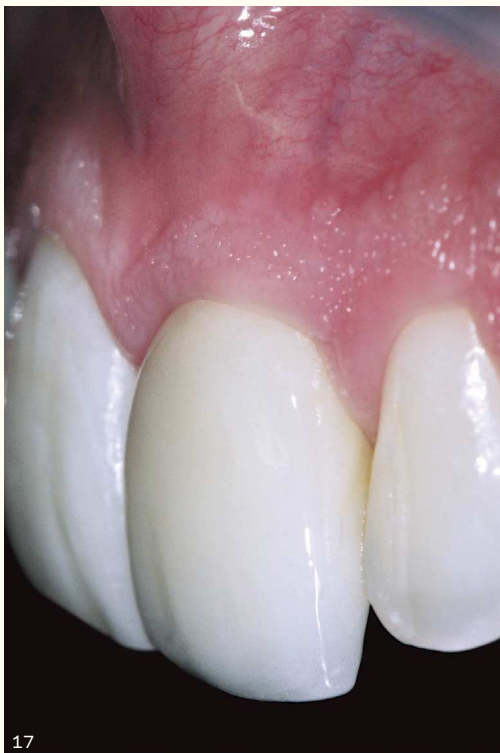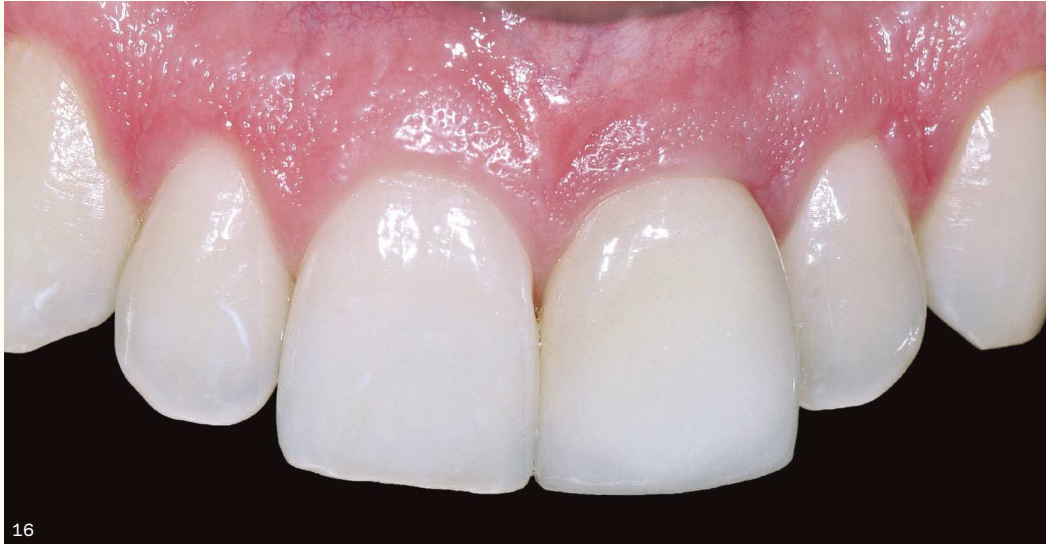On the contrary, should gingival margin be appropriate or with minor recession liable to potential gain, and should bone defects be absent or allowing flapless reconstruction

(whenever possible), it is reasonable to assert that implant placement is likely to yield highly satisfactory results within the context of planned esthetic rehabilitation (Figs 6 to 18).





**Figures 6 to 15.** Flapless extraction followed by immediate implant placement with connective tissue grafting, socket filling with Bio-Oss (Geistlich Pharma AG) and provisional implant for immediate esthetic outcomes. Note the excellent tissue conditions favored by reconstructive procedures conducted for prosthetic finishing. (Prosthesis: Dr. Daniela Mendonça, Goiânia/GO — Brazil).



**Figures 16, 17, 18.** Tissue stability three years after treatment completion.

## CONCLUSION

Despite controversy over the concepts of thin and thick tissue biotype as well as the ideal bone graft used to fill the gap between implant and buccal bone, current evidence allows us to assert that implant placement in the anterior maxilla and the palatal surface of the socket, associated with filling with inorganic bovine matrix of slow remodeling and buccal connective tissue grafting, have positive effects on the maintenance of tissue morphology necessary to attain the so-called stability. But what would tissue stability be? As a clinician I believe this concept should be defined as the maintenance of prosthetic outcomes, including morphology, volume and texture of peri-implant mucosa and bone after rehabilitation procedures. This is because

even after 50 years of contemporary post-osseointegration Implantodontics and despite all advances we still have many questions that remain unanswered with regard to modifications of the alveolar ridge and the mucosa. For instance, the real influence of different implant surfaces, prosthetic connections and provisional implants design, which seems to exert some influence over treatment outcomes, requires further studies conducted to control potential variables and reach definite conclusions.

One way or the other, rehabilitation treatment conducted to replace lost teeth with immediate implants needs to focus on longevity of results. And that certainly is our biggest challenge. May you all have a good decision-making.

## REFERENCES:

1. Araújo MG, Lindhe J. Dimensional ridge alterations following tooth extraction. An experimental study in the dog. *J Clin Periodontol.* 2005;32(2):212-8.
2. Amler MH. The time sequence of tissue regeneration in human extraction wounds. *Oral Surg Oral Med Oral Pathol.* 1969;27(3):309-18.
3. Cardaropoli G, Araújo M, Lindhe J. Dynamics of bone tissue formation in tooth extraction sites. An experimental study in dogs. The time sequence of tissue regeneration in human extraction wounds. *J Clin Periodontol.* 2003;30(9):809-18.
4. Chen ST, Darby IB, Reynolds EC. A prospective clinical study of non-submerged immediate implants: clinical outcomes and esthetic results. *Clin Oral Implants Res.* 2007;18(5):552-62. Epub 2007 Jun 30.
5. Covani U, Marconcini S, Galassini G, Cornelini R, Santini S, Barone A. Connective tissue graft used as a biologic barrier to cover an immediate implant. *J Periodontol.* 2007;78(8):1644-9.
6. Evian CI, Emling R, Rosenberg ES, Waasdorp JA, Halpern W, Shah S, et al. Retrospective analysis of implant survival and the influence of periodontal disease and immediate placement on long-term results. *Int J Oral Maxillofac Implants.* 2004;19(3):393-8.



## Immediate *versus* early implant placement



Leandro Soeiro NUNES

PHD resident in Oral and Maxillofacial Surgery and Traumatology, Catholic University of Rio Grande do Sul (PUCRS).

### Counterpoint: *Early implant placement*

#### INTRODUCTION

Rehabilitation of patients who lost a tooth in the anterior maxilla has always been an esthetic issue; however, osseointegrated implants have yielded excellent esthetic outcomes and, for this reason, have become an appropriate treatment option. Being that the case, choosing the right moment for implant placement after extraction is paramount and should be based on proper clinical and imaging examinations, as well as on professional experience. During the Third ITI Consensus Conference<sup>1</sup> held in Gstaad, Switzerland, in 2003, the ITI group reached a consensus to classify post-extraction implant placement, grouping the moments of implant placement into “immediate”, “early” (4 to 16 weeks) and “delayed” (> 16 weeks).

Implant placement in fresh socket is a fact, and provided that it is well conducted, it yields satisfactory outcomes.<sup>2,3,4</sup> However, the technique is relatively complex and its success is strongly associated with the clinician’s professional experience, knowledge of anatomy, good surgical technique and the use of high-quality material. Patients’ anxiety and hurry in solving their problems lead many clinicians to run unnecessary risks which might hinder final treatment outcomes in the medium and long-term. In some cases, the presence of infection, severe bone loss, the need for bone regeneration and/or increased buccal bone contour (Figs 1, 2, 3) contraindicate immediate implant placement, in which case it is advisable to wait a few weeks after extraction.

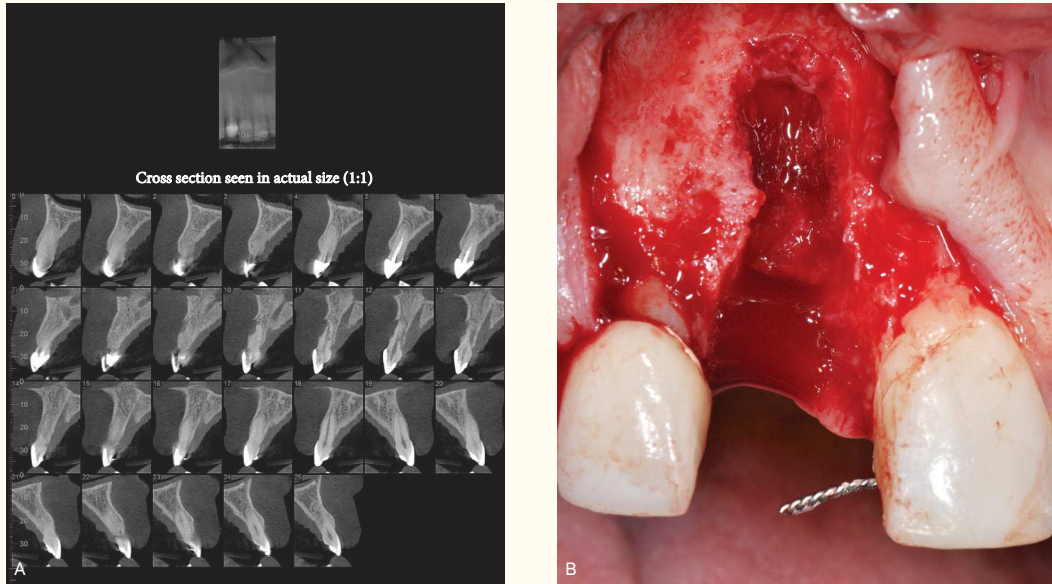
**How to cite this article:** Santana W, Nunes LS. Immediate *versus* early implant placement. Dental Press Implantol. 2014 July-Sept;8(3):34-55.

**Submitted:** September 10, 2014 - **Revised and accepted:** September 16, 2014

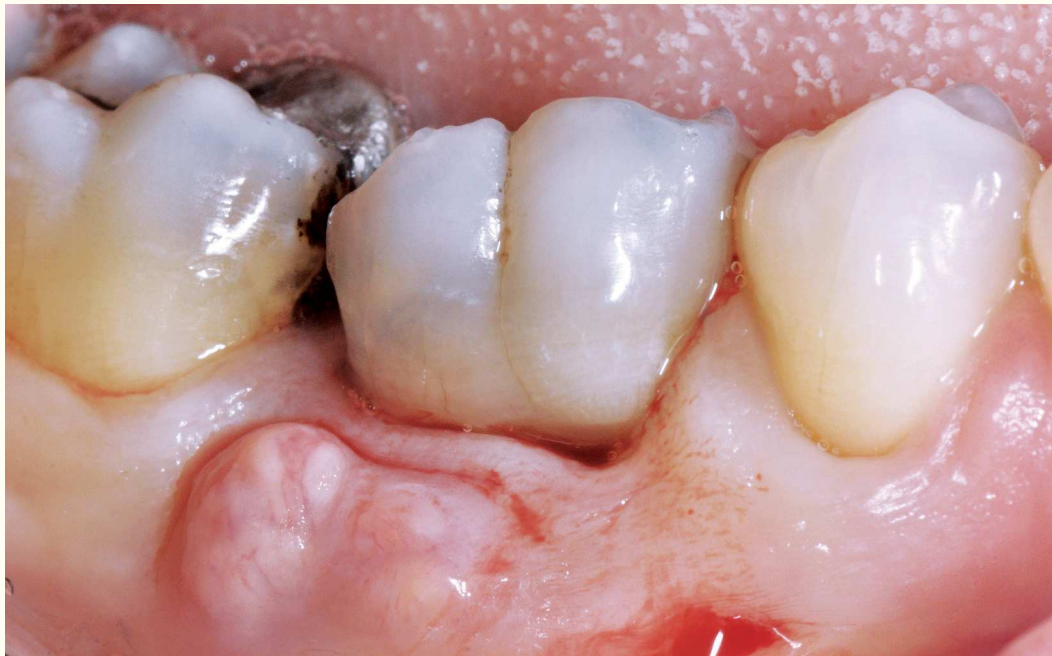**Contact address:** Leandro Soeiro Nunes  
E-mail: leandrossnunes@hotmail.com

» The authors report no commercial, proprietary or financial interest in the products or companies described in this article.

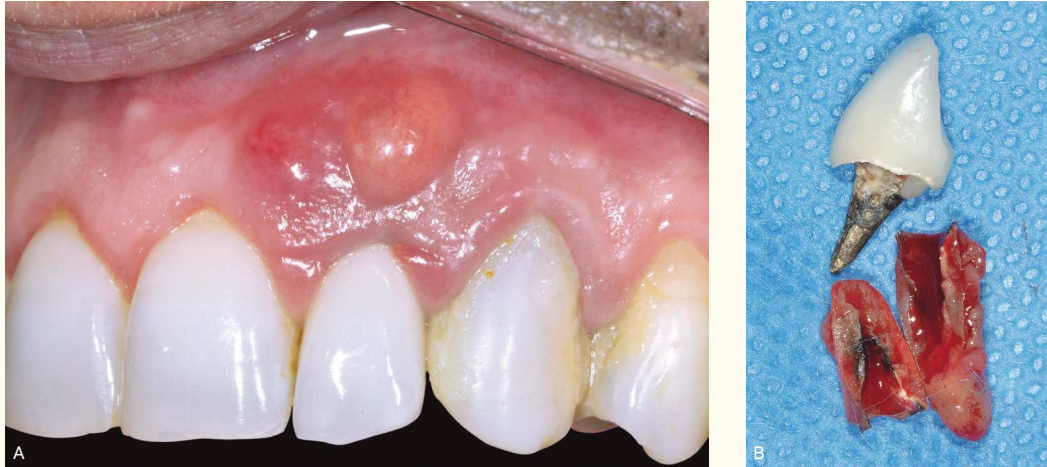» Patients displayed in this article previously approved the use of their facial and intraoral photographs.



**Figure 1.** A) Central incisor with extensive post-trauma root resorption associated with loss of buccal bone plate. B) Clinical case after central incisor extraction.



**Figure 2.** Cervical abscess in tooth with crown fracture.



**Figure 3. A)** Acute apical abscess with active suppuration in lateral incisor with root fracture. **B)** Lateral incisor extracted due to root fracture.

In these cases, early implant placement is the approach of choice, as it allows local infection to be solved as well as soft tissue to heal, which will contribute to closing the flap after implant placement and associated bone regeneration. Several studies demonstrate that the alterations of the alveolar ridge occurring after extraction cannot be avoided by means of immediate implant placement. Additionally, soon after extraction, the site presents high osteoclastic activity which will be responsible for bundle bone resorption and dimensional alterations of the socket. By the time early implant placement happens, these alterations have already occurred, thereby allowing lost tissue to regenerate in a predictable manner and with high success rates.

This treatment approach has yielded excellent results in the long run.<sup>5,6</sup> A 10-year follow-up study conducted with 511 implants placed in 303 patients had a success

rate of 97%, and a survival rate of 98.8%.<sup>7</sup> According to Buser et al,<sup>8</sup> two anatomical structures are paramount: interproximal vertical bone crest height and buccal bone plate height and thickness. The interproximal bone crest height of the adjacent tooth is what determines the presence or absence of peri-implant papilla. Thus, cases of adjacent teeth with minimal bone height cannot be controlled by the surgeon. However, horizontal deficiencies in the buccal implant surface can be addressed by means of guided bone regeneration techniques.

Early implant placement has to be associated with guided bone regeneration (GBR) so as to recover the lost bone structure. Clinical trials<sup>9,10</sup> have demonstrated that implants placed at sites with lack of buccal bone have higher chances of complications involving soft tissues and/or compromised prognosis in the long-term. With a view to avoiding further complications and associated failure at sites

with unsatisfactory bone volume, the importance of regenerative procedures carried out before or during implant placement is highlighted. The main objective of early implant placement is providing increased contour on the buccal surface of the implant. Such an increase of contour should be combined with proper implant three-dimensional positioning, so as to allow correct prosthesis placement and final rehabilitation.

In order to carry out implant placement and guided bone regeneration at the same time, a few requirements are rendered necessary. In this context, the clinician might apply the following criteria in order to aid decision making:

- In terms of esthetics and function, it should be possible to place the implant in proper three-dimensional position;
- It should be possible to achieve primary stability at this specific position;
- Peri-implant bone defect should have favorable morphology (two or three walls) in order to allow bone regeneration with predictable results at the region of the defect.

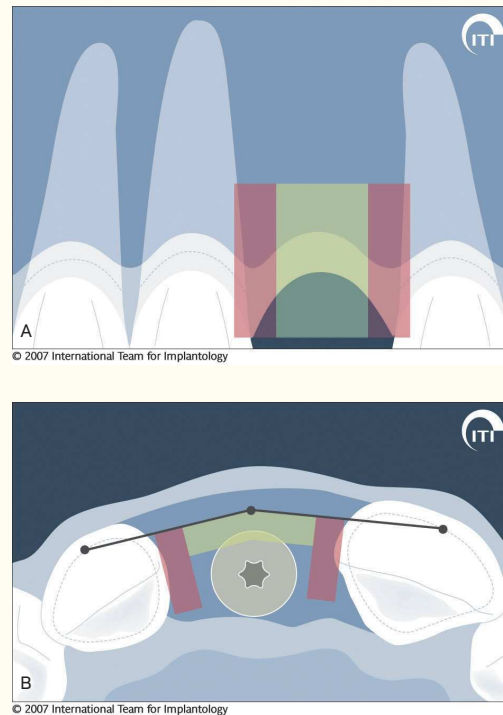
Implant placement in proper three-dimensional position is paramount to produce satisfactory functional and esthetic results (Fig 4). Furthermore, primary stability is key to the success of osseointegration. Therefore, having a residual ridge that allows implant stability is essential for this technique.

Additionally, the morphology of bone defect is a very important local factor for the success of guided bone regeneration carried out at the same time of implant placement. Moreover, counting the number of bone walls that might contribute to bone neoformation is a well-grounded method used to distinguish

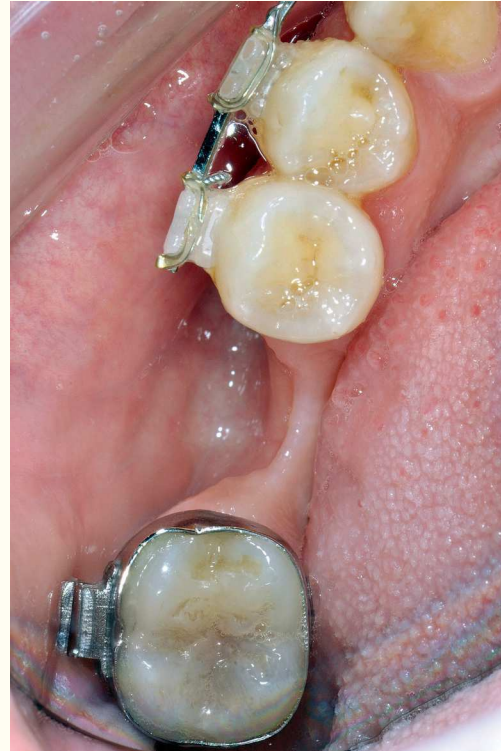one case from the other. It is an easy rule: The more bone walls available, the better the potential for healing of a given site. Should bone defect be found in a single wall (Fig 5), the case is more complicated than defects found in two or three bone walls. Bone defects found in two or three walls present a favorable morphology. They are commonly found in post-extraction sites (Fig 6).

With a view to speeding bone neoformation up and preserving bone volume in the long-term, clinicians should opt for implants with proper surface treatment, in addition to material with osteogenic properties (when in contact with implants) and a layer of material of low resorption index.

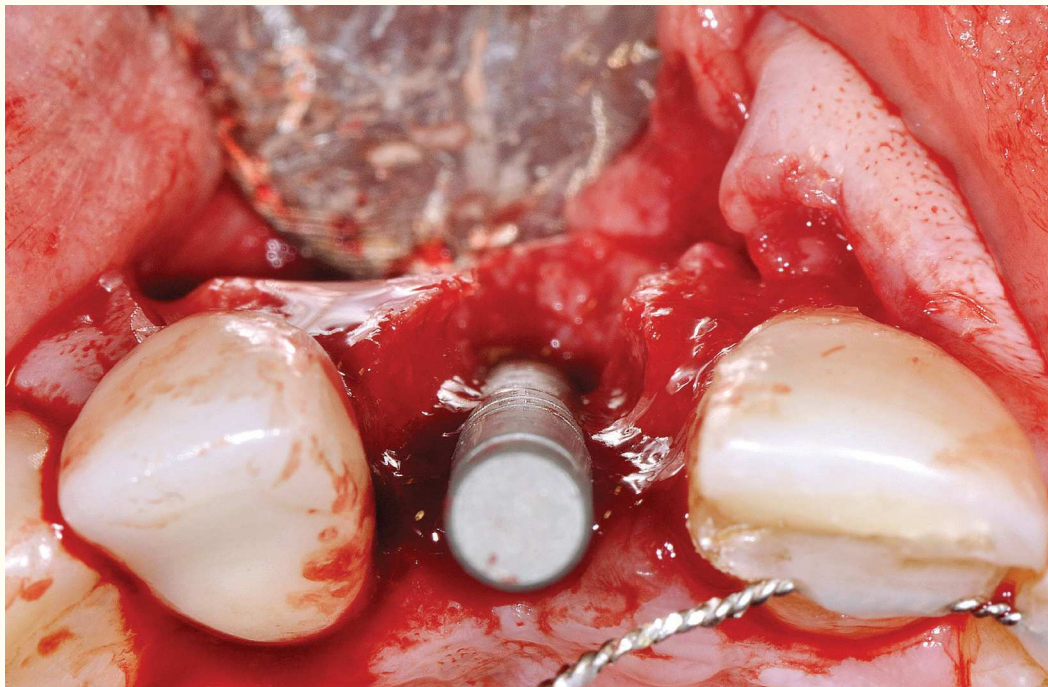
Thus, autogenous bone resulting from bone curettage performed at the



**Figure 4.** Ideal three-dimensional implant position (Source: ITI, 2007).



**Figure 5.** Single bone wall defect rendering GBR unpredictable and difficult.

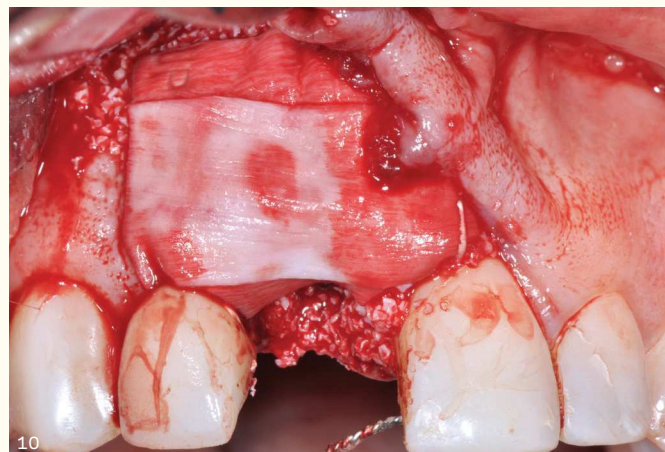
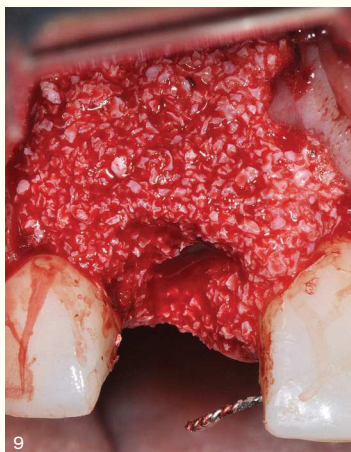
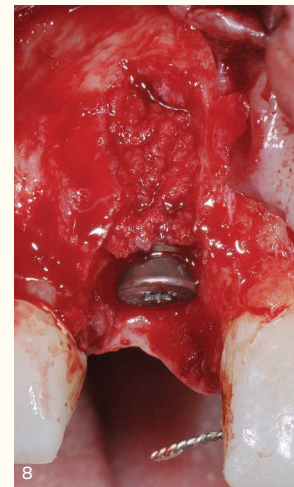
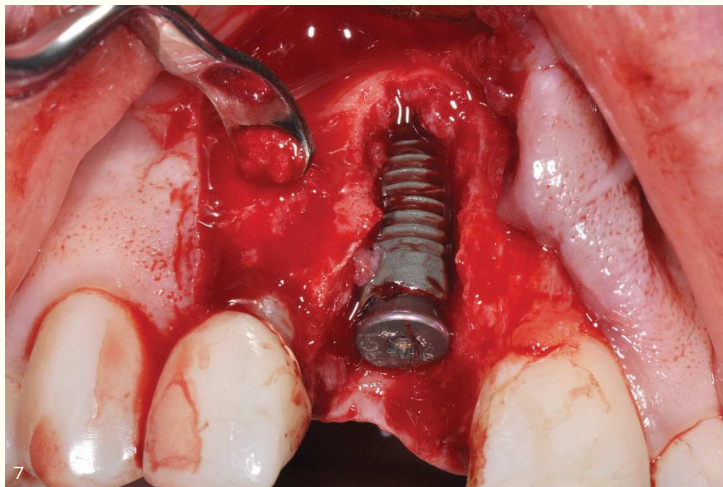


**Figure 6.** Defect of two bone walls (mesial and distal) at an extraction site, which favors GBR.

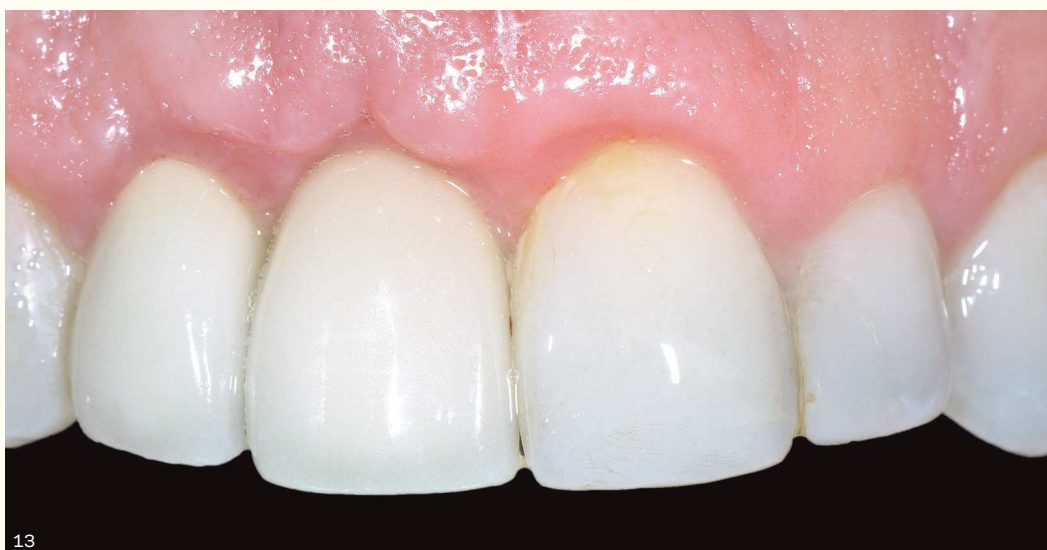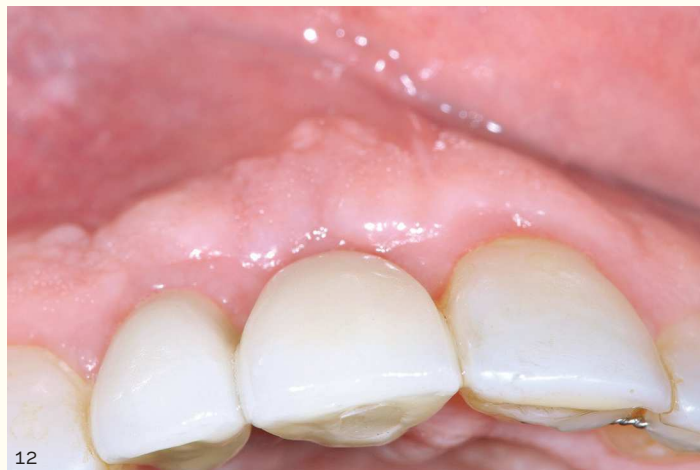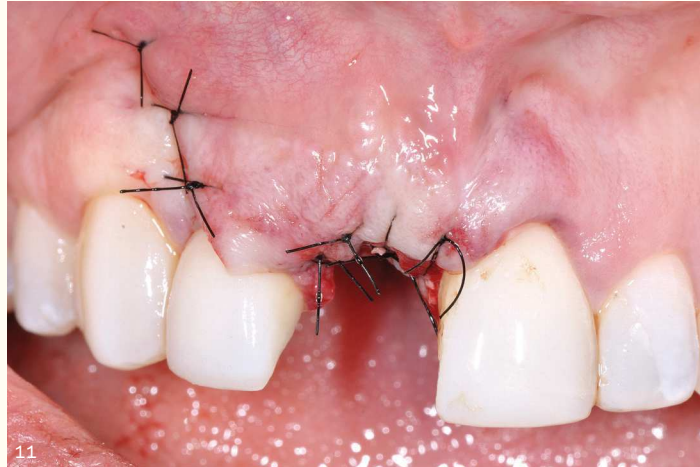same surgical site should be directly applied to the surface of the implant exposed (Figs 7, 8). A layer of biomaterial with low absorption rate (hydroxyapatite, Bio-Oss) should be applied over the autogenous bone to improve the quality of alveolar contour and preserve bone graft architecture in the long-term (Fig 9). A resorbable collagen membrane functions as a provisional barrier that keeps biomaterial in the correct position, in addition to preventing unwanted cellular invasion (Fig 10). First intention wound healing is key to treatment success

and should happen without any tension (Fig 11). After osseointegration, the implant can be exposed and subjected to prosthetic rehabilitation (Figs 12, 13). The presence of an appropriate buccal bone plate favors maintenance of buccal gingival margin in the long-term. As for the presence of papillae, it is determined by the bone crest present in adjacent teeth and prepared during conditioning of soft tissues.

Early implant placement performed at the same time of guided bone regeneration proves highly predictable and with satisfactory esthetic



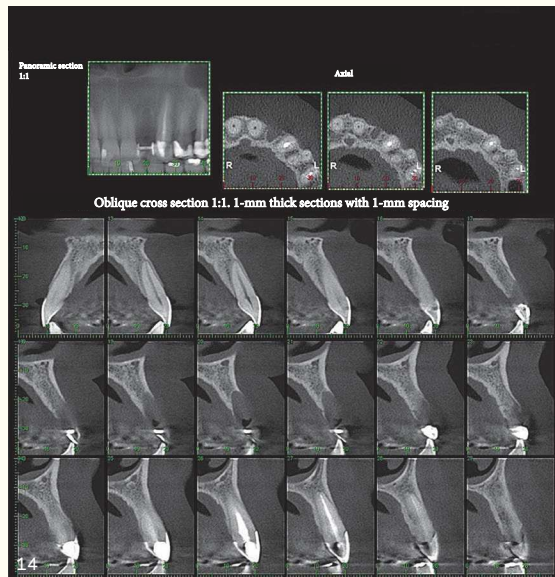**Figures 7 to 13.** Early implant placement six weeks after extraction of central incisor with root resorption and severe bone loss. After placing the implant in ideal position, GBR (Bio-Oss, Geistlich, Switzerland) was carried out to increase buccal contour and favor prosthetic rehabilitation (one-year follow-up).



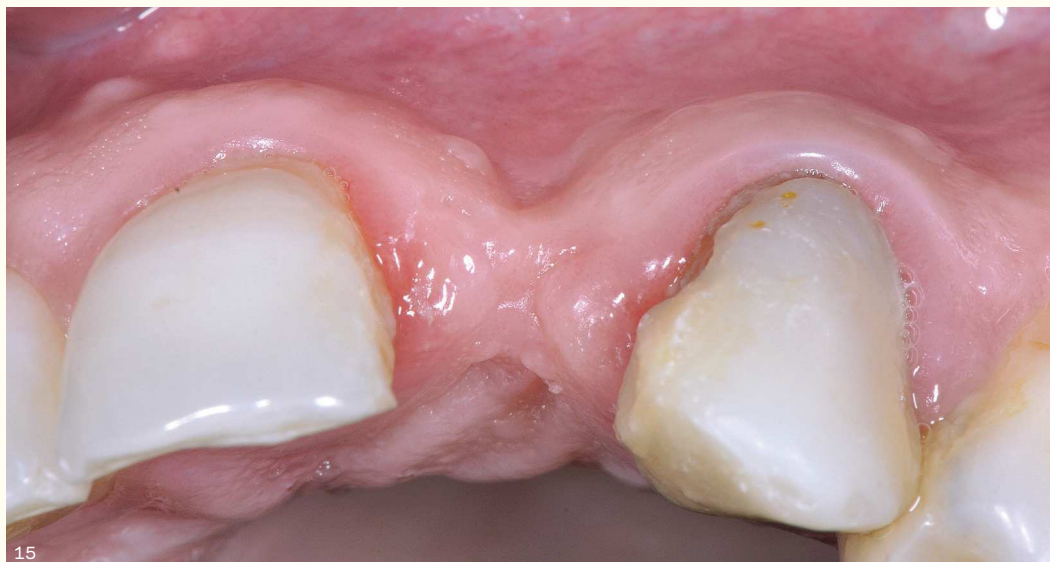results. It can be performed in the anterior (Figs 14 to 27) and posterior region (Figs 28 to 35). In 2013, the issue of implant placement in extraction sockets was brought back to discussion during the Fifth ITI Consensus Conference (Bern, Switzerland).<sup>11</sup> The results of that extensive literature review revealed that both immediate and early implant placement yield excellent esthetic

results; however, they differ in terms of degrees of difficulty.

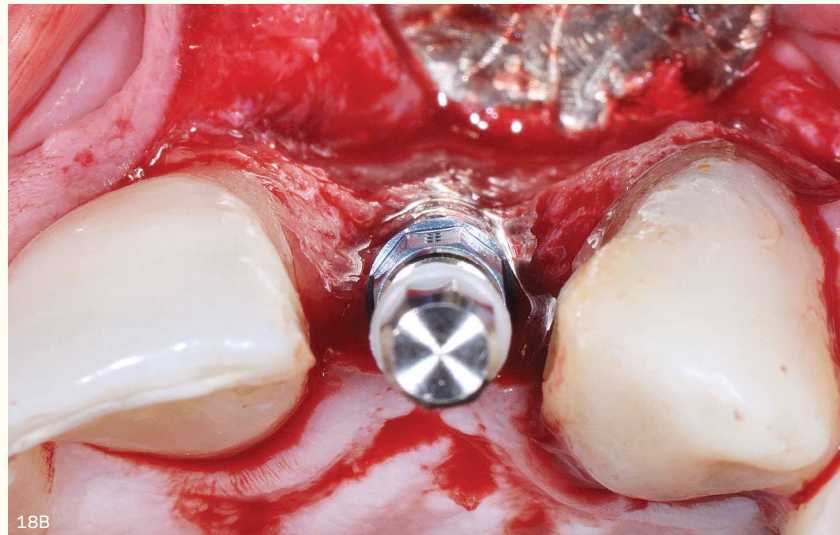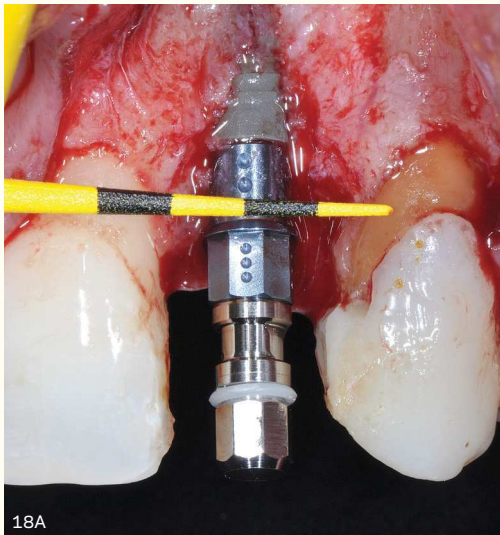
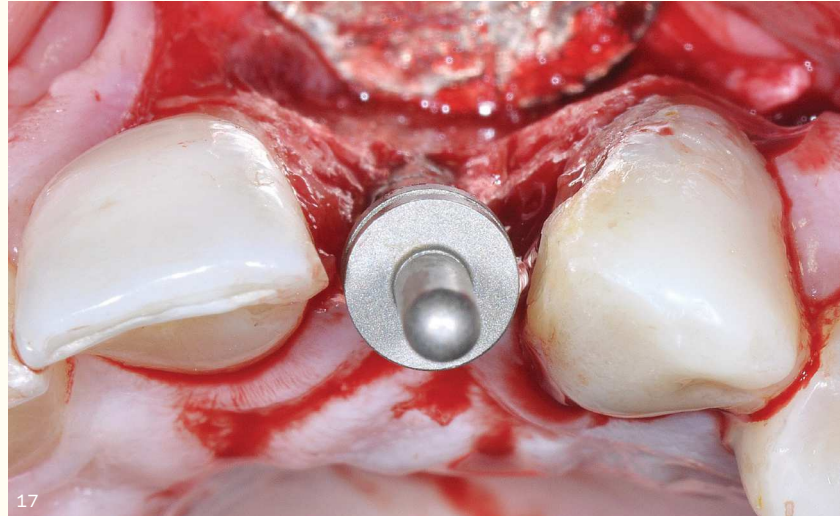
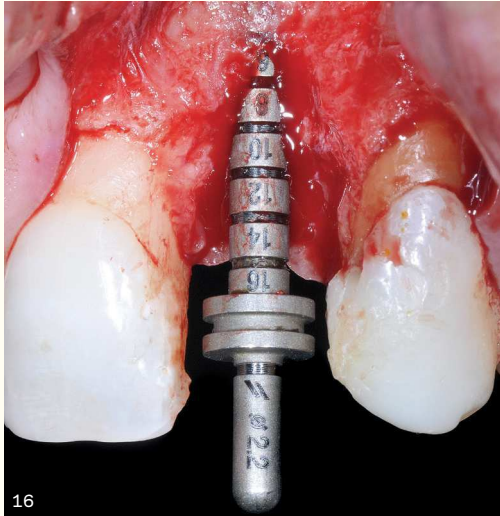
Despite numerous changes in implant protocols and approaches made in the last few years, accurate diagnosis and proper planning remain crucial to achieve treatment excellence. Implant placement at sites with inappropriate amount of bone has become routine in the clinical practice.

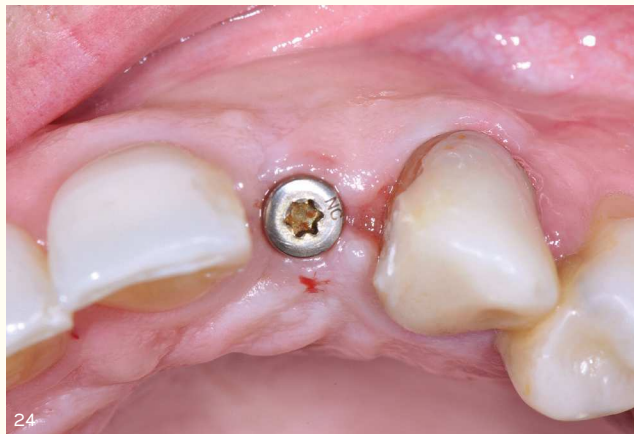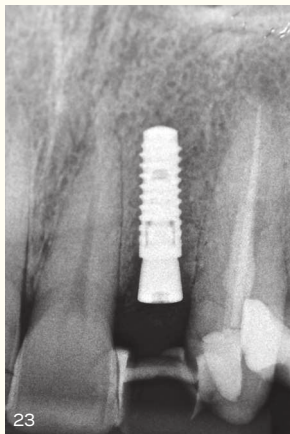
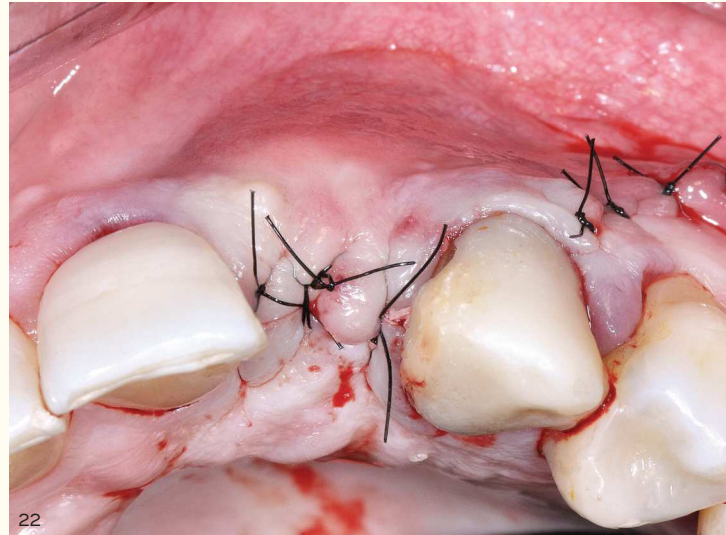
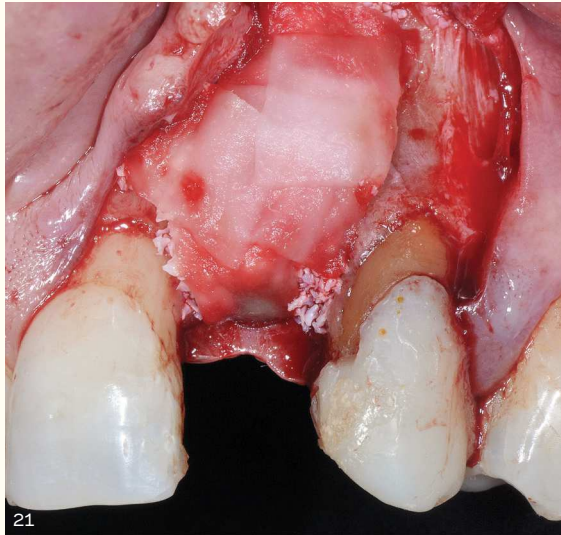
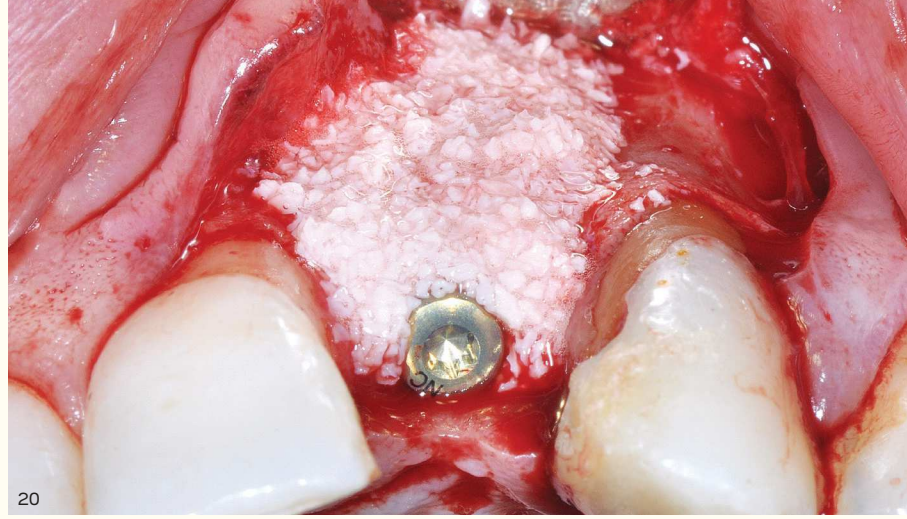
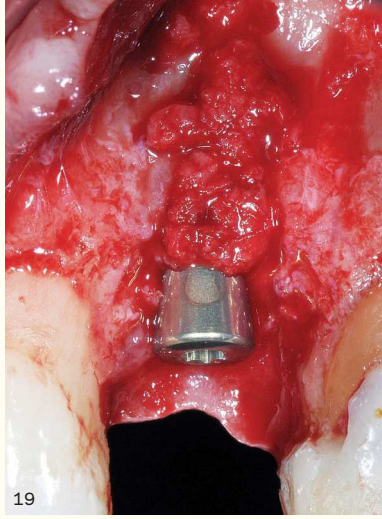


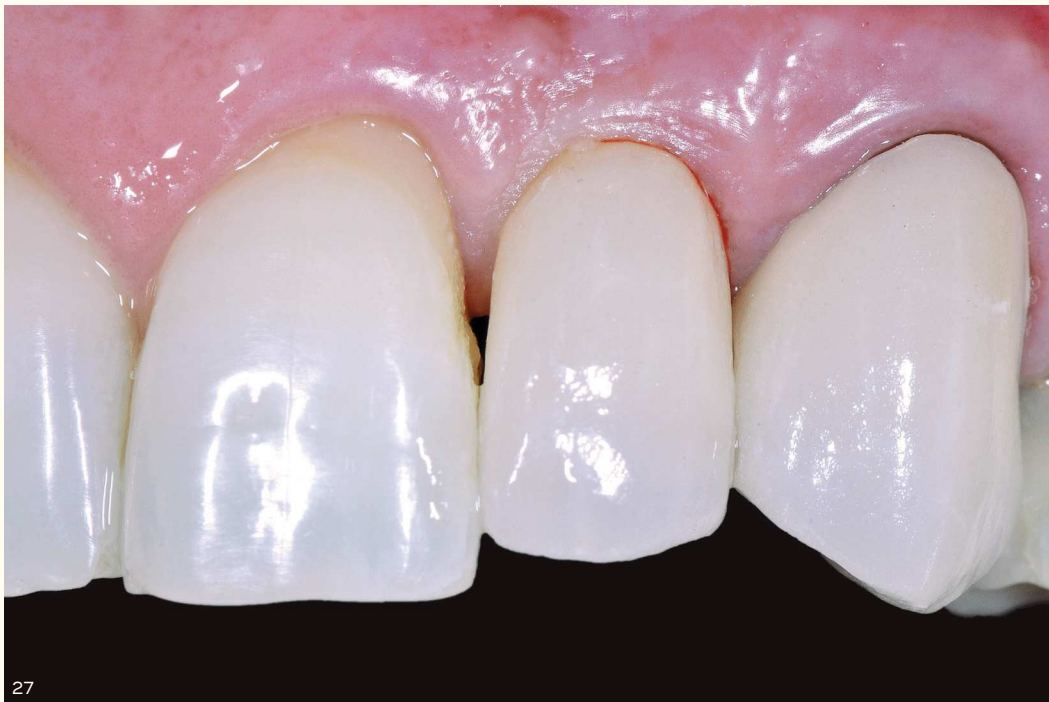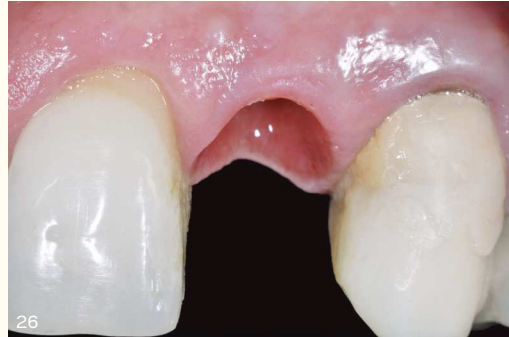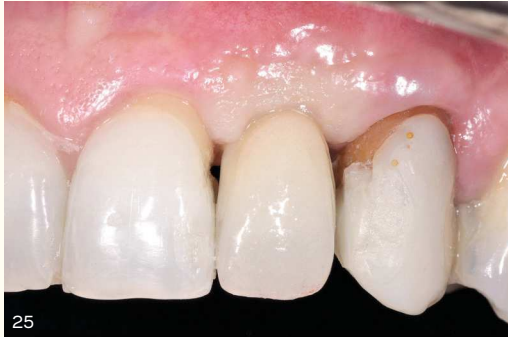**Figures 14 to 27.** Rehabilitation of upper lateral incisor extracted due to root fracture and acute abscess, as shown in Figure 3. Absence of buccal bone plate and need for bone regeneration are common in these cases. Note the importance of correct three-dimensional implant placement and increased contour. Conditioning of soft tissues is performed by means of a provisional prosthesis, extremely important to achieve satisfactory final results.

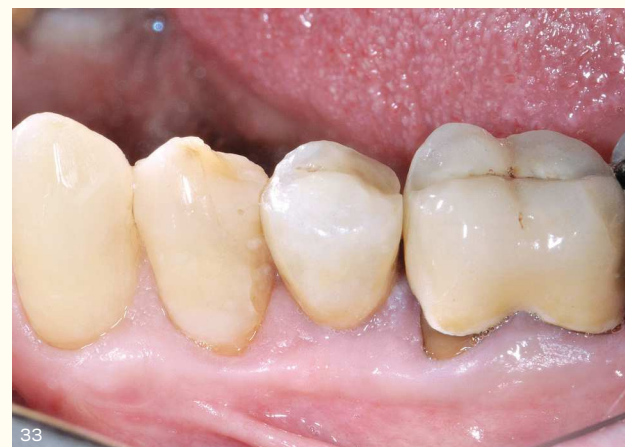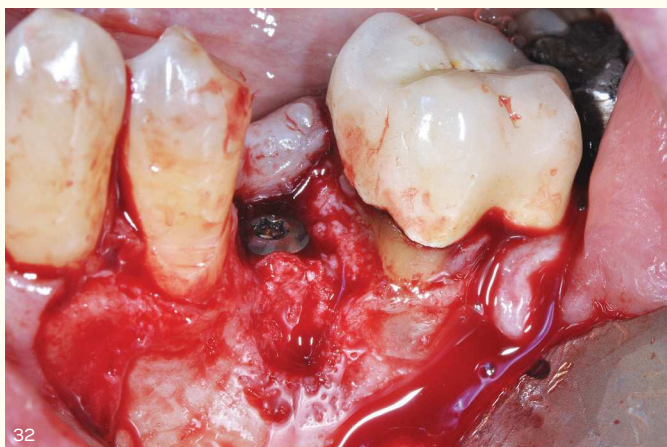
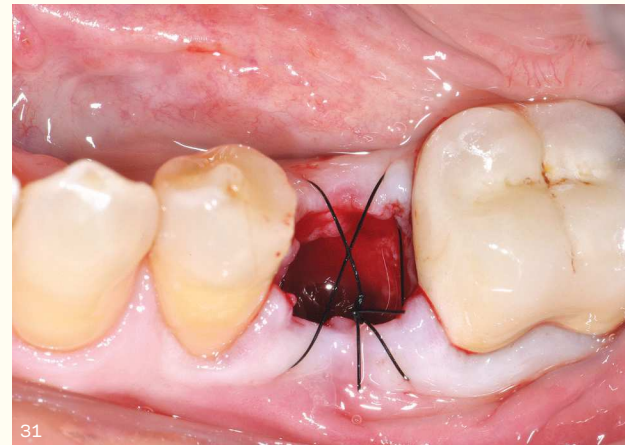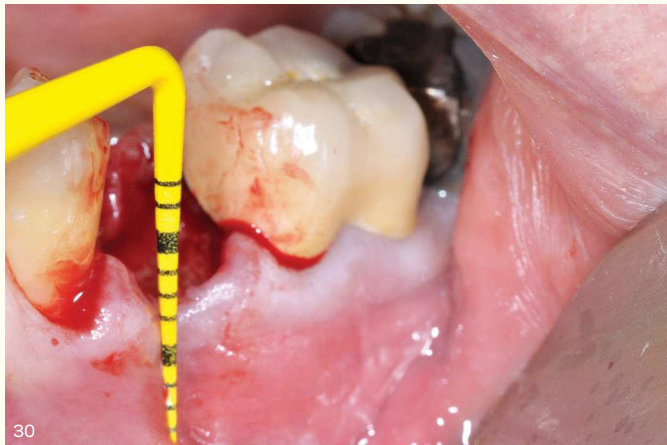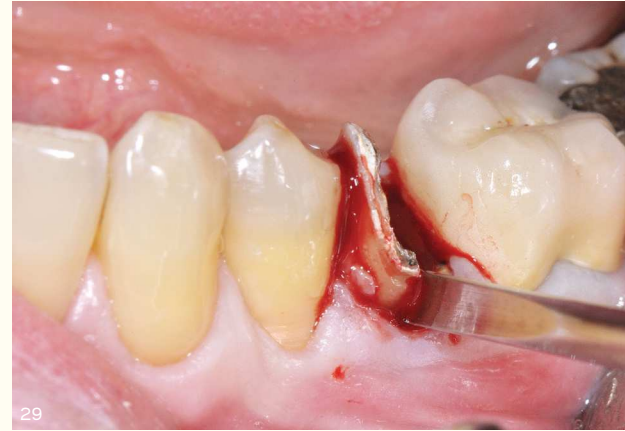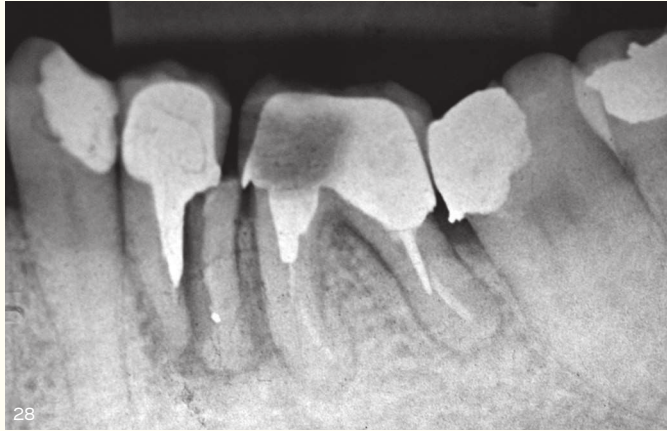




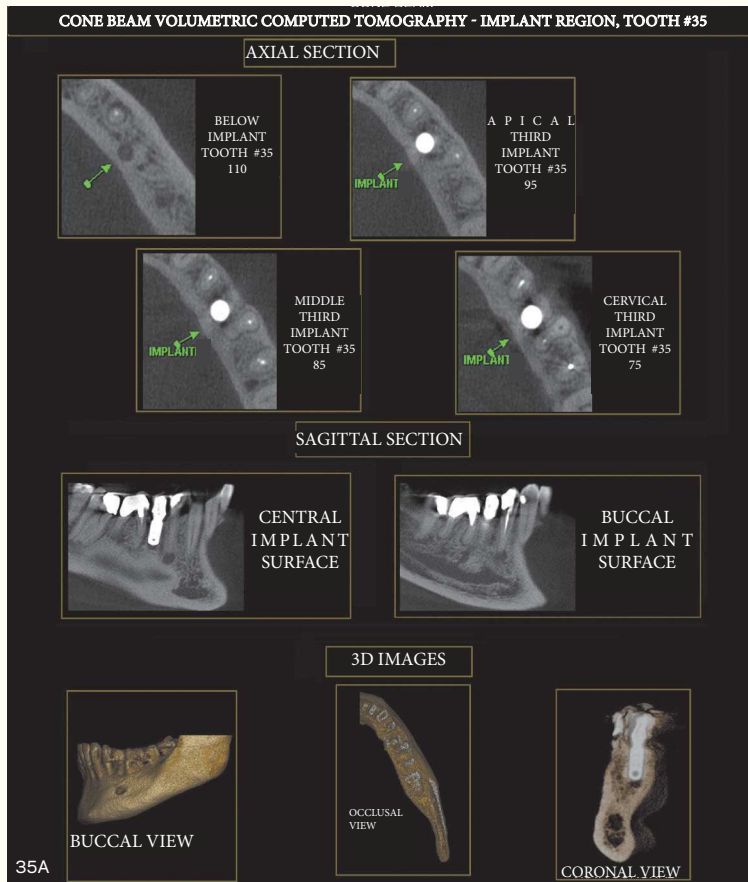




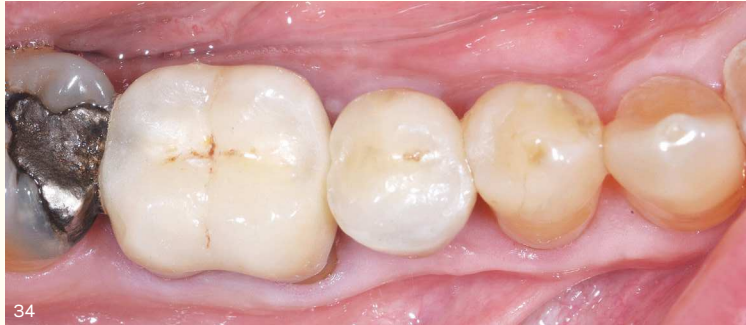

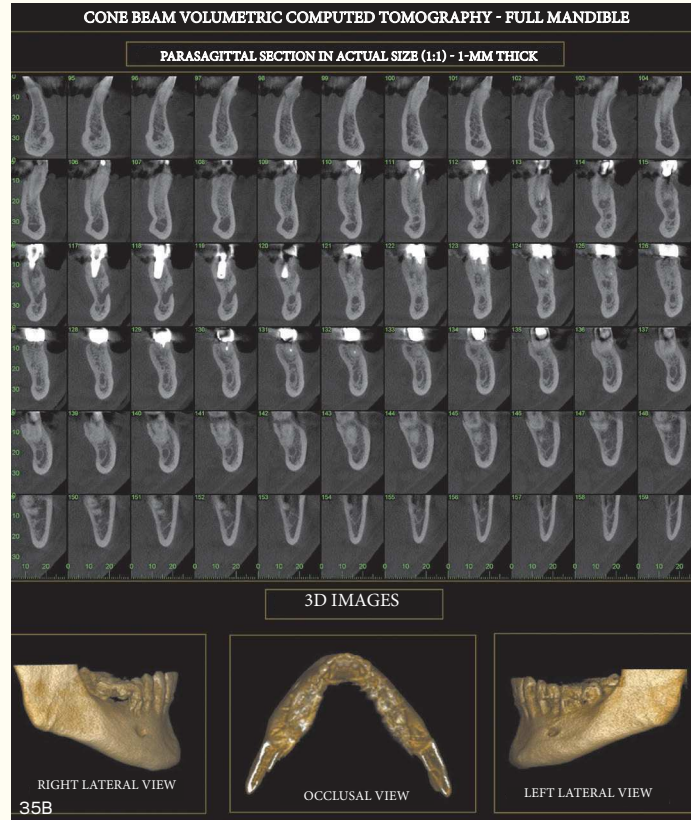


**Figures 28 to 35.** Extraction carried out due to root fracture. The implant (Straumann Bone Level, 4.1 x 12 mm, Switzerland) was installed six weeks after extraction. Early implant placement was followed by GBR. Final rehabilitation was carried out after osseointegration. Note the buccal surface of prosthetic rehabilitation one year later. Note the preservation of buccal volume obtained by means of the GBR technique and revealed by the imaging examination taken after implant placement with concomitant GBR. The examination reveals bone volume on the implant buccal surface where there used to be a bone defect.



For this reason, regeneration procedures have become extremely important to achieve osseointegration. Immediate implant placement does not always yield the best results. As we have already mentioned, early implant placement in

extraction sockets is a predictable procedure with high success rates and low risks of further complications. Therefore, using renowned techniques, evidence-based material and proper professional training are the keys to success.



REFERENCES:

1. Hämmerle CHF, Chen ST, Wilson TG. Consensus statements and recommended clinical procedures regarding the placement of implants in extraction sockets. *Int J Oral Maxillofac Implants.* 2004;19 Suppl:26-8.
2. Kan JYK, Rungcharassaeng K, Morimoto T, Lozada J. Facial gingival tissue stability after connective tissue graft with single immediate tooth replacement in the esthetic zone: Consecutive Case Report. *J Oral Maxillofac Surg.* 2009;67(11 Suppl):40-8.
3. Kan J, Rungcharassaeng K, Lozada JL, Zimmerman G. Facial gingival tissue stability following immediate placement and provisionalization of maxillary anterior single implants: a 2-to 8-year follow-up. *Int J Oral Maxillofac Implants.* 2011;26(1):179-87.
4. Chen ST, Darby IB, Reynolds EC, Clement JG. Immediate implant placement postextraction without flap elevation. *J Periodontol.* 2009;80(1):163-72.
5. Buser D, Chen ST, Weber H-P, Belsler UC. Early implant placement following single-tooth extraction in the esthetic zone: biologic rationale and surgical procedures. *Int J Periodontics Restorative Dent.* 2008;28(5):441-51.
6. Buser D, Halbritter S, Hart C, Bornstein MM, Grütter L, Chappuis V, et al. Early Implant placement with simultaneous guided bone regeneration following single-tooth extraction in the esthetic zone: 12-month results of a prospective study with 20 consecutive patients. *J Periodontol.* 2009;80(1):152-62.
7. Buser D, Janner SFM, Wittneben J-G, Brägger U, Ramseier CA, Salvi GE. 10-year survival and success rates of 511 titanium implants with a sandblasted and acid-etched surface: a retrospective study in 303 partially edentulous patients. *Clin Implant Dent Relat Res.* 2012;14(6):839-51.
8. Buser D, Chen ST, Weber HP, Belsler UC. Early implant placement following single-tooth extraction in the esthetic zone: biologic rationale and surgical procedures. *Int J Periodontics Restorative Dent.* 2008;28(5):441-51.
9. Kan JYK, Rungcharassaeng K, Sclar A, Lozada JL. Effects of the facial osseous defect morphology on gingival dynamics after immediate tooth replacement and guided bone regeneration: 1-Year results. *J Oral Maxillofac Surg.* 2007;65(7 Suppl 1):13-9.
10. Chen ST, Darby IB, Adams GG, Reynolds EC. A prospective clinical study of bone augmentation techniques at immediate implants. *Clin Oral Implants Res.* 2005;16(2):176-84.
11. Chen ST, Buser D. Esthetic outcomes following immediate and early implant placement in the anterior maxilla: a systematic review. *Int J Oral Maxillofac Implants.* 2014;29 Suppl:186-215.