

# Rehabilitation of the maxilla with computer-assisted flapless surgery according to virtual preoperative planning: A case report

**Abstract / Introduction:** Computer-guided surgery combined with CAD/CAM technology is a useful technique for placement of osseointegrated dental implants with utmost accuracy, since it employs virtual planning technology which allows visualization by a computer software of the relationship between one's prosthetic needs and the amount of bone available. **Objective:** The aim of this study was to report a case of maxillary rehabilitation with the use of the Neoguide system (Neodent®, Curitiba, Brazil), with the aid of computer-guided flapless technique and immediate loading. **Methods:** After pre tomographic preparation and virtual planning, eight Titamax EX Morse taper implants (Neodent®, Curitiba, Brazil) were placed using a prototyped surgical guide. After implant placement, panoramic radiographs and CT scans were performed. Subsequently, a fixed implant-supported denture was installed. **Conclusion:** The use of computer-guided flapless surgery with immediate loading proved a valuable resource in maxillary rehabilitation, with reduced surgical time and decreased postoperative symptoms such as pain, swelling and inflammation. **Keywords /** Dental implants. Computer-guided surgery. Fixed implant-supported prosthesis.

**Jean UHLENDORF**

Professor, Latin American Institute of Dental Research and Education.

**Yuri UHLENDORF**

Professor, Latin American Institute of Dental Research and Education.

**Jaques LUIZ**

Professor, Latin American Institute of Dental Research and Education.

**José Antônio BRESSANI**

Professor, Anhanguera University (UNIDERP) and Union of Dentists — Campo Grande and Cuiabá — Brazil.

**Willian de ARAÚJO**

Specialist in Product Management and Engineering, Positivo University.

**How to cite this article:** Uhlendorf J, Uhlendorf Y, Luiz J, Bressani JA, Araújo W. Rehabilitation of the maxilla with computer-assisted flapless surgery according to virtual preoperative planning: A case report. *Dental Press Implantol.* 2014 July-Sept;8(3):66-75. doi: <http://dx.doi.org/10.14436/2237-650X.8.3.066-075.oar>

**Submitted:** November 10, 2013 - **Revised and accepted:** July 04, 2014

**Contact address:** Jean Uhlendorf

Rua Jacarezinho, 656 – CEP: 80710-150 – Curitiba/PR – Brazil – Email: [juhlendorf@yahoo.com.br](mailto:juhlendorf@yahoo.com.br)

» The authors Jean Uhlendorf and Willian de Araújo report having employment relationship with the company Neodent which is mentioned throughout this article.

» Patients displayed in this article previously approved the use of their facial and intraoral photographs.

## INTRODUCTION

The concept of computer-guided surgery emerged as a result of the development of prototyping processes. The technique consists in transferring to a virtual model the images of a patient's bone structure combined with an orientation guide, thus enabling the reproduction of a virtual plan by means of a prototyped surgical guide manufactured on the basis of CAD/CAM technology.<sup>1</sup> The prototyped surgical guide allows flapless implant placement and the application of an immediate loading protocol. The clinical applicability and reliability of this resource has been proven by several studies.<sup>2-6</sup>

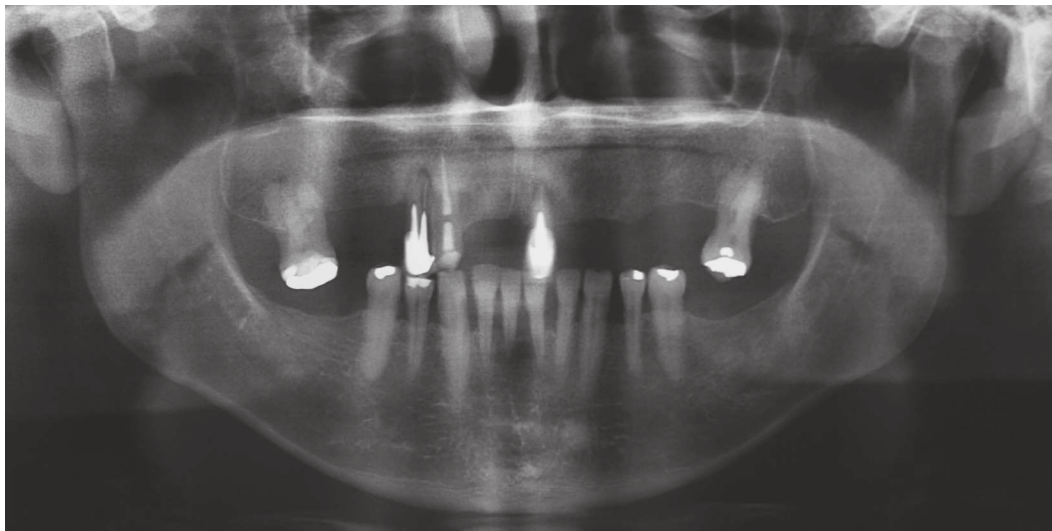
Computer-guided surgery helps professionals to place dental implants with utmost accuracy, since it employs virtual planning technology which allows visualization by a computer software of the relationship between one's prosthetic needs and the amount of bone available. The implant site is

critical to achieve a successful rehabilitation, whereas computer-guided technique results not only in superior accuracy when placing implants with bone anchorage, but also in improved occlusal emergence, thereby allowing implants to be inserted in a predictable, reliable manner.<sup>7-11</sup>

This article reports a clinical case in which computer-guided flapless technique with immediate loading was employed to rehabilitate an edentulous maxilla.

## CLINICAL CASE REPORT

A 49-year-old, male patient presented at the clinic of the Latin American Institute of Dental Research and Education (ILAPEO) for evaluation. Clinical examination revealed he presented with various upper teeth missing, a number of teeth indicated for extraction, and wore a partial removable denture. The latter was his chief complaint. Panoramic radiograph (Fig 1) and laboratory tests were requested.



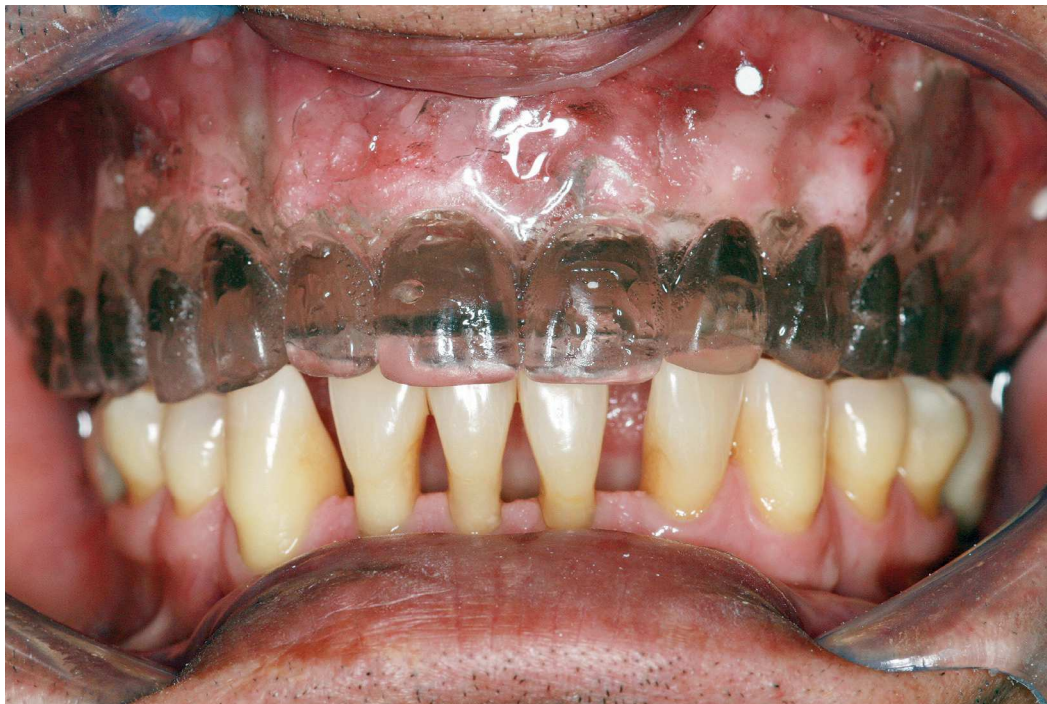**Figure 1.** Initial panoramic radiograph.

The first phase of treatment consisted in extracting the remaining upper teeth and fabricating a temporary complete denture. After healing, the preparation necessary before CT scanning was performed. It consisted of a diagnostic wax up of the maxilla made to establish the vertical dimension and determine esthetic and functional parameters. The wax up was duplicated with colorless acrylic resin so as to obtain a CT guide (Fig 2). In this guide, five well distributed and asymmetric gutta-percha markings were made. The tomographic guide was tested and adjusted, an interocclusal relief was fabricated and the patient was referred to CT scanning.

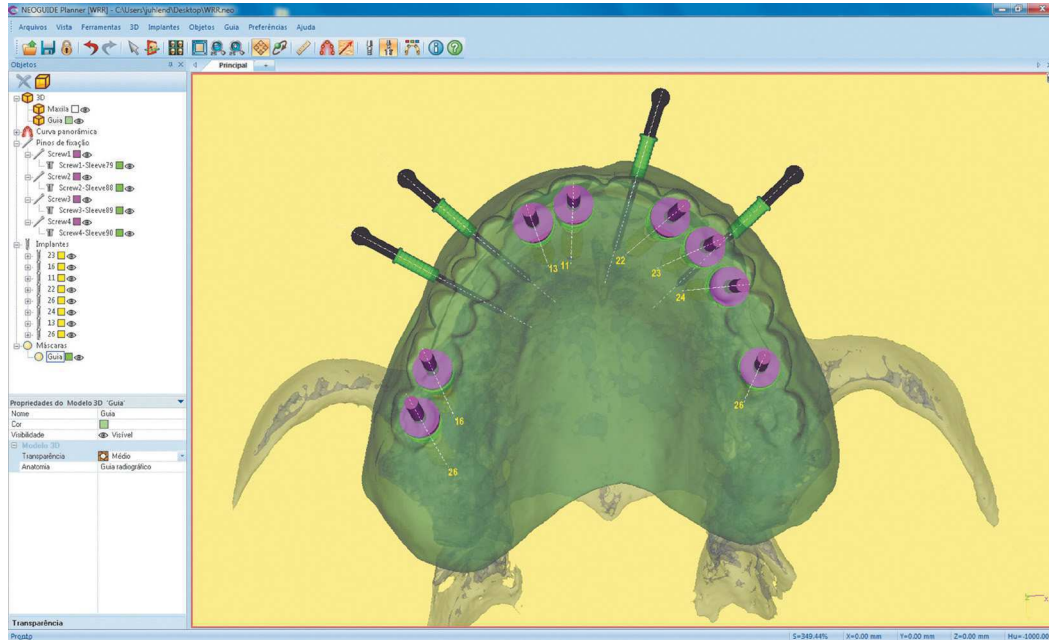
Image acquisition was based on the double scanning technique: A CT scan was performed with the guide and the interocclusal

record in place, and then a new CT scan with just the tomographic guide was taken. To this end, an i-Cat (Imaging Sciences, Hatfield, USA) Cone Beam Computed Tomography (CBCT) scanner was used. The images obtained with CBCT in DICOM format were converted with Neoguide Builder software (Neodent®, Curitiba, Brazil).

Neoguide Planner software (Neodent®, Curitiba, Brazil) was used to perform a virtual planning of implants and prosthetic components (Fig 3), so as to allow bone anchorage of implants and the emergence of the prosthetic screws to be distributed in an optimal manner for the case. Based on this planning, a prototyped surgical guide was fabricated (Neodent®, Curitiba, Brazil) with a view to transferring the virtual planning to the surgical procedure.



**Figure 2.** Tomographic guide with gutta-percha markings.



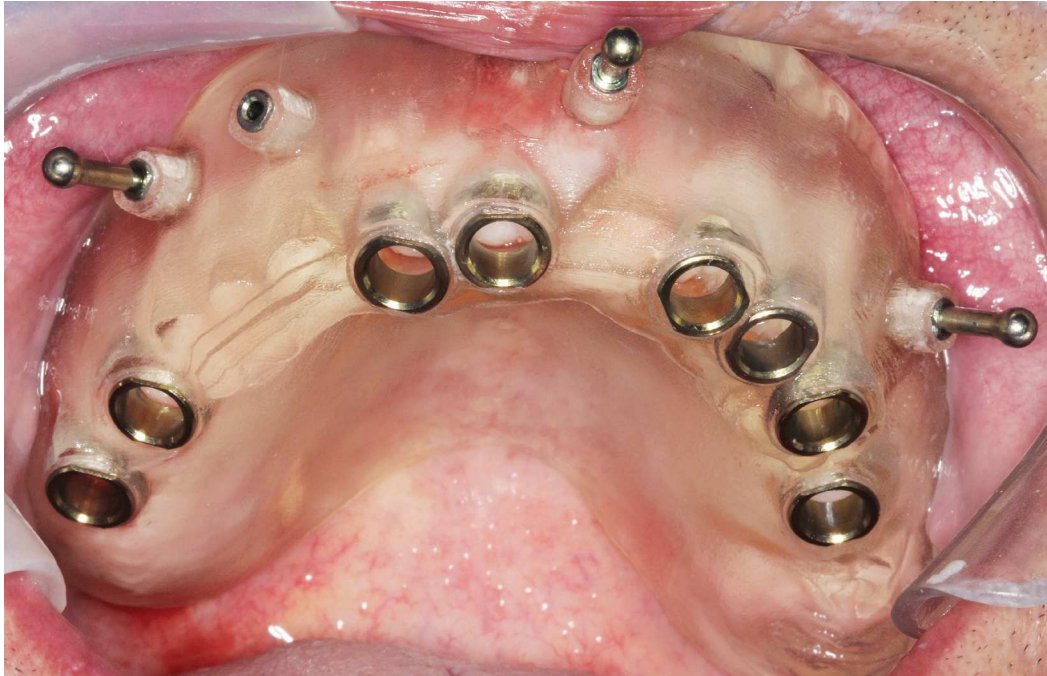
**Figure 3.** Virtual planning using the Neoguide Planner software.

The surgical guide was disinfected through immersion in 0.12% chlorhexidine digluconate. Anesthesia was applied with a solution based on 2% mepivacaine hydrochloride with epinephrine 1:100,000 (DFL®, Rio de Janeiro, Brazil). Application was performed slowly and gradually so as to avoid swelling in the region, which could have made it difficult to place the surgical guide. The guide was stabilized with the use of a self-drilling graft screw in the center of the palate along with three fixing pins (Fig 4).

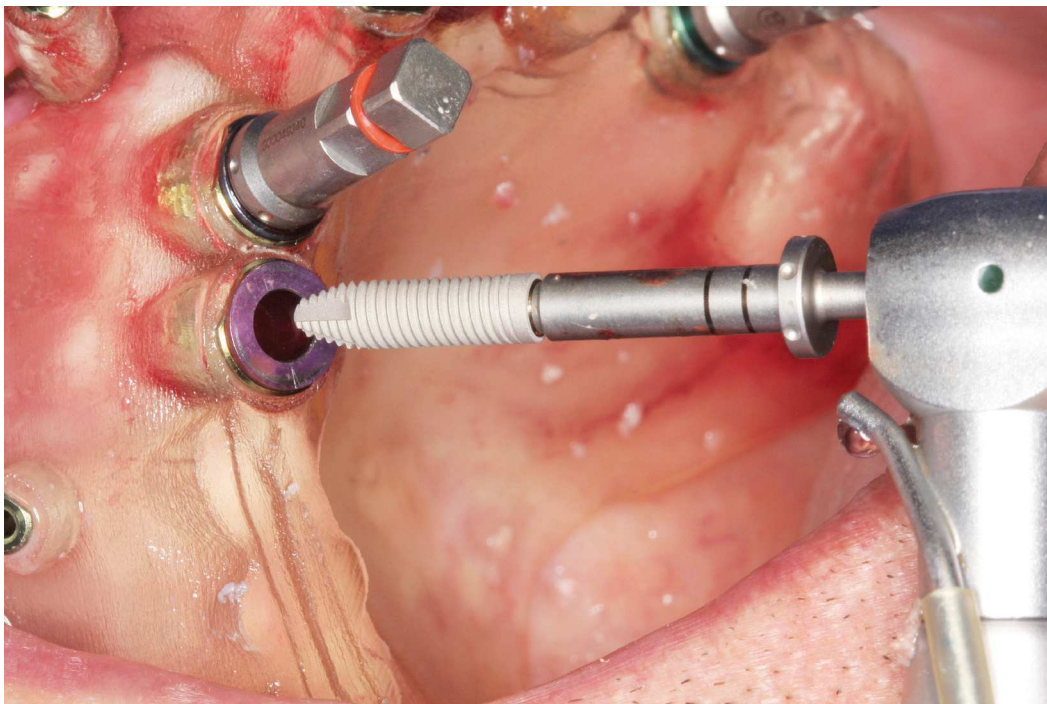
With the use of the Neoguide surgical kit (Neodent®, Curitiba, Brazil), surgical instrumentation followed the progressive sequence of drills. The in and out movements of the drills was performed frequently with constant and copious irrigation. Eight Titamax EX Morse taper implants

(Neodent®, Curitiba, Brazil) (Fig 5) were installed. Installation was finished with a torque wrench (Fig 6). Installation torque was above 32 N/cm<sup>2</sup> for all implants, which allowed the use of immediate loading. After flapless implant placement (Fig 7), the surgical guide was removed and mini-pillar-type intermediaries (Neodent®, Curitiba, PR, Brazil) were installed. Immediately thereafter, postoperative panoramic radiographs (Fig 8) were taken.

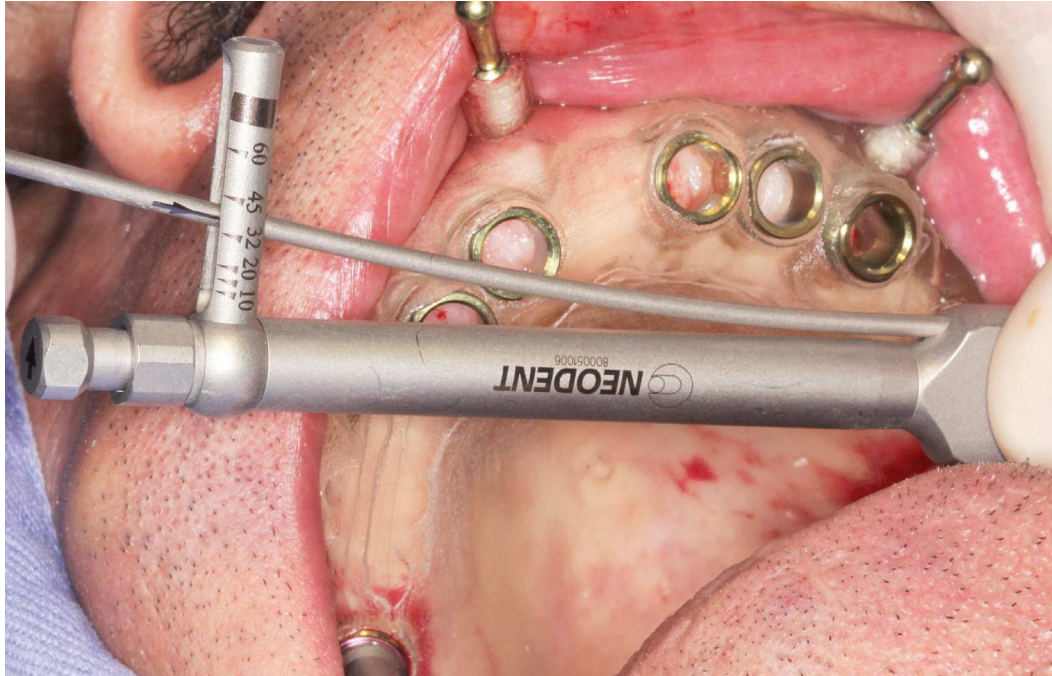
A transfer impression was performed with the aid of the CT guide, and a definitive hybrid fixed prosthesis was fabricated and installed (Fig 9) by following the protocol of immediate loading with the technique of passive cementation,<sup>12</sup> thus immediately restoring patient's aesthetics and function (Fig 10).



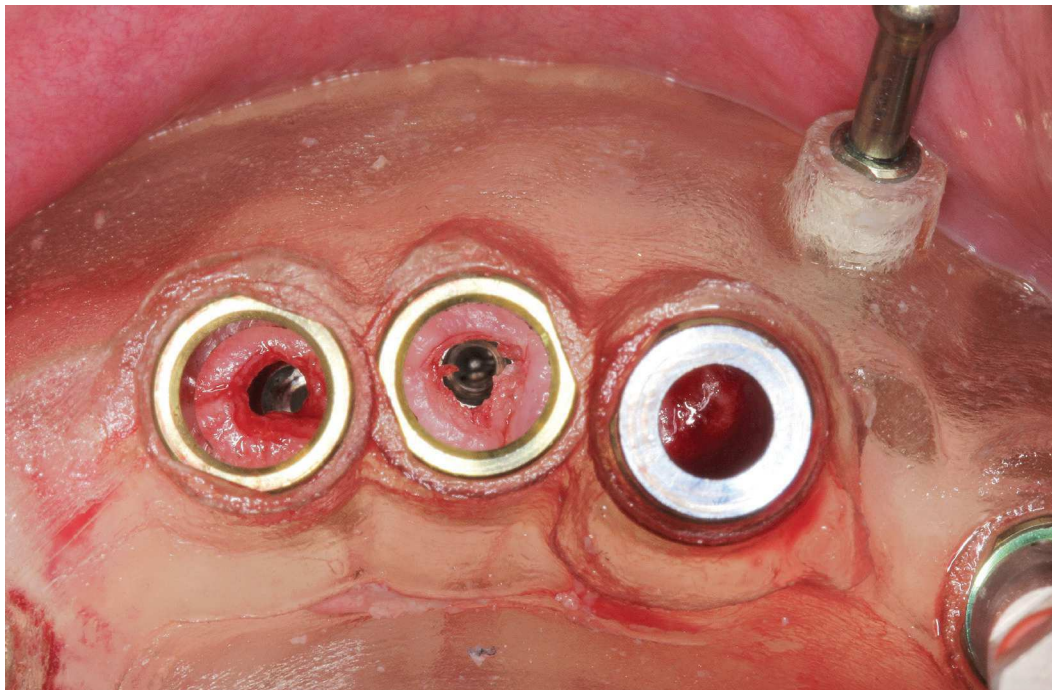
**Figure 4.** Fixing the prototyped surgical guide.



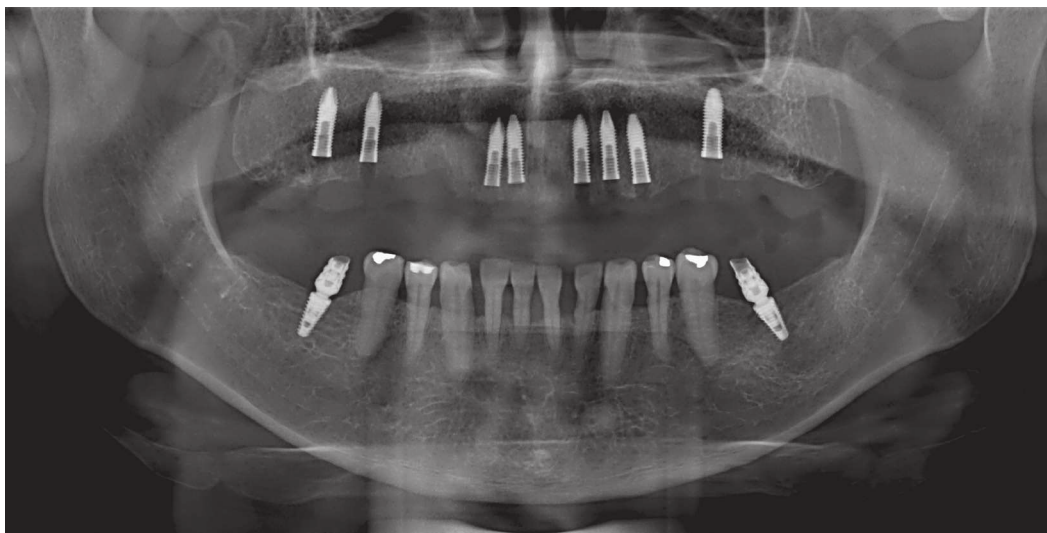
**Figure 5.** Flapless implant placement with the surgical guide.



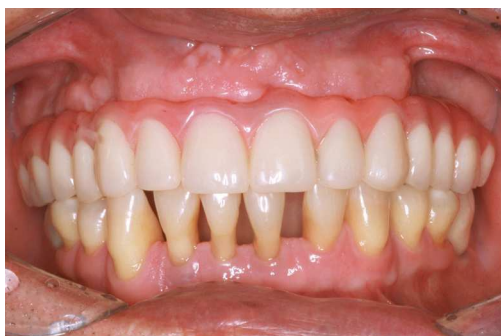**Figure 6.** Finishing implant installation with a torque wrench.



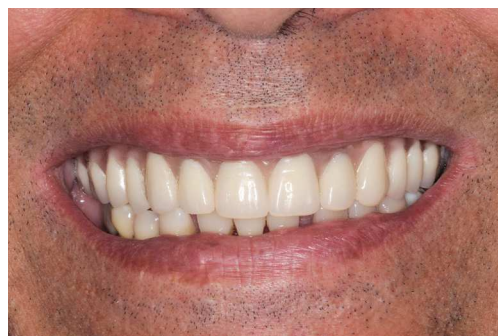**Figure 7.** Flapless implant placement.



**Figure 8.** Postoperative panoramic radiograph.



**Figure 9.** Prosthesis in place, intraoral view.



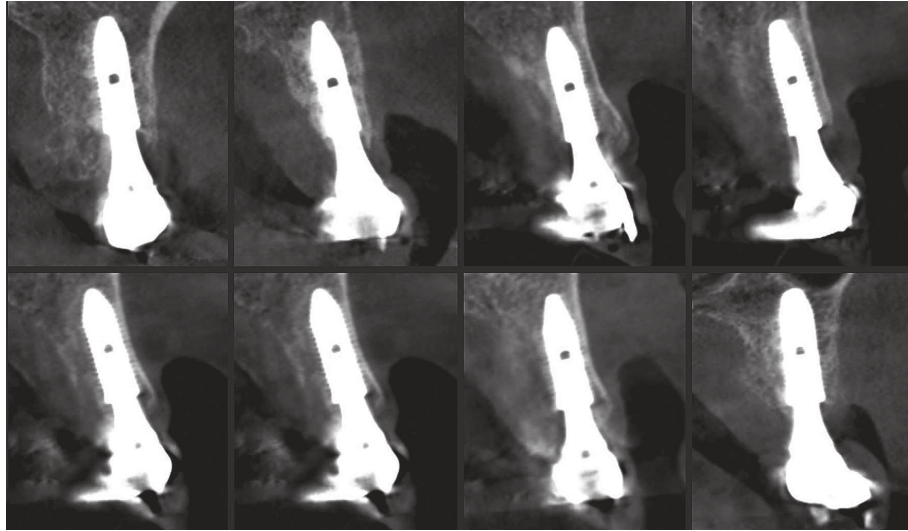
**Figure 10.** Prosthesis in place, patient smiling.

Postoperative control was carried out by means of clinical and radiographic examination, including a CT scan (Fig 11) and a panoramic radiograph (Fig 12). The prosthesis was removed and each implant was tested individually. All implants were successful and showed no irreversible or persistent signs and symptoms such as pain, infection,

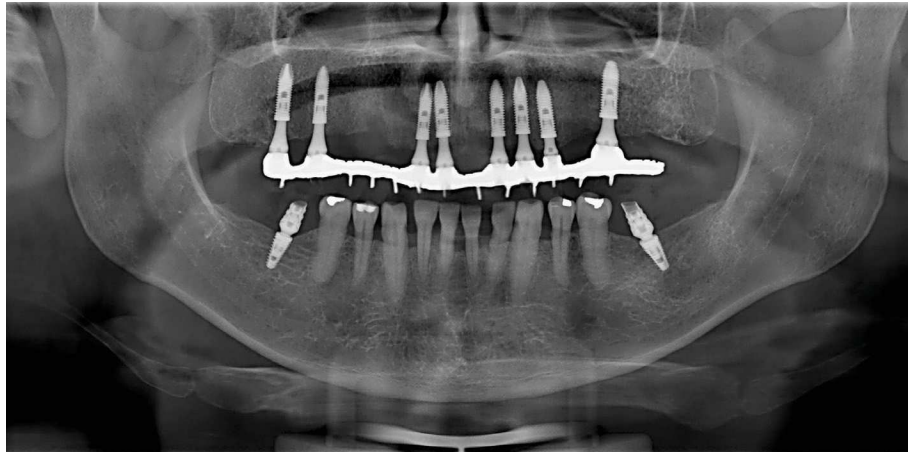
neuropathy, paresthesia or mobility. Moreover, there was no evidence of peri-implant radiolucency on the radiographs.

## DISCUSSION

CAD/CAM technology has been increasingly used to address many issues in Implantology. The possibility of conducting virtual



**Figure 11.** Postoperative CT images.



**Figure 12.** Final panoramic radiograph.

planning and fabricating a prototyped surgical guide results in increasingly safe and accurate diagnosis and treatment planning. This technique streamlines the surgical procedure, thereby enabling the use of virtual planning for placing osseointegrated implants.<sup>7-9</sup>

With regard to the number of implants required for maxillary implant-supported

rehabilitation, studies<sup>13-16</sup> suggest that four to six implants are enough to attain long-term success. However, when bone is abundant, a greater number of implants can result in a better distribution of forces acting on the rehabilitation,<sup>17</sup> thus avoiding the need for a distal cantilever. The location of implants should also favor occlusal balance,



creating a favorable support polygon, thereby minimizing possible biomechanical risks and prosthetic complications.<sup>17-19</sup> For these reasons, the authors chose to install eight implants so as to ensure good distribution in view of patient's prosthetic needs.

The insertion torque measured at the time of implant placement was found to be between 32 and 45 N/cm<sup>2</sup>. These are the benchmarks found in the literature,<sup>13-16</sup> and are seen as a decisive parameter for applying the technique of immediate loading. These values made immediate loading possible in the case reported herein, thereby bringing to the patient the added benefit of not having to wait for osseointegration to occur.

In the present case, the technique of guided surgery offered important advantages: reduced surgical time; decreased postoperative symptoms, such as pain, swelling and inflammation; and, as a result, faster recovery. When properly indicated and applied, this technique offers reduced patient morbidity, greater surgical precision, increased patient's comfort and safety for the professional. Moreover, it minimizes surgical errors and potential damage to anatomical structures.<sup>1-6,9-11,13-16</sup>

As it is the case with all techniques, there are indications and contraindications to be considered before choosing the computer-guided technique. There must be an adequate amount of bone, good mouth opening, as well as sufficient keratinized tissue, as computer-guided surgery limits the possibility of manipulating soft tissues.<sup>20-22</sup>

According to studies<sup>23-26</sup> comparing virtual planning and implants placed by means

of computer-guided surgery, there is no guarantee of absolute precision. Based on a literature review, D'Haese et al<sup>26</sup> concluded that angular variations may vary from 0.9 to 4.5 degrees. Impaired visibility during instrumentation and installation, and limited tactile control during surgery should also be considered. The various preoperative impression phases, the fabrication of the tomographic guide, CT scanning and fixation of the surgical guide should be carefully performed, given that minor errors might add up during these steps and result in significant deviations.<sup>27</sup> These factors underscore the impossibility of clinically applying the technique in cases of severe atrophy, high complexity and borderline cases, in which bone quantity is insufficient. A margin of safety should be adopted to avoid potential risks, such as: implant failure, fenestration and damage to important anatomical structures.<sup>23-30</sup>

It is essential to understand the indications and limitations of the technique, as well as follow the steps of pre-CT preparation in a judicious manner so as to achieve favorable and successful implant placement while reproducing the preoperative virtual planning.

## CONCLUSION

The use of immediate loading associated with the computer-guided flapless technique proved a valuable resource in maxillary rehabilitation. There was a reduction in surgical time and a decrease in postoperative symptoms, such as pain, swelling and inflammation. Moreover, the patient was completely satisfied with the success of treatment.

## REFERENCES:

1. Van Steenberghe D, Glauser R, Blombäck U, Andersson M, Schutyser F, Pettersson A, et al. A computed tomographic scan-derived customized surgical template and fixed prosthesis for flapless surgery and immediate loading of implants in fully edentulous maxillae: a prospective multicenter study. *Clin Implant Dent Relat Res.* 2005;7 Suppl 1:S111-20.
2. Maló P, Nobre M, Lopes A. The use of computer-guided flapless implant surgery and four implants placed in immediate function to support a fixed denture: preliminary results after a mean follow-up period of thirteen months. *J Prosthet Dent.* 2007;97(6 Suppl):S26-34.
3. Merli M, Bernardelli F, Esposito M. Computer-guided flapless placement of immediately loaded dental implants in the edentulous maxilla: a pilot prospective case series. *Eur J Oral Implantol.* 2008;1(1):61-9.
4. Johansson B, Friberg B, Nilson H. Digitally planned, immediately loaded dental implants with prefabricated prostheses in the reconstruction of edentulous maxillae: a 1-year prospective, multicenter study. *Clin Implant Dent Relat Res.* 2009;11(3):194-200.
5. Pomares C. A retrospective study of edentulous patients rehabilitated according to the 'all-on-four' or the 'all-on-six' immediate function concept using flapless computer-guided implant surgery. *Eur J Oral Implantol.* 2010;3(2):155-63.
6. Meloni SM, De Riu G, Pisano M, Massarelli O, Tullio A. Computer assisted dental rehabilitation in free flaps reconstructed jaws: one year follow-up of a prospective clinical study. *Br J Oral Maxillofac Surg.* 2012;50(8):726-3.
7. Kopp KC, Koslow AH, Abdo OS. Predictable implant placement with a diagnostic/surgical template and advanced radiographic imaging. *J Prosthet Dent.* 2003;89(6):611-5.
8. Parel SM, Triplett RG. Interactive imaging for implant planning, placement, and prosthesis construction. *J Oral Maxillofac Surg.* 2004;62(9 Suppl 2):41-7.
9. Marchack CB. An immediately loaded CAD/CAM-guided definitive prosthesis: a clinical report. *J Prosthet Dent.* 2005;93(1):8-12.
10. Sanna AM, Molly L, Van Steenberghe D. Immediately loaded CAD-CAM manufactured fixed complete dentures using flapless implant placement procedures: a cohort study of consecutive patients. *J Prosthet Dent.* 2007;97(6):331-9.
11. Marra R, Acocella A, Rispoli A, Sacco R, Ganz SD, Blasi A. Full-mouth rehabilitation with immediate loading of implants inserted with computer-guided flap-less surgery: a 3-year multicenter clinical evaluation with oral health impact profile. *Implant Dent.* 2013;22(5):444-52.
12. Borges AF, Dias Pereira LA, Thomé G, Melo AC, de Mattias Sartori IAM. Prostheses removal for suture removal after immediate load: success of implants. *Clin Implant Dent Relat Res.* 2010;12(3):244-8.
13. Mertens C, Steveling HG, Stucke K, Pretzl B, Meyer-Bäumer A. Fixed implant-retained rehabilitation of the edentulous maxilla: 11-year results of a prospective study. *Clin Implant Dent Relat Res.* 2012;14(6):816-27.
14. Li W, Chow J, Hui E, Lee PK, Chow R. Retrospective study on immediate functional loading of edentulous maxillas and mandibles with 690 implants, up to 71 months of follow-up. *J Oral Maxillofac Surg.* 2009;67(12):2653-62.
15. Maló P, Nobre M, Lopes A. The rehabilitation of completely edentulous maxillae with different degrees of resorption with four or more immediately loaded implants: a 5-year retrospective study and a new classification. *Eur J Oral Implantol.* 2011;4(3):227-43.
16. Crespi R, Vinci R, Capparé P, Romanos GE, Gherlone E. A clinical study of edentulous patients rehabilitated according to the "all on four" immediate function protocol. *Int J Oral Maxillofac Implants.* 2012;27(2):428-34.
17. Çağlar A, Aydın C, Ozen J, Yilmaz C, Korkmaz T. Effects of mesiodistal inclination of implants on stress distribution in implant-supported fixed prostheses. *Int J Oral Maxillofac Implants.* 2006;21(1):36-44.
18. Bellini CM, Romeo D, Galbusera F, Agliardi E, Pietrabissa R, Zampelis A, et al. A finite element analysis of tilted versus nontilted implant configurations in the edentulous maxilla. *Int J Prosthodont.* 2009;22(2):155-7.
19. Duyck J, Van Oosterwyck H, Vander Sloten J, De Cooman M, Puers R, Naert I. Magnitude and distribution of occlusal forces on oral implants supporting fixed prostheses: an in vivo study. *Clin Oral Implants Res.* 2000;11(5):465-75.
20. Sohmura T, Kusumoto N, Otani T, Yamada S, Wakabayashi K, Yatani H. CAD/CAM fabrication and clinical application of surgical template and bone model in oral implant surgery. *Clin Oral Implants Res.* 2009;20(1):87-93.
21. Yong LT, Moy PK. Complications of computer-aided-design/computer-aided-machining-guided (NobelGuide) surgical implant placement: an evaluation of early clinical results. *Clin Implant Dent Relat Res.* 2008;10(3):123-7.
22. Komiyaama A, Klinge B, Hultin M. Treatment outcome of immediately loaded implants installed in edentulous jaws following computer-assisted virtual treatment planning and flapless surgery. *Clin Oral Implants Res.* 2008;19(7):677-85.
23. Van Assche N, van Steenberghe D, Guerrero ME, Hirsch E, Schutyser F, Quirynen M, et al. Accuracy of implant placement based on pre-surgical planning of three-dimensional cone-beam images: a pilot study. *J Clin Periodontol.* 2007;34(9):816-21.
24. Horwitz J, Zuabi O, Machtei EE. Accuracy of a computerized tomography-guided template assisted implant placement system: an in vitro study. *Clin Oral Implants Res.* 2009;20(10):1156-62.
25. Valente F, Schirolli G, Sbrenna A. Accuracy of computer-aided oral implant surgery: a clinical and radiographic study. *Int J Oral Maxillofac Implants.* 2009;24(2):234-42.
26. D'haese J, Van De Velde T, Komiyaama A, Hultin M, De Bruyn H. Accuracy and complications using computer-designed stereolithographic surgical guides for oral rehabilitation by means of dental implants: a review of the literature. *Clin Implant Dent Relat Res.* 2012;14(3):321-35.
27. Komiyaama A, Pettersson A, Hultin M, Näsström K, Klinge B. Virtually planned and template-guided implant surgery: an experimental model matching approach. *Clin Oral Implants Res.* 2011;22(3):308-13.
28. Di Giacomo GA, Cury PR, Araujo NS, Sendyk WR, Sendyk CL. Clinical application of stereolithographic surgical guides for implant placement: preliminary results. *J Periodontol.* 2005;76(4):503-7.
29. Arisan V, Karabuda ZC, Ozdemir T. Accuracy of two stereolithographic guide systems for computer-aided implant placement: a computed tomography-based clinical comparative study. *J Periodontol.* 2010;81(1):43-51.
30. Verhamme LM, Meijer GJ, Boumans T, Schutyser F, Bergé SJ, Maal TJ. A clinically relevant validation method for implant placement after virtual planning. *Clin Oral Implants Res.* 2013;24(11):1265-72.