Assessment of radiographic methods used in the vertical location of sites selected for mini-implant insertion

Liz Matzenbacher*, Paulo Sérgio Flores Campos**, Nilson Pena***, Telma Martins de Araújo****

Abstract

Objective: Evaluate the effectiveness of image diagnostic systems used in the vertical location of sites selected for mini-implant insertion. **Methodology:** The subjects comprised four patients in whose posterior regions 32 interradicular sites were located for mini-implants insertion. These sites were represented by orifices filled with gutta-percha on acetate dental trays (PCg - contact point of dental crowns on the acetate dental trays; PIg – mini-implant insertion point on the acetate dental tray). Periapical and interproximal radiographs were taken and cone beam computed tomography images of the dental trays placed in the mouth were acquired. The following points were considered: PC – radiodense image of point PCg; PI – radiodense image of point Pig; PCx – contact points between the dental crowns, which were determined on the radiograph. The following vertical measurements were used: Gold standard – from PCg to PIg; measurement 1 – from PC to PI; and measurement 2 – from PCx to PI. The measurements were compared by means of a descriptive analysis and Student's t-test. **Results:** As regards measurement 1, a statistically significant difference was noted for the gold standard in 4.1%, 25% and 100% of the measurements assessed with cone beam computed tomography images, interproximal and periapical radiographs, respectively. Regarding measurement 2, a statistically significant difference was noted for the gold standard in 4.1%, 56.2% and 100% of the measurements assessed with computed tomography images, interproximal and periapical radiographs, respectively. **Conclusions:** Cone beam computed tomography yielded the most accurate vertical position assessment of the sites selected for mini-implant insertion; interproximal radiographs can be used, although certain limitations apply; pericapical radiographs yielded less than satisfactory results and are therefore contraindicated for this particular purpose.

Keywords: Image diagnosis, Dental radiograph, X-Ray, Computed Tomography, Orthodontic anchorage procedures.

* A student specializing in Orthodontics and Facial Orthopedics at the Dental College of the Bahia State Federal University – FO.UFBA.
** Associate Professor of Radiology at the Bahia State Federal University.
*** Doctor in Radiology from the Piracicaba School of Dentistry (UNICAMP – Campinas State University). Researcher for The Bahia State Research Support Foundation (FAPESB).
**** Holds a Master's degree and a Doctorate Degree in Orthodontics from the Rio de Janeiro Federal University (UFRJ). Full Professor of Orthodontics at the Bahia State Federal University (FO.UFRJ). Coordinator of the Orthodontics Specialist Course at the School of Dentistry of the Bahia State Federal University (FO.UFBA). Director of the Brazilian Board of Orthodontics and Facial Orthopedics.

INTRODUCTION

Mini-implants require a simple and swift surgical intervention[5,12]. A safe insertion, however, entails careful clinical and radiographic assessment, proper planning and a reliable implantation protocol with a special focus on the region's anatomy to ensure no lesions are made to noble structures[2,3].

Mini-implants can be installed in anatomical regions with minimum bone quantity. Interradicular space is often the site of choice. Should interproximal bone quantity and root proximity be poorly assessed, there is increased risk of radicular perforation[7,17-23,26,28]. Studies have shown that a slight contact between the device and the periodontal ligament or cementum, without impairment to the vascular-nervous bundle or invasion of the root canal, will not affect tooth vitality. All measures should be undertaken, however, to stave off this kind of incident in order to avoid patient discomfort and potential clinical and/or legal implications[2,21].

Additionally, the major factor in determining the failure of these devices lies in overlooking the proximity between the mini-implant and the tooth root. Lamina dura proximity, for instance, can compromise mini-implant stability[16]. Whenever interradicular space is scant, smaller diameter mini-implants should be preferred, although a minimum diameter of 1.4 mm is recommended since smaller diameters tend to fracture during installation or removal[1].

It is advocated that an accurate identification of the selected site can be made by means of surgical guides[3,13,15,20,28]. Nevertheless, it is common knowledge that two-dimensional images obtained from intraoral radiographs do not necessarily reflect the precise relationship between space and adjacent anatomical structures given the fact that different planes can produce slant or garbled images[6,19]. Kim et al.[13] and Kitai et al.[14] have favored the use of computed tomography for viewing surgical guides. Although computed tomography can show tridimensional images, however, not only is it relatively costlier, but it also exposes patients to a higher radiation dose compared with intraoral radiography.

The evolvement of mini-implants should not be circumscribed only to their different types, shapes and surgical techniques, but should also be geared to the development of imaging diagnostic systems[8,11]. Thus, a study aimed at probing the degree of accuracy made available by radiographic exams is fully justified. Such knowledge would certainly ensure that a safe and reliable method is utilized in planning mini-implant insertion.

Therefore, knowing ahead of time that the proper selection of mini-implant insertion sites is of utmost importance for surgical procedure success, and further acknowledging the fact that interradicular space is often scarce, concern with the radiographic technique best suited to inform the aforementioned insertion sites can prove a useful addition to the literature.

MATERIALS AND METHODS

Four 25-to-28-year-old female subjects were selected, all of whom were patients at the Prof. Édimo Soares Martins Center for Orthodontics and Facial Orthopedics, located at the School of Dentistry of the Bahia Federal University. The choice was based on the following criteria: Complete permanent dentition down to the first molars; absence of posterior crowding and the need for computed tomography in planning mini-implant installation for anchorage.

To obtain the radiographs and tomographic images, the patients used acetate dental trays where the selected mini-implant insertion sites were represented by gutta-percha filled orifices. To this end, plaster models of each patient's dental arch were cast and subsequently plastic trays were produced with a Plastvac P7 vacuum forming machine (Bio-art, São Carlos/SP, Brazil), using 1 mm thick acetate plates (Whiteness – FGM, Joinville/SC, Brazil).

In all, thirty-two sites were selected for mini-implant installation in the interradicular spaces between second bicuspids and first molars of all hemiarches. Insertion points were determined clinically by intersecting an imaginary vertical line through the contact point and across the transitional zone between the keratinized mucous membrane and the free mucous membrane. The distances between contact points and insertion points were gauged clinically with the aid of a calibrated probe and subsequently transferred to the acetate trays (Fig. 1A,C). In order to place the marking media, 1 mm diameter orifices were bored into the dental trays, using a no. 2200 diamond (Fig. 1B, D), and filled with gutta-percha.

The patients were subjected to three different image diagnostic techniques: Interproximal and periapical radiographs of maxillary and mandibular posterior regions and cone beam computed tomography. The exams were performed (A B) using acetate dental trays placed in the patient's mouth Fig. 2).

Acquisition of interproximal and periapical radiographs

These radiographs were acquired using Insight Kodak film (Rochester, New York, USA). The periapical bisecting angle technique was adopted with a Prisma brand support (Prisma Produtos Clínicos Ltda, Brasilia/DF, Brazil); and a Heliodent Vario (Sirona – The Dental Company, Bensheim, Germany) unit was used with the tube adjusted for 70KVp, 7mA current operation and 0.4 second exposure time; distances of 27 cm and 30 cm were maintained for the focal area and the film for the interproximal and periapical radiographs, respectively. The automatic film processing was utilized with a Periomat Plus processor (Dürr Dental, Bietigheim-Bissingen, Germany) set for 5-minute intervals, from dry to dry.

Two interproximal radiographs and four periapical radiographs of each patient were acquired for the posterior region (upper and lower, right and left hand sides).

Acquisition of computed tomography images

Cone beam computed tomography images were acquired using an i-CAT Cone Beam 3-D Dental Imaging System (Imaging Sciences International, Hatfield, PA, USA), whose tube was adjusted to operate at 120KVp and 46.72 mA. A two-arch acquisition protocol was adopted

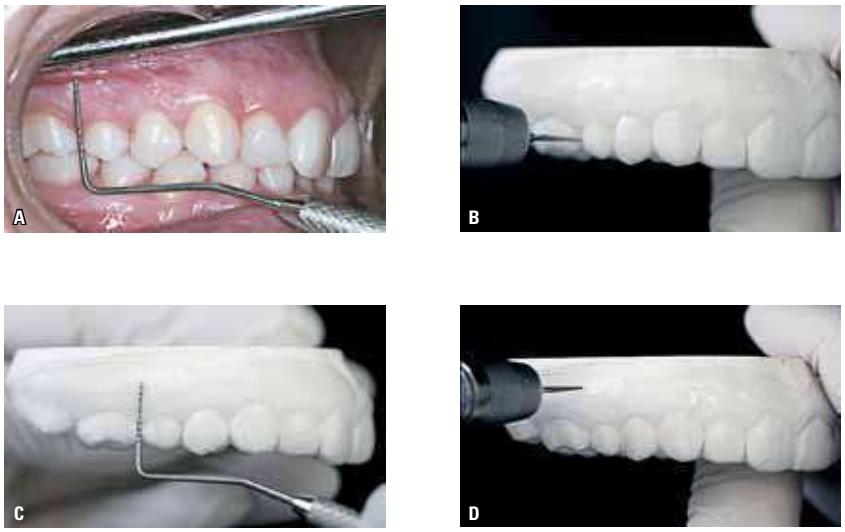

FIGURE 1 - **A)** Site selection for mini-implant installation within the limits of the free and keratinized mucous membranes. **B)** Contact point perforation (bur no. 2200). **C)** Transfer from the site of choice to the acetate tray. **D)** Insertion point perforation (bur no. 2200).

FIGURE 2 - Acetate dental trays placed in patient's mouth showing the selected points filled with gutta-percha: contact point between dental crowns and the site selected for mini-implant insertion.

with an 8 cm FOV and 0.2 mm voxel (2 arc, 8 cm, 40 sec, 0.2 voxel, max. res.). Image acquisition, reconstruction and assessment were all carried out with the aid of the XoranCat version 3.0.34 software (Xoran Technologies, Ann Arbor, Michigan) by a radiology specialist experienced in cone beam computed tomography.

Points and measurements

Five different points and measurements were used for assessment, namely PCg - contact point of the dental crown on the acetate dental tray, filled with gutta-percha (Fig. 3A); PIg – mini-implant insertion point on the acetate tray, filled with gutta-percha (Fig. 3A); PC - radiopaque image of the PCg point on radiographs and computed tomography images (Fig. 3B, C, D, 5B); PI – radiopaque image of point PIg on the radiographs and computed tomography images (Fig. 3B, C, D); PCx - contact point between the dental crowns as determined on the radiograph by the examiner (Fig. 3C, D, 5B). This point was created to identify the drift of points PCg and PIg on the radiographic images.

For this study, two linear measurements of the radiographic images were obtained: Measurement 1 – from point PC to point PI; measurement 2 – from point PCx to point PI. Measurements made directly on the acetate trays were considered gold standard: From point PCg to point PIg.

The distances in between points, both on the radiographs and the acetate trays, were measured with a high precision digital Mitutoyo Digimatic Caliper 0.01-150 mm (Mitutoyo, Brazil) by a single examiner (Fig. 4A, C). In order to test and validate the results, this procedure was repeated twice with a one-week interval between the two.

Given the fact that the acetate tray points all had 1.0 mm diameter, the point centers were used as reference for the measurements (Fig. 4A).

The measurements on the interproximal and periapical radiographs were performed with the help of a light box in a dark room with black carton masks and the window sized accurately to fit the X-ray film. PCx points were marked with a 0.3 mm pencil holder (Pentel, Japan) on a 0.003 mm thick acetate film used for cephalometric tracing (3M/Unitek, Monrovia, CA, USA), attached to the radiographs (Fig. 4B,C).

Once the tomographic images had been acquired, the measurements were performed using XoranCat software's 'distance' tool. In the multiplanar assessment environment, in the axial display window, the image was turned around so as to make the occlusal plane of the side of interest to be placed parallel to the vertical plane (Fig. 5C). Additionally, in the sagittal window, the image was turned around so as to cause the tooth's long axis to remain perpendicular to the horizontal plane (Fig. 5B).

The points were identified within the three

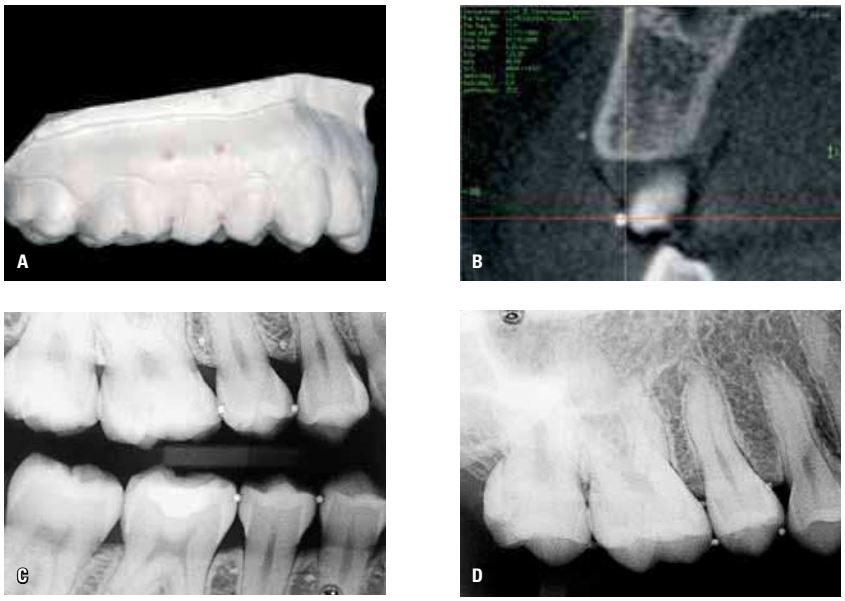

FIGURE 3 - An illustration of the points used in the present study: **A)** Acetate dental tray; **B)** Computed tomography image, coronal view; **C)** Interproximal radiograph; **D)** Periapical radiograph.

FIGURE 4 - **A)** Measurement taken on the acetate tray. **B)** PCx point marking. **C)** Periapical radiograph measurement using a digital gauge.

FIGURE 5 - Image of XoranCat software's multiplanar assessment environment showing an analysis of the right hand side region in between the bicuspids: **A)** coronal slice, with points PC and PI visible; **B)** sagittal slice, identifying point PCx overlaid on top of point PC; **C)** axial slice, used as an aid in positioning all other slices.

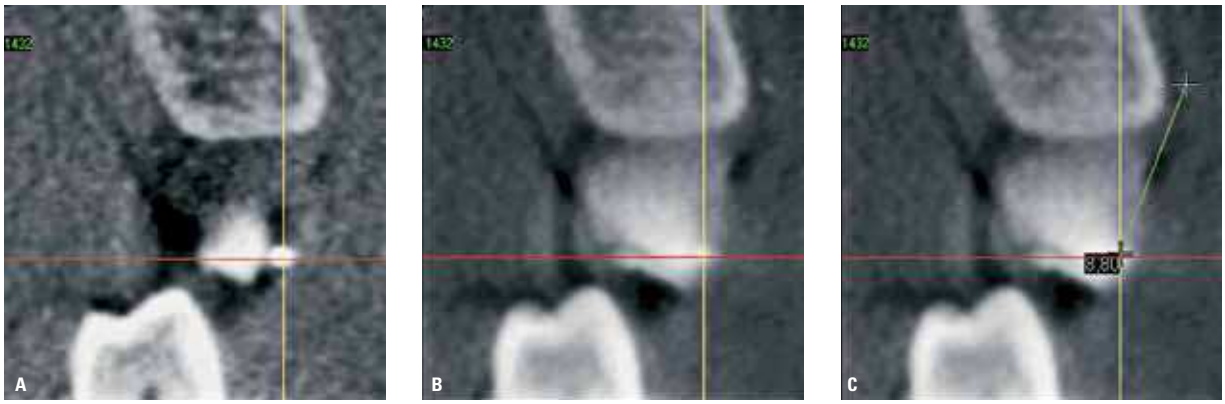

FIGURE 6 - **A)** Image of a computed tomography 0.2 mm slice identifying point PC. **B)** Slice thickness was increased to 3 mm allowing the identification of points PC and PI. **C)** Measurement performed.

planes and using a measuring tool available in the software, measurements were made on the coronal view. Considering that computed tomography unveils a tridimensional view, the choice was made to measure the coronal view since it displays a better visualization of the points than the sagittal view. The thickness of the ideal tomographic slice to identify the center of the gutta-percha points was 0.2 mm (Fig. 6A). In most cases, however, the points were not on the same coronal view for this slice. Therefore, in order to identify and measure them it was necessary to increase slice thickness (Fig. 6B, C). Measurements for this group were performed only once since they were made digitally, using the aforementioned software.

Statistical analysis

The data were tabulated and analyzed with descriptive statistics of the reading variable by calculating the central trend and dispersion measurements, assessing researcher's gauging and reproducibility. Student's t-test was utilized for paired samples with a 95% confidence interval, with the purpose of comparing each discrete radiographic exam with the gold standard.

RESULTS

After analyzing the central trend and dispersion measurements, a significant correlation was noted for the three readings of the interproximal and periapical radiographs and for the acetate trays, thereby confirming the reading variable's reproducibility and gauging. It was found that $p > 0.98$ and $p > 0.97$ for the gold standard, $p > 0.97$ and $p > 0.96$ for the interproximal radiographs, $p > 0.98$ and $p > 0.97$ for the periapical radiographs concerning measurements 1 and 2, respectively.

As regards measurement 1, a statistically significant difference was noted in relation to the gold standard in 4.1%, 25% and 100% of the areas in the computed tomography images, interproximal and periapical radiographs, respectively. Regarding measurement 2 a statistically significant difference was noted in relation to the gold standard in 4.1%, 56.2% and 100% of all areas, in relation to the areas in the computed tomography images, interproximal and periapical radiographs, respectively (Table 2). For the interproximal radiographs, concerning measurements 1 and 2, 65.3% and 34.6% of the areas corresponded to the upper and lower arches, respectively (Table 1, 2).

Table 1 - Mean and standard deviation values for three measurement 1 readings, in millimeters.

	Gold standard		interproximal		periapical		tomographic image	
	X	d.p.	X	d.p.	X	d.p.	X	d.p.
14-15								
Patient 1	6.74	0.12	6.64	0.02	4.38**	0.03	6.55	0.10
Patient 2	7.63	0.03	7.46	0.02	5.35**	0.03	7.60	0.10
Patient 3	8.47	0.05	8.04*	0.05	5.54**	0.04	8.33	0.10
Patient 4	8.07	0.04	7.83	0.01	4.95**	0.05	7.92	0.10
15-16								
Patient 1	6.42	0.07	6.34	0.04	3.8**	0.01	6.17 *	0.10
Patient 2	7.83	0.02	7.45*	0.03	5.96**	0.04	7.83	0.10
Patient 3	8.01	0.05	7.94	0.03	5.44**	0.01	7.98	0.10
Patient 4	8.66	0.02	7.81**	0.06	6.25**	0.12	8.79	0.10
24-25								
Patient 1	8.24	0.03	7.67**	0.02	5.55**	0.03	8.09	0.10
Patient 2	8.08	0.07	7.89	0.04	6.32**	0.03	7.97	0.10
Patient 3	8.98	0.01	8.35**	0.01	6.12**	0.02	8.83	0.10
Patient 4	7.95	0.03	8.08	0.04	6.33**	0.09	8.09	0.10
25-26								
Patient 1	7.88	0.16	7.02*	0.05	5.92**	0.07	7.94	0.10
Patient 2	8.45	0.01	8.56	0.07	7.56**	0.06	8.29	0.10
Patient 3	8.53	0.03	8.56	0.02	7.14**	0.04	8.36	0.10
Patient 4	7.62	0.05	7.83	0.01	6.20**	0.02	7.81	0.10
34-35								
Patient 1	6.53	0.08	6.31	0.06	4.90**	0.02	6.40	0.10
Patient 2	8.28	0.03	7.05	0.03	7.05**	0.03	7.99	0.10
Patient 3	8.26	0.04	7.75**	0.04	6.23**	0.06	8.41	0.10
Patient 4	8.99	0.04	8.98	0.02	6.72**	0.02	8.94	0.10
35-36								
Patient 1	7.30	0.07	5.50**	0.03	5.38**	0.02	7.28	0.10
Patient 2	8.24	0.03	8.16	0.03	5.74**	0.05	8.12	0.10
Patient 3	7.61	0.06	7.55	0.03	6.09**	0.04	7.59	0.10
Patient 4	8.58	0.04	8.66	0.07	5.42**	0.02	8.32	0.10
44-45								
Patient 1	7.69	0.03	7.66	0.03	5.53**	0.02	7.52	0.10
Patient 2	8.99	0.05	8.84	0.03	7.36**	0.03	9.02	0.10
Patient 3	7.51	0.03	7.56	0.01	6.22**	0.01	7.57	0.10
Patient 4	7.70	0.03	7.64	0.02	5.91**	0.05	7.53	0.10
45-46								
Patient 1	7.17	0.01	6.99	0.07	4.74**	0.05	7.10	0.10
Patient 2	7.69	0.02	7.77	0.06	6.85**	0.02	7.57	0.10
Patient 3	6.33	0.05	6.14	0.04	4.96**	0.03	6.40	0.10
Patient 4	7.38	0.03	7.43	0.04	4.49**	0.06	7.43	0.10

Student's t-test comparing each area with the gold standard, where (*) relates to $p<0.05$ and (**) refers to $p<0.00$.

Table 2 - Mean and standard deviation values of the three measurement 2 readings, in millimeters.

	Gold standard		interproximal		periapical		tomographic image	
	X	d.p.	X	d.p.	X	d.p.	X	d.p.
14-15								
Patient 1	6.74	0.12	6.56	0.07	2.50**	0.04	6.55	0.10
Patient 2	7.63	0.03	7.45	0.07	4.56**	1.16	7.60	0.10
Patient 3	8.47	0.05	7.04**	0.63	4.14**	0.02	8.33	0.10
Patient 4	8.07	0.04	7.65*	0.04	4.14**	0.12	7.92	0.10
15-16								
Patient 1	6.42	0.07	5.82*	0.09	2.03**	0.03	6.17*	0.10
Patient 2	7.83	0.02	7.44*	0.03	4.67**	0.57	7.83	0.10
Patient 3	8.01	0.05	7.00**	0.01	3.93**	0.07	7.98	0.10
Patient 4	8.66	0.02	7.77**	0.04	5.12**	0.00	8.79	0.10
24-25								
Patient 1	8.24	0.03	7.50**	0.01	3.64**	0.08	8.09	0.10
Patient 2	8.08	0.07	7.65*	0.04	4.20**	0.03	7.97	0.10
Patient 3	8.98	0.01	7.79**	0.01	5.10**	0.02	8.83	0.10
Patient 4	7.95	0.03	8.08	0.01	5.60**	0.08	8.09	0.10
25-26								
Patient 1	7.88	0.16	7.00**	0.01	4.63**	0.03	7.94	0.10
Patient 2	8.45	0.01	8.53	0.07	5.95**	0.07	8.29	0.10
Patient 3	8.53	0.03	7.24**	0.08	5.32**	0.07	8.36	0.10
Patient 4	7.62	0.05	7.62	0.04	5.86**	0.84	7.81	0.10
34-35								
Patient 1	6.53	0.08	6.02	0.07	3.61**	0.07	6.40	0.10
Patient 2	8.28	0.03	8.15	0.04	5.48**	0.05	7.99	0.10
Patient 3	8.26	0.04	7.45**	0.05	5.16**	0.01	8.41	0.10
Patient 4	8.99	0.04	8.92	0.02	4.88**	0.10	8.94	0.10
35-36								
Patient 1	7.30	0.07	4.85**	0.06	3.55**	0.02	7.28	0.10
Patient 2	8.24	0.03	8.15	0.04	4.23**	0.09	8.12	0.10
Patient 3	7.61	0.06	7.52	0.04	5.06**	0.03	7.59	0.10
Patient 4	8.58	0.04	8.65	0.04	2.83**	2.81	8.32	0.10
44-45								
Patient 1	7.69	0.03	6.55*	0.32	2.30**	0.01	7.52	0.10
Patient 2	8.99	0.05	8.41*	0.04	6.72**	0.01	9.02	0.10
Patient 3	7.51	0.03	7.01*	0.00	4.71**	0.02	7.57	0.10
Patient 4	7.70	0.03	7.60	0.02	4.81**	0.01	7.53	0.10
45-46								
Patient 1	7.17	0.01	6.60**	0.01	1.97**	0.04	7.10	0.10
Patient 2	7.69	0.02	7.77	0.07	5.53**	0.04	7.57	0.10
Patient 3	6.33	0.05	5.91*	0.04	3.72**	0.04	6.40	0.10
Patient 4	7.39	0.03	7.44	0.05	2.88**	0.12	7.43	0.10

Student's t-test comparing each area with the gold standard, where (*) relates to $p<0.05$ and (**) refers to $p<0.00$.

DISCUSSION

Mini-implants have evolved a great deal in terms of shape, type and surgical technique and have consequently become an increasingly safe and standardized resource. Nevertheless, few studies have been conducted to investigate radiographic techniques available to the professional during planning and at insertion time.

In the present study, radiographic measurements were performed on acetate paper and a 100th millimeter precision digital gauge was employed, but not directly upon the radiograph since the tip of the caliper might scratch the film and impair the measurement of subsequent readings. Three readings of each exam were conducted, within a week's interval in between them, with the aim of calculating the mean measurement value. Based on an analysis of the central and dispersion trend measurements, a significant correlation was noted amongst the three readings. A similar methodology was used in studies by Gher and Richardson[10] to assess researcher reproducibility and gauging in performing the readings.

Due to the fact that during the radiographic image analysis a vertical distortion appeared along with point drifts, two measurements were performed (measurement 1: PC – PI; measurement 2: PCx – PI), since measurement alone might not disclose the actual radiographic distortion.

Vertical distortions are based on object depth given the distance to the film – in this case there were two objects, namely, the alveolar process and the marker. We therefore have objects on different planes, which yield, as a result, different distortions. However, Ruschel et al.[25] recommend, even in dry skull studies, that the marker not be in contact with the bone crest so as to simulate a clinical situation, for in the mouth the gingival tissue is located between the marker and the bone. Should the marker remain in contact with the bone crest, we would have two objects at the same distance but which would not represent an actual clinical condition.

When measurement values are set lower they tend to mistakenly show that the mini-implant would be installed too close to the bone crest and would therefore be contraindicated at such site due to increased bone crest fracture risk or the risk of having the mini-implant inserted in the soft tissue. If a professional were to migrate the point towards the cervical region, consequently decreasing the interdental horizontal distance, given the conic shape of the roots, she might be led to mistakenly select a smaller diameter mini-implant. It might even imply that the available space would be inadequate for the insertion of a temporary anchorage device. This consideration is rather relevant, and according to Araújo[1] the size of the available insertion area should be duly assessed since reduced space requires smaller size mini-implants. For insertion in between roots it is preferable to select at least a 1.4 mm diameter mini-implant since smaller diameters are at a greater fracture risk during installation or removal, particularly on the mandible where the cortical bone is thicker. Should this space prove inadequate the need arises to assess the possibility of using alternative areas, altering angulation or even separating the roots orthodontically so as to expand the available space, thus facilitating safe mini-implant insertion.

The findings of the present study have demonstrated that periapical radiographs show statistically significant differences in 100% of the areas (Table 1, 2), and are therefore contraindicated as a tool in selecting the best mini-implant installation site since the guide image will drift too far off towards the alveolar bone crest. The vertical distortion is so significant that it precludes even horizontal measurements of the proposed site. Additionally, one can infer that since the surgical guide images undergo considerable vertical distortion in pericapical radiographs, these radiographs would not be indicated for assessing

installed mini-implants.

On measurement 1, the interproximal radiographs showed satisfactory results (Table 1). Despite having disclosed a statistically significant difference in 25% of the areas, such difference has no clinical relevance. According to Callegari-Jacques4, statistically significant differences found in dental radiographic image measurements may not be relevant from a clinical or biological perspective given the limitations of the values found by the measurements.

On measurement 2, the interproximal radiograph showed a statistically significant difference in 56.2% of the regions (Table 2), with measurement values set lower than the gold standard. An increase in the number of areas with statistically significant differences between measurement 1 and measurement 2 could be justified taking into account the correction of the contact point, which drifted vertically towards the cervical region, thereby leading it closer to the insertion point in the radiograph, which compounded the distortion brought about by the vertical angulation.

As can be observed in the interproximal radiographs, the upper arch showed greater distortion compared with the lower arch, which can be explained by the positive vertical angulation used in the procedure (+5° to +10°), which is more appropriate for the lower arch due to the implantation of teeth in the bone base. In assessing the areas which showed statistically significant differences in relation to the gold standard, one can observe that 34.6%, 42.3% and 23% showed vertical distortion within the 0 to 0.5, 0.5 to 1 mm and 1 to 1.5 mm ranges, respectively (Graph 1). Despite the low percentage found in regions within the 1.0 to 1.5 mm range, one should be cautious when using interproximal radiographs for the purposes mentioned in this research since, more often than not, the available interradicular space is so scarce that 1.5 mm may have clinical relevance. A comparison between intraoral radiographic results shows that interproximal radiographs are more accurate than periapical radiographs. These results corroborate Reed and Polson[24], Sewerin[27] and Thunthy[29] who reported that whenever mini-implant anchorage becomes necessary the chosen site should be analyzed using interproximal radiographs since periapical radiographs tend to produce slant and garbled images.

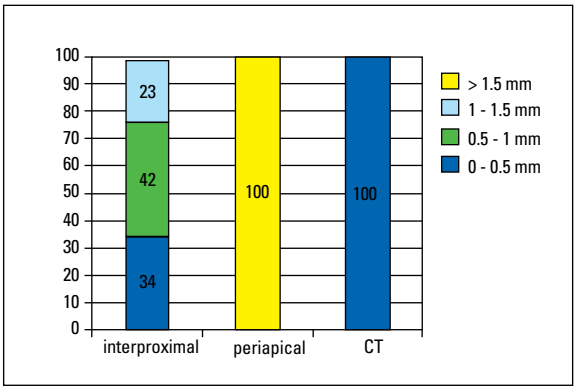

GRAPH 1 - Areas that showed statistically significant differences in relation to the gold standard, distributed in millimeter intervals.

Cone beam computed tomography yielded statistically significant results in 4.1% of the samples only, with a difference of 0.50 mm at the most. It is therefore considered the most accurate and reliable of all methods studied for viewing proposed mini-implant insertion sites.

For new patients, professionals should carefully assess the cost-benefit relationship and order a cone beam computed tomography image, which will provide, in one single exam, all conventional 2D images that comprise orthodontic documentation with the added benefit of a more detailed tridimensional view of dentofacial structures. From a financial standpoint, cone beam computed tomography proved most convenient since nowadays an estimate for the exam makes up approximately the same amount spent on conventional orthodontic documentation. Insofar as biological costs are concerned, due

to the patient's exposure to radiation, it should emphasized that a single cone beam computed tomography exam can replace the exposure entailed in a number of conventional radiographic exams, which are routinely used in orthodontic practice[9].

CONCLUSION

Based on the findings of the present study, it is possible to conclude that cone beam computed tomography is the most accurate and effective exam for assessing the vertical position of sites selected for mini-implant insertion. Compared with the gold standard, CT exams did not show any differences higher than 0.50 mm. Interproximal radiographs can be used in spite of obvious limitations whereas pericapical radiographs yielded unsatisfactory results.

ACKNOWLEDGEMENTS

The authors wish to thank Drs. João Carlos Costa da Silva and Elmo Anísio Costa da Silva for their invaluable contribution to this study.

Submitted: maio de 2008
Revised and accepted for publication: julho de 2008

REFERENCES

1. ARAÚJO, T. M. Ancoragem esquelética com mini-implantes. In: LIMA FILHO, R. M. A.; BOLOGNESE, A. M. **Ortodontia**: arte e ciência, 1. ed. Maringá: Dental Press, 2007. p. 393-448.
2. ARAÚJO, T. M.; NASCIMENTO, M. H. A.; BEZERRA, F.; SOBRAL, M. C. Ancoragem esquelética em Ortodontia com mini-implantes. **Rev. Dental. Press Ortodon. Ortop. Facial**, Maringá, v. 11, n. 4, p. 126-156, jul./ago. 2006.
3. BAE, S. M.; PARK, H. S.; KYUNG, H. M.; KWON, O. W.; SUNG, J. H. Clinical application of micro-implant anchorage. **J. Clin. Orthod.**, Boulder, v. 36, no. 5, p. 298-302, May 2002.
4. CALLEGARI-JACQUES, S. M. **Bioestatística**: princípios e aplicações. Porto Alegre: Artmed, 2003. p. 247-258.
5. COSTA, A.; RAFFAINL, M.; MELSEN, B. Miniscrews as orthodontic anchorage: a preliminary report. **Int. J. Adult Orthodon. Orthognath. Surg.**, Chicago, v. 13, no. 3, p. 201-209, 1998.
6. DUCKWORTH, J. E.; JUDY, P. F.; GOODSON, J. M.; SOCRANSKY, S. S. A method for the geometric and densitometric standardization of intraoral radiographs. **J. Periodontol.**, Chicago, v. 54, no. 7, p. 435-440, July 1983.
7. FABBRONI, G.; AABED, S.; MIZEN, K.; STARR, D. G. Transalveolar screws and the incidence of dental damage: a prospective study. **Int. J. Oral Maxillofac. Surg.**, Copenhagen, v. 33, no. 5, p. 442-446, July 2004.
8. FREITAS, A.; VAROLI, O. J.; TORRES, F. A. Técnicas radiográficas intrabucais. In: FREITAS, A.; ROSA, J. E.; SOUZA, I. F. **Radiologia odontológica**. 1. ed. São Paulo: Artes Médicas, 2004. p. 103-166.
9. GARIB, D. G.; RAYMUNDO JUNIOR, R.; RAYMUNDO, M. V.; RAYMUNDO, D. V.; FERREIRA, S. N. Tomografia computadorizada de feixe cônico (Cone beam): entendendo este novo método de diagnóstico por imagem com promissora aplicabilidade na Ortodontia. **Rev. Dental Press Ortodon. Ortop. Facial**, Maringá, v. 12, n. 2, p. 139-156, mar./apr. 2007.
10. GHER, M. E.; RICHARDSON, A. C. The accuracy of dental radiographic techniques used for evaluation of implant fixture placement. **Int. J. Periodontics Restorative Dent.**, Chicago, v. 15, no. 3, p. 268-283, June 1995.
11. GRABER, T. M.; VANARSDALL, R. L. **Orthodontics**: current principles and techniques. 5th ed. Missouri: Elsevier, 2005.
12. KANOMI, R. Mini-implant for orthodontic anchorage. **J. Clin. Orthod.**, Boulder, v. 31, no. 11, p. 763-767, Nov. 1997.
13. KIM, S. H.; CHOI Y. S.; HWANG, E. H.; CHUNG, K. R.; KOOK, Y. A.; NELSON, G. Surgical positioning of orthodontic mini-implants with guides fabricated on models replicated with cone-beam computed tomography. **Am. J. Orthod. Dentofacial Orthop.**, St. Louis, v. 131, no. 4, p. S82-S89, Apr. 2007. Supplement.
14. KITAI, N.; YASUDA, Y.; TAKADA, K. A stent fabricated on a selectively colored stereolithographic model for placement of orthodontic mini-implants. **Int. J. Adult Orthodon. Orthognath. Surg.**, Chicago, v. 17, no. 4, p. 264-266, 2002.
15. KOYANAGI, K. Development and clinical application of a surgical guide for optimal implant placement. **J. Prosthet. Dent.**, St. Louis, v. 88, no. 5, p. 548-552, Nov. 2002.
16. KURODA, S.; YAMADA, K.; DEGUCHI, T.; HASHIMOTO, T.; KYUNG, H. M.; TAKANO-YAMAMOTO, T. Root proximity is a major factor for screw failure in orthodontic anchorage. **Am. J. Orthod. Dentofacial Orthop.**, St. Louis, v. 131, no. 4, p. S68-S73, Apr. 2007. Supplement.
17. KYUNG, S. H.; CHOI, J. H.; PARK, Y. C. Miniscrew anchorage used to protract lower second molars into first molar extraction sites. **J. Clin. Orthod.**, Boulder, v. 37, no. 10, p. 575-779, Oct. 2003.
18. KYUNG, H. M.; PARK, H. S.; BAE, S. M.; SUNG, J. H.; KIM, I. B. Development of orthodontic micro-implants for intraoral anchorage. **J. Clin. Orthod.**, Boulder, v. 37, no. 6, p. 321-328, June 2003.
19. MAH, J.; BERGSTRAND, F. Temporary anchorage devices: a status report. **J. Clin. Orthod.**, Boulder, v. 39, no. 3, p. 132-136, Mar. 2005.
20. MAINO, B. G.; BEDNAR, J.; PAGIN P.; MURA, P. The spider screw for skeletal anchorage. **J. Clin. Orthod.**, Boulder, v. 37, no. 2, p. 90-97, Feb. 2003.
21. MOREA, C.; DOMINGUEZ, G. C.; WUO, A. V.; TORTAMANO, A. Surgical guide for optimal positioning of mini-implants. **J. Clin. Orthod.**, Boulder, v. 39, no. 5,

p. 317-321, May 2005.
22. PARK, H. S.; BAE, S. M.; KYUNG, H. M.; SUNG, J. H.; Micro-implant anchorage for treatment of skeletal Class I bialveolar protrusion. **J. Clin. Orthod.**, Boulder, v. 35, no. 7, p. 417-422, July 2001.
23. POGGIO, P. M.; INCORVATI, C.; VELO, S.; CARANO, A. "Safe zones": a guide for miniscrew positioning in the maxillary and mandibular arch. **Angle Orthod.**, Appleton, v. 76, no. 2, p. 191-197, Mar. 2006.
24. REED, B. E.; POLSON, A. M. Relationships between bitewing and periapical radiographs in assessing crestal alveolar bone levels. **J. Periodontol.**, Chicago, v. 55, no. 1, p. 22-27, Jan. 1984.
25. RUSCHEL, G.; NACONECY, M. M.; VEECK, E. B.; COSTA, N. P. Tomografia linear X tomografia computadorizada. **Rev. Odonto Cienc.**, Porto Alegre, v. 16, n. 34, p. 264-267, set./dez. 2001.
26. SCHNELLE, M. A.; BECK, F. M.; JAYNES, R. M.; HUJA, S. S. A radiographic evaluation of the availability of bone for placement of miniscrews. **Angle Orthod.**, Appleton, v. 74, no. 6, p. 832-837, Dec. 2004.
27. SEWERIN, P. Utilize your dental X-ray set better. **Int. Dent. J.**, London, v. 37, no. 1, p. 38-42, Mar. 1987.
28. SUZUKI, E. Y.; BURANASTIDPORN, B. An adjustable surgical guide for miniscrew placement. **J. Clin. Orthod.**, Boulder, v. 39, no. 10, p. 588-590, Oct. 2005.
29. THUNTHY, K. H. Radiographic illusions due to faulty angulations. **Dent. Radiogr. Photogr.**, Rochester, v. 51, no. 1, p. 1-7, 13-15, 1978.

Contact
Liz Matzenbacher da Silva
Centro de Ortodontia e Ortopedia Facial
AV. Araújo Pinho, nº 62, 7º andar - Canela - Salvador / BA
CEP: 40.110-150 - E-mail: lizmdasilva@hotmail.com