

Evaluation of dental changes in the maxilla of patients submitted to surgically-assisted rapid maxillary expansion without pterygomaxillary suture involvement*

Paulo Roberto Pelucio Camara**, Fernanda C. Goldenberg***, Dov C. Goldenberg****, Nivaldo Alonso*****, Marco A. Scanavini*****

Abstract

Objective: to evaluate transverse changes in the maxillary dental arch and the amount of tipping of the anchoring teeth caused by the Hyrax expansion appliance in patients submitted to surgically-assisted rapid maxillary expansion (SARME), as well as the effectiveness of this surgical technique. The sample consisted of 34 pairs of plaster cast models of 17 patients, 6 male and 11 female. Methods: measurements of the changes in the vertical and transverse planes were taken in plaster cast models. The surgical procedure performed was an osteotomy on the lateral maxillary walls without pterygoid plate involvement, osteotomy from the nasal spine to the dental midline (upper central incisors), separation of the midpalatal suture using a chisel, and nasal septum separation. Activations were initiated on the third day post-surgery, once in the morning and once at night. Results: there was a statistically significant expansion – 6.03mm, 9.82mm, 8.66mm, 9.72mm and 5.67mm, in the canine, first and second pre-molar areas, respectively. When the amount of crown tipping was evaluated for the anchoring teeth, an asymmetrical buccal tipping was observed, since the values found for first molars were 6.89° (right) and 9.56° (left), while the values for first pre-molars were 4.74° (left) and 3.26° (right) – the latter being considered statistically non-significant. Conclusions: the surgical technique applied in this study proved to be effective in achieving maxillary transverse change, resulting in dentoalveolar tipping of the appliance anchoring teeth.

Keywords: Maxillary expansion. Orthognathic surgery. Dental cast models.

* Based on the Master's thesis presented to the Methodist University of São Paulo (Unesp).

** Master in Orthodontics, Methodist University of São Paulo (Unesp). Orthodontist of the Craniomaxillofacial Surgery Service of the Division of Plastic and Burn Surgery, University of São Paulo Medical School – FMUSP.

*** Doctor of Science, Unifesp. Full professor of Orthodontics at the Methodist University of São Paulo (Unesp).

**** Doctor in Plastic Surgery, University of São Paulo Medical School – FMUSP.

***** Full Professor, University of São Paulo Medical School – FMUSP.

***** Head of the School of Dentistry and Chairman of the graduate program in Orthodontics of the Methodist University of São Paulo (Unesp).

INTRODUCTION

Maxillary transverse changes leading to unilateral or bilateral posterior crossbites are responsible for several different occlusal problems. Achieving adequate maxillary transverse dimension is essential for a functional and stable occlusion. In the maxilla, proximity to skeletal maturity increases osseous interdigitation as result of the fusion of craniofacial sutures^{11,14}. This, in turn, makes it more difficult to separate the maxilla at the midpalatal suture if the procedure is performed using only orthopedic forces through rapid maxillary expansion (RMA). In such cases, a maxillary suture release by osteotomy is the chosen method to reduce bone resistance and make the maxillary transverse expansion effective.

In SARME, an osteotomy is performed on the structures that are resisting expansive forces. This procedure brings advantages such as skeletal expansion, absence of pain, reduced periodontal health risks, increased nasal air flow, cosmetic improvement in the buccal corridor, as well as avoiding tooth extractions to correct dental crowding^{15,16,18,20}.

The results obtained from surgical expansion show a significant increase in maxillary transverse width, with correction of posterior crossbite and reduction of palatal depth, minimizing the buccal tipping of posterior teeth^{13,16} that may have occurred with RMA.

Clinically, we can observe maxillary arch atresia or posterior crossbite in patients that require maxillary expansion, which can be corrected with treatment.

The objective of the present study was to analyze the effects of SARME (without separation of the pterygomaxillary suture), by using plaster cast models to determine any possible transverse changes and buccal tipping of the canines, first and second pre-molars, first and second maxillary molars, as well as the overall effectiveness of this surgical technique.

MATERIAL AND METHODS

The sample used in this study consisted of 34 pairs of plaster cast models from 17 patients, 6 male and 11 female, subjected to SARME. As exclusion criteria, patients could not feature congenital malformations or facial syndromes.

Patients were selected from the Graduate Program in Orthodontics at the Methodist University of São Paulo (Unesp), and from the Craniomaxillofacial Surgery Service of the Division of Plastic and Burn Surgery at the Central Institute of the University of São Paulo Medical School General Hospital (HCFMUSP).

For each patient, two pairs of models were prepared, obtained at different stages: T1 – initial (prior to the surgical procedure), and T2 – three months after the activation of the expansion appliance was ended.

The expansion appliance used was a Hyrax-type expansion appliance, built with a 13mm expansion screw (Morelli, Sorocaba / SP).

Each patient was subjected to general anesthesia and nasotracheal intubation. A Le Fort I osteotomy was performed on the maxilla, with separation of the central and lateral maxillary pillars without pterygomaxillary suture involvement. The midpalatal suture was separated, starting at the anterior nasal spine and between the central incisors over the alveolar bone. After the osteotomy, the Hyrax appliance was activated with the purpose of confirming maxillary separation, maintaining a 1-mm separation between the central incisors. Appliance activation took place on the third day post-op, with two daily activations – one in the morning (1/4 turn) and another at night (1/4 turn) – until reaching total screw opening or achieving occlusal objectives⁷ (Fig. 1).

Transverse and vertical measurements were made in plaster cast models placed in a three-dimensional manual measuring device, in which values were measured by shifting all three axes, X, Y and Z (Fig. 2). The measuring device was

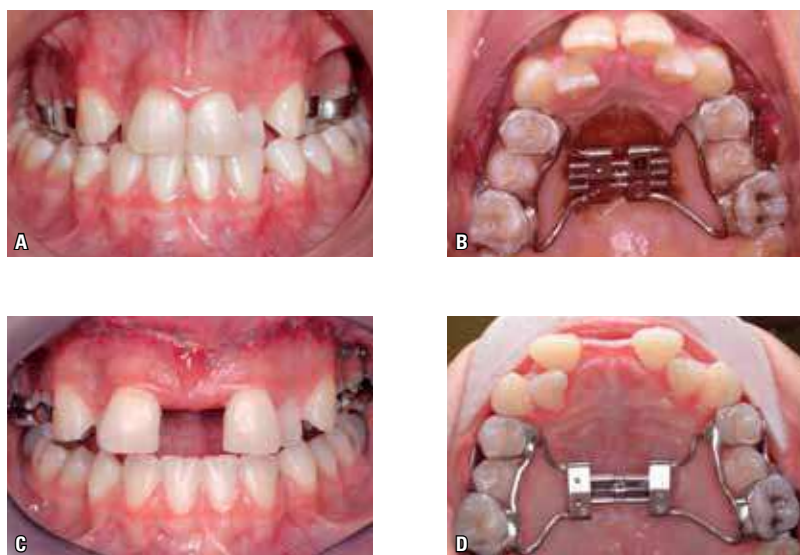


FIGURE 1 - **A, B)** Frontal and upper occlusal views of the Hyrax expansion appliance, placed with bands on the first maxillary molars and first pre-molars, with a buccal and palatal connecting arch between these teeth. **C, D)** Frontal and upper occlusal views of the expansion appliance after activation, demonstrating the expansion effect on the maxillary teeth.

developed on an aluminum platform, on top of which two 150-mm digital calipers were placed, forming a 90° angle (horizontal plane, X and Y axes), as well as a 50-mm Mitutoyo® analog sliding caliper (vertical plane, Z axis).

The reference points on the maxillary dental arches were determined on the maxillary plaster cast model of each patient, and reference points were set on the occlusal surface of teeth, as shown on figure 3.

Transverse measurements (X axis) had the objective of quantifying the changes occurred after the activation of the Hyrax expansion appliance. The measurements were taken after placing the plaster model on the three-dimensional measuring device, with the occlusal plane leveled by referencing the mesiopalatal cusps of the first molars and the incisal edges of the central incisors, thus measuring the linear distances between left and right teeth (Fig. 4).

For posterior teeth tipping, the horizontal (X axis) and vertical (Z axis) linear distances of the

buccal and palatal cusps of maxillary first molars and premolars were measured (Fig. 5, 6). The measurements were later computed in a mathematical formula to convert linear distances into degrees (Fig. 7). The horizontal measurements were placed over the X-axis, and vertical measurements were placed over the Z-axis, as shown on figure 6.

Once the desired measurement was obtained, the mathematical formula illustrated on figure 7 was applied, with the purpose of determining the amount of tipping of each tooth in periods T1 and T2. A positive value was attributed to buccal tipping, while palatal tipping received a negative value.

RESULTS

To verify the effects obtained from the treatment, Student's t-test was applied, at a 5% significance level ($p < 0.05$) for paired data, as shown on tables 1 and 2. Method error was evaluated by applying Dahlberg's formula.




FIGURE 2 - Three-dimensional measuring device developed at Umesp. **A)** frontal view, showing the vertical measurement clock (Z-axis), and **B)** upper view, showing the two digital calipers for transverse (X-axis), and anteroposterior (Y-axis) measurements.

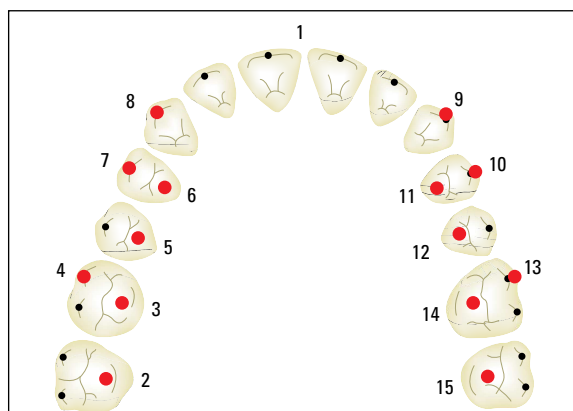


FIGURE 3 - Linear distances: distance between canines – linear distance, in mm, obtained between points 8 and 9; distance between first pre-molars – distance obtained between points 6 and 11; distance between second pre-molars – distance obtained between points 5 and 12; distance between first molars – distance obtained between points 3 and 14; distance between second molars – distance obtained between points 2 and 15.

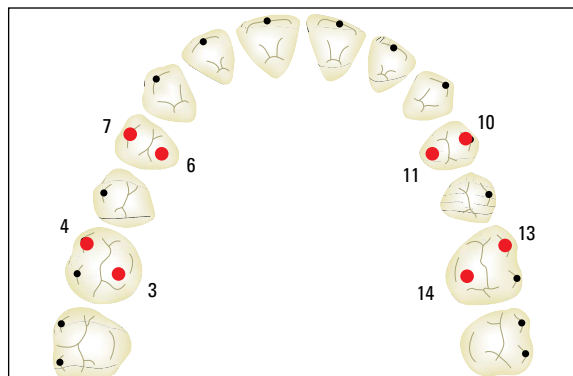


FIGURE 5 - Landmarks used to calculate the degree of dental tipping: Maxillary right first pre-molar – points 7 to 6; maxillary left first pre-molar – points 10 to 11; maxillary right first molar – points 4 to 3; maxillary left first molar – points 14 to 13.



FIGURE 4 - Transverse measurements performed on plaster cast models.

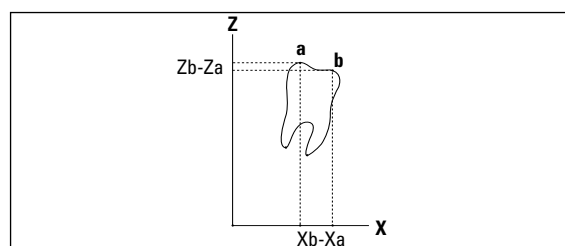


FIGURE 6 - Graph along Z and X coordinates, with Xa (buccal cusp) and Xb (palatal cusp) in the horizontal plane and Za (buccal cusp) and Zb (palatal cusp) in the vertical plane.

$$\theta = \arctg \left(\frac{Z_b - Z_a}{X_b - X_a} \right) \cdot \frac{180}{\pi}$$

FIGURE 7 - Mathematical formula used to determine angular measurement.

Transverse measurements

Distance between maxillary canines

There was a statistically significant increase in the distances between left and right canines, as shown on table 1. The mean difference (T2 – T1) between the intervals was 6.03mm.

Distance between maxillary pre-molars

There was a statistically significant increase in the distances between first and second pre-molars, as shown on table 1. The mean difference (T2 – T1) between the intervals was 9.82mm for the first pre-molar and 8.66mm for the second pre-molar.

Distance between maxillary molars

There was a statistically significant increase in the distances between first and second molars, as shown on table 1. The mean difference (T2 – T1)

between the intervals was 9.72mm for the first molar and 5.67mm for the second molar.

Dental tipping

Tipping of the maxillary first molars

After measurement of the X and Z axes, as demonstrated on figures 5 and 6, and application of the mathematical formula in figure 7, it was possible to observe buccal tipping of the right and left first molars, resulting in statistically significant values, as shown on table 2. Mean observed variation was 6.89°, demonstrating buccal tipping of the right first molar. For the left first molar, mean buccal tipping observed was 9.56°.

Tipping of maxillary first pre-molars

The behavior of first pre-molars was not statistically similar, with a tendency for asymmetrical tipping. For right first pre-molars, the observed

TABLE 1 - Distance between teeth.

VARIABLES	T1		T2		T2 - T1		T	P
	Mean	s.d.	mean	s.d.	mean	s.d.		
distance between canines	29.85	2.53	35.87	2.41	6.03	1.27	-18.92	0.0000
distance between first pre-molars	25.51	2.59	35.33	2.82	9.82	1.48	-27.33	0.0000
distance between second pre-molars	30.96	3.32	39.62	4.62	8.66	5.30	-6.33	0.0000
distance between first molars	36.03	4.27	45.75	3.99	9.72	1.57	-24.74	0.0000
distance between second molars	43.39	4.14	49.07	4.68	5.67	2.40	-9.45	0.0000

* statistically significant difference (p < 0.05).

n.s. = statistically non-significant difference.

TABLE 2 - Buccal-lingual tipping.

VARIABLES	T1		T2		T2 - T1		T	P
	mean	s.d.	mean	s.d.	mean	s.d.		
right molar tipping	7.28	8.02	14.17	7.18	6.89	5.55	-5.12	0.0001
left molar tipping	4.01	9.48	13.57	9.45	9.56	9.08	-4.34	0.0005
right pre-molar tipping	-5.58	10.11	-2.32	7.97	3.26	6.96	-1.93	0.0715
left pre-molar tipping	-7.33	7.37	-2.58	7.68	4.74	3.98	-4.92	0.0002

* statistically significant difference (p < 0.05).

n.s. = statistically non-significant difference.

tipping was not considered statistically significant, as shown on table 2. However, buccal tipping measured on left first pre-molars proved to be statistically significant, as shown on table 2, with a variation of 4.74°.

DISCUSSION

Timms & Vero²¹ suggest that, in patients under 25, rapid maxillary expansion⁸ (RMA) should be attempted. However, the risk exists of failure in this type of treatment, and the high relapse rates in adults^{2,4,10,14,22} should also be considered.

The fusion of maxillary sutures is the main reason for this difficulty. Therefore, the surgical release of all maxillary sutures is reported in the literature as the most adequate choice of treatment; as affirmed by Betts et al.⁷, the release of the pterygoid process must be performed so that no limitation occurs in posterior maxillary expansion. Kennedy et al.¹² conducted studies in monkeys and concluded that the zygomatic pillar is the area that offers greater resistance to maxillary expansion; however, in order to basal maxillary movement occur, all maxillary pillars and sutures must be sectioned. Thus, the area for the osteotomy is still a subject of much debate and controversy. Based on literature findings that show the efficacy of expansion in patients submitted to maxillary osteotomies^{1,3,14,17}, the surgical technique selected for the present work did not involve separation of the pterygoid process during the osteotomy. The level of expansion obtained must be correlated to the level of buccal tipping in order to determine the efficacy of the surgical technique. Few studies correlate dentoalveolar expansion with tipping.

The amount of transverse change produced by SARME is effective in both the anterior and posterior regions of the maxilla^{1,3,6,9,14,17,19}. On table 3, the efficacy of this procedure can be evaluated, from other studies found in the literature.

A comparison of the results obtained in the present sample with those from other studies indicates that the level of expansion obtained was in

accordance with the findings in the literature, even though the surgical technique did not involve the osteotomy of the pterygomaxillary suture.

In evaluating the transverse change between the canines, the result obtained in the sample indicates a statistically significant increase in the distances between right and left canines. The mean found for the differences (T2 – T1) between intervals was 6.03mm. When compared with other findings, it can be observed that an important variation was obtained on the canines; since the variation between the analyzed studies was 4.1mm and 6.03mm, it demonstrates that regardless of the surgical technique employed, significant transverse variations were obtained for these teeth, even though they did not receive direct support through bands or wires.

The transverse distance between maxillary pre-molars showed a statistically significant increase. For first pre-molars, the mean between intervals was 9.82mm; for second pre-molars, 8.66mm. It can be observed that the variation was similar for first and second pre-molars, which shows that the second pre-molar followed the transverse movement that was produced. The 1.16mm difference between the first and second pre-molars is likely due to the absence of support from bands on the second pre-molars, which had palatal support (stainless steel wire). The values obtained in the literature were similar; however, Antilla et al.¹, and Byllof & Mossaz⁹ found the increase in transverse distance to be greater in the second pre-molar, as shown on table 3, which is different from the findings of this study and other studies in the literature.

When evaluating molar transverse distance, the mean variation between intervals found for first molars was 9.72mm and 5.67mm for second molars. The value found between first pre-molars and first molars was comparable; however, it must be mentioned these teeth were used as anchorage for the application of expanding forces and were also connected to the expansion screw by bands.

TABLE 3 - Comparison of articles that measured dental changes in patients subjected to SARME.

AUTHOR	OSTEOTOMY	CANINES	FIRST PRE-MOLARS	SECOND PRE-MOLARS	FIRST MOLARS	SECOND MOLARS
Anttila et al. ¹	osteotomy on lateral maxillary wall	4.1mm	6.8mm	7.2mm	7.2mm	5.1mm
Bays, Grecco ³	osteotomy on lateral maxillary wall	4.5mm	0	0	5.8mm	0
Berger et al. ⁶	Le Fort osteotomy with pterygomaxillary suture involvement	4.84mm	0	0	5.78mm	0
Byloff, Mossaz ⁹	Le Fort osteotomy with pterygomaxillary suture involvement	5.19mm	8.08mm	8.26mm	8.73mm	5.48mm
Northway, Meade ¹⁴	osteotomy on lateral walls	4.26mm	0	0	5.9mm	0
Schimming et al. ¹⁷	osteotomy on lateral walls	5.9mm	0	0	6.0mm	0
Stromberg, Holm ¹⁹	Le Fort osteotomy with pterygomaxillary suture involvement	5.0mm	0	0	8.3mm	0

Similar performance has been observed in other works. However, the amount of transverse change was noteworthy for the second molars, which responded with a lower variation also observed in other studies.

It can be suggested that such a variation is due either to the lack of an extension of the osteotomy over the pterygomaxillary suture or the lack of direct support on the second molars. In the work by Byloff & Mossaz⁹, who used a more invasive osteotomy, the result found for the second molar is similar to that obtained in the present sample. Thus, the osteotomy is likely not to be responsible for the lack of expansion in that area, due to the absence of band support in the second molars, which resulted in smaller transverse change. Comparing the measurements found for the canines (6.03mm) and second molars (5.67mm), a correlation is found between the obtained values, as both groups did not receive direct support from the expansion appliance during activation. This alteration may be the result of the change that took place over the maxillary bone only.

Regarding the tipping observed in the posterior teeth, the results exhibited an asymmetric behavior, in which the left teeth showed greater buccal tipping, which could be a trait of the analyzed sample. The method employed for this sample allows for the individual measuring of tipping endured for each tooth.

The changes in the left and right maxillary first molars were calculated in the T1 and T2 time intervals, with the purpose of quantifying the obtained movement. The values found were statistically significant, as shown on table 2. Mean observed variation was 6.89°, showing significant buccal tipping of the right molar. For the left molar, mean buccal tipping of 9.56° was observed. The results demonstrated an asymmetrical behavior for this group of teeth, teeth on the left side showed statistically greater buccal tipping, which could be a trait of the analyzed sample.

The changes found in the left and right maxillary first pre-molars at T1 and T2 time intervals were different, as shown on table 2. For the right side, the mean observed variation was 3.26°,

which was statistically non-significant. Buccal tipping in the left first pre-molars, however, was statistically significant, with a 4.74° change. Tipping in these teeth was also asymmetrical in regard to buccal movement of posterior teeth.

The sample demonstrated that there is effective transverse gain; however, there was buccal pendular movement of the crowns of teeth supporting the Hyrax appliance. First pre-molars and first maxillary molars showed the greatest transverse changes. The changes in these teeth are the added result of two effects: the expansive transverse movement that occurs due to bone separation and buccal tipping of dental crowns. Buccal tipping may be considered an undesirable effect, according to the clinic needs for each patient, as lateral teeth movement should be more parallel.

CONCLUSIONS

From the results obtained with the surgical

technique applied in SARME, it can be concluded that:

- Regarding transverse changes, there was a statistically significant increase in the transverse distances of the canines, first and second pre-molars, first and second molars.

- There was a statistically significant increase in the tipping of left and right first molars, as well as of the first pre-molars on one side, suggesting asymmetrical behavior of the teeth evaluated based on SARME.

- The surgical technique applied proved to be effective, as it allowed transverse changes in the maxilla, although with buccal tipping of the crowns of teeth supporting the expansion appliance.

Sent: September 2007
Reviewed and accepted: June 2008

REFERENCES

1. ANTILA, A. et al. Feasibility and long term stability of surgically assisted rapid maxillary expansion with lateral osteotomy. **Eur. J. Orthod.**, Oxford, v. 26, no. 4, p. 391-395, 2004.
2. BARBER, A. F.; SIMS, M. R. Rapid maxillary expansion and external root resorption in man: A scanning microscope study. **Am. J. Orthod.**, St. Louis, v. 79, no. 6, p. 630-652, June 1981.
3. BAYS, R. A.; GRECO, J. M. Surgically assisted rapid palatal expansion: An outpatient technique with long-term stability. **J. Oral. Maxillofac. Surg.**, Stuttgart, v. 50, no. 2, p. 110-113, Feb. 1992.
4. BELL, R. A. A review of maxillary expansion in relation to rate of expansion and patient's age. **Am. J. Orthod.**, St. Louis, v. 81, no. 1, p. 32-37, Jan. 1982.
5. BELL, W. H.; EPKER, B. N. Surgical-orthodontic expansion of the maxilla. **Am. J. Orthod. Dentofacial Orthop.**, St. Louis, v. 70, no. 5, p. 517-528, Nov. 1976.
6. BERGER, J. L. et al. Stability of orthopedic and surgically assisted rapid palatal expansion over time. **Am. J. Orthod. Dentofacial Orthop.**, St. Louis, v. 114, no. 6, p. 638-645, Dec. 1998.
7. BETTS, N. J. et al. Diagnosis and treatment of transverse maxillary deficiency. **J. Adult Orthod. Orthognat. Surg.**, Chicago, v. 10, no. 2, p. 75-96, June 1995.
8. BIEDERMAN, W. A hygienic appliance for rapid expansion. **JPO: J. Pract. Orthod.**, Hempstead, v. 2, no. 2, p. 67-70, Feb. 1968.
9. BYLOFF, F. K.; MOSSAZ, C. F. Skeletal and dental changes following surgically assisted rapid palatal expansion. **Eur. J. Orthod.**, Oxford, v. 26, no. 4, p. 403-409, July/Aug. 2004.
10. CAPELOZZA FILHO, L.; CARDOSO NETO, J.; SILVA FILHO, O. G.; URSI, W. J. S. Non-surgically assisted rapid maxillary expansion in adults. **Int. J. Adult Orthodon. Orthognath. Surg.**, Chicago, v. 11, no. 1, p. 57-66, 1996.
11. GURGEL, J. A.; SANT'ANA, E.; HENRIQUES, J. F. C. Tratamento orto-cirúrgico das deficiências transversais da maxila. **R. Dental Press Ortodon. Ortop. Facial**, Maringá, v. 6, n. 6, p. 59-66, nov./dez. 2001.
12. KENNEDY, J. W.; BELL, W. H.; KIMBROUGH, O. L.; BARRY, J. W. Osteotomy as adjunct to rapid maxillary expansion. **Am. J. Orthod. Dentofacial Orthop.**, St. Louis, v. 70, no. 2, p. 123-137, Apr. 1976.
13. LINES, P. A. Adult rapid maxillary expansion with corticotomy. **Am. J. Orthod. Dentofacial Orthop.**, St. Louis, v. 67, no. 1, p. 44-56, 1975.
14. NORTHWAY, W. M.; MEADE JR., J. B. Surgically assisted rapid maxillary expansion: A comparison of technique, response, and stability. **Angle Orthod.**, Appleton, v. 67, no. 4, p. 309-320, 1997.
15. PERSSON, M.; THILANDER, B. Palatal suture closure in man from 15 to 35 years of age. **Am. J. Orthod. Dentofacial Orthop.**, St. Louis, v. 72, no. 1, p. 42-52, 1977.
16. RIBEIRO JÚNIOR, P. D. et al. Avaliação clínica dos procedimentos de expansão cirurgicamente assistida da maxila (ECAM). **R. Dental Press Ortodon. Ortop. Facial**, Maringá, v. 11, n. 1, p. 44-59, jan./fev. 2006.
17. SCHIMMING, R. et al. Surgically and orthodontic rapid palatal expansion in adults using Glassman's technique: Retrospective study. **Br. J. Oral Surg.**, Edinburgh, v. 38, no. 1, p. 66-69, June 2000.

18. SILVERSTEIN, K.; QUINN, P. D. Surgically-assisted rapid palatal expansion for management of transverse maxillary deficiency. **J. Oral. Maxillofac. Surg.**, Philadelphia, v. 55, no. 7, p. 725-727, 1997.
19. STROMBERG, C.; HOLM, J. Surgically assisted rapid maxillary expansion in adults: A retrospective long-term follow-up study. **J. Craniomaxillofac. Surg.**, Edinburgh, v. 23, no. 4, p. 222-227, 1995.
20. TIMMS, D. J. et al. A study of basal movement with rapid maxillary expansion. **Am. J. Orthod. Dentofacial Orthop.**, St. Louis, v. 77, no. 5, p. 500-507, May 1980.
21. TIMMS, D. J.; VERO, D. The relationship of rapid maxillary expansion to surgery with special reference to midpalatal synostosis. **Br. J. Oral Surg.**, Edinburgh, v. 19, no. 3, p. 180-196, 1981.
22. TURVEY, T. A. Maxillary expansion: A surgical technique based on surgical-orthodontic treatment objectives and anatomical considerations. **J. Maxillofac. Surg.**, Stuttgart, v. 13, no. 2, p. 51-58, Apr. 1985.

Contact address

Paulo Roberto Pelucio Camara
Rua Apeninos 930 cj. 93, Paraíso
CEP: 04.104-020 – São Paulo / SP
E-mail: prpcamara@uol.com.br