

Angle Class I malocclusion with congenitally missing and retention of mandibular second premolars*

Eduardo Silveira Ferreira**

Abstract

This article reports the orthodontic treatment of a 14 year and 6 months old patient that had a Class I malocclusion with an ectopic position and retention of the tooth 45. This case was treated the extraction of the tooth 45 and space closure in the lower arch. Initial, final and post-treatment orthodontic records will be presented and discussed. This case was presented to the Brazilian Board of Orthodontics and Facial Orthopedics (BBO), category 7, free choice, as part of the requirements of achieve the title of BBO diplomate.

Keywords: Angle Class I Malocclusion. Tooth Retention. Congenitally Missing Tooth. Corrective Orthodontics.

HISTORY AND ETIOLOGY

The 14 years old patient presented himself for an initial consultation in good general health, reporting allergy sinus and nasal-oral breathing. He did not report any history of serious illnesses nor trauma. He was in the decelerating phase of the pubertal growth spurt curve and his dental history reported deficient oral hygiene and the presence of marginal gingivitis. His main complaint was the edentulous inferior spaces and the orthodontic treatment was prescribed by his dentist. The patient had not had any orthodontic treatment until this moment.

DIAGNOSES

The patient presented a Class I skeletal pattern with ANB of 1° ($SNA=81^\circ$ and $SNB=80^\circ$) and

increased FMA and Y axis values in relation to Steiner and Down analysis ($FMA=31^\circ$ and Y axis = 64°). This information can be seen on Table 1.

The dental features can be observed in Figures 1 and 2. The patient had a dental Class I relationship with problems (spaces) located in the inferior second premolars region⁵, lower medium line deviation of 1mm to the left, 1mm anteroinferior crowding, 2mm overjet, 3mm overbite and the following teeth (15, 25, 22, 23 and 31) were rotated.

In the facial evaluation, the subject had a slight labial protrusion with lower lip ahead of the upper lip ($UL=1\text{mm}$ and $LL=3.5\text{mm}$). He had passive lip sealment, a slightly enhanced lower facial third and no evident asymmetries nor mandibular functional deviation (Fig. 1).

* Case report, category 7, free choice, approved by the Brazilian Board of Orthodontics and Facial Orthopedics (BBO).

** Ms and PhD in Orthodontics by Federal University of Rio de Janeiro, Brazil; Professor of Orthodontics at Federal University of Rio Grande do Sul, Brazil; BBO diplomate.

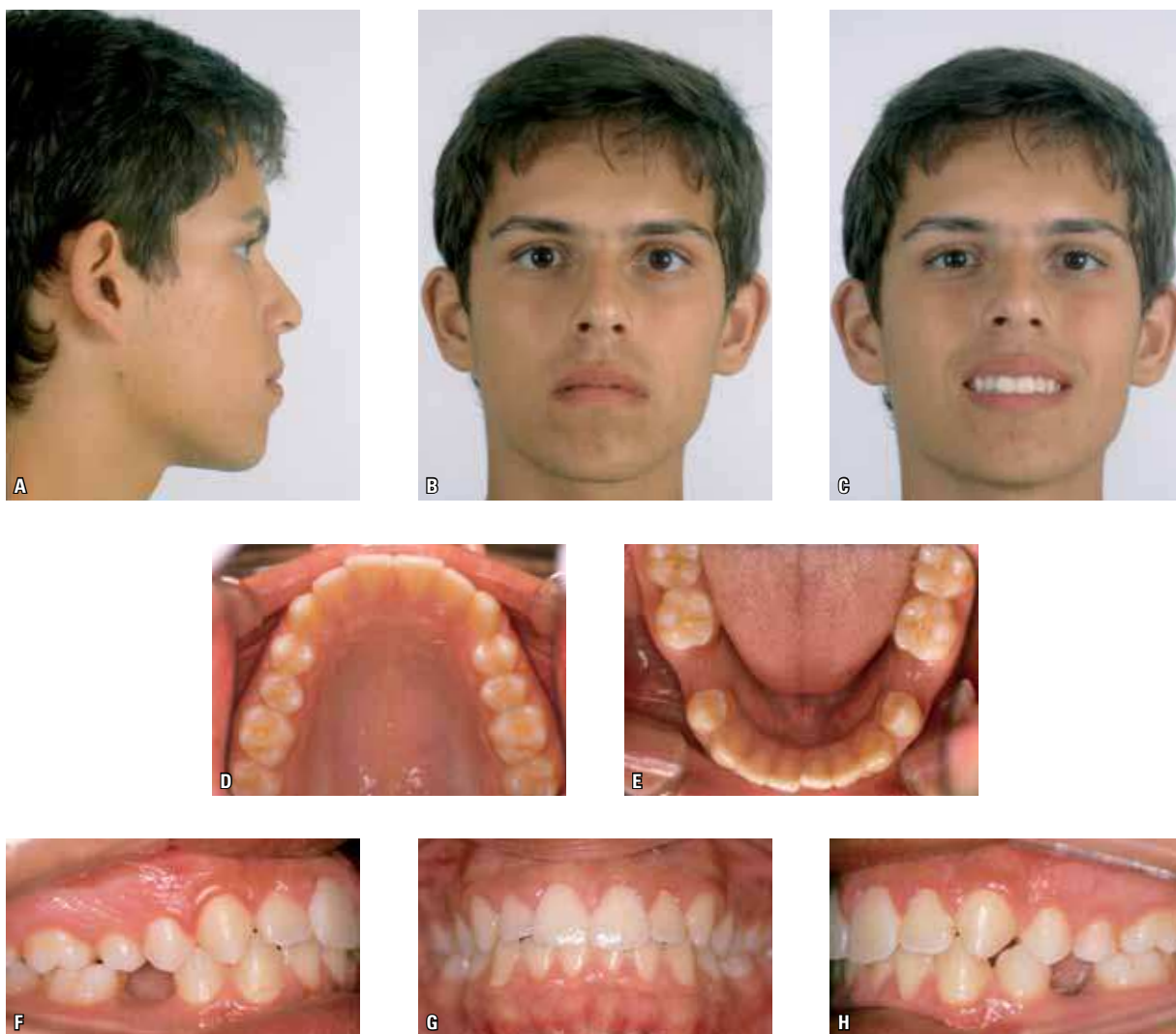


FIGURE 1 - Initial facial and intraoral photographs.

The radiographic evaluation revealed the absence of teeth 35 and 45 and the root resorption of tooth 46 (Fig. 4, 5). Previous panoramic radiographs indicated prolonged retention of teeth 75 and 85, ectopia and cystic lesion in tooth 45 that was later diagnosed as fibroameloblastoma (Fig. 3), upper teeth roots with incorrect axial inclinations and the presence of third molars. The hand and wrist radiograph showed advanced stages of calcification of the phalanges and wrist bones, and the presence of the sesamoid bone (Fig. 6). The lateral radiograph and cephalometric tracing (Fig.

7) revealed a balanced facial growth⁶, clean upper airways, buccal inclined incisors and a straight facial profile. The cephalometric values are presented in Table 1.

TREATMENT GOALS

The goal was to maintain the vertical, transverse and anteroposterior pattern of both jaws. In the upper jaw, the main objective was to level, align and stabilize the teeth for latter use as anchorage unit for Class II elastic mechanics¹⁰. The specific goal for the lower dentition was mesial

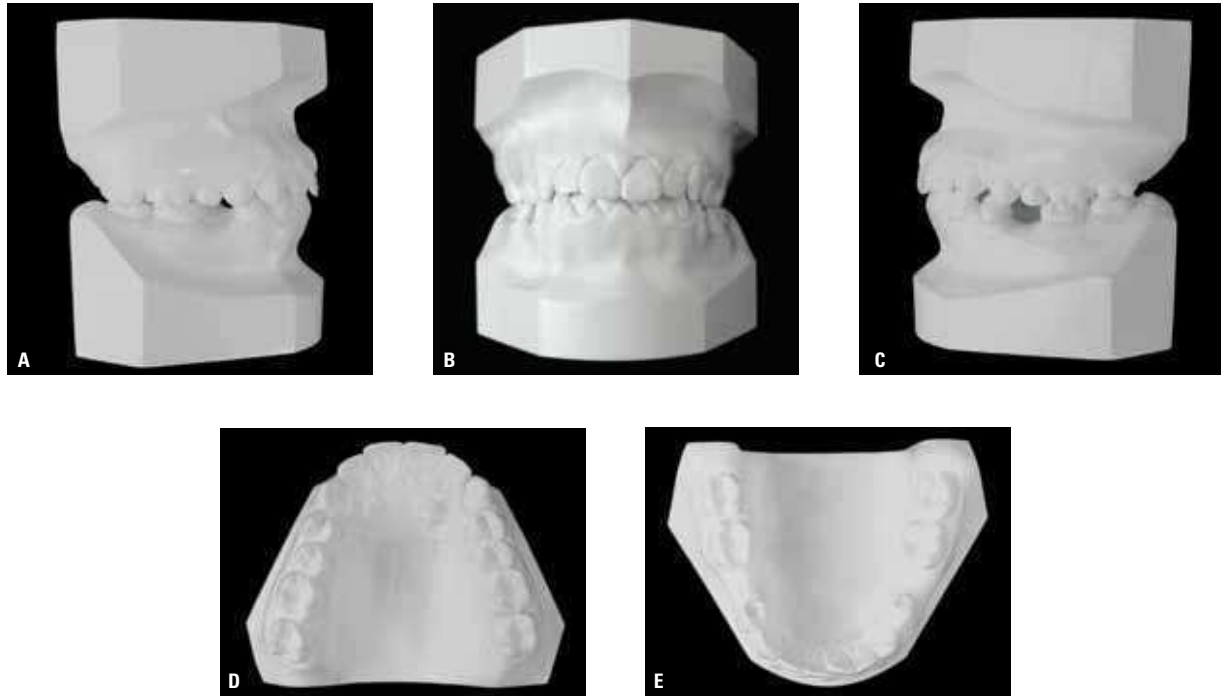


FIGURA 2 - Initial dental cast.

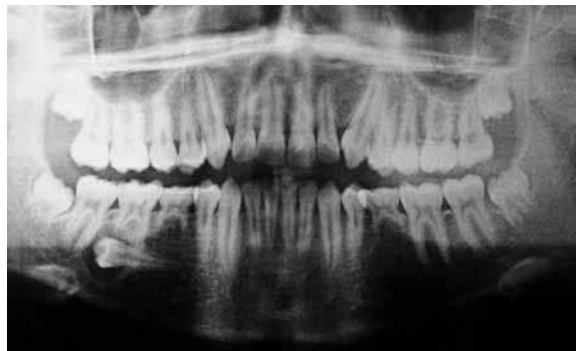

FIGURE 3 - Panoramic radiograph previously to the orthodontic appointment.

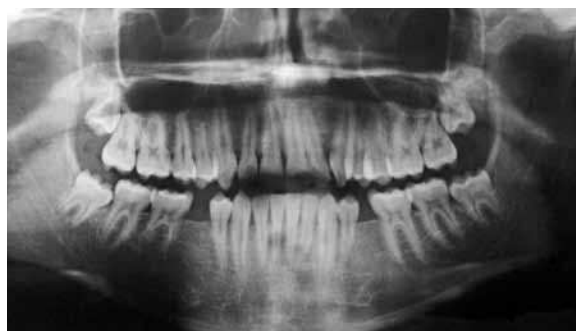

FIGURE 4 - Initial panoramic radiograph.

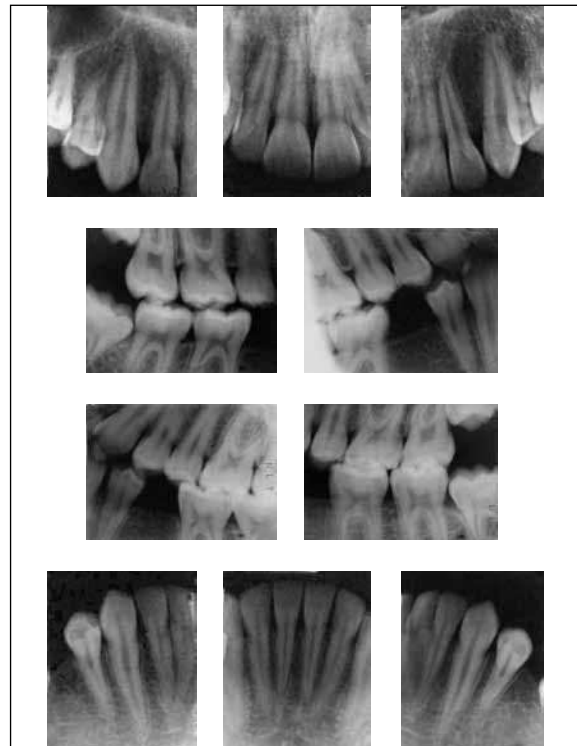


FIGURE 5 - Periapical radiographs of anterior superior and inferior teeth and left and right bitewings radiographs.

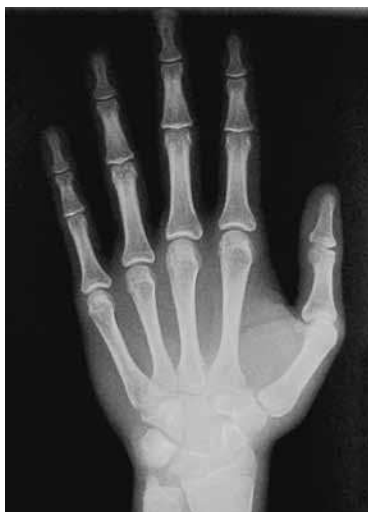

FIGURE 6 - Hand and wrist radiograph.

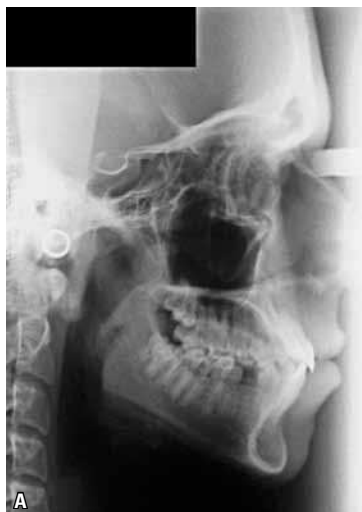
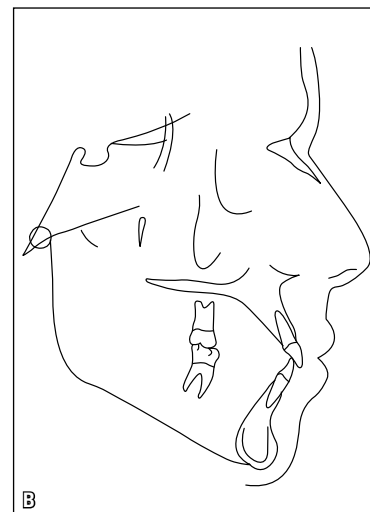
FIGURE 7 - Initial lateral radiograph (A) and cephalometric tracing (B).



movement of molars, leveling of Spee curve, the maintenance of lower canine distance and improvement of the overjet and overbite. Therefore, by the end of the treatment, a molar Class III and cuspid Class I relationship was to be obtained³. The patient rejected the orthodontic treatment proposal of maintaining the spaces for further implants and prosthetics of teeth 45 and 35. Hence, the treatment plan of totally closing the spaces in the region was chosen.

TREATMENT PLANNING

In order to achieve the treatment goals, the patient was informed about the treatment plan which consisted of upper and lower Edgewise appliance, 0.022" x 0.028" slot and 0.014", 0.016", 0.018" and 0.020" stainless steel arches for leveling and aligning. From the 0.020" arch, chain elastic were to be used in order to move mesially the lower molars, keeping the anterior teeth tied-together. Later, this movement would be continued with 0.018" x 0.025" arch and, if necessary, Class II elastics (force magnitude of 180g) would be installed in both sides. For finalization, it was planned the use of 0.019" x 0.026" in both jaws with individ-

ualized bends according to the patient's need^{7,8}. After the active treatment end, a removable appliance (wraparound) made of 0.032" stainless steel wire and a lingual arch bonded to the lower cuspid teeth made of twisted 0.032" wire would be used. The extraction of the upper third molars as well as the bonding of a wire segment in the buccal faces of teeth 46 to 44 and 36 to 34 was not discarded. The patient was formally informed of the needed care of his orthodontic appliances as well as his oral hygiene⁴.

TREATMENT PROGRESS

Orthodontic bands with welded accessories were made for the upper and lower molars. The other teeth were bonded with 0.022" x 0.028" edgewise brackets.

Sequential arches from 0.014" to 0.020" were used for leveling and aligning of both upper and lower teeth. In the lower arch, with 0.020" wire, all anterior teeth as well as both bicuspids were tied-together and the molars were mesialized with the aid of chain elastic. This mechanic was sustained in the 0.018" x 0.025" stainless steel wire. Class II elastics (180g) were used to aid the an-

chorage loss in both sides.

After the lower spaces were closed the case was finalized with 0.019"x 0.026"arches in both jaws.

After all treatment goals were obtained, the fixed orthodontic appliances were removed and the retention phase was initiated. A removable appliance (wraparound) made of 0.032" stainless steel wire and a lingual arch bonded to the lower cuspid teeth made of twisted 0.032" wire were used. The upper appliance was to be used 24h a

day during the first year and to sleep for following year. The lower arch was to be used indetermi- nately.

TREATMENT RESULTS

The patient's final records evaluation (Fig. 8-12) show that the primary goals were achieved^{1,9}. The maxilla was kept in its position and the upper incisors were slightly retracted. The lower molars were moved mesially and their distance decreased from 46.5mm to 43mm, while the intercanine

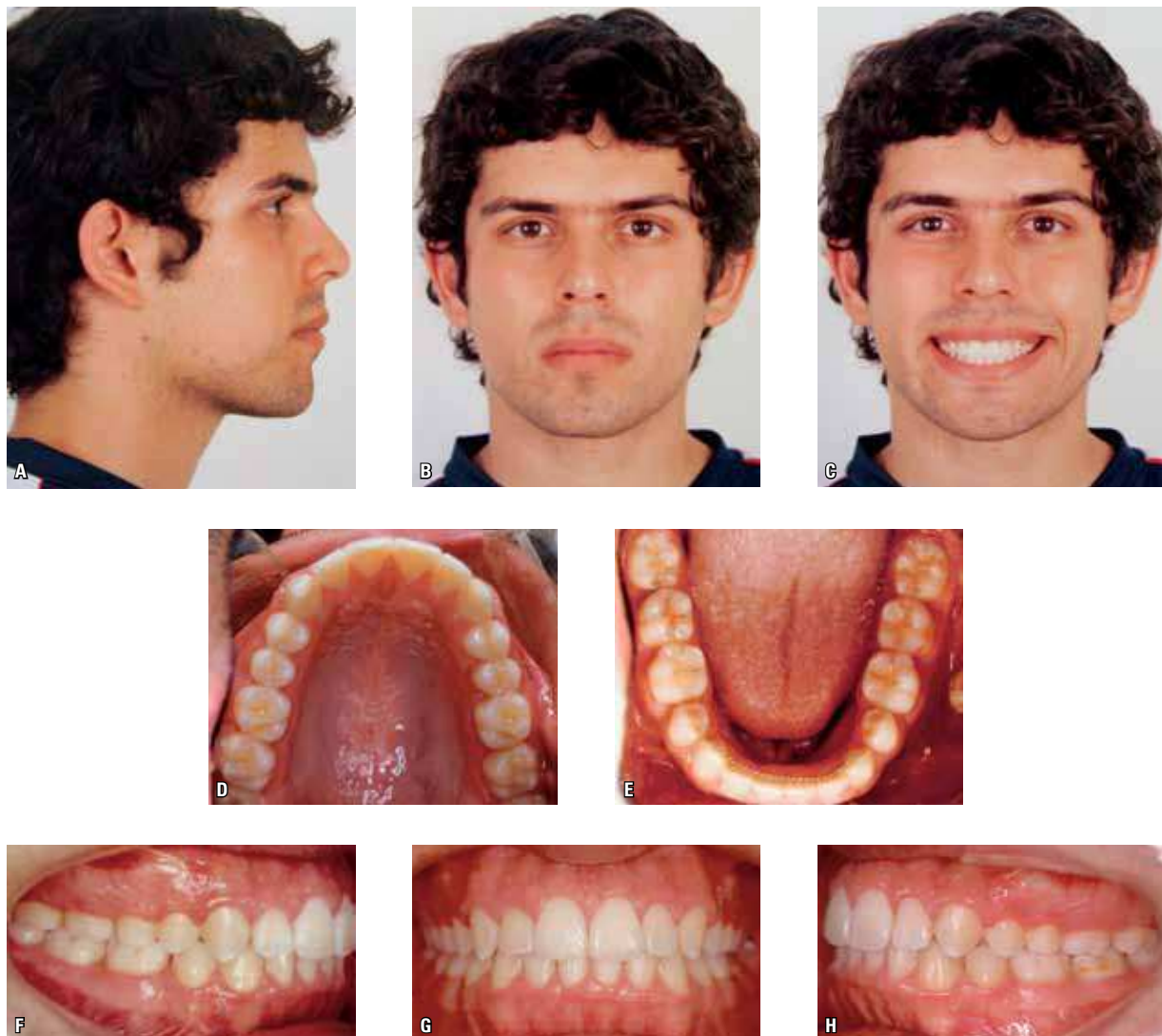


FIGURE 8 - Final facial and intraoral photographs.

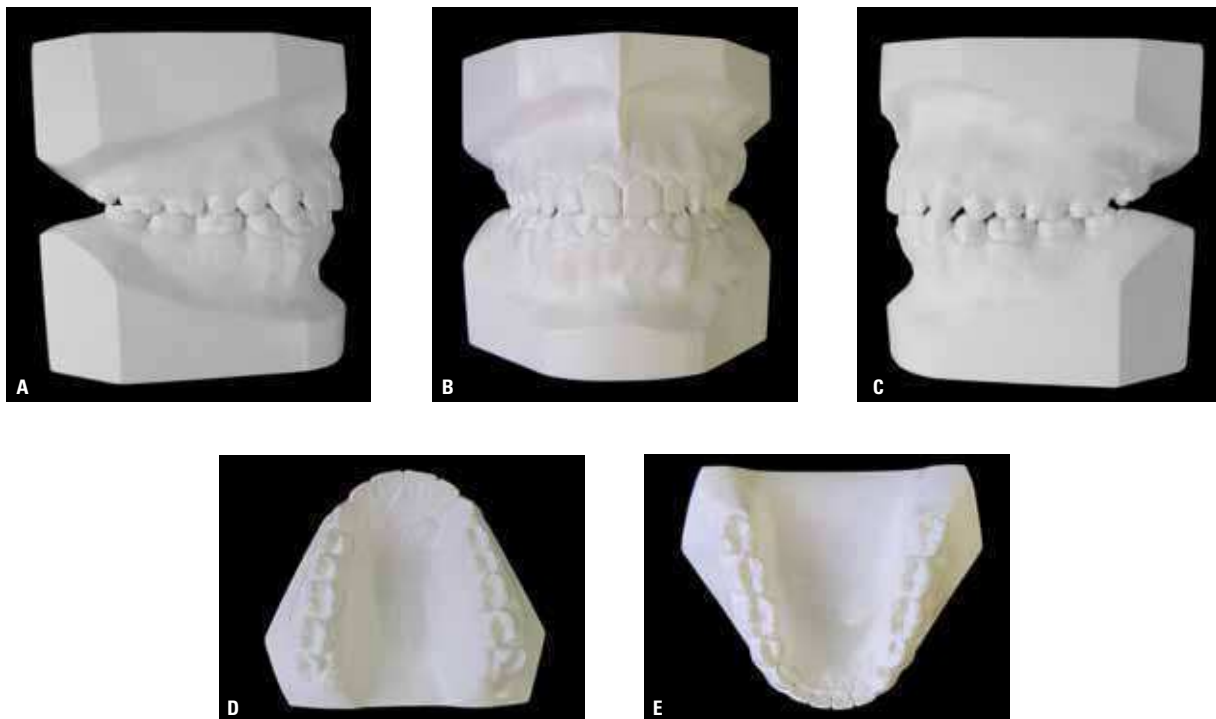


FIGURE 9 - Final dental cast.

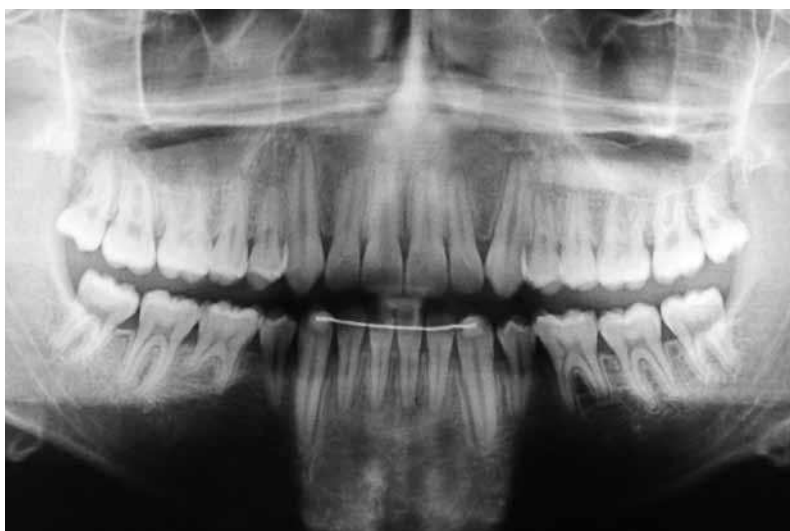

FIGURE 10 - Final panoramic radiograph.

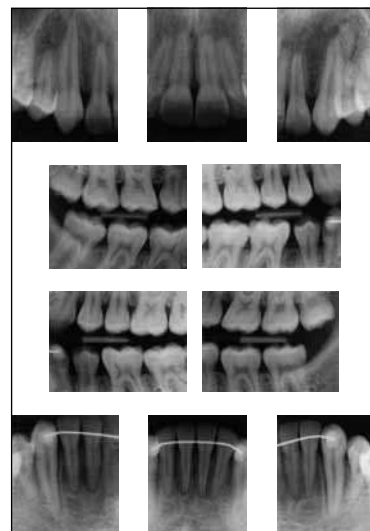


FIGURE 11 - Final periapical radiographs of anterior superior and inferior teeth and left and right bitewings radiographs.

distance was practically kept stable (Table 2). The cephalometric analysis indicated the maintenance of the skeletal pattern, with minor reduction of Y axis and SN-GoGn angle values. There was also a reduction of the linear values and an increase of the incisal angle. In the facial profile, a 1mm and 2.5mm retraction of the upper and lower lip respectively in relation to Steiner S line (Table 1).

In the panoramic radiograph analysis (Fig. 10), a good root parallelism was observed, except in the upper lateral incisors and canine area, and the lesion absence of fibroameloblastoma (tooth 45).

A general rounding of the upper incisors roots was noted as well as significant radicular loss in teeth 36 and 46. The remaining structures were normal, including the third molars, which were already erupted.

The dental occlusion was improved in the molars regions', even with the relationship between upper first bicuspid with lower first molars and upper second molars with lower third molars. The facial aesthetics had no significant alterations and the smile line showed significant improvement with the alignment of anterior

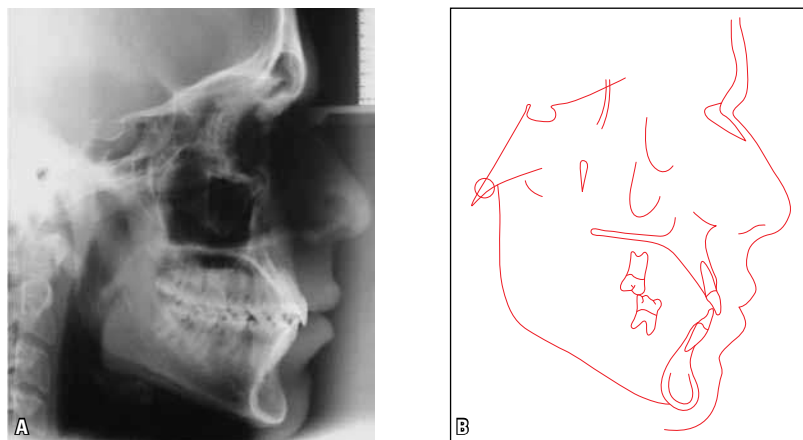


FIGURE 12 - Final lateral radiograph (A) and cephalometric tracing (B).

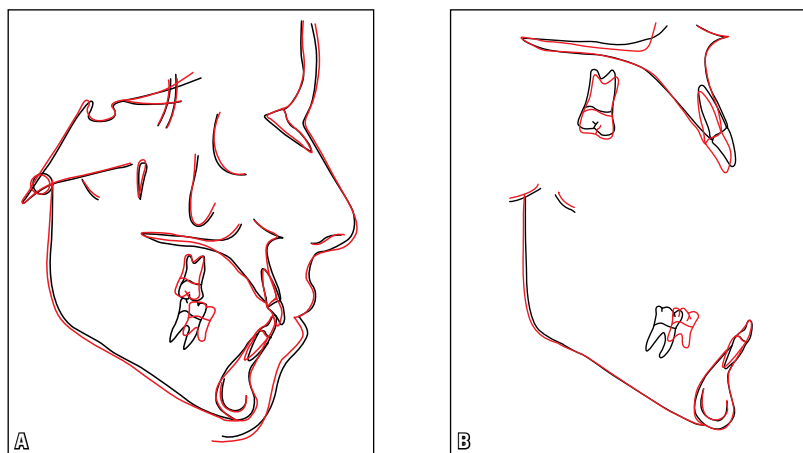


FIGURE 13 - Superimpositions, total (A) and partials (B), of initial (black) and final (red) cephalometric tracings.

TABLE 1 - Cephalometric measurements.

	MEASUREMENTS	STANDARD	A	B	DIFERENCE A - B	C
SKELETAL PATTERN	SNA (Steiner)	82°	81°	81°	0	80°
	SNB (Steiner)	80°	80°	80°	0	80°
	ANB (Steiner)	2°	1°	1°	0	0°
	Convexity Angle (Downs)	0°	-2°	0°	2	-1°
	Y Axis (Downs)	59°	64°	61°	3	62°
	Facial Angle (Downs)	87°	85°	83°	2	86°
	SN – GoGn (Steiner)	32°	32°	30°	2	31°
	FMA (Tweed)	25°	31°	31°	0	30°
DENTAL PATTERN	IMPA (Tweed)	90°	85°	89°	4	89°
	∠ – NA (degrees) (Steiner)	22°	20°	22°	2	21°
	∠ – NA (mm) (Steiner)	4mm	11mm	8mm	3	9mm
	∠ – NB (degrees) (Steiner)	25°	21°	23°	2	22°
	∠ – NB (mm) (Steiner)	4mm	8mm	7mm	1	6mm
	Interincisal Angle (Downs)	130°	133°	134°	1	135°
	∠ – APo (mm) (Ricketts)	1mm	6mm	4,5mm	1,5	5mm
PROFILE	Upper Lip – S Line (Steiner)	0mm	1mm	0mm	1	0mm
	Lower Lip – S Line (Steiner)	0mm	3,5mm	1mm	2,5	0mm

TABLE 2 - transverse distances measurements of both arches (mm).

MEDIDAS	A	B	A - B	C
Lower intercanine distance	29,5mm	29mm	0,5	30mm
Lower intermolar distance	46,5mm	43mm	3,5	42mm
Upper intercanine distance	37mm	38mm	1	38mm
Upper intermolar distance	54mm	54mm	0	55mm

teeth. The total treatment time was 39 months; the upper retention was to be used 24h per day during one year and additional 12 months of nocturnal use.

The records 5 years after the end of orthodontic treatment (Fig 14-18) showed that the relationships obtained, the space closure and the minor increase of the overbite remained stable. The

radiographic evaluation showed that the resorption in the teeth 46 and 36 did not evolve after the ceasing of orthodontic treatment². The upper third molars were extracted and the cystic lesion area presented itself with normal skeletal aspect. The cephalometric values and the distances between molars and canines presented small variation as shown in Table 1.

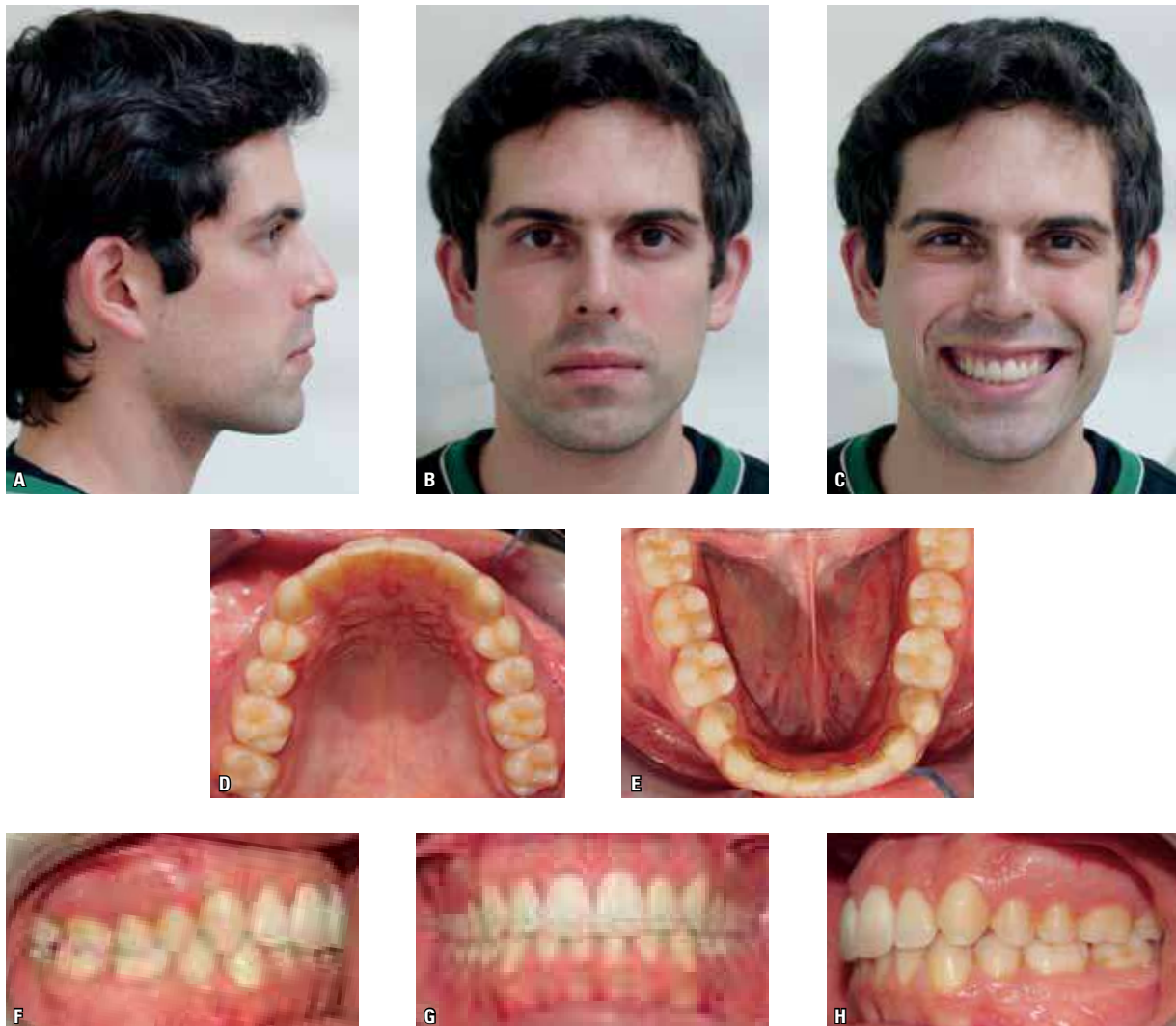

FIGURE 14 - 5 years post-treatment facial and intraoral photographs.

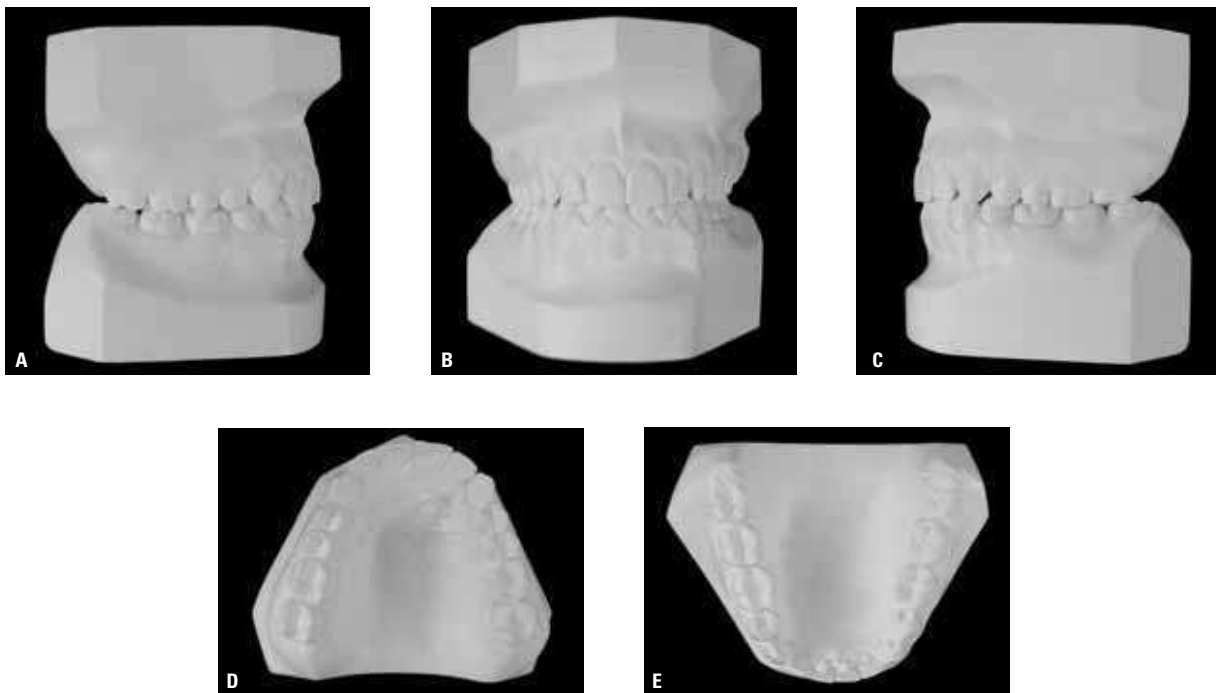


FIGURE 15 - 5 years post-treatment dental casts.

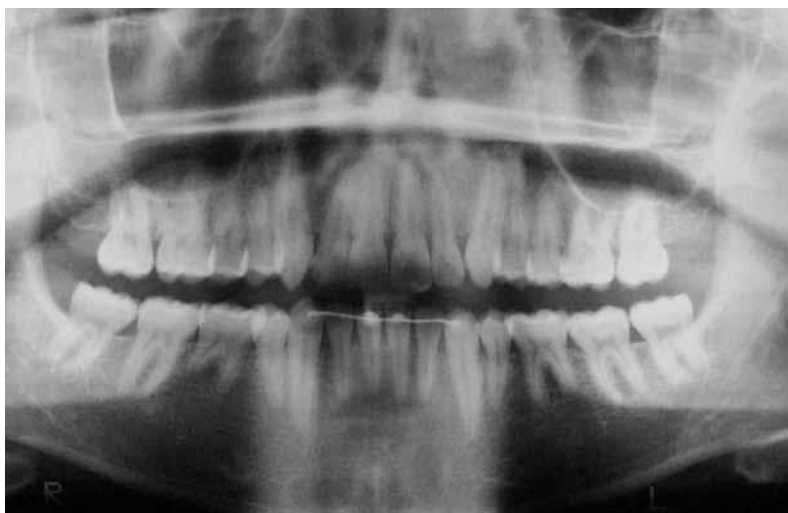

FIGURE 16 - 5 years post-treatment panoramic radiograph.

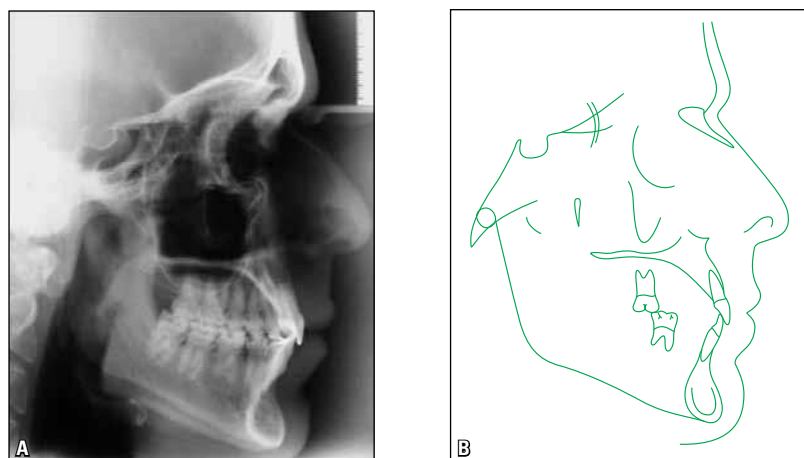


FIGURE 17 - 5 years post-treatment lateral radiograph (A) and cephalometric tracing (B).

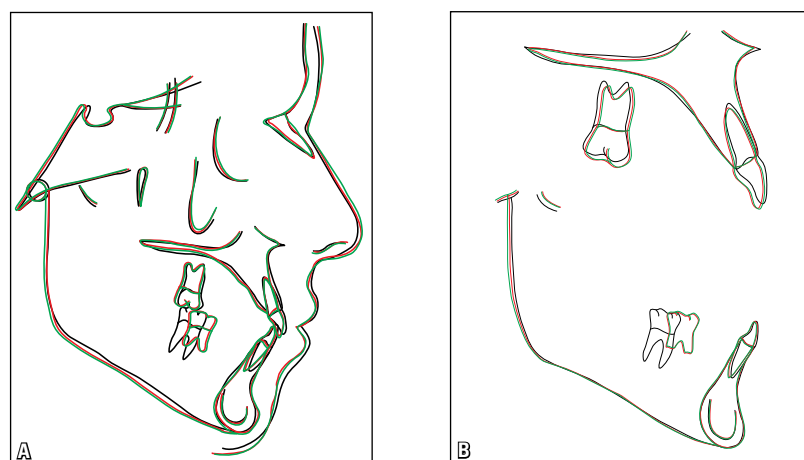

FIGURE 18 - Superimpositions, total (A) and partials (B), of initial (black), final (red) and 5 years post-treatment (green) cephalometric tracings.

FINAL CONSIDERATIONS

The treatment results were obtained by space closure of teeth 35 and 45. The patient used all orthodontic devices and was responsible in fulfilling his duties. His parents were informed about the delicate situation of the root resorption of tooth 46 due to its cystic lesion and orthodontic movement, which might result in its extraction and future implant replacement. The records after 5 years after the removal of the orthodontic appliances show the stabilization of the tooth 46 situ-

ation. Radiographic control was made during the entire treatment period (Fig 12B). The lower left first molar also presented root resorption due to the great mesial movement until reaching tooth 34. The superimposition of the cephalometric tracings shows the facial pattern evolution associated with the orthodontic mechanics described in the treatment planning (Fig. 13, 18). The patient is still being controlled by the surgeon responsible for the lesion removal before the beginning of the orthodontic treatment in order to diagnose any relapse.

Posted on: August 2009
Revised and accepted: September 2009

REFERENCES

1. ANDREWS, L. F. The six keys to normal occlusion. **Am. J. Orthod.**, St. Louis, v. 62, no. 3, p. 296-309, Sept. 1972.
2. CONSOLARO, A.; CONSOLARO, M. F. M. O. **Controvérsias na Ortodontia & atlas de Biologia da movimentação dentária**. 1. ed. Maringá: Dental Press, 2008.
3. DAWSON, P. E. **Avaliação, diagnóstico e tratamento dos problemas oclusais**. 2. ed. São Paulo: Artes Médicas, 1993.
4. GRABER, T. M.; VANARSDALL, R. L. **Ortodontia: princípios e técnicas atuais**. 3. ed. Rio Janeiro: Guanabara Koogan, 2002.
5. KOKICH, V. Early management of congenitally missing teeth. **Semin. Orthod.**, Philadelphia, v. 11, no. 3, p. 146-151, Sept. 2005.
6. LANGLADE, M. **Cefalometria ortodôntica**. 1 ed. São Paulo: Ed. Santos, 1993.
7. LIMA FILHO, R. M. A.; BOLOGNESE, A. M. **Ortodontia: arte e ciência**. 1. ed. Maringá: Dental Press, 2008.
8. PROFFIT, W. R.; FIELDS JÚNIOR, H. W.; SARVER, D. M. **Ortodontia contemporânea**. 4. ed. Rio de Janeiro: Elsevier, 2008.
9. STRANG, R. **Tratado de Ortodontia**. 3. ed. Buenos Aires: Ed. Bibliográfica Argentina, 1957.
10. TWEED, C. H. **Clinical Orthodontics**. St. Louis: C.V. Mosby, 1966. v. 1.

Contact address

Eduardo Silveira Ferreira
Rua Dona Laura, 87 conjunto 301 – bairro Rio Branco
CEP: 91430-091 – Porto Alegre / RS
E-mail: clinicaferreira@terra.com.br