


Roberto Carlos Bodart Brandão

- Bachelor in Dentistry – UFES, 1987.
- Master's in Orthodontics –UFRJ, concluded in 1991.
- Doctorate in Orthodontics – UNESP/Araraquara, concluded in 2000.
- Professor of Orthodontics – UFES, since 1991.
- Professor of the Specialization Course in Orthodontics – FAESA.
- Charter member of the BBO, since 2005.
- Vice-president of the Brazilian Orthodontics Association – Espírito Santo Section (ABOR-ES).
- Consultant of the Dental Press Journal of Orthodontics and Facial Orthopedics.
- Has given more than 200 lectures and courses, has had articles published in Orthodontics and Aesthetics journals.



I would like to invite our dear readers to enjoy the knowledge – resulting from his clinical experience and scientific fundamentals – of an icon of Brazilian orthodontics. Prof. Roberto Carlos Bodart Brandão demonstrated, in his answers to the interviewers, profound knowledge and unique confidence while discussing the issues of disjunction, finalization, aesthetic excellence, occlusion, selective grinding and retaining. A sports fanatic, particularly nautical sports, Prof. Roberto regularly goes deep sea fishing, in addition to occasionally practicing windsurf and tennis. Restless, curious and very critical – especially of himself – he looks for his mistakes every day in order not to repeat them. He enjoys technology, but believes his profession is art and background. He also enjoys cooking, especially for family and friends, who are, according to him, his “greatest wealth”. He is the son of Aloayr da Silva Brandão and Wilda Bodart Brandão (he, a general dentist, retired, one of those who worked from 7 am to 9 pm with two jobs and a private practice – tireless; she, a retired grade school teacher, who rose rapidly to become principal of a public school, through her competence and seriousness, a charismatic leader). Dr. Roberto works from his private clinic, located in Vitória/ES, where he works alongside his wife Larissa – also an orthodontist, a graduate from Universidade Federal Fluminense. I wish you all an excellent scientific contact with this five-star orthodontist.

Telma Martins de Araujo

Do you employ expansion followed by contraction – O senhor emprega a expansão seguida de contração, tão defendida na atualidade, como auxiliar na maxillary protraction? Telma Martins de Araujo

The results of the studies have been positive, and I have included this practice in my cases of Class III malocclusion with maxillary retrusion, stimulated especially by the studies of Dr. Liou, who pioneered the technique¹³. As I do not have access the double-hinged expander developed by the author, I use the conventional Haas expander. After the expansion and contraction period (seven weekly cycles), I begin protraction using an orthopedic facemask. The casuistry, while still limited, is positive for this protocol, but we need more long-term studies to consider the stability of those results. The early treatment of Class III is one of the greatest accomplishments of orthodontics, and all effort and knowledge must be applied to correct and control growth, even when we know many cases will end up in surgical procedures, which should be clearly explained to patients and guardians.

What is your experience with non-surgical expansion in adult patients? Telma Martins de Araujo

Scientific evidence shows that closure of the midpalatal suture occurs around the age of 16 for girls and 18 for boys; in the same study, however, open sutures were found in cadavers up to 27 years of age¹⁵. Based on these findings, I adopt a rather uncommon clinical approach for some cases of transverse maxillary deficiency. I usually attempt rapid maxillary expansion in patients up to 23 years old, depending on their individual characteristics. In these patients with posterior crossbite, I evaluate the thickness of the buccal bone plate in the maxillary arch, which should not feature salient root contours to the touch, and check the degree of synostosis of the midpalatal suture, which can be evaluated using occlusal radiography, or even better, through volumetric tomography. I use Dolphin

Imaging software to reconstruct tomographic images; I believe in an improvement in the resolution of these images in the short-term, as they have not yet proven to be reliable. In the cases where the images suggest the suture has not fully closed, I make use of the Hyrax appliance activated four times a day during four or five days. I then reevaluate the patient, and if a diastema has developed between the maxillary central incisors (a clinical sign of expansion), I move on to activation twice a day, following the conventional protocol, until achieving overcorrection of the transverse problem (Fig. 1). I regard late expansion as a valid attempt, with which I have achieved a lot of success, but I know I have not reached the best possible scientific evidence for that practice. If expansion does not occur, the patient is previously informed of the need for surgically assisted rapid maxillary expansion (SARMA). Most patients prefer the clinical treatment, if possible, before the surgical solution.

How do you evaluate the incorporation of torque in posterior teeth, during the initial or advanced stages of treatment, using the same prescription of pre-adjusted brackets or the same pattern of bends on orthodontic arch wires for all patients? Jonas Capelli Junior

This question requires a reflection, and I shall divide the answer into two parts. First, I will discuss the concerns I have with torque during orthodontic treatment. I am very self-critical, and I believe I learn more from my mistakes than with my successes. During my practice, I have observed that incorporating undesirable torques leads to significant delays in treatment, as well as potential iatrogeny. In that context, I recommend all clinicians observe the torques in the posterior teeth of their patients prior to treatment and also after the leveling phase using round arch wires. The torques of posterior teeth are normally just fine in both cases. Therefore, there is no need, in most patients, to incorporate torques, but there is a need to control them. Therefore, we would make a mistake if we incorporated

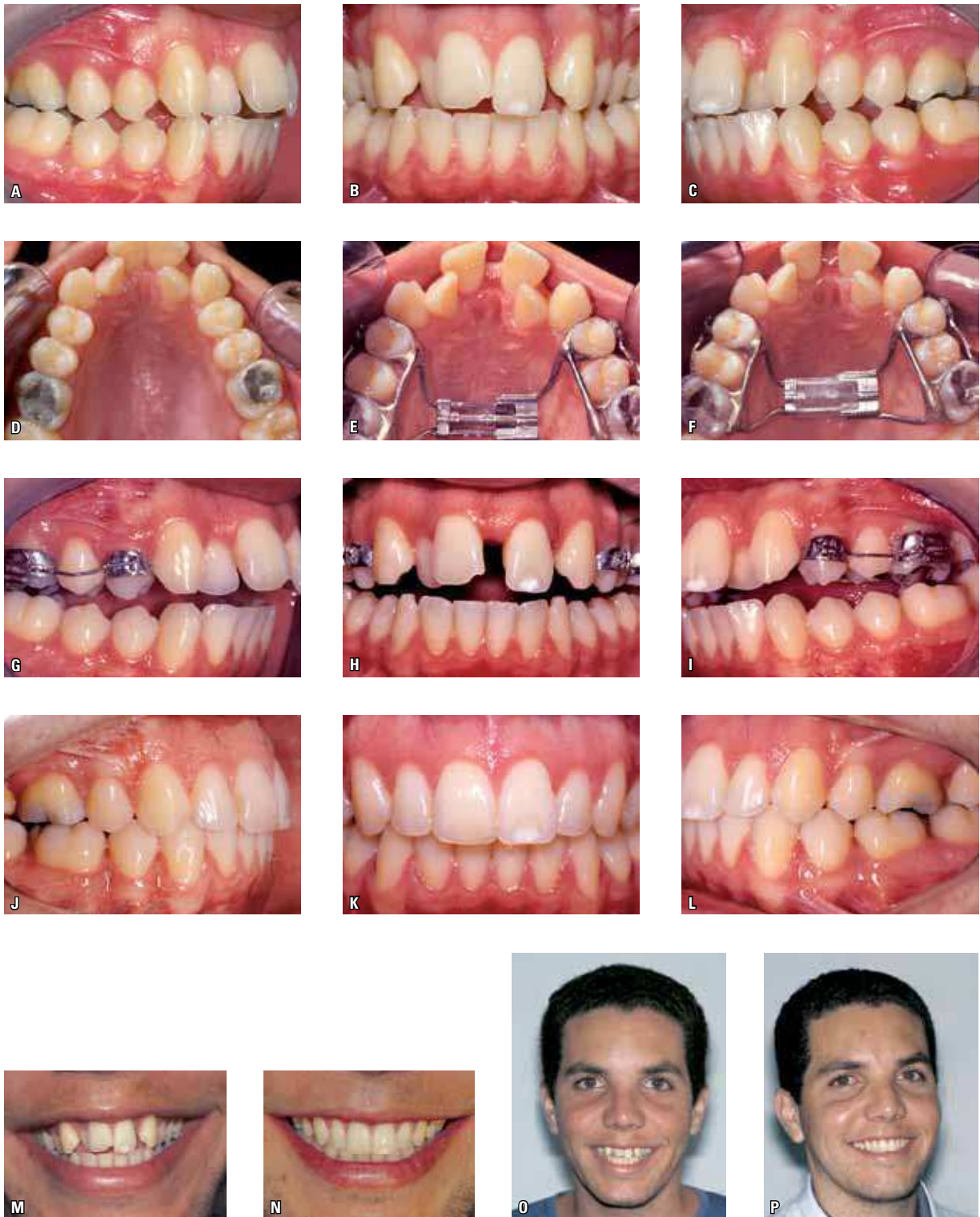

FIGURE 1 - **A, B, C, D**) 23-year-old patient, with posterior bilateral crossbite associated with a Class II division 1 malocclusion, anterior open bite. **E, F**) Correction of transverse problem through late maxillary disjunction, without surgical assistance, using the Hyrax. **G, H, I**) Result of the disjunction, with bite opening, temporary. **J, K, L**) Final result obtained with fixed appliances. In order to correct the Class II, the maxillary first premolars and mandibular second premolars were extracted for a camouflage effect. **M, N, O, P**) Smile comparison, before and after correction, purely clinical.

root movements where they are not necessary. This observation is far from forgoing the use of rectangular arch wires in treatments, but it defines that their use should be preceded by an important judgment. Prior to setting a rectangular arch, one should question whether there is the need to make root movements in posterior teeth. As the answer is usually no, the arch should be passive in those teeth. This is only effectively achieved if an “arch reading” is done prior to setting. The worst could happen if the torque indicated for a molar were the opposite of that resulting of standard Edgewise bend or a Straight-wire prescription. This simple procedure, of “arch reading”, avoids two serious problems: (1) by incorporating an undesirable buccal root movement in posterior maxillary teeth, this leads to a reduction in periodontal thickness, adding a risk of periodontal recession, and at the same time, contraction of the maxillary arch, possibly resulting in a posterior crossbite; (2) if the movement is lingual by the root of the same teeth, there will be extrusion of the palatal cusp, and consequently an open bite (Fig. 2). For any of these situations, a problem is added or aggravated in the malocclusion, demand-

ing time and mechanical effort that were previously unnecessary².

The second part of the answer concerns the use of pre-adjusted appliances, using an author’s judgment as a finished solution. We need only observe the countless number of appliances available in the market, and each author’s declarations favoring their own product and pointing out the problems with the competition, to suspect these ready-made solutions. The search for the perfect appliance is limited by the diversity in tooth shapes and dental arches that can be considered normal. A geometric progression would explain the variety of situations and the impossibility of finding a solution that could fit perfectly into a single case. Variation in human occlusion is the rule, and not a given average applied to determine the torque and angling of a prescription. Additionally, there is the variation in the torque result whenever the height in which a bracket is bonded is changed (Fig. 2). The idea of perfect techniques only find space when there is no scientific basis – and that goes both for pre-adjusted appliances and conventional techniques (Edgewise, Ricketts), when critical thinking is not used before

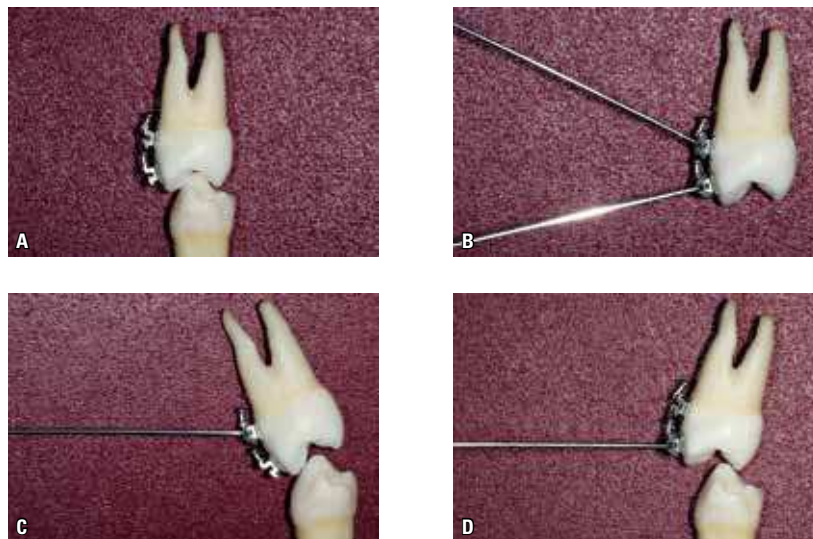


FIGURE 2 - A) Bonding of two same prescription brackets at different heights on a premolar crown. B) Verify the opposite effects of root torques when wires are placed orthogonally to the brackets. C) Root buccal torque effect in the more apical bracket, with a potential contraction of the arch and risk of periodontal recession. D) Opposite effect on the occlusal-bonded racket, root lingual torque, creating premature contact and potential open bite. Although they represent extremes, these figures show how much the effect of torque incorporated into the brackets is dependent on tooth morphology.

any procedure. It is certainly easier to win the lottery than find an appliance that can treat a malocclusion, with quality, in the hands of an orthodontist without the proper qualifications. Professional qualification demands hard training, obtained only in specialization courses with at least 2,000 hours in the classroom. Unfortunately, the lack of management in Brazilian orthodontics has led many to consider normal specialization courses with three days a month, with a class load that until recently would not even be acceptable for refresher courses. What has changed? In the rest of the world, nothing – the number of courses has decreased, with only those with higher quality remaining, prioritizing critical thinking by the orthodontist, and not the technique. In Brazil, there is desperation, excess of dentists, lack of patients, the low compensation and low quality in education... in short, lack of management. That is the great challenge of ABOR – to take the responsibility of managing the field of orthodontics, as happens with medicine in Brazil and orthodontics in the United States, where organized specialists are the managers of their specialties. It is a battle that should be fought by all orthodontists, organized, giving support to ABOR and BBO, as that is the only solution.

Your training was in “standard Edgewise” and, after a few years, you migrated to “Straight-wire”. What you would say to orthodontists who still practice only “standard Edgewise” and, likewise, to schools and orthodontists who are educated only in straight-wire? Luiz G. Gandini Junior

Indeed, my initial education was at UFRJ, which has a curriculum based on the Edgewise technique, intensively and extensively reviewed and revised. I believe that is one of the main reasons I am in this privileged position, answering questions made by prominent professionals in Brazilian orthodontics. I have a visceral bond with my professors at UFRJ, of whom I would highlight four names: Professor Alderico Artese, for his innovative and sagacious spirit;

Professor Carlos Teles, for his straight conduct; Professor Ana Maria Bolognese, for her determination towards scientific evidence; and lastly, Professor Nelson Mucha, who is an icon of excellence, who has inspired an entire generation of orthodontists. I definitely believe that students need guidance, a consistent education that combines critical thinking, knowledge and training, aiming for the best possible professional judgment. As such, building an orthodontic plan based on consistent techniques, which require great control over the wire and dental accessories – such as the Edgewise, Ricketts and Segmented Arch techniques – is precious and essential in the education of an orthodontist. In fact, the solution for each problem in orthodontics should lie within the orthodontist, and, to that end, there is the need for a long and thorough education, in addition to dominating a technique, and not being a hostage to it. Unfortunately, recent graduates seek the shortest route, and are led to specialization courses, even Master’s degrees, in which they are trained like technicians of a straight-wire factory. When faced with the reality of clinical practice, they discover that, without a solid basis, it is not possible to build a career, and they lose themselves in more courses and new techniques. Five years ago, after 15 years in orthodontics, I opted for the use of pre-adjusted brackets. I don’t consider I have changed techniques, as I continue to use loops and resources based on Edgewise. I consider all prescriptions of what is known as “Straight-wire” to be, in fact, variation of the Edgewise technique. With the use of pre-adjusted appliances, I believe I made my clinical life easier, especially in the early stages of treatment, and I have noticed, more than ever, that any prescription has its limits. Certainly, one who is trained only in Edgewise and masters the technique, is able to use any straight wire prescription. The opposite is not true. For all that, I consider it absolutely essential that an orthodontist’s initiation be through techniques featuring a scientific basis, exhaustive training and a long history of success, such as the Edgewise technique.

After your doctorate in Araraquara, you began to apply the Segmented Arch Technique. How did that alter your orthodontic life, and what is the role of that philosophy within your practice today? Luiz G. Gandini Junior

I am very thankful to the faculty and friends who welcomed me at Unesp-Araraquara, which was essential to my scientific and personal ascent. Scientifically, I learned and discussed the segmented arch technique (SAT), which was valuable in the understanding I currently have of the biomechanics involved in orthodontics, so that I was able to understand and correct my mistakes. To understand the concept of statically determinate movement and the six geometries of statically indeterminate movement helped me determine the force and momentum produced on each tooth, which can generate desirable and undesirable effects in each activation of the appliance¹⁷. We should consider that much that happens in the use of continuous arches is linked to back-and-forth tooth movements. Thus, in the sequence of wire replacements, we end up fixing the problems we have previously caused, losing time and leading to cases of malpractice. That is eliminated when I apply the concepts

and resources of SAT in tooth movement³. I have incorporated the routine use of a palatal arch and Nance appliance as parts of the two- and three-piece device, using a cantilever, retractions loops, intrusion arch, among other resources, prior to or concomitantly with the use of continuous arches (Fig. 3). The use of the cantilever allows for greater inter-bracket distance and greater activation amplitude using a rectangular loop. Consequently, the force is reduced and control over movement is increased, which quickly corrects the rotation of the canines, without sequelae. In short, after I gained extensive knowledge of SAT, I understand the Edgewise technique much better, and I have more resources to avoid or revert undesirable effects. On the personal side, I learned a lot about teamwork. The attentive manner in which I was treated as a student makes me believe it was a privilege for me to have done my doctorate work in Araraquara. I cannot forget how I was impacted by professor Joel Claudio da Rosa Martins, who gave the sample for my doctorate thesis, and from whom I draw inspiration when I try to be a better professional and when I need to rekindle my dedication and respect for orthodontics.

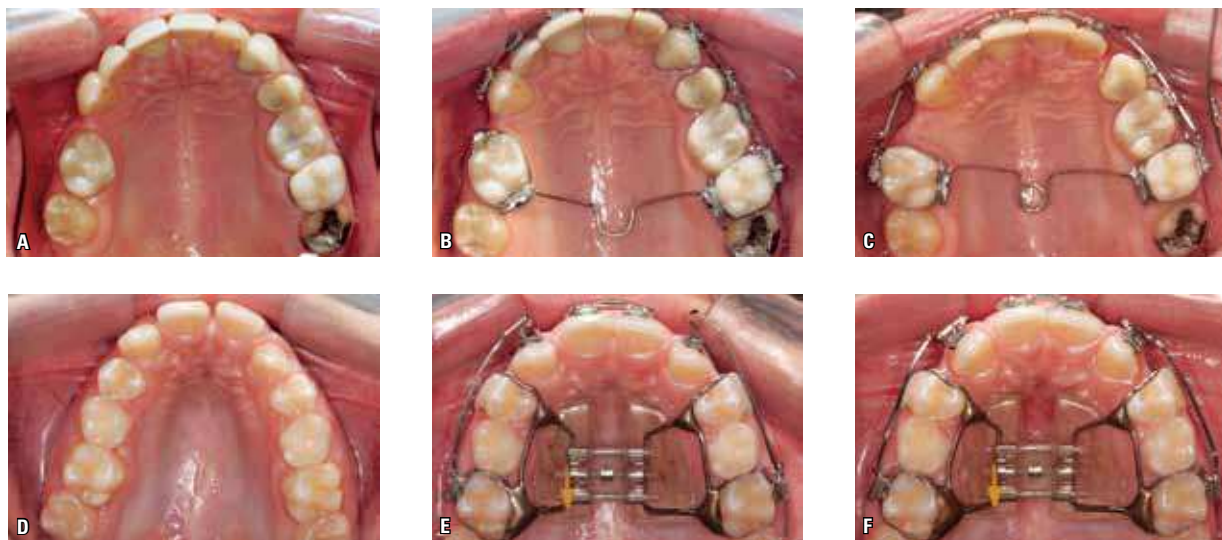


FIGURE 3 - A, B, C) Correction of rotation in tooth 16, with a palatal arch, using the entire maxillary arch as anchorage, optimizing the effect of biomechanics. **D, E, F)** Case of absence of lateral incisors: correction of rotation of canines using rectangular TMA wire in a cantilever with rectangular loop, simultaneous with the mesial movement of the crown and root. The use of these resources prevented the application of excessive and undesirable forces on the incisors.

Assembling an orthodontic appliance is a meticulous procedure that requires care. In your view, what are the most critical points of that stage and which can result in time delays and complications during the finishing phase? Roberto Rocha

Finishing is guided by a philosophical principle that should be within each orthodontist: a treatment should not be planned starting from a malocclusion, but rather with a clear for a perfect occlusion. Improving a malocclusion, straightening teeth, is not the true profession of an orthodontist; reaching an occlusion with adequate aesthetics, function and stability is. Therefore, finishing a treatment begins during planning and appliance assemblage, and not in the last few months of orthodontic treatment. I believe that bonding is one the main determinants of a good finishing phase. Usually, an orthodontist has a formula for bonding with pre-set heights for each tooth, and uses instruments that use the cusp tip or incisal edges of teeth as parameters. It is as we normally learn: 3.5mm for molar, 4mm for premolars, and so on, varying the magnitude of the numbers depending on the instructor or professional. The use of height measurement

instruments makes it much easier, but what truly happens is the establishment of a standard error. It is easy to understand how the error is recurrent, because the parameter is incorrect. What we want to achieve when assembling the appliance is not to level the cusp tips of posterior teeth, but rather to level the marginal crests and contact points. In the case of anterior teeth, in addition to the contact points, we want to define the ideal overbite, incisal exposure and smile curve^{16,27}. Therefore, these should be the parameters to define bonding height, by combining tooth morphology with the ideal occlusion and best possible aesthetics. I have my own way of assembling the appliance, using an essential principle: individualization (Fig. 4). I regard the first molars as the anchor teeth, for their simple roots and crown, and because they are the first to be set with the bands, when I solder the accessories tangent to the occlusal edge of the band, at the same height as the opposite hemi-arch. I then go on to bonding the second premolars with the necessary height difference to level the marginal crests. For example, if I need to extrude these teeth by 1mm, that will be the height difference to the first molar. I can use any instrument to check, without being

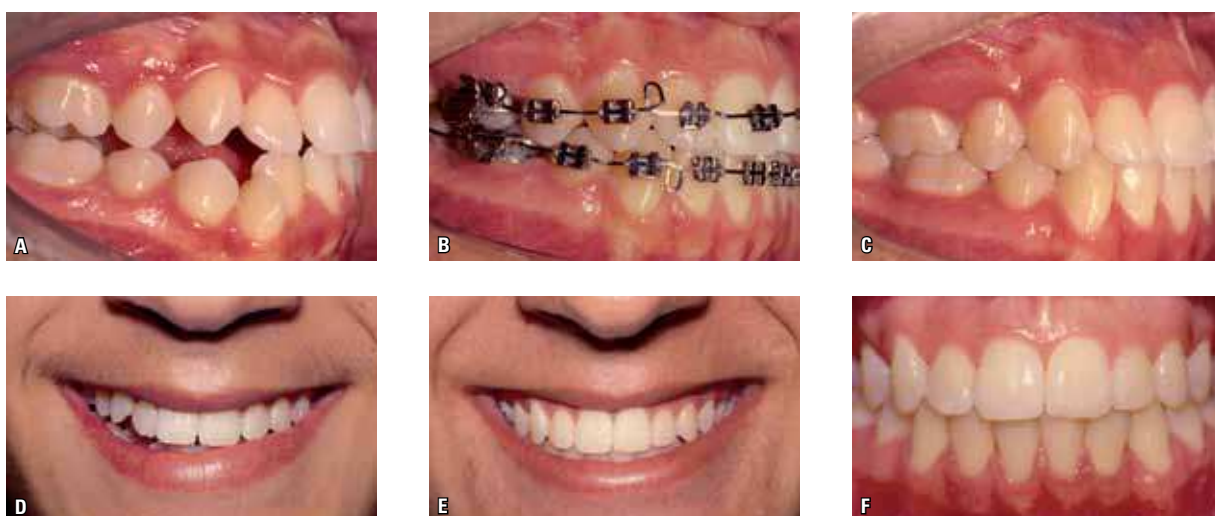


FIGURE 4 - A, B, C) Before, during and after evolution of the treatment for dental crowding, in which, although the cusp tips of 16 and 14 were leveled before treatment, there was need for extrusion of 14 to level the marginal crests. D, E) Smile, before and after. It can be noticed that the necessary extrusion of the right-side teeth was obtained, so that the smile curve could be corrected, obtaining interproximal contacts parallel to the sagittal plane. F) Frontal view of the final occlusion.

limited by fixed numbers, or I can use only my visual perception. Similarly, I use the second premolars as reference to bond the first premolars, based on the ideal contact point – which is the main objective of orthodontics – and not at the buccal cusps, as they are variable and non-crucial to the treatment. The bonding of anterior teeth defines the correction or maintenance of the exposure of these teeth at rest, phonation and during smiling. Therefore, it defines how the overbite should be corrected. At that stage, extra care is required, as the intrusion of anterior maxillary teeth tends to age the face. I work with a perception that defines the dominance of the central incisors in the smile, without forgetting that the smile curve should follow the outline of the lower lip^{10,25}. In cases where there is incisal wear or non-permanent prosthetic work, the gingival contour should be prioritized, with vertical tooth movements without periodontal fibrotomy, as explained in our article published in the Dental Press Journal of Aesthetics²⁸.

In cases where the maxillary lateral incisor is absent, what are your treatment options and suggestions to optimize the outcome? Roberto Rocha

First of all, it is necessary that the patient and guardians be completely informed of the treatment possibilities, as they perception and personal desires are determinant to define the therapeutic approach. Such information is followed by a suggestion, indicating of the three following strategies: implants, self-transplants, or canine mesialization, with defined parameters. In pre-adolescents, especially when there is a gingival smile, I try to discard the implant option, as there is still active vertical growth, and as facial growth continues after the stop of body growth, continuing up to age 23, we would be condemning the patient to spend his teenage and young adult life with edentulous gaps or temporary prosthetics, compromising aesthetics and retention^{11,21}. Moreover, there is the difficulty in determining the end of facial growth, as one mil-

limeter is not much for a treatment, but is a lot for relapse²⁶.

I consider gap closure to be the best option, even if not the absent lateral incisor. I will explain. The option that pleases me the most is the tooth self-transplant. I have recently incorporated it into my clinical practice, based on what the Denmark group have shown, and on the works of professors João Batista Gagno Intra and Armelindo Roldi from the endodontics department at UFES, along with professor Consolaro at FOB-USP^{4,7}. It is actually not a new technique – it is 50 years old, compared to the 25 years osteointegrated implants have been in clinical use. In our specific case, we shall use the best from each conventional option: (a) the canine retains its form and function, in its natural position, as in the implant option; and (b), a tooth is used to construct, either with restorations or prosthetics, the crown of a lateral incisor, which will follow the vertical growth of the face, erupting naturally. It is a simple, although precise, surgical procedure, in which the site is opened using the same drill used for implants, with reduced speed, and whose diameter and depth should be guided by volumetric tomography (Fig. 5). Usually, premolars that have not yet erupted are chosen as donor teeth, with 2/3 or the root (or slightly more) – of those, I consider mandibular teeth to have a more adequate root form. The tooth should be splinted from adjacent teeth, with a low rigidity wire, for one or two months, and force can be applied starting in the fourth month, as recommended by Dr. Paulsen¹⁹. In most cases, there is a progressive closure of the pulp chamber of the transplanted tooth, with no need for endodontic treatment^{4,7,19}. I believe that, with the use of the temporary anchorage devices, the closure of the posterior space of the transplanted tooth is much simpler than the mesialization of canines in the anterior area. Lastly, we remind that an implant requires bone, whereas a self-transplant creates bone.

Whenever the self-transplant is not possible, canine mesialization should be considered. In those

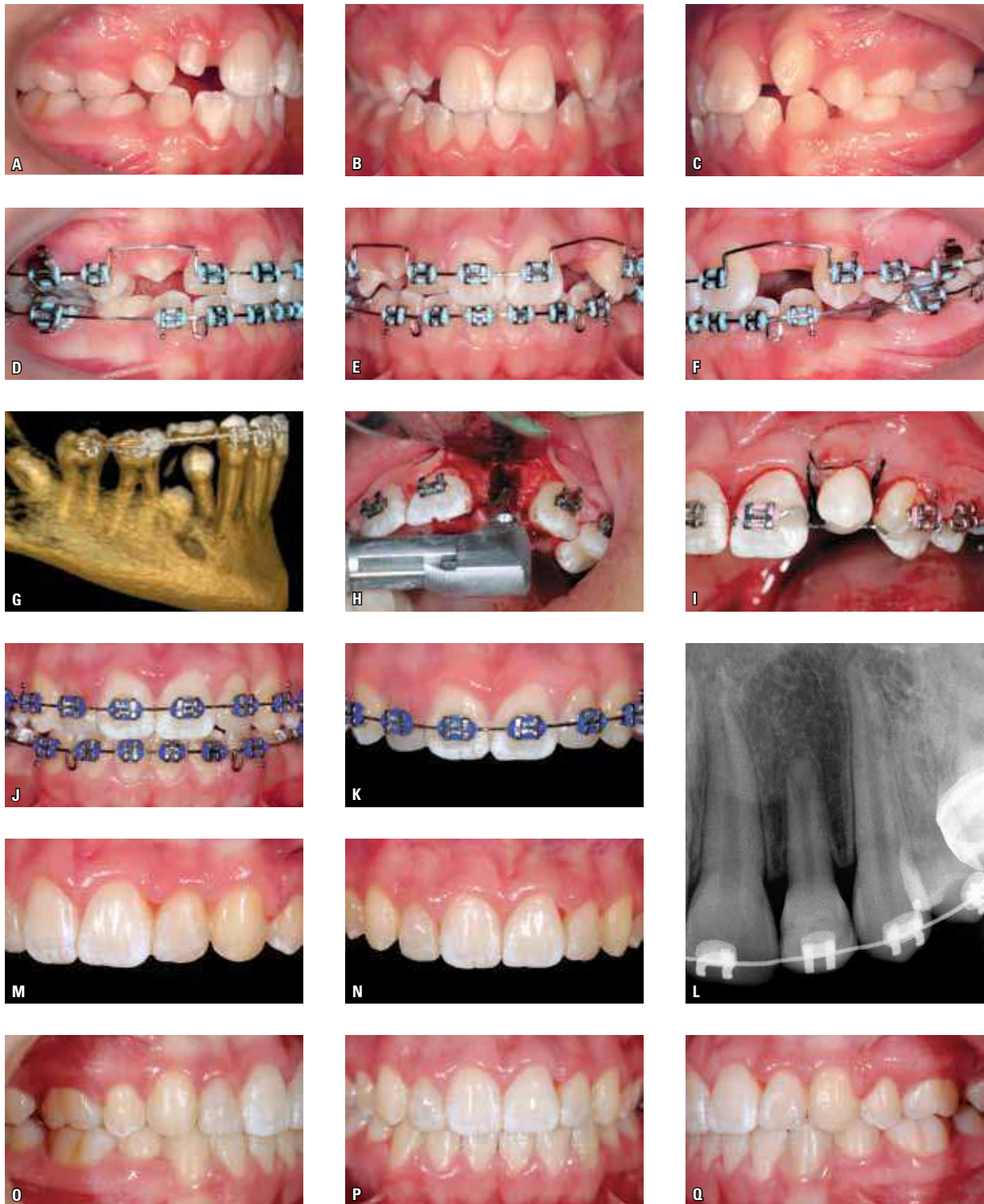

FIGURE 5 - **A, B, C**) Patient with multiple agenesia (teeth 15, 22, 25 and 35) microdontia of tooth 12. **D, E, F**) Opening the space of tooth 22 and closure of the spaces from the maxillary agenesia. **G**) Tomography image used to decide for the transplantation of tooth 44, still occluded, with good root anatomy and 2/3 root formation. **H**) Preparing the receiving area with implant drills, sized based on the tomography. **I**) Tooth 44 positioned in place of tooth 22. **J, K, L**) During tooth movement, 12 months after self-implant (notice root formation under way). **M, N, O, P, Q**) Finalized case, after being subjected to gingivoplasty and new restorations on 12 and 22.

cases, appliance setting should be differentiated in order to optimize the outcome. Special consideration should be given to the gingival contour, and plan canine extrusion – preceded by incisal and palatal wear – and intrusion of the first premolars. Gingivectomy and bone recontouring may be necessary to improve aesthetics and remove accumulated tissue. When the canines have impactful shape and color, the resources of aesthetic dentistry can modify tooth elements in an almost non invasive manner. When canine mesialization is chosen, it is recommended that occlusal adjustment be made, so that there is group function. Thus, the stress is reduced on the maxillary first pre-molar, distributing the progressively lower forces in a posterior aspect, in lateral movements^{2,11,12}.

I do not discard the option of opening spaces for implants – especially in adults, in order to abbreviate treatment – when there is little support for the upper lip or when the treatment simulations with canine mesialization do not please the patient. The selection of the professional who will perform the implant is decisive for the aesthetic success when that strategy is chosen, as a bone or gingival graft may be necessary in order to avoid the dark shadow of the screw and the risk of gingival recession²⁶.

Patients with vertical growth patterns always require a more careful planning, and are more critical with regards to stability. In your understanding, the use of skeletal anchorage devices can reduce the need for extractions in vertical excess cases? Roberto Rocha

I consider vertical problems, especially excess, to be the greatest challenges to an orthodontists, particularly when we consider treatment stability. Studies show a 35% prevalence of open bite relapse, which represents a disaster in clinical practice⁹. What happens most times with relapse is an extrusion of posterior teeth, especially maxillary teeth, reestablishing the occlusal vertical dimension (OVD), which had been changed by the treatment and is dictated by muscle tone.

Indeed, the muscle factor is the determining and limiting factor for our success, and there is no safe evaluation that can indicate whether the dental or skeletal changes we have generated through treatment will be followed by the necessary muscular adaptations⁶. First of all, we must get rid of the illusory view that speech therapies could be effective in this type of muscular adaptation, as there is no scientific principle to support that dogma. Genetic and environmental factors can explain greater or lesser stability. The type of muscle fiber that prevails in the masseter muscle is directly related to an individual's facial pattern: type I fibers prevail in dolichofacial individuals, whereas type II fibers prevail in brachyfacial ones²². Among environmental factors, I find that two protocols have a proven effect: (a) the use of active tips, generating discomfort in the low or protruded tongue posture^{6,9}; and (b) use of Bite-block, which, somehow, tends to increase the tone of mandibular elevator muscles, while at the same time generating intrusion forces on posterior teeth¹. In the clinical approach, the results that show the best efficiency and stability are the cases treated with extractions followed by some form of vertical control, precisely because they do not lead to significant changes in the patient's OVD⁵.

From this evidence, I would not regard the temporary anchorage device (TAD) as eliminating the need for extractions, but rather as an important tool in two strategies: (a) the first, and most evident, is as a vertical control device associated with extractions, making the retraction of anterior teeth more effective, instead of head gear appliances; (b) the second indication is when the retraction of anterior teeth is not recommended, and TADs would work as active elements in the intrusion of posterior teeth. In this case, it should be noted that, the less change in the patient's OVD, the better the prospects for long-term stability – in other words, the prognosis is always better in less extensive open bites (Fig. 6). It is important to highlight that the intrusion movement leads to

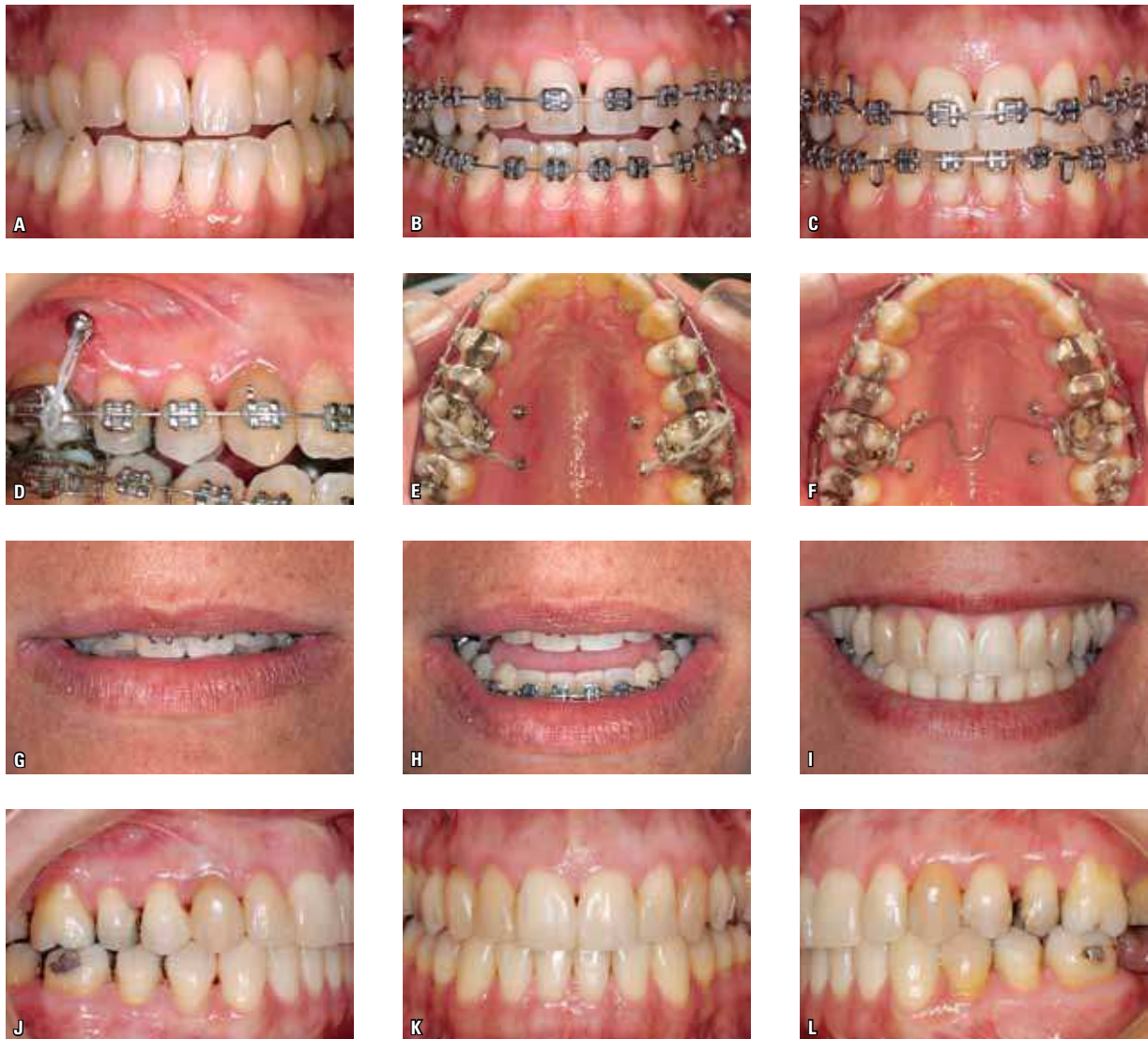

FIGURE 6 - Open bite **A)** before, **B)** during leveling, and **C)** after intrusion of maxillary molars using temporary anchorage devices. **D, E)** Biomechanics for the intrusion of posterior teeth with elastic band trespassing the occlusal of the first molars. **F)** Another biomechanics, using palatal mini-implants, after the loss of those placed buccally. **G, H)** Aesthetic evaluation of the exposure of maxillary incisors at rest and during speech, which is essential prior to appliance removal. In this case, for a 45-year-old woman, 3mm exposure of the maxillary incisors is more jovial and attractive. **I, J, K, L)** Final smile and occlusion.

changes in the arrangement of periodontal ligament fibers, which need at least six months for turn-over. Therefore, the mini-implant should be kept for that period, attached to the dental arch, after correcting the open bite. Long-term follow-up studies of severe open bite cases treated only with TAD are not yet reliable to determine any greater or lesser risk for relapse, when compared to ortho-surgical treatment.

Do you believe very long canines compromise the smile? What is your advice, from appliance setting to finalization, with regard to this aspect? Telma Martins de Araujo

This question deserves careful attention. I have written and spoken quite a bit on occlusion and its determinants, and within that context I emphasize the importance of the function of the canines. On the other hand, this gnathologic as-

pect cannot be an instance of “the more, the merrier”, because that is not justifiable. The function of the canine must establish a disocclusion of posterior teeth in mandibular movements, which can be minimal. The practice of extruding canines to obtain guides, without adding other parameters, has produced a few “vampires” by the end of orthodontic treatment. Therefore, from the time the appliance is assembled (ideally preceded by a setup), one should consider that canine shapes with prominent cusps create two problems: the first being a practical one, as the tip of the canine can interfere with the appliance, breaking the arch or blocking tooth movement; as the second being an aesthetic issue²⁴. When setting the appliance, along with leveling the contact points, the smile’s aesthetics should be considered according to priorities: the first one is the dominance of the central incisors, the second is the curvature of the smile following the curvature of the lower lip, and the third is the gingival contour of the central incisors and canines at the same height and the lateral incisor 0.5 to 1mm below. Therefore, in order to reach these objectives, it may be necessary to wear the canine cusp. This makes it possible to minimize the marked anatomy of that tooth and evidence the size and expression of the central incisors, as well as define the smile curvature. Far from neglecting the function of the canine, it is possible to combine its shape with improved aesthetics (Fig. 7).

Should cases finished in Class II or Class III molar relationships get a differentiated occlusal adjustment compared to cases finished in molar relationship? Jonas Capelli Junior

The main objectives are the same: equipotent simultaneous bilateral contacts and immediate disocclusion of posterior teeth in excursive movements, with effective anterior guides^{14,18}. A few considerations are necessary, which differentiate the finalization and occlusal adjustment when the final molar relationship is not molar relationship.

For instance, in the finalization of a Class II malocclusion treated with camouflage (extraction of the maxillary first premolars), the disto-occlusal molar relationship defines that the maxillary first molar must occlude with the mandibular second premolar, which has a smaller vestibulo-lingual size. In that case, the mesial rotation of the maxillary first molar should be regarded as normal, so that there can be contact between the mesio-vestibular cusp of that tooth with the vestibular cusp of the mandibular premolar, thus establishing the desired “A” contact (Fig. 8). Even more complicated is the finalization of cases with Class II molar relationship, which is common in cases of absence of the mandibular second premolars, treated with anchorage loss (Fig. 8). In those cases, there will be intercuspation of the maxillary second premolar between the cusps of the mandibular first molar, which implies the need for change in tooth anatomy, with selective wear, in order to match normally incompatible sizes and shapes, thereby avoiding occlusal trauma with tooth movement and risk of root resorption. Whenever there is contact between premolars and molars, it should be of a lesser magnitude than the contact established between molars (Fig. 9).

What are the requirements to consider in order to achieve excellence in final treatment results? Luiz G. Gandini Junior

I have 11 principles or requirements that I consider essential in order to obtain a good final result, always careful to use protocols based on clinical and scientific evidence.

- Principle 1 – a consistent diagnosis and planning protocol, with clear parameters and reproducible references: always handle the patient in centric relation before and after treatment, and consider the patient’s age in order to define the final incisor exposure at rest, speech, and smile (Fig. 6, 7).
- Principle 2 – analyze the Rectangular Archwire (Ideal or Straight) to personalize the case: avoid undesirable movements that tend to create premature contact, which delays treatment, opens

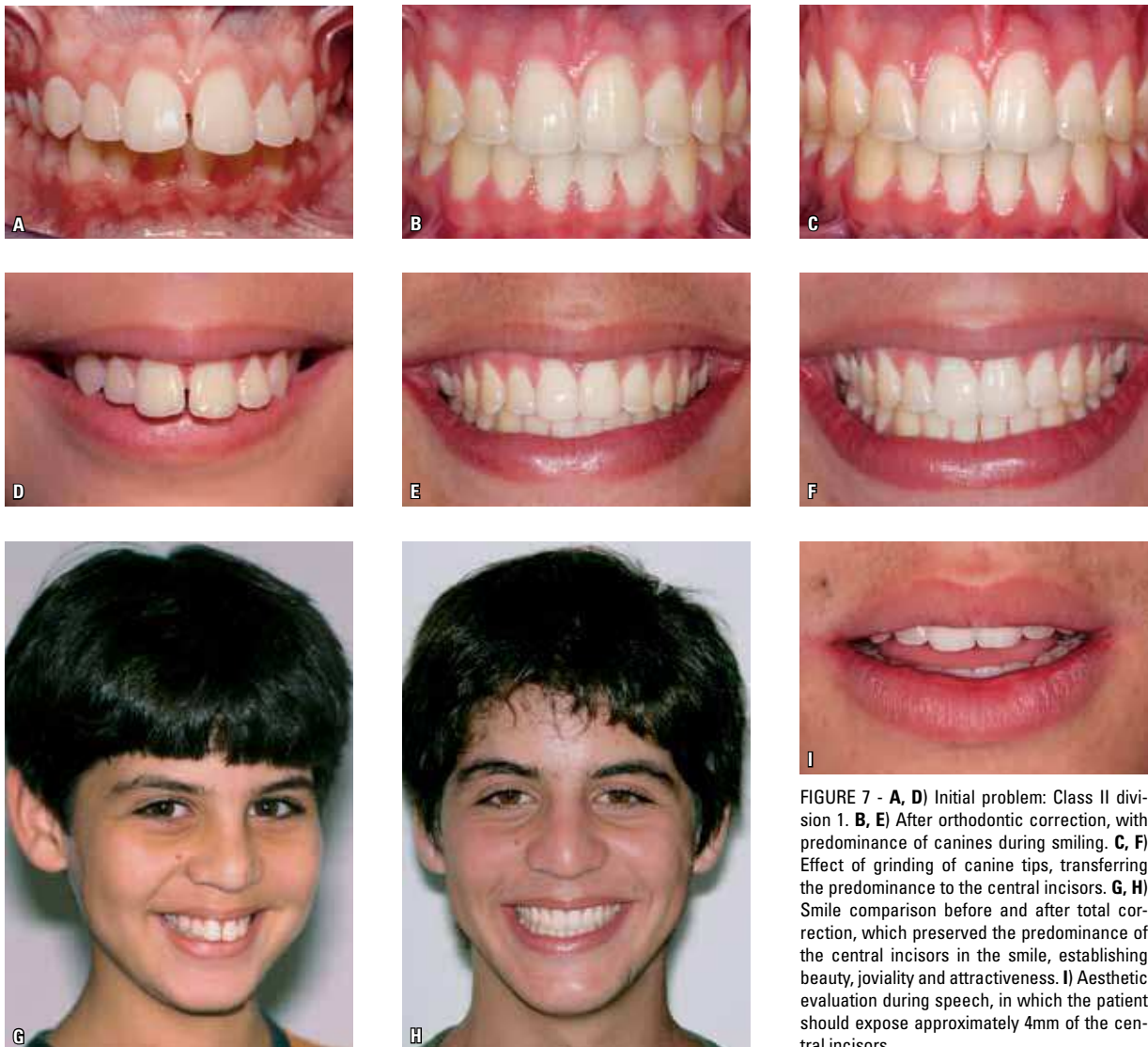


FIGURE 7 - **A, D**) Initial problem: Class II division 1. **B, E**) After orthodontic correction, with predominance of canines during smiling. **C, F**) Effect of grinding of canine tips, transferring the predominance to the central incisors. **G, H**) Smile comparison before and after total correction, which preserved the predominance of the central incisors in the smile, establishing beauty, joviality and attractiveness. **I**) Aesthetic evaluation during speech, in which the patient should expose approximately 4mm of the central incisors.

the bite and predisposes to root resorption through occlusal trauma².

- Principle 3 – know and control dental and periodontal response to torque movement, by increasing or limiting the root effect: avoid periodontal recessions in risk patients, with lesser periodontal thickness, and optimize the desirable response in the whole expanse of the buccal corridor.

- Principle 4 – verify the plausibility of vertical tooth movement and the risk of occlusal trauma, by checking with articulating paper: make tooth

movement possible without causing side effects, and reduce the time of treatment and use of elastic bands (Fig. 15).

- Principle 5 – consider that compensatory treatment (with extractions) requires some adaptations in tooth positions, admitting variations from the ideal: obtain the best intercuspation, and with that, the stability in correcting Angle Classes II and II, and use limits of aesthetic perception by professionals and laypersons (Fig. 8, 9).

- Principle 6 – regard the gingival contour as

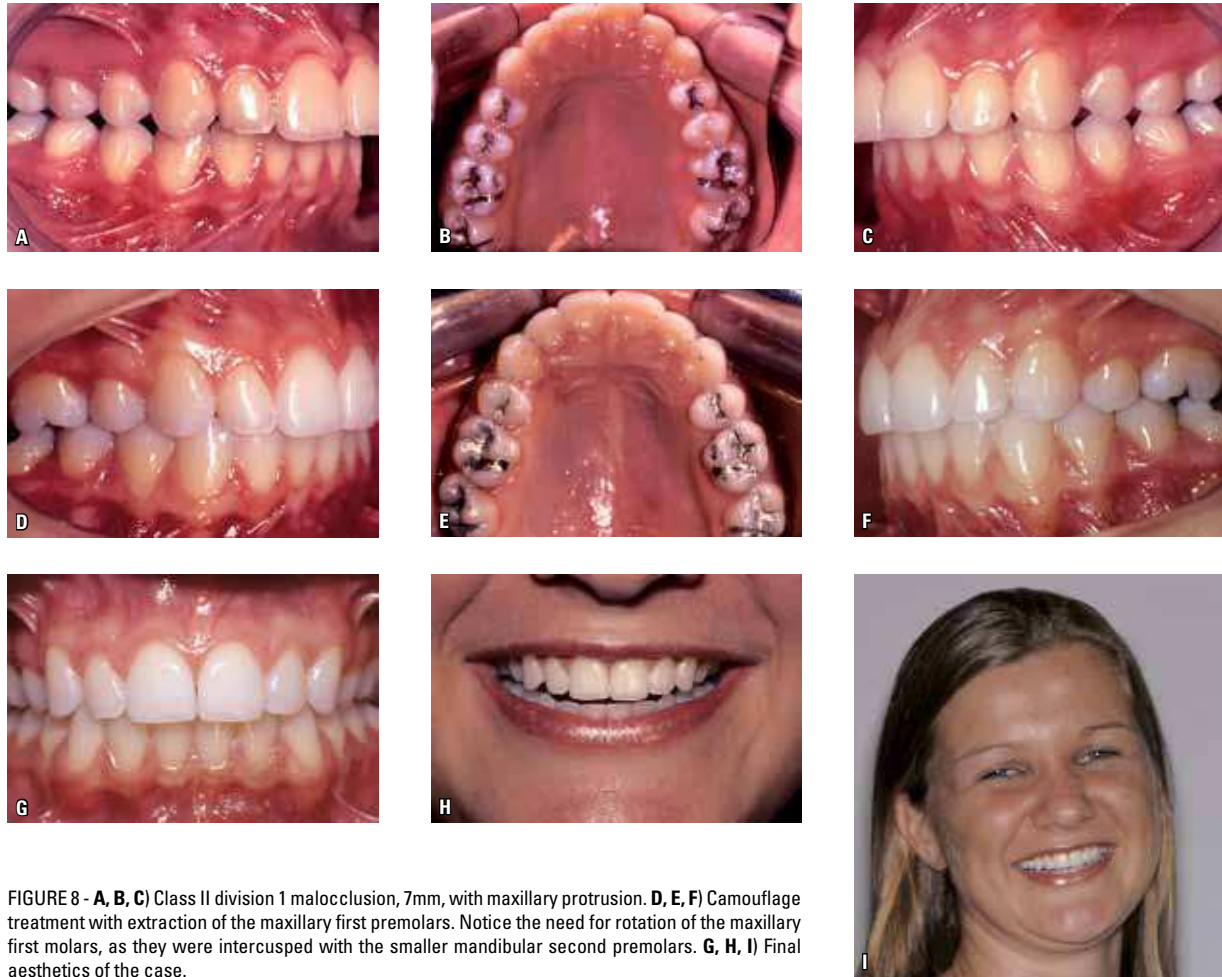


FIGURE 8 - **A, B, C**) Class II division 1 malocclusion, 7mm, with maxillary protrusion. **D, E, F**) Camouflage treatment with extraction of the maxillary first premolars. Notice the need for rotation of the maxillary first molars, as they were intercusped with the smaller mandibular second premolars. **G, H, I**) Final aesthetics of the case.

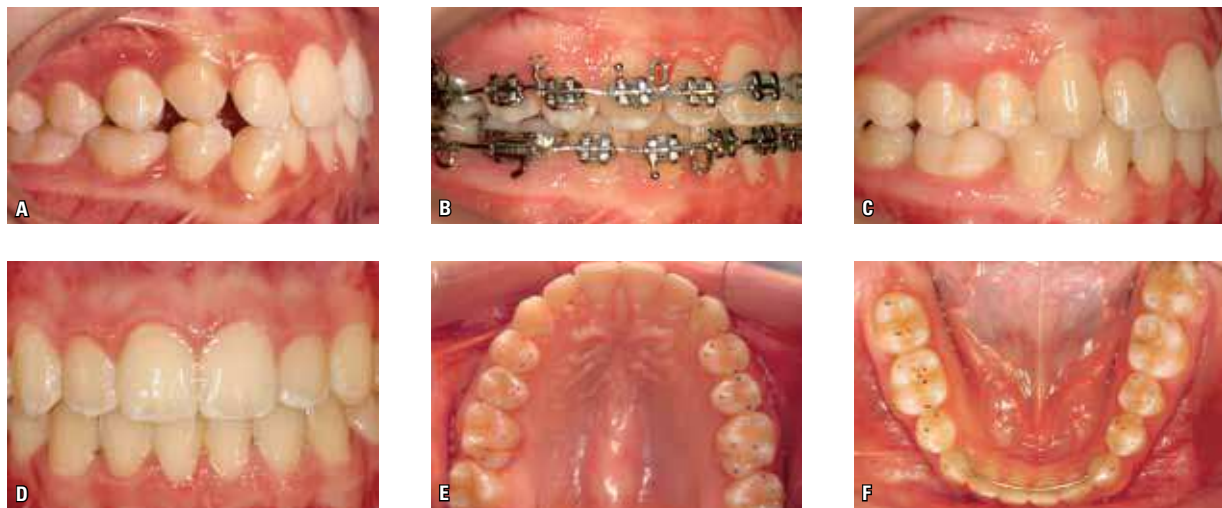


FIGURE 9 - Young female patient with agenesis of element 45: before (**A**), during (**B**) and after (**C**) orthodontics. Gap closure was chosen, achieving a mesio-occlusion molar relationship (Class III). The intercuspatation of the maxillary second premolar with the mandibular first molar was possible only with selective grinding. **D, E, F**) Evaluation of the final occlusion and contact adjustment.

a priority in mutilated patients or those with dental wear, defining the amplitude of movement and periodontal procedures: achieve excellence in periodontal aesthetics, using the appliance to achieve specific results, expanding the resources of Periodontics¹⁰ (Fig. 10).

- Principle 7 – consider the adequate incisal contour, by relating: (a) dental form and ratios; (b) smile curve; and (c) the height of interproximal contacts. All with the objective of achieving excellence in smile aesthetics, with dominance of the maxillary central incisors, using the appliance and incisal wear with clear objectives, including speech dynamics^{16,24,27} (Fig. 11).

- Principle 8 – consider the standards of excellence in the facial height-width ratio and its correlation with tooth sizes: work together with other

specialties, incorporating parameters and enriching the aesthetic result, in addition to establishing limits to interdental wear (Fig. 12).

- Principle 9 – consider smile amplitude and buccal corridor as aesthetic parameters and markers of tooth positioning in the basal bone: position teeth in the basal bone, giving priority to maxillary disjunction as tool to improve aesthetics and increase stability, and respect the limits of the muscles (Fig. 11).

- Principle 10 – establish axial, bilateral, simultaneous and equipotent forces, without horizontal results. With the objective of reducing treatment relapse, eliminate periodontal risk and meet the expectations of colleagues who send us patients².

- Principle 11 – face new technologies and practices by considering three factors: plausibility, effi-

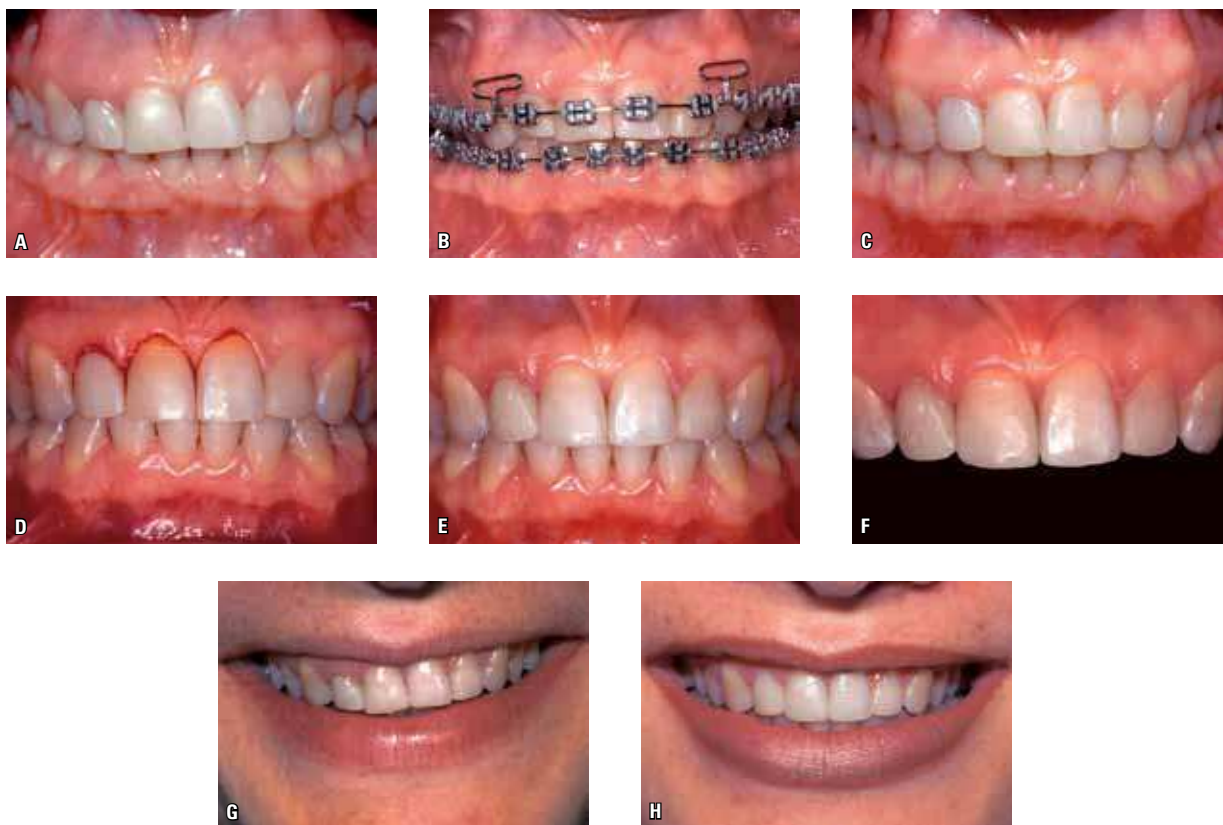

FIGURE 10 - **A**) Patient recommended for orthodontic correction aiming to improve gingival contour. **B**) Archwire with T loops for asymmetrical intrusion of anterior teeth. **C**) After orthodontics, note the accumulation of gingival tissue. **D, E, F**) Final correction through gingivectomy. **G, H**) Smile comparison, before and after treatment.

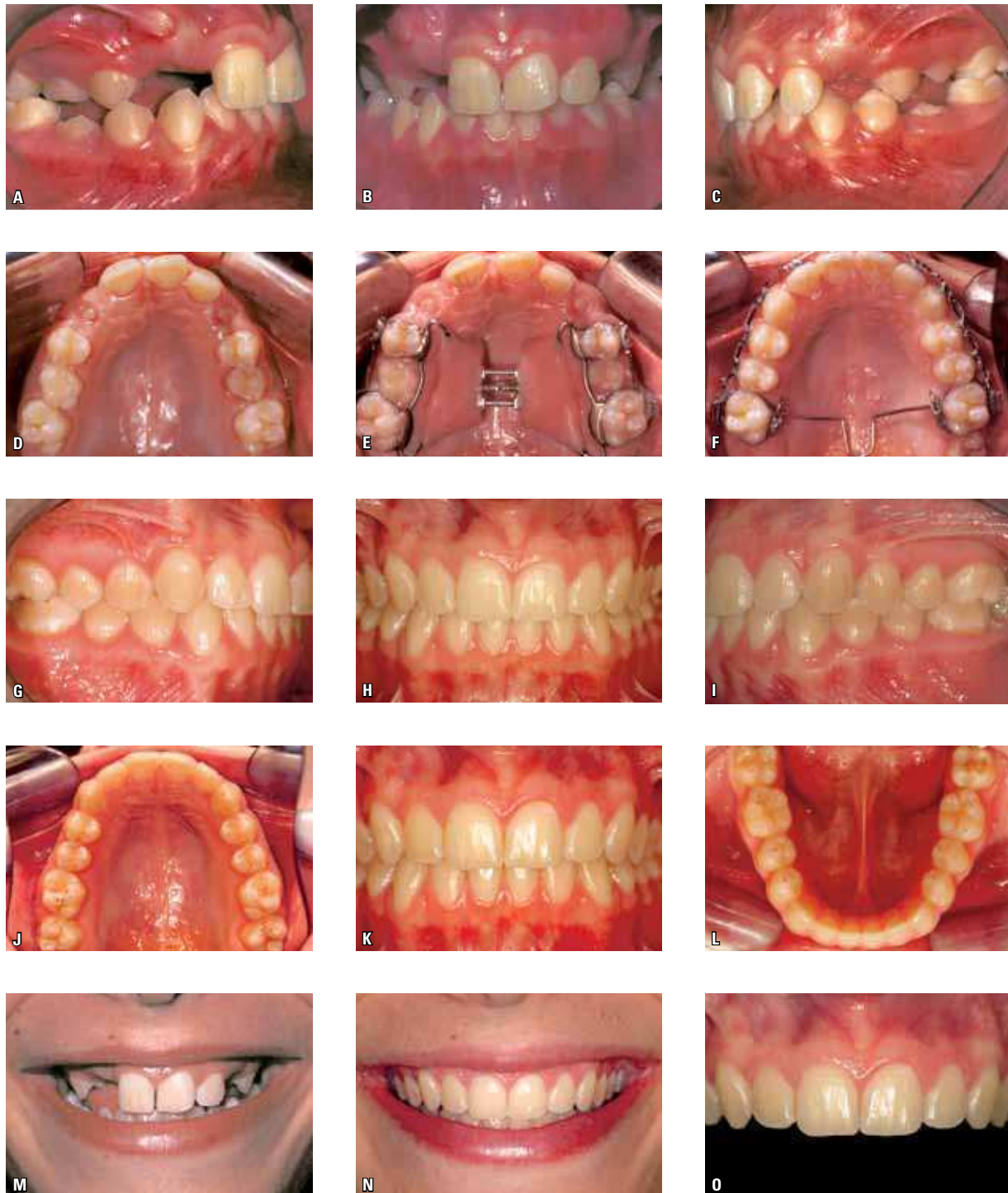

FIGURE 11 - A, B, C) Patient featuring a lack of space in the maxillary arch and posterior crossbite. **D, E, F)** Evolution of the correction of the maxillary transverse gap. **G, H, I)** Immediate result of orthodontics, where the occlusion and smile curve were given priority, always considering dental integrity. **J, K, L)** After six months, with the definition of occlusal contacts and the effect of the gingivoplasty on tooth 21, establishing improved stability and aesthetics. **M, N, O)** Before-and-after smile comparison, in which the following aesthetic determinants can be observed: central incisors crown width equal to 80% of their height; contact points height equal to 50% of central incisor clinical crown height, reducing to 10% posterior; lateral incisors height equal to 80% of the central incisors and canines height, with gingival level 1mm below; smile curvature following lower lip contour, with dominance of the central incisors.

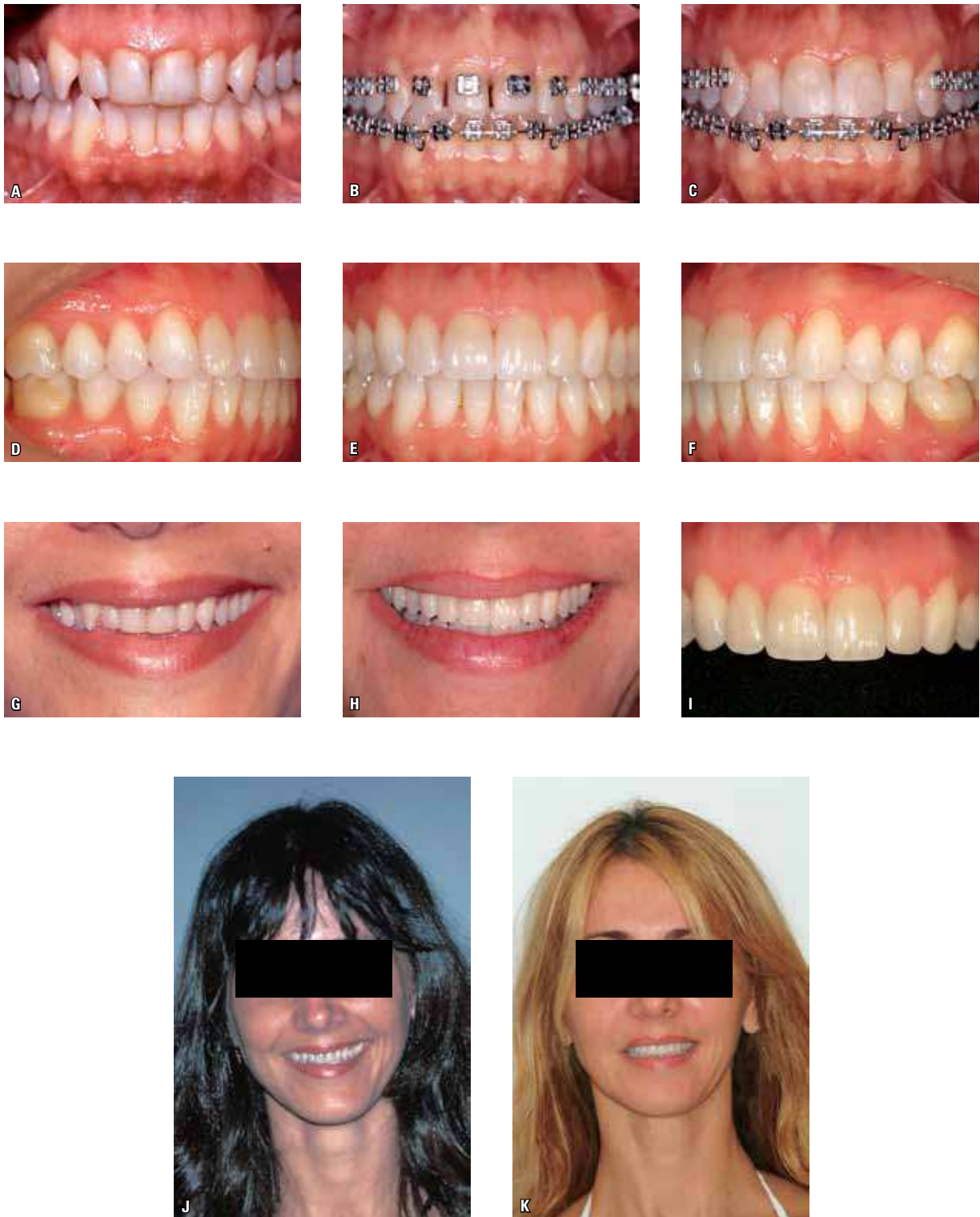

FIGURE 12 - **A, B, C**) Evolution of treatment to open spaces in order to achieve a mesio-distal increase in the incisors, followed by restorations. **D, E, F**) Final result, after orthodontics and porcelain veneers. **G, H**) Before-and-after smile comparison, evidencing dental proportions. **I**) Final dental proportions and forms. **J, K**) Before-and-after facial comparison, considering that teeth were increased based on facial proportions, as it was the only available parameter, due to pre-treatment destruction of teeth.

ciency and stability. This is in order not to overvalue what is new, under the risk of forsaking proven studies and practices, and consider that the parameters of success are built on scientific evidence, not words.

I plan to detail these principles in an article soon.

At what times during corrective orthodontic therapy do you recommend selective grinding procedures for occlusal adjustment? Paulo César Rodrigues Conti

As previously described in the article "Occlusal adjustment in Orthodontics: why, when and how?", published by the Dental Press Journal of Orthodontics and Facial Orthopedics, there are three moments in which occlusal adjustment should be considered². The first is prior to setting the appliance, as there are malocclusions, such as functional crossbites, that can be solved with selective grinding, if there is no associated maxillary atresia. The second moment is during orthodontic treatment, in this case associated particularly with vertical tooth movements. We recommend that, prior to performing bends for dental extrusion, especially when associated with intermaxillary elastics, a verification be made using articulating paper (Accufilm®) of the risk of incorporating an occlusal trauma, as it would make movement impractical, in addition to create side effects such as roots resorption and iatrogenic open bites. In those cases, when the need is detected for selective occlusal grinding, the objective is to provide improve quality of dental intercuspation and reduce treatment time, as they make tooth movement biomechanically feasible (Fig. 15). The last opportunity for occlusal adjustment by grinding or addition should be considered six months after fixed appliance have been removed and prior to discontinue the use of the retainer. We should wait until that time to allow natural accommodation by function. Grinding is a refinement of occlusal contacts, which should be simultaneous and equipotent, with A and B or B and C contacts, with stop and balance in each tooth. Normally, it

is a procedure that lasts only 10 to 20 minutes, as the greater and best occlusal adjustment has already been made through the precise movements during corrective orthodontic treatment. Effective anterior guides, with immediate disocclusion in excursive movements, are normally established during the orthodontic phase. The occlusal adjustment should not be seen as the silver bullet for problematic orthodontic treatments, but rather as a way to achieve excellence, with the objective of attaining occlusal balance, and therefore contribute to dental stabilization (Fig. 13). Normally, cases with gaps and undesirable tooth movements after the removal of retainers are related to the lack of occlusal balance and the presence of parafunction.

In your opinion, should small discrepancies (up to 1.5mm) between the centric relation (CR) and habitual maximum intercuspation (HMI) positions be correcting through occlusal adjustment during finalization? Paulo César Rodrigues Conti

There are two different situations that should be observed. First of all, in the population without occlusal pathologies, there is the prevalence of a small difference between CR and HMI positions, approximately 1.5mm, which is considered natural and physiological. Likewise, I do not believe that the CR position is the only acceptable one to finish an orthodontic treatment. On the other hand, the orthodontist needs a parameter for diagnosis and a reference during treatment. For the diagnosis, manipulating the patient in CR may mean the difference between a more or less complex treatment². For instance, a patient with severe Angle Class II malocclusion in HMI, after being manipulated in CR may prove to be a simpler case, avoiding orthognathic surgery to treat it (Fig. 14). Another situation that evidences the importance of patient manipulation in CR is during orthodontic treatment. At each activation of the appliance, the professional creates the occlusal contacts and interferences, which can shift the mandibular posi-

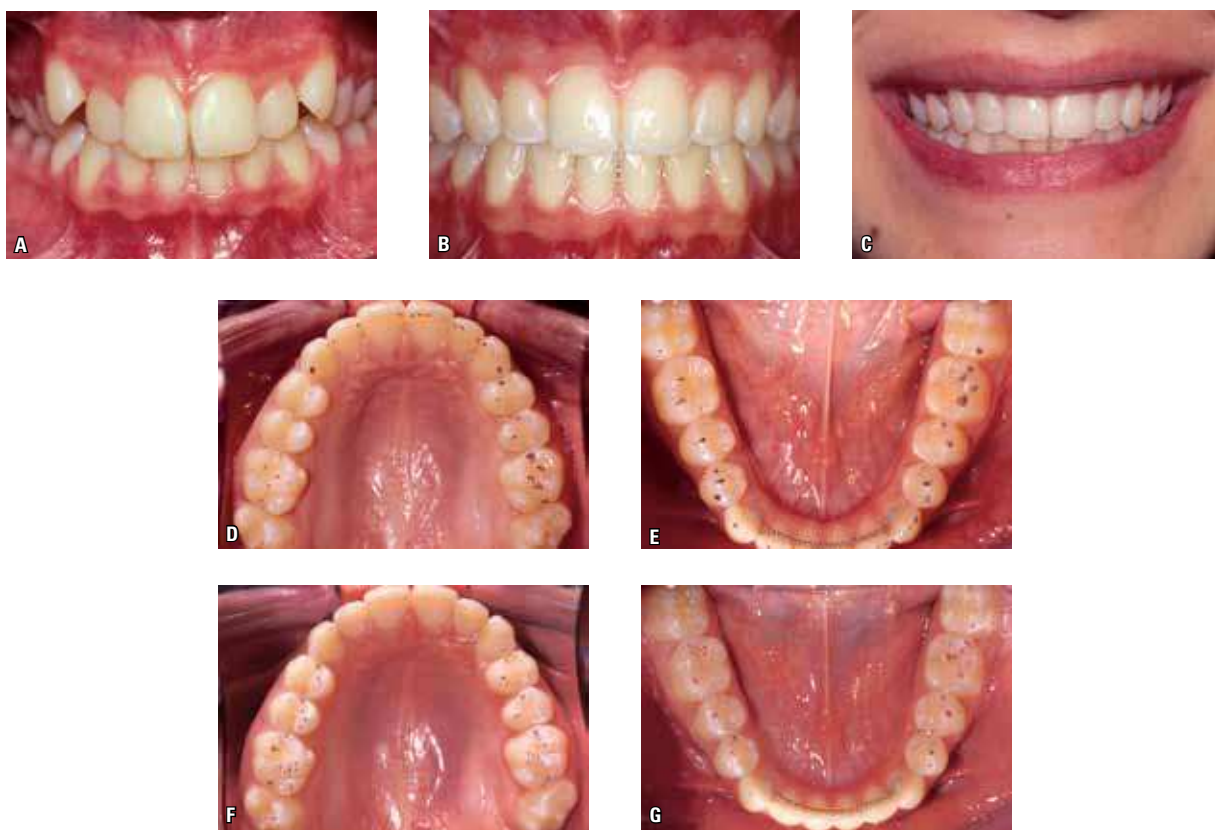

FIGURE 13 - **A**) Initial malocclusion, with dental crowding. **B, C**) Result obtained after orthodontics. **D, E**) Occlusal contacts six months after removal of appliances. **F, G**) Occlusal balance achieved through selective grinding; maxillary retainer use is allowed after this stage.

tion, establishing a new HMI. In other words, it is a new malocclusion at every monthly consultation, leaving the orthodontist lost during treatment. The only reproducible position is CR, and therefore it should be used as guidance for each activation of the appliance. CR is a reference for the orthodontist, and not an obsession^{18,23}.

Therefore, I believe there can be, at the end of treatment, a small discrepancy of up to 1.5mm between CR and HMI, as long as this mandibular shift does not create excessive anterior contact, whose horizontal component would lead to tooth migration. This is an important evaluation prior to removing the retainers, as the check should be made by manipulating the patient in CR and asking him to clench his teeth, while the professional

places a fingertip on the crown of maxillary teeth. If vibration (fremitus) occurs, it is a sign of excessive effort on those teeth, and the contacts should be checked using articulating paper (Accufilm®). In the cases where the anterior deviation of CR to HMI results in excessive horizontal force, even with a deviation lower than 1.5mm, occlusal adjustment in CR should be considered the best path to avoid opening anterior spaces and periodontal recession, as excessive horizontal forces on anterior superior teeth lead to tipping. In the absence of anterior retention, in muscularly competent patients, this strong anterior contact could explain the relapse of mandibular dental crowding. In the cases with small CR-HMI deviations, where there is not a strong anterior contact in HMI, the final adjust-

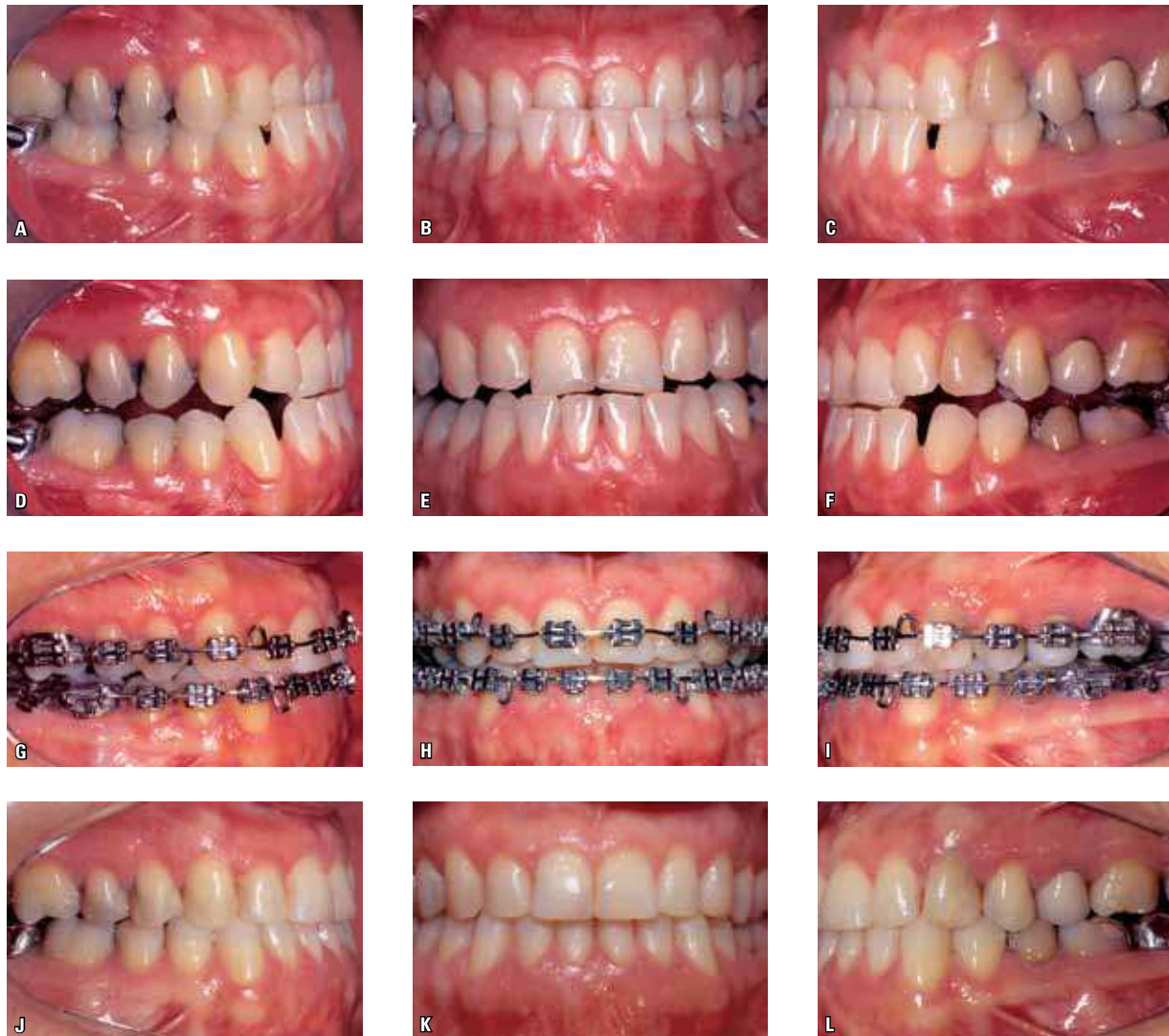

FIGURE 14 - **A, B, C**) Evaluation of malocclusion in HMI, detecting a severe Class III. **D, E, F**) Evaluation of the same patient in CR, which transforms the case in a simpler treatment, possible to be corrected without surgery. **G, H, I**) Correction under way, based on the use of intermaxillary elastics. **J, K, L**) Final result, including temporary incisal restorations with composite resin.

ment should be made in the latter position, which is the more common situation?

Considering there is an increase in the amount of occlusal contacts after the removal of the orthodontic appliance, how do you see the ever more common use of thermoplastic retainers (acetate plates) as devices for post-treatment maxillary retention? Jonas Capelli Junior

Thermoplastic retainers are plates that cover all teeth, including their occlusal surface. Because they are transparent, patients like them. Orthodontists who use them believe in the need to retain vertical tooth movement, avoiding post-treatment accommodation. What seems an advantage is in fact disastrous when we observe what happens in the six months following appliance removal, as the acetate plate obstructs a significant increase

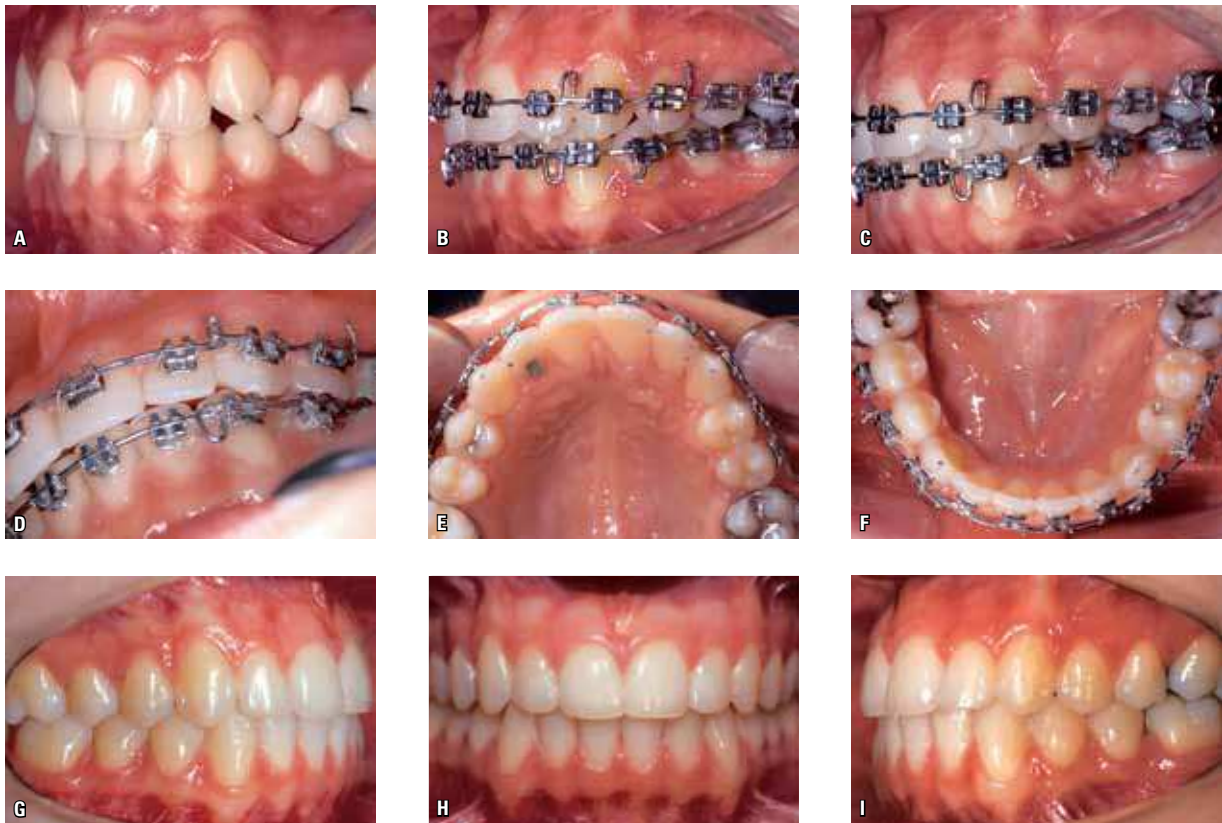

FIGURE 15 - **A)** Patient with Class I malocclusion with crowding. **B, C)** At the beginning of the finalization phase, there is the need for step-bends to improve intercuspation. **D, E, F)** The efficiency of biomechanics was only possible because the premature contact was previously detected, resulting in selective grinding of the distal marginal crest of tooth 22 in order to allow vertical movement. **G, H, I)** Final result, obtained after 26 months of orthodontics, with no time loss and without sequelae.

in the number of occlusal contacts^{8,20}. Physiologic dental movement at the moment of irruption is natural, desirable and necessary, increasing the number of occlusal contacts after the active orthodontic treatment – so that later these contact can be distributed qualitatively, through occlusal adjustment by grinding. In fact, no matter how good the professional and his care during finalization, there will always be room for the normal muscular function to complement dental intercuspation in the most physiological and stable manner. We

cannot forego this help from nature, which establishes a potential continuous irruption of teeth, improving an element's contact with its antagonist. That is the great advantage of using retaining appliances that have no material interposed between the two dental arches. Of course, we are discussing minor post-treatment accommodations, and not an anterior open bite due to lack of finalization. Our choice is usually the wraparound appliance, which has a continuous clip passing distally from the last teeth of the maxillary arch,

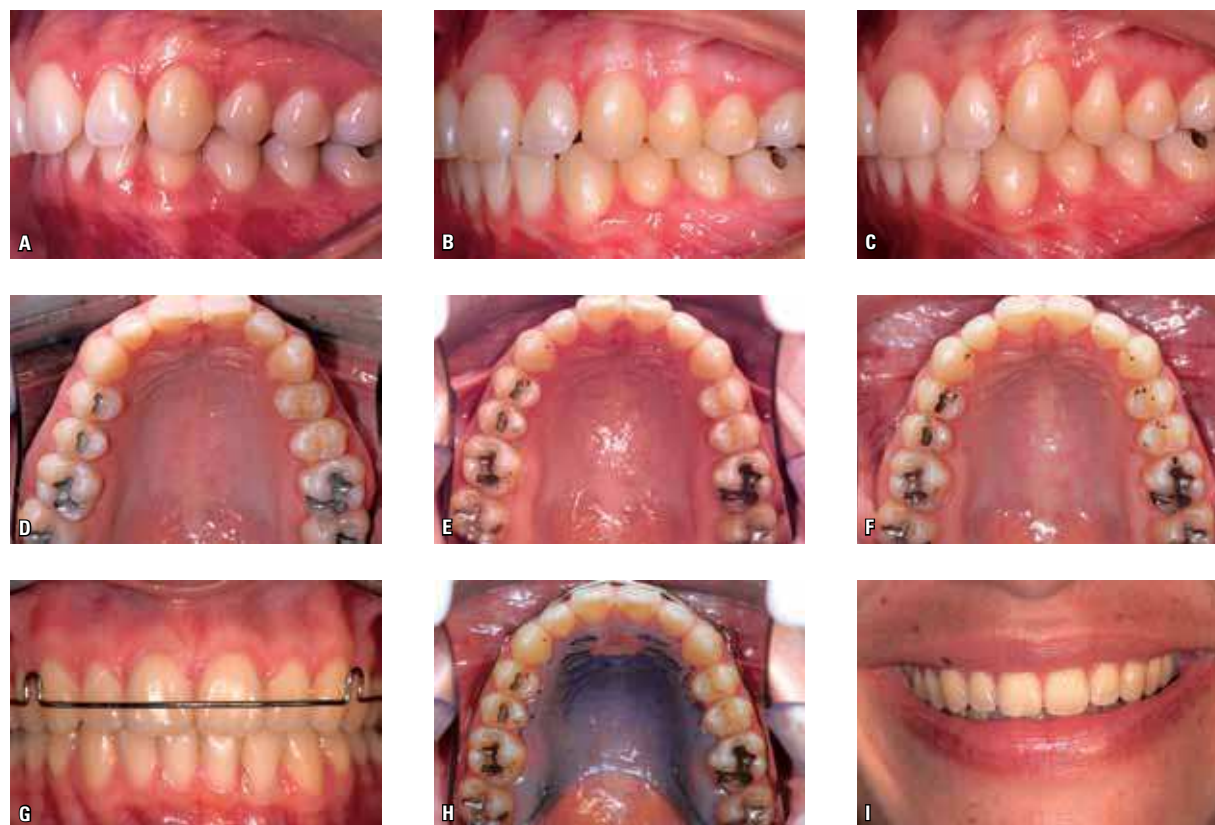

FIGURE 16 - **A, D)** Class II division 1 malocclusion in an adult patient. **B, E)** Result of occlusion immediately after treatment. **C, F)** After six months of retention, note the increase of occlusal contact from muscle action. **G, H)** Wraparound-type appliance that enables accommodation after orthodontics, as there are no occlusal interferences. **I)** Final smile.

combined with the arch bonded to the lower canines (Fig. 16). When tooth eruption is stopped with the use of thermoplastic appliances, the need and number of additions increases, through restorations, in an attempt to achieve the necessary contacts for occlusal balance. Therefore, scientific evidence and clinical excellence counter-indicate the use of thermoplastic appliances as retainers after orthodontic treatment, and point to the need to wait for six months using retainers with appli-

ances that do not cause occlusal interference, in order to perform adjustments through grinding, aiming for the best possible occlusal balance².

Contact Address

Roberto Carlos Bodart Brandão
 Av. Américo Buaiz, 501/1007 - Enseada da Praia do Suá
 CEP: 29.050-911 - Vitória / ES
 E-mail: roberto@ortobrandao.com.br

REFERENCES

- ALTUNA, G.; WOODSIDE, D. G. Response of midface to treatment with increase vertical occlusal forces: Treatment and post treatment effects in monkeys. **Angle Orthod.**, Appleton, v. 55, no. 3, p. 345-356, 2006.
- BRANDÃO, R. C. B.; BRANDÃO, L. B. C. Ajuste oclusal na Ortodontia: por que, quando e como? **R. Dental Press Ortodon. Ortop. Facial**, Maringá, v. 13, n. 3, p. 124-156, 2008.
- BURSTONE, C. J.; KOENIG, H. A. Force systems from an ideal arch. **Am. J. Orthod. Dentofacial Orthop.**, St. Louis, v. 65, no. 3, p. 270-289, Mar. 1974.
- CONSOLARO, A.; PINHEIRO, T. N.; INTRA, J. B. G.; ROLDI, A. Transplantes dentários autógenos: uma solução para casos ortodônticos e uma casuística brasileira. **R. Dental Press Ortodon. Ortop. Facial**, Maringá, v. 13, n. 2, p. 23-28, 2008.
- HANS, M. G.; TENG, C. M.; CHEN, Y. H.; YANG, C. Y. An evidence-based approach to treatment of open bite and deep bite. **World J. Orthod.**, Carol Stream, v. 8, no. 1, p. 45-64, 2007.
- HUANG, G.; JUSTUS, R.; KENNEDY, D. B.; KOKICH, V. G. Stability of anterior open bite treated with crib therapy. **Angle Orthod.**, Appleton, v. 60, no. 1, p. 17-26, 1990.
- INTRA, J. B. G. **Avaliação clínica e radiográfica da reparação pulpar e periodontal em dentes auto-transplantados**. 2003. Dissertação (Doutorado)-Faculdade de Odontologia, Universidade Federal do Rio de Janeiro, Rio de Janeiro, 2003.
- JANSON, G. **Análise funcional e ajuste oclusal em Ortodontia**. 1986. Dissertação (Mestrado)-Faculdade de Odontologia de Bauru, Universidade de São Paulo, Bauru, 1986.
- JUSTUS, R. Correction of anterior open bite with spurs: Long term stability. **World J. Orthod.**, Carol Stream, v. 2, no. 3, p. 219-231, 2001.
- KOKICH, V. G. Esthetics: the orthodontic-periodontic restorative connection. **Semin. Orthod.**, Philadelphia, v. 2, no. 1, p. 21-30, 1996.
- KOKICH, V. G.; KINZER, G. A. Managing congenitally missing lateral incisors, Part I: Canine substitution. **J. Esthet. Restor. Dent.**, London, v. 17, no. 1, p. 5-10, 2005.
- KOKICH, V. G.; SPEAR, F. M. Interdisciplinary management of anterior guidance: A case report. **Advanced Esthetics & Interdisciplinary Dentistry**, Seattle, v. 3, no. 3, p. 2-6, 2007.
- LIQU, E. J. W. Toothborne orthopedic maxillary protraction in Class III patients. **J. Clin. Orthod.**, Boulder, v. 39, no. 2, p. 68-75, Feb. 2005.
- McNEIL, C. Selective tooth grinding and equilibration. In: _____ **Science and practice of occlusion**. Carol Stream: Quintessence, 1989.
- MELSEN, B. Palatal growth studied on human autopsy material. **Am. J. Orthod. Dentofacial Orthop.**, St. Louis, v. 68, no. 1, p. 42-54, 1975.
- MORLEY, J.; EUBANK, J. Macroesthetic elements of smile design. **J. Am. Dent. Assoc.**, Chicago, v. 132, no. 1, p. 39-45, 2001.
- MULLINGAN, T. F. Common sense mechanic: Static equilibrium. **J. Clin. Orthod.**, Boulder, v. 13, no. 11, p. 762-766, Nov. 1979.
- OKESON, J. P. Critérios para uma oclusão funcional ideal. In: OKESON, J. P. **Tratamento das desordens temporomandibulares e oclusão**. 4. ed. São Paulo: Artes Médicas, 2000. p. 87-100.
- PAULSEN, H. U.; ANDREASEN, J. O.; SCHWARTZ, O. Pulp and periodontal healing, root development and root resorption subsequent to transplantation and orthodontic rotation: A long-term study of autotransplanted premolars. **Am. J. Orthod. Dentofacial Orthop.**, St. Louis, v. 108, no. 5, p. 630-640, 1995.
- RAZDOLSKY, Y.; SADOWSKY, C.; BeGOLE, E. A. Occlusal contacts following orthodontic treatment: A follow-up study. **Angle Orthod.**, Appleton, v. 59, no. 3, p. 181-186, 1989.
- ROSA, M.; ZACHRISSON, B. U. Integração da Ortodontia (fechamento de espaço) e da Odontologia Estética no tratamento de pacientes com agenesia de incisivos laterais superiores. **Rev. Clín. Ortodon. Dental Press**, Maringá, v. 1, no. 1, p. 41-55, 2002.
- ROWLERSON, A.; RAOUL, G.; DANIEL, Y.; CLOSE, J.; MAURAGE, C. A.; FERRI, J.; SCIOTE, J. J. Fiber-type differences in masseter muscle associated with different facial morphologies. **Am. J. Orthod. Dentofacial Orthop.**, St. Louis, v. 127, no. 1, p. 37-46, Jan. 2005.
- SADOWSKY, C.; POLSON, A. M. Temporomandibular disorders and functional occlusion after orthodontic treatment: Results of two long-term studies. **Am. J. Orthod. Dentofacial Orthop.**, St. Louis, v. 86, no. 5, p. 386-390, Nov. 1984.
- SARVER, D. M. Principles of cosmetic Dentistry in Orthodontics: Part 1. Shape and proportionality of anterior teeth. **Am. J. Orthod. Dentofacial Orthop.**, St. Louis, v. 126, no. 7, p. 749-753, 2004.
- SPEARS, F. M.; KOKICH, V. G.; MATHEWS, D. P. Interdisciplinary management of anterior dental esthetics. **J. Am. Dental Assoc.**, Chicago, v. 137, no. 2, p. 160-169, 2006.
- THILANDER, B.; ÖDMAN, J.; LEKHOLM, U. Orthodontic aspects of the use of oral implants in adolescents: A ten year follow-up study. **Eur. J. Orthod.**, Oxford, v. 23, no. 6, p. 715-731, 2001.
- TJAN, A. H. L. The JGP. Some esthetic factors in a smile. **J. Prosthet. Dent.**, St. Louis, v. 51, no. 1, p. 24-28, 1984.
- ZANETTI, G. R.; BRANDÃO, R. C. B.; ZANETTI, L. S. S.; CASTRO, G. C.; BORGES FILHO, F. F. Integração orto-perio-prótese para correção de assimetria gengival: relato de caso. **Rev. Dental Press Estét.**, Maringá, v. 5, n. 4, p. 104-115, 2008.

Jonas Capelli Junior

- Full professor - UERJ.
- Doctorate in Dentistry - UERJ.
- Specialist in Orthodontics - UERJ.

Luiz Gonzaga Gandini Junior

- Tenured professor - Unesp.
- Post-doctorate in Orthodontics - Baylor College of Dentistry.
- Doctorate in Orthodontics - Unesp/Araraquara.
- Master's in Orthodontics - Unesp/Araraquara.
- Specialist in Orthodontics - APCD/Araraquara.

Paulo César Rodrigues Conti

- Tenured professor - FOB-USP/Bauru.
- Post-doctorate - University of Medicine and Dentistry of New Jersey/USA.
- Doctorate in Dentistry - USP/São Paulo.
- Specialist in Temporomandibular Dysfunction Orofacial Pain - FOB-USP/Bauru.
- Specialist in Dental Prosthetics - USP/São Paulo.

Roberto Rocha

- Doctorate in Dentistry - UFRJ.
- Master's in Dentistry - UFRJ.

Telma Martins de Araujo

- Doctorate in Orthodontics - UFRJ.
- Master's in Orthodontics - UFRJ.
- Full Professor of Orthodontics - UFBA.
- Coordinator of the Specialization Course in Orthodontics - UFBA.
- Director of the Brazilian Board of Orthodontics and Facial Orthopedics.