



Aesthetics in Orthodontics: Six horizontal smile lines

Carlos Alexandre Câmara*

Abstract

Introduction: Smile analysis is an important stage for the diagnosis, planning, treatment and prognosis of any dental treatment involving aesthetic objectives. The evaluation of the intrinsic characteristics of the smile is a necessary procedure to achieve consistent form in orthodontic treatments, which in turn makes it necessary to recognize the components and factors that affect these characteristics. **Objective:** The objective of this work is to present six horizontal smile lines and their importance in obtaining the desired results in orthodontic treatments. **Conclusion:** The analysis of the six horizontal smile lines facilitates the understanding of the intrinsic characteristics that interfere in the aesthetics of the mouth. Moreover, a harmonization of these lines gives each professional a higher possibility of success in their treatments that include aesthetic objectives.

Keywords: Orthodontics. Aesthetics in Orthodontics. Dental aesthetics. Mouth aesthetics. Smile.

INTRODUCTION

Obtaining a beautiful smile is always the main objective of any aesthetic dental treatment. After all, it is the beauty of the smile that will make the difference between an acceptable or pleasing aesthetic result for any given treatment. Nevertheless, in spite of its importance, the intrinsic characteristics of the smile are little discussed. Much is said of the clinical consequences of dental procedures on the smile, but its intrinsic characteristics are not widely evaluated. These characteristics can sometimes be altered and sometimes not, as they are integral parts of the individual. As such, the field of dentistry has

no reach over these characteristics, and can only make evaluations of them.

Evaluating beauty is always subjective. However, we need adequate tools to overcome the challenge of this subjectivity. In orthodontics, it is not enough only to recognize what is interfering with the smile—it requires a diagnosis of what is not normal, in order to establish a treatment plan. Just as in functional problems, in which we follow conducts that lead us to a diagnosis of the anomalies, aesthetic problems also require parameters so we can find the defects. When searching for the visualization of problems, several rules and assumptions are created, leading sometimes to an

* Specialist in Orthodontics (FO-UERJ). Certified member of the Brazilian Board of Orthodontics and Facial Orthopedics (BBO).

underestimation of defects or an overvaluing of rules, creating paradigms that are not supported by proven scientific data. The very essence of aesthetic dentistry, which involves artistic criteria, contributes to this fact. The use of simple and reliable mechanisms can improve the possibilities of success, if not eliminate performance errors.

There are some tools that can be used for that purpose. The Diagram of Dental Aesthetic References (DDAR) is an auxiliary diagnostic tool that is well suited to that purpose. The diagram consists of six frames that surround the maxillary incisors and canines; their limits are specific to each aesthetic reference. The function of the DDAR is to give an exact idea of the positioning and ratios between teeth, as well as their relationship with the gum and lips.⁵ Originally conceived to aid in the visualization of maxillary anterior teeth, DDAR, when aided by additional data, makes it possible to objectively evaluate the smile, facilitating the aesthetic diagnosis and prognosis. Thus, the objective of this work will be to present the new characteristics of DDAR and its role in the “six horizontal smile lines”, which in turn assist the diagnosis, treatment and prognosis of mouth aesthetics.

DIAGRAM OF DENTAL AESTHETIC REFERENCES - DDAR (new characteristics)

The Diagram of Dental Aesthetic References (DDAR) was created to facilitate the visualization

of maxillary anterior teeth, by suggesting what needs to be created or achieved with those teeth, aiming for the best possible dental aesthetics. The objective of the diagram is to give an exact idea of the positioning and ratios between teeth, as well as their relationship with the gum and lips in frontal view. As previously mentioned, the diagram consists of six frames that surround the maxillary incisors and canines; their limits are specific to each dental reference. Each frame surrounds its respective tooth, observing its limits (Fig 1). Although these frames can serve as references in the different observation planes, DDAR is evaluated at a 90° view from the frontal plane—in other words, perpendicular to it. Its use facilitates the planning and visualization of the best aesthetic positioning of anterior teeth, and its objective is to provide data that can assist the reorganization and restructuring of those teeth, whenever they need to be repositioned and/or restored. However, although the original conception of DDAR is useful to assist in the evaluation of mouth aesthetics, a few references of dental, gingival and labial structures can be added to its format, improving and facilitating the visualization of the smile.

In its original format, DDAR makes reference to the gingival zenith, which are most apical landmarks of the gingival contour. The present reevaluation will add the locations of the extremities of gingival papillae (papillary tips) and emphasize the contact points (Fig 2).

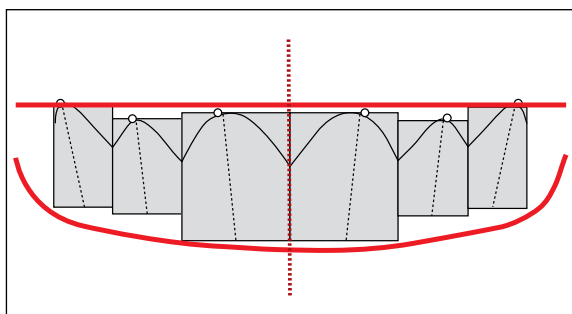


FIGURE 1 - Diagram of Dental Aesthetic References (DDAR).

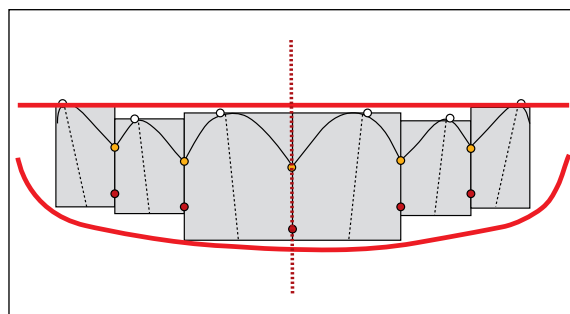


FIGURE 2 - DDAR with new reference points: contact points and gingival papillary tips.

The union of these points will form lines that give evaluative references in the analysis of the smile. As such, DDAR will intrinsically have four lines, formed by the following structures (Fig 3):

- Cervical line–gingival zenith.
- Papillary line–papillary tips.
- Contact points line–contact points.
- Incisal line–incisal edges (incisal line).

The relationship of the papillary line with the contact points line will create a band named connector band, in a reference to the concept of dental connectors.¹⁹ This band, formed by the two lines (papillary and contact points), added to the cervical and incisal lines, will provide the horizontal dental references of the smile in a frontal view.

The other two lines that make up the group of horizontal smile lines are the upper lip line and lower lip line. These lines, along with the dental and gingival lines, compose the group of six horizontal smile lines (Fig 4).

CERVICAL LINE

The cervical or gingival line is formed from the union of the apices of the canines, maxillary lateral and central incisors. As the most apical point of the gingival contour, the apex in

maxillary teeth is usually located distal to the long axis of the tooth. However, this rule does not always apply to the maxillary lateral incisors. On those teeth, the gingival limit may be centered on the long axis. Because the apexes of the maxillary canines are most often higher than the lateral incisors and about the same level as the central incisors, the cervical line attains a convex aspect in relation to the occlusal plane. That would be the ideal form of the cervical line. When the lateral incisors are positioned more apical, at the same height as the canines and central incisors, the line becomes plain. When the gingival contour of the canines is below the lateral incisors, the line formed will be concave (Figs 5 to 7). The concave cervical line is the least pleasing among the three possibilities.

There will be situations in which the heights of the anterior teeth will be asymmetrical, leading to the formation of an asymmetrical cervical line (Fig 8). It should be clear that the position of the gingival zenith can vary widely between teeth and each individual will have a uniquely shaped cervical line, making it practically impossible to characterize all the possibilities. The nomenclature used for the cervical line (plain, concave, and convex) serves only as an evaluation

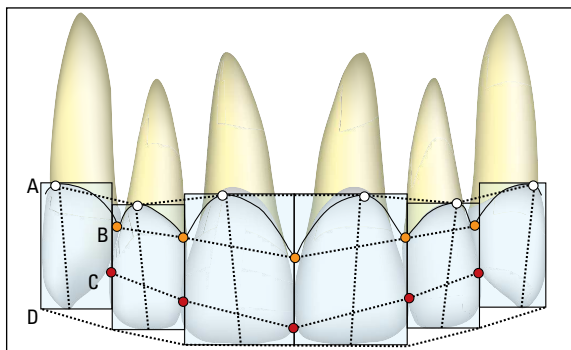


FIGURE 3 - Aesthetic reference lines: Cervical Line (A); Papillary Line (B); Contact Points Line (C); Incisal Line (D).

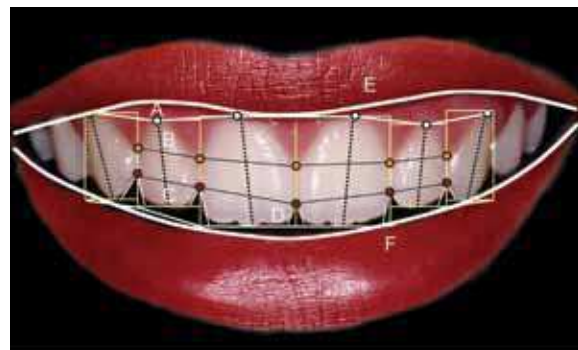


FIGURE 4 - The six horizontal smile lines. Cervical Line (A); Papillary Line (B); Contact Points Line (C); Incisal Line (D); Upper Lip Line (E); Lower Lip Line (F).

reference. The variation in the cervical height of teeth will depend on the periodontal conditions of each tooth, as well as on tooth size, tipping, eruption pattern, and occlusal plane tipping.

INCISAL LINE

The incisal line follows the edges of anterior maxillary teeth. The ideal is that in young patients the incisal edges of the central incisors be below the edges of the lateral incisors and canines in a frontal view. In that configuration, the form of the incisal line resembles the outline of a “deep plate” (Fig 9). A change in the positioning of the incisal edges modifies that figure. When the incisal edge of the central incisors are no longer below the lateral incisors, the outline will change, becoming known as “shallow plate”, or depending on the relation, an “inverted plate”.

In general, the configuration of the incisal line is related to the patient’s age. Over time, there is wear of the central incisors, leading to these changes. However, it is not only wear-related changes that affect the outline of the incisal line.

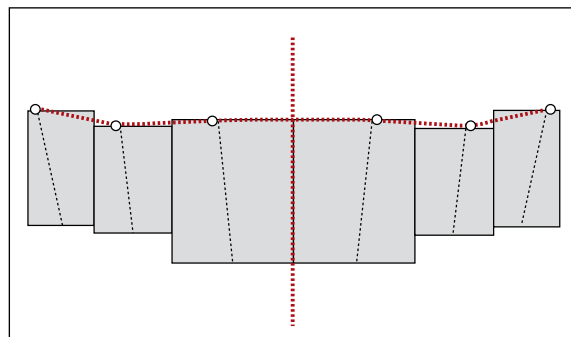


FIGURE 5 - Convex form of the cervical line.

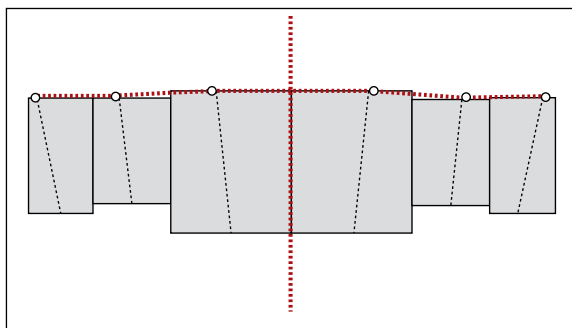


FIGURE 6 - Plain form of the cervical line.

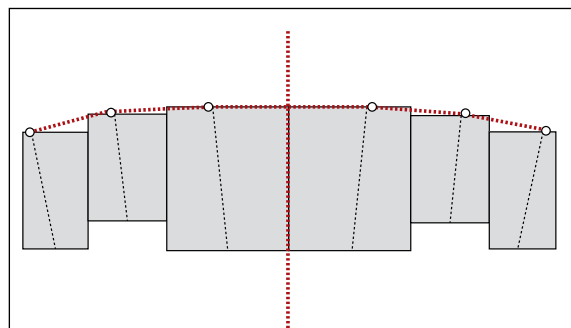


FIGURE 7 - Concave form of the cervical line.

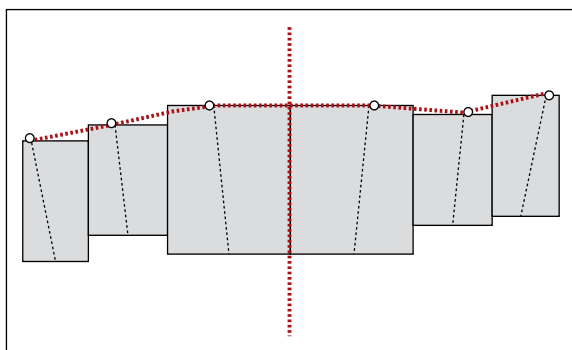


FIGURE 8 - Asymmetrical cervical line.

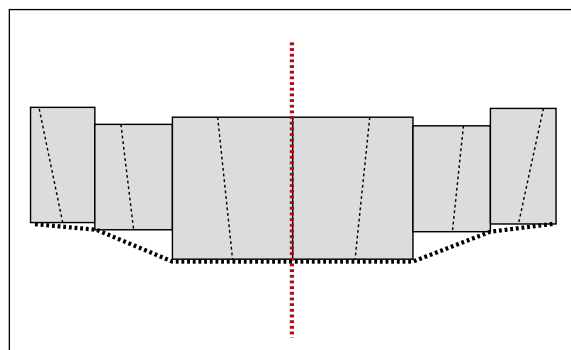


FIGURE 9 - Incisal line in the form of a “deep plate”.

As with the cervical line, tooth size, tipping, eruption patterns, and occlusal plane tipping can also alter the outline. The most utilized term when the incisal line forms an “inverted plate” is “inverted smile”. The line becomes concave in relation to the frontal occlusal plane, giving an aged and anti-aesthetic appearance. The classification of the incisal line may also use the nomenclature concave (“inverted plate”), plain (“shallow plate”) and convex (“deep plate”). Other frequently used terms to describe the incisal line are the “smile arch”,²⁵ “incisal curvature”⁶ and “seagull wing”.¹⁶

CONTACT POINTS LINE

The contact between anterior maxillary teeth is done in a descending fashion, starting from the canine. The contact between the canine and lateral incisor is positioned higher than the contact between the lateral and central incisors; the contact between the central incisors is even lower. The contact points should be narrow, unless there is a discrepancy in the mesio-distal diameter of the crown.² The position of the contact between teeth is related to tooth position and form.¹⁶ As such, the line that unites these points will be parallel to the incisal line, whenever there is no discrepancy between the sizes, shapes and angles of anterior teeth. Although there is a contact point whenever a tooth touches another, the ideal is when that contact happens in an area broader than a single point, forming a connector space. Connector spaces are areas in which teeth appear to touch. As will be seen further on, this fact has a positive influence on dental aesthetics. For practical purposes, whenever the dental contact takes place over an area instead of in a single point, we consider the most apical site as the reference for the contact point (Fig 10).

PAPILLARY LINE

The papillary line is formed by the tips of the gingival papillae located between the canines and

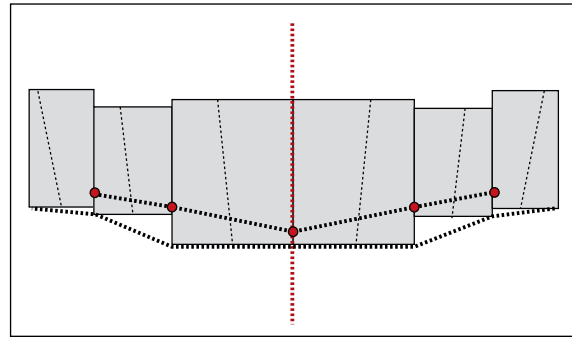


FIGURE 10 - Contact points line. This line should have a certain parallelism with the incisal line.

lateral incisors, and between the maxillary lateral incisors and central incisors. There are no studies that have evaluated the standard height for this relationship. In other words, there is no definition of an ideal model for the relationship between the heights of the papillae. Nevertheless, based on works that evaluated the ideal height of the central incisors and the relationship between the papillary tips and the position and size of teeth,^{13,27} it can be presumed that an ideal line would be parallel to the line formed by the contact points. According to the work of Kurt and Kokich,¹³ the papilla in the central incisors fills half the size of those teeth, under normal conditions. As such, it would be expected that the same pattern would be repeated for the lateral incisors and canines. Given that the lateral incisors are smaller than the central incisors and the papilla should fill half the height of their crowns, the position of the papilla between the central and lateral incisor should be in an apical aspect in relation to that of the central incisors, as well as to the papilla of the lateral incisor and canine (Fig 11).

Connector band

The location where anterior teeth appear to touch is named a connector space. As previously mentioned, there is a difference between a connector space and a contact point. Contact points are small areas in which teeth touch. Connector spaces are larger, broader, and can be defined

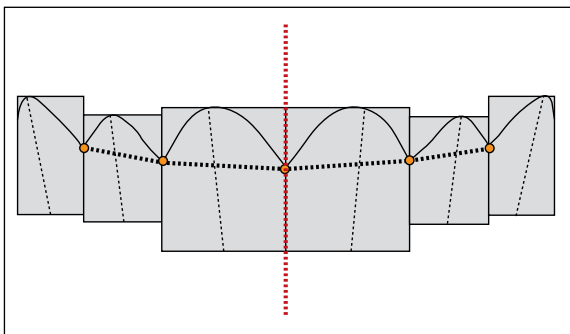


FIGURE 11 - Papillary line. It consists of the tips of gingival papillae.

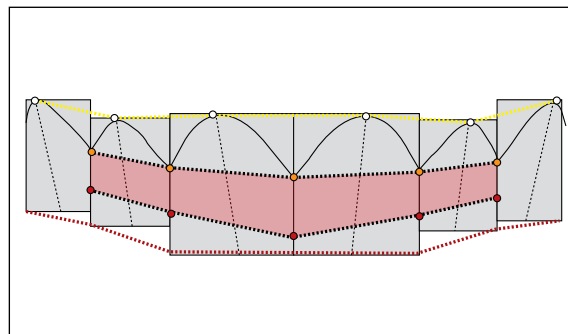


FIGURE 12 - Connector band. This band is delimited by the contact points line and papillary line. The figure of the band resembles the shape of a "hang glider".

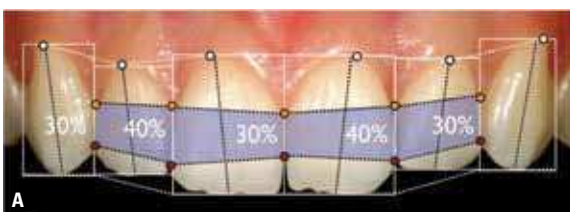

FIGURE 13 - Unfavorable ratio of the "connector band" 30-40-30-40-30 (A). A simple re-contour with the addition of composite resin between the central incisors led to the formation of a favorable "connector band": 30-40-50-40-30 (B).



as zones in which two adjacent teeth appear to touch. The best aesthetic relationship of anterior teeth is one that follows the 50-40-30 rule for the connector space.¹⁹ This rule establishes that the connector space between the central incisors should be 50% of the size of those teeth. The ideal connector space between the central and lateral incisor is 40% of the length of the central incisors, and the connector space between the lateral incisor and the canine is 30% of the same reference. Although the reference points to determine the connector space were not defined by Morley and Eubank,¹⁹ these references can be created from the contact points and the gingival papilla. Therefore, whenever there are no dark spaces or diastemas between two teeth, with the space filled by the gingival papilla, the area of the connector spaces will be delimited by the papillary tips and the contact points. As such, using the papillary line and the contact points line as

reference, we will have a band named "connector band". The figure of this band resembles the shape of a "hang glider" (Fig 12). Small changes in this band can make a difference in dental aesthetics. Dental remodeling can increase or decrease the connector space, resulting in an improved configuration of the area (Fig 13).

Clinical Application

The clinical evaluation of DDAR with the four lines and connector band will permit the use of a checklist that will be able to detect errors in tooth positions and their relationship to the gingiva. By observing the form of each line, a plan can be drawn focusing on correcting the defects, harmonizing the lines, and later evaluating the achieved results. This evaluation facilitates the diagnosis and makes it easier and more practical for all professionals who treat aesthetic problems to detect problems (Fig 14).

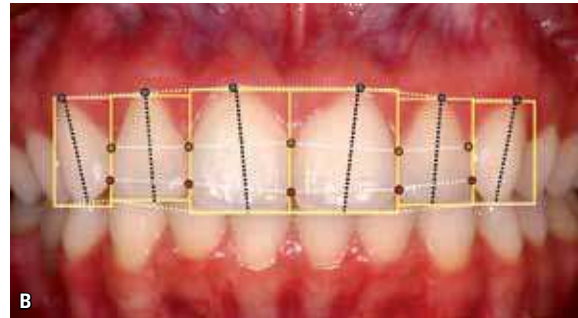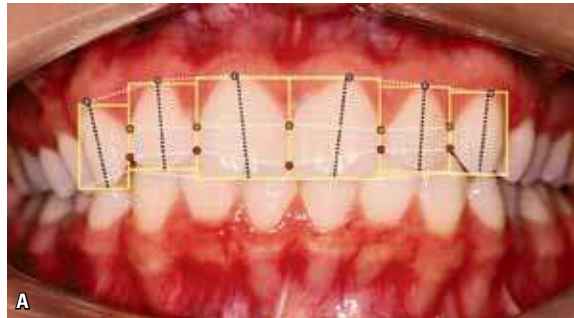


FIGURE 14 - CHECKLIST – Cervical line: concave (accentuated) and asymmetrical. Incisal line: inverted “deep plate” form (concave) and asymmetrical. Connector band: 30% (13/12) – 20% (12/11) – 40% (11/21) – 20% (21-22) – 20% (22/23) (A). CHECKLIST – Cervical line: concave (slight) and symmetrical. Incisal line: “deep plate” form (convex) and symmetrical. Connector band: 30% (13/12) – 35% (12/11) – 40% (11/21) – 35% (21/22) – 30% (22/23) (B).

Lip analysis

In addition to teeth, DDAR also involves the lips. After the labial evaluation, the six horizontal smile lines are found – in addition to the four dento-gingival lines, there are the upper and lower lip lines. Both the upper and lower lips have a marked effect on the beauty of the smile. Individually, each lip will influence the dentolabial ensemble, and together they will create figures that will determine the visible tooth exposure. The lip separation that occurs during smiling will permit the exposure of dental and gingival structures. This separation can be called “labial unveiling”, as it will be this unveiling that will give the dental work a chance to be shown (Fig 15). Labial unveiling is what makes possible the evaluation of the relationship between the white (teeth) and pink (gums) aesthetics, and their relationship with the lips. The three-dimensional relationship these structures have with one another is what will cause the effect of beauty or not.

This concept is essential, as it leads to the need to know a series of factors that influence that unveiling. The greater or lesser tooth exposure will be influenced by labial unveiling and all intrinsic factors to it, such as its formation, stages, phases and lip involvement. As such, before we begin evaluating the upper and lower lip lines, we will present the factors that affect the smile.

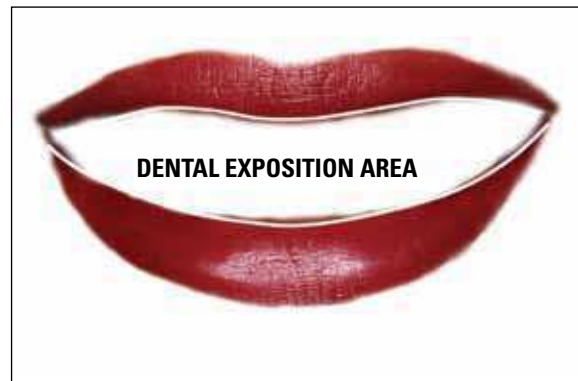


FIGURE 15 - “Labial unveiling”.

Smile formation

The smile can be defined as a change in facial expression that involves a sparkle in the eyes, an upper curvature in the corners of the lips, no sound emission, and less distortion of muscle forms than with a laugh.¹² It begins at the commissure and extends laterally; the lips may initially remain in contact, except in people who do not feature passive lip seal or have a short upper lip. As the smile expands, the lips separate, the commissures curve upwards, and the teeth are exposed. The maxillaries are separated, and a dark space develops between upper and lower teeth, known as negative space.¹⁸ During smiling, upper lip height is diminished, and the width of the mouth is increased by 23% to 28% compared to the lip at rest.²⁶

The symmetry of muscle activity should not be overestimated. In normal people, individual variability of motor function is observed between different sides of the same individual. Combined measurements, both of skin mobility and muscle activity, indicate that there is an average asymmetry of 64% between the sides of the human face.⁴

Stages of the smile

In smile analysis, its stages should be observed. There are two stages in smile formation: the first (voluntary smile) elevates the upper lip towards the nasolabial groove through the contraction of the elevator muscles that originate in this groove and are inserted in the lip. The medial bundles elevate the lip in the area of the anterior teeth, and the lateral bundles act on the area of the posterior teeth. The lip then finds resistance due to the adipose tissue in the cheeks. The second stage (spontaneous smile) begins with higher elevation, both in the lip and in the nasolabial groove, under the action of three muscle groups: the elevator of the upper lip, originating in the infraorbital area; the zygomatic major muscle and the upper fibers of the buccinator muscle.²³

The appearance of half-shut eyes should accompany the final stage and represents the contraction of the periocular musculature (orbicular muscles of the eyes), in order to support the maximum elevation of the upper lip through the nasolabial fold. The half-shut look that accompanies the smile is a muscular trigger of the face that activates the centers in the temporal anterior area of the brain, which regulates the production of pleasant emotions. Therefore, without this final action of semi-closure of the eyes, the noticeable happy smile is probably a false smile, without joy from the person who gives it⁹ (Fig 16).

Phases of the smile

In addition to the stages, the smile also follows phases. These phases are threefold: the first is named the initial “peak” phase, which corresponds to the period in which the lips depart from a neutral position until the position of maximum lip contraction during the spontaneous smile. During this phase, mouth width is increased and lip height is reduced, the commissures move upwards and sideways in the same ratio, with great individual variability in the direction of the movement of these points. It is

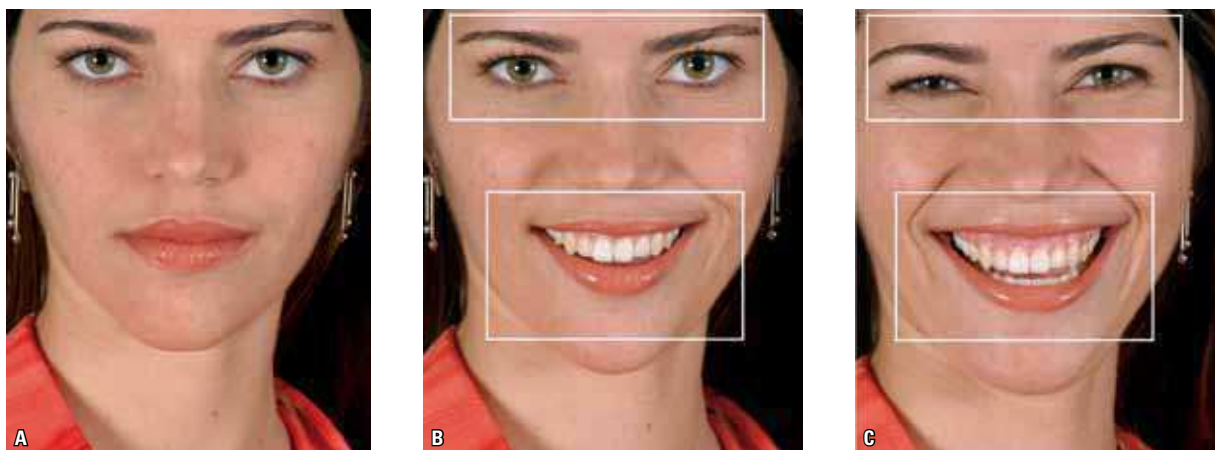


FIGURE 16 - Resting position (A). First stage of the smile – Social smile (B). Second stage of the smile – Spontaneous smile. Notice that in this stage the patient's eyes are half-shut. (C).

the shortest phase of the cycle, lasting on average less than 0.5 second. The second phase is lip support. It is during this phase that the smile is dependent on stimulus. The duration of this phase is quite variable and depends on individual volition. The last phase is the decline, in which the lips close again. The duration of this phase is usually longer than the initial peak phase, but as with the support phase, it is not possible to measure its duration because it is subject to a stimulus. In evaluating the smile cycle, it can be observed that the only reproducible phase is the initial one. Unlike the other phases, which can be influenced by individual volition, the peak phase depends only on the initial stimulus that causes the smile, although its duration is extremely brief.²⁶ This hinders the collection of static images, such as photographs, as it is practically impossible to record the maximum smile obtained during the first phase. That is why several authors advise against evaluating the smile using photographic images, recommending instead that video images be taken.^{1,24}

Stimulating and recording the smile

Although 18 types of smiles have been recorded,⁹ the smile that directly interests the field of dentistry is the one that expresses joy. This is the smile type known as Duchenne, in which there is a contraction of the orbicular musculature of the eyes combined with traction of the corner of the lip by the zygomatic major muscle; among the different types of smiles, it is the one that best demonstrates satisfaction or happiness. It is the spontaneous smile.⁹ As such, the smile that expresses pleasure is the type that professionals seek to record. For that type of record, a stimulus is necessary. In this case, the stimulus becomes a problem, as what is funny to one person is not so to another. The difficulty in obtaining photographs that represent the patient's natural smile in clinical practice was observed by Rigsbee et al,²² who reported that the interac-

tion of the photographing professional and the patient should not be underestimated, and suggested the use of phrases to obtain the picture. This method is also recommended by Zachrisson³⁰, who suggests the use of the word "cheese" to stimulate the exposure of the incisors during smiling. For records of the resting position, the author recommended that teeth be slightly apart, and that perioral soft tissues and the mandibular position be relaxed.³⁰ Although the use of phrases can be useful, the best way to obtain a smile is through comic stimulus. The use of videos, photographs, or even the professional's comic ability can be used to provoke the stimulus. What is important is that the stimulus causes a smile that expresses pleasure. For evaluations that involve the relationship between the teeth and upper lip, it is recommended, in spite of possible questioning, that the patient pronounce the sound of the letter "e" in an uninhibited and exaggerated manner. This causes the maximum elevation of the upper lip.²¹

Recording the smile is another problem. The ideal is that static (photographs) and moving (video) records be made. In the static records, image gathering should include close-up shots in frontal, sagittal, and oblique planes. For the moving records, video should be recorded and uploaded to a computer, and the best image selected.^{24,25} During the evaluation, preference can be given to the social or spontaneous smile with maximum elevation of the upper lip. What is important is that the initial record be the same as the final record, so that differences can be evaluated without interference from the different stages. In other words, if the first record was made in stage 1, so should the final record.

UPPER LIP LINE

The upper lip line represents the lower edge of the lip, and dictates the exposure of upper teeth. Not only anterior teeth have their exposure limited by this line, but posterior teeth as

well. Several authors recommend that during smiling, the position of the lower edge of the upper lip should coincide with the gingival edge of the maxillary central incisor.^{14,15,17} However, other authors consider that a smile could be aesthetically acceptable with exposure of up to 2 mm of gingival tissue.^{3,10,30} This difference in opinions leads to inadequate and confusing concepts that do not help the standardization of smile classifications. Although the simplest way to classify the smile line—using the relationship between the maxillary incisors and the upper lip—is through height (low, medium, and high), the description of the parameters is still inadequate. For example, the classification of smile heights as described by Tjan et al²⁹ used by Dong et al,⁸ regards as high any smile in which the crown of the maxillary central incisor is totally exposed. Therefore, a smile with a band of gingival tissue only 1 mm thick would receive the same classification as a smile with, for instance, 5 mm of gingival tissue exposure. The same can be said of the classification described by Teo,²⁸ which classifies as Class I all smiles in which the buccal surface of the incisor is totally exposed, regardless of the amount of visible gingival tissue. Likewise, the classification of a smile when the upper lip does not expose the maxillary incisors is also confusing in the descriptions by some authors.^{3,11} In the Goldstein¹¹ classification, a smile featuring the upper lip covering only 1 mm of the crown of the maxillary central incisor will receive the same classification as another smile with the upper lip covering more than half or even the entire crown of the maxillary central incisor.

As previously mentioned, the ideal is for the height of the smile line to be classified using as reference the relationship between the lower edge of the upper lip and the gingival edge of the maxillary central incisor. However, a 2 mm limit should be established above and below the gingival edge, thus instituting the three classes of smile height: high, medium, and low (Fig 17).

As such, a positive aspect is that, with a 4 mm difference, the differentiation of high and low smiles—the smile types that lead patients to seek treatment—is clinically facilitated.²¹ Moreover, a numeric differentiation is created among the heights, making it easier to measure their classification.

Smile height is influenced by age and gender. The older the individual, the greater is the tendency for a low-type smile.⁷ This piece of information is clinically relevant, as high smiles tend to become medium smiles with age, and low smiles become even lower over time. In other words, there is a possibility of self-correction for “gingival” smiles over time, which is not true for low smiles.

Gender also seems to influence smile height. Although not many studies exist on the subject, the work of Puppin²¹ shows that there is a greater tendency for women to show medium (55.9%) and high (37.7%) smile lines, while men feature medium (54%) and low (23.8%) smile lines. These findings are similar to the values found in the work of Peck, Peck and Kataja,²⁰ who also observed that medium (52.2%) and high (32.5%) smiles are more common in women and that medium (48%) and low (33%) smiles prevail in men.

The smile line can be regarded as a determining factor in the evaluation of mouth aesthetics.

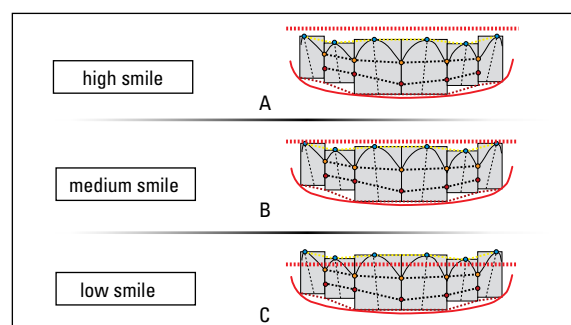


FIGURE 17 - High smile (A); medium smile (B); low smile (C).

The aesthetic results of orthodontic treatments always maintain a strong relationship to this line. It is not uncommon for the conclusion of orthodontic treatments to be compromised by the smile line. Either high or low smiles can compromise the results. This is perhaps the great challenge of contemporary orthodontics in its search for excellence. The integration between the different dentistry specialties will need to be expanded also to the medical fields that can positively interfere in the solution of mouth aesthetic problems that are compromised by the negative influence of the smile line, in particular the upper lip line. Medical and dental interventions that are able to correct a negative labial influence are always welcome. This integrated approach by professional teams will bring new possibilities of better results, expanding treatment options, and perhaps creating a higher demand for the solution of problems involving mouth, facial and dental aesthetics.

LOWER LIP LINE

Although the lower lip line is less studied than the upper lip line, it is no less important. It consists of the group formed by the upper and lower lips that will produce labial unveiling.

In general, it is the shape of the lower lip and the incisal edges of maxillary and mandibular tips that create a pleasing or unpleasing smile ensemble.²⁵ What is important is that the maxillary incisal plane and the shape of the lower lip retain a harmonious relationship.³⁰ That harmony is represented in the parallelism of the arch formed the incisal edges of maxillary teeth with the upper edge of the lower lip.

There should be harmony between the curvature of the incisal edge of anterior maxillary teeth with the curvature of the upper edge of the lower lip during voluntary smiling.¹¹ This relationship between the incisal edges of canines and maxillary incisors with the lower lip is called the smile arch.^{10,24} The ideal is for the curvature

of incisal edges to be parallel to the lower lip and the incisal edges slightly apart or softly touching the lip. However, this is only possible when the lower lip creates a natural curvature, with the corners of the mouth turned upwards, and incisal edges follow that curvature. In other words, in order to achieve a pleasing effect, it is necessary that dental and labial structures be symmetrical. In case the lips or teeth limit the parallelism between them, the smile arch will not be possible. Labial asymmetry is also a limiting factor for this harmony between teeth and lip.

As previously mentioned, the ideal is that the line formed by the incisal edges of anterior teeth creates the form of a “deep plate”, in which the central incisors are positioned more inferior to the lateral incisors and canines, and are in harmony with the other smile lines⁵ (Fig 18).

This configuration varies with age. As age advances, the “deep plate” form is altered, giving way to a new “shallow plate” or “inverted plate” form. That is, the line that contours the incisal edge becomes plainer or more concave. The wear in the incisal edges creates these new forms over time. Knowledge of these characteristics creates the possibility of rejuvenating or aging a smile. A change in the “plate forms” can make this effect possible⁵ (Fig 19).

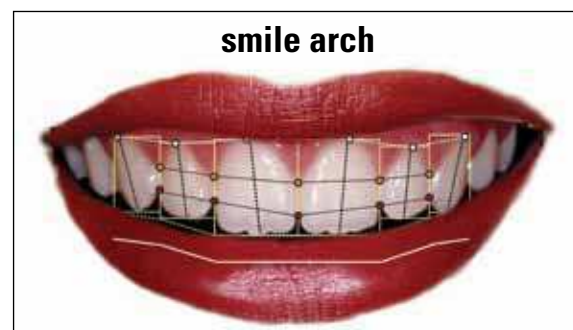

FIGURE 18 - The vertical positioning of the maxillary incisors and canines forms a curvature; the line that contours this relationship resembles the figure of a “deep plate”.

It should be clear that the ideal relationship of parallelism between maxillary teeth and lower lip is dictated by the lip. The contraction pattern of the lower lips and their relationship with teeth are much less uniform than those of the upper lips. Whereas in the relationship between the upper lip and maxillary teeth it is possible to establish three defined positions with regard to the smile line (high, medium, and low), the same is not possible with the lower lip. The smile's own dynamics complicate this evaluation. The possibility of an individual opening his mouth wider or not makes a standardized evaluation more difficult. Maxillary teeth may occasionally touch the lower lip (contact position), remain apart (non-contact position), or else be covered by the lip (covered position).¹⁰ This situation can vary among individuals or even in the same person depending on mouth opening. The muscle contractions of the lower lip also alter this relationship. Muscles such as the risorius, mentalis, triangularis and quadratus of the lower lip are responsible for the contraction of the lower lip and its greater or lesser participation during smiling interferes in labial contraction and symmetry.²³ Variations in the contraction and intensity of muscle groups play an important role in the creation of different smiles.

Vigorous contractions pull down the lower lip, increasing tooth exposure. Individuals with intense contractions of the lower lip tend to also expose their lower teeth (Fig 20).

This situation requires attention, as the needs and possibilities of the aesthetic treatment change perspective, because the evaluation is usually made of the relationship between the lips and maxillary teeth, and not the full arch. Seeking parallelism between the incisal line and the lower lip (smile arch) is totally unfeasible, showing us that establishing aesthetic rules and objectives by taking the lower lip in consideration does not allow standardizations. Another situation that also creates difficulties in obtaining the smile arch is when the lower lip contracts in an inverted fashion; the contraction of the lower lip is greater in the area of the canines than in the area of the incisors, possibly due to greater action by the risorius muscle. When the upper lip also contracts in the same manner, the appearance of “mirroring” is created between the lips. This lower lip contour is usually accompanied by a low smile line and the figure formed by the lips resembles the infinity symbol (∞). (Fig 21). This “infinity-type” smile figure indicates an unfavorable prognosis for mouth aesthetic treatments.

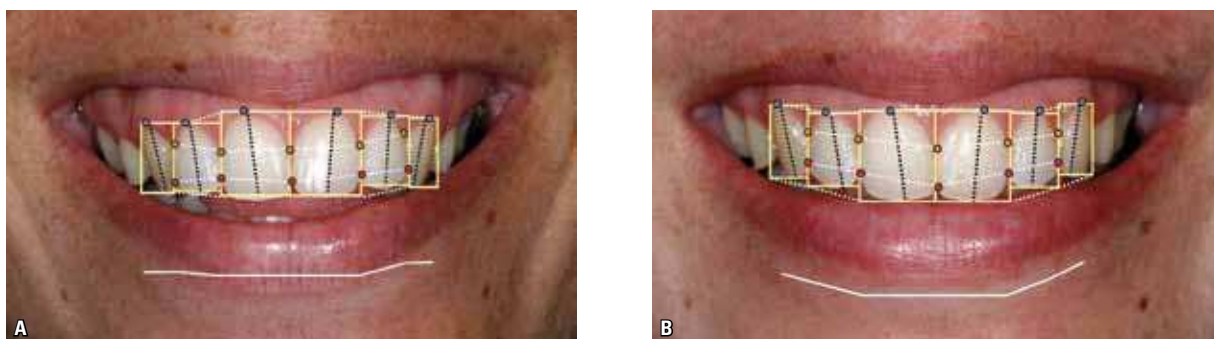


FIGURE 19 - The vertical repositioning of the maxillary incisors and canines, after an ortho-surgical treatment featuring maxillary impaction and rotation, resulted in an improved relationship between the incisal edges of the maxillary anterior teeth and the lower lip, creating the “deep plate” figure. This convex line gives a more pleasing and jovial aesthetic aspect (A, B).

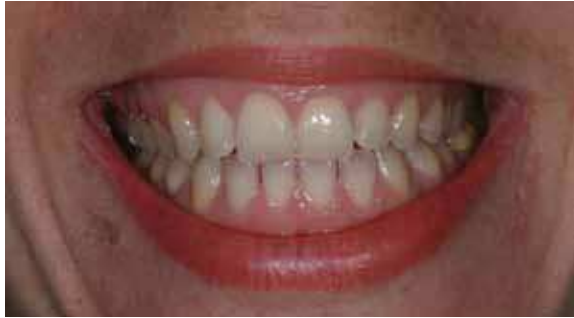

FIGURE 20 - Excessive contraction of the lower lip, completely exposing the mandibular incisors.

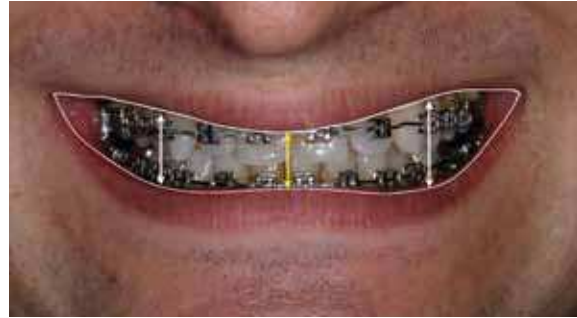


FIGURE 21 - "Mirroring" of lower lip and upper lip forms. Notice that the area of the lower lip (yellow arrow) is closer to the upper lip than the lateral areas (white arrows). The figure formed by the lips resembles the infinity symbol (∞).

CONCLUSION

Knowledge of the intrinsic characteristics of the smile helps in the aesthetic perception of it. Being able to evaluate the smile of each patient assures the professional of the possibility of seeing what needs to be done, what can be done, and what should be accepted. In other words, being able to interpret the nuances of a smile gives each orthodontist the opportunity to act in a conscious manner in the mouth aesthetic treatment of their patients, allowing the diagnosis to be integrated with the prognosis and giving a realistic outlook of the results than can be obtained. In that perspective, the six horizontal smile lines meet this purpose, as the analysis of these lines facilitates the understanding of the intrinsic characteristics of the smile and gives each professional a better look into their chances for success. Nevertheless, we know that observing the six lines is not enough to evaluate a smile. Several other factors also need to be taken in consideration. Buccal corridor, number of exposed teeth during smiling, frontal, oblique and profile facial analyses, relationship between resting and speech positions and the smile are some factors that should also be observed in order to achieve a better diagnosis of mouth aesthetics. Although these components were not examined in this work,

they should not be ignored, as, along with the six lines, they can allow a complete observation of the smile, facilitating its understanding and treatment possibilities.

ACKNOWLEDGEMENTS

Adilson Torreão, Adilson Torreão Filho, Aldino Puppim, Isana Álvares, Jonas Capelli Jr., Marco Antônio Almeida, Vera Cosendey.

Submitted: March 2009
Revised and accepted: December 2009

REFERENCES

1. Ackerman MB, Ackerman JL. Smile analysis and design in the digital era. *J Clin Orthod*. 2002 Apr;36(4):221-36.
2. Andrews LF. *Straight-Wire: the concept and appliance*. San Diego: Wells; 1989.
3. Arnet GW, Bergman RT. Facial keys to orthodontic diagnosis and treatment planning. Part I. *Am J Orthod Dentofacial Orthop*. 1993 Apr;103(4):299-312.
4. Burres SA. Facial biomechanics: the standards of normal. *Laryngoscope*. 1985 Jun;95(6):708-14.
5. Câmara CALP. *Estética em Ortodontia: diagramas de referências estéticas dentárias (DRED) e Faciais (DREF)*. Rev Dental Press Ortod Ortop Facial. 2006 nov/dez;11(6):130-56.
6. Chiche G, Pinault A. Artistic and scientific principles applied to esthetic dentistry. In: Chiche G, Pinault A. *Esthetics of anterior fixed prosthodontics*. St. Louis: Quintessence; 1994. p. 13-32.
7. Cosendey V L. *Avaliação do relacionamento entre o lábio superior e incisivos durante a fala e o sorriso*. [dissertação]. Rio de Janeiro (RJ): Universidade do Estado do Rio de Janeiro; 2008.
8. Dong J, Jin T, Cho H, Oh S. The esthetics of the smile: a review of some recent studies. *Int J Prosthodont*. 1984 Jan;12(1):16-24.
9. Ekman P, Davidson RJ, Friesen WV. The Duchenne smile: emotion expression and brain physiology II. *J Pers Soc Psychol*. 1990 Feb;58(2):342-53.
10. Fowler P. Orthodontics and orthognathic surgery in the combined treatment of an excessive gummy smile. *New Zealand Dent J*. 1999 Jun;95:53-4.
11. Goldstein RE. *Estética em Odontologia*. Rio de Janeiro: Ed. Guanabara Koogan; 1980.
12. Grove PB. *Webster's third new international dictionary of the English language*. Springfield: G and C Merriam Company; 1961.
13. Kurth JR, Kokich VG. Open gingival embrasures after orthodontic treatment in adults: prevalence and etiology. *Am J Orthod Dentofacial Orthop*. 2001 Aug;120(2):116-23.
14. Legan HL, Burstone CJ. Soft tissue cephalometric analysis for orthognathic surgery. *J Oral Surg*. 1980 Oct;38(10):744-51.
15. Levine RA, McGuire M. The diagnosis and treatment of the gummy smile. *Compend Contin Educ Dent*. 1997 Aug;18(8):757-62, 764; quiz 766.
16. Magne P, Belsler U. *Restaurações adesivas de porcelana na dentição anterior. Uma abordagem biomimética*. São Paulo: Quintessence; 2003.
17. Marckley RJ. An evaluation of smiles before and after orthodontic treatment. *Angle Orthod*. 1993 Fall;63(3):183-9.
18. Mathews TG. The anatomy of a smile. *J Prosthet Dent*. 1978 Feb;39(2):128-34.
19. Morley J, Eubank J. Macro esthetic elements of smile design. *J Am Dent Assoc*. 2001 Jan;132(1):39-45.
20. Peck S, Peck L, Kataja M. Some vertical lineaments of lip position. *Am J Orthod Dentofacial Orthop*. 1992 Jun;101(6):519-24.
21. Puppin FA. *Avaliação quantitativa de medidas dento-faciais relacionadas à altura da linha do sorriso*. [dissertação]. Rio de Janeiro (RJ): Universidade do Estado do Rio de Janeiro; 2002.
22. Rigsbee OH 3rd, Sperry TP, BeGole EA. The influence of facial on smile characteristics. *Int J Adult Orthodon Orthognath Surg*. 1988;3(4):233-9.
23. Rubin LR. The anatomy of a smile: its importance in the treatment of facial paralysis. *Plast Reconstr Surg*. 1974 Apr;53(4):384-7.
24. Sarver DM, Ackerman MB. Dynamic smile visualization and quantification: Part 1. Evolution of the concept and dynamic records for smile capture. *Am J Orthod Dentofacial Orthop*. 2003 Jul;124(1):4-12.
25. Sarver DM. The importance of incisor positioning in the esthetic smile: smile arc. *Am J Orthod Dentofacial Orthop*. 2001 Aug;120(2):98-111.
26. Tarantili VV, Halazonetis DJ, Spyropoulos MN. The spontaneous smile in dynamic motion. *Am J Orthod Dentofacial Orthop*. 2005 Jul;128(1):8-15.
27. Tarnow DP, Magner AW, Fletcher P. The effect of the distance from the contact point to the crest of bone on the presence or absence of the interproximal dental papilla. *J Periodontol*. 1992 Dec;63(12):995-6.
28. Teo CS. An evaluation of the smiling lip line. *Singapore Dent J*. 1981 May;6(1):27-30.
29. Tjan AH, Miller GD, The JG. Some esthetics factors in a smile. *J Prosthet Dent*. 1984 Jan;51(1):24-8.
30. Zachrisson BU. Esthetic factors involved in anterior tooth display and smile: vertical dimension. *J Clin Orthod*. 1998;32(7):432-45.

Contact address

Carlos Alexandre Câmara
 Rua Joaquim Fagundes 597, Tirol
 CEP: 59.022-500 – Natal / RN
 E-mail: cac.ortodontia@digi.com.br