

Assessment of mandibular advancement surgery with 3D CBCT models superimposition

Alexandre Trindade Simões da Motta**, Felipe de Assis Ribeiro Carvalho***, Lúcia Helena Soares Cevidanes****, Marco Antonio de Oliveira Almeida*****

Abstract

Objectives: To assess surgery and short-term post-surgery changes in the position of the condyles, rami and chin after mandibular advancement. **Methods:** Pre-surgery (T1), 1 week post-surgery (T2), and 6 weeks post-surgery (T3) CBCT scans were acquired for 20 retrognathic patients with short or normal face height. Three-dimensional models were built and superimposed through a fully automated voxel-wise method using the cranial base of the pre-surgery scan as reference. Anatomic regions of interest were selected and analyzed separately. Within-subject surface distances between T1-T2, T2-T3, T1-T3 were computed. Color-coded maps and semi-transparent display of overlaid structures allowed the evaluation of displacement directions. **Results:** After an antero-inferior chin displacement with surgery in all cases (>4 mm in 87.5%), 25% of the patients showed some kind of posterior movement (<3 mm), and 69% showed an antero-superior movement after splint removal. Comparing T1-T3, an antero-inferior (87.5% of the cases) or only inferior (12.5%) displacement was observed (>4 mm in 80%). Considering all directions of displacement, the surface distance differences for the condyles and rami were small: 77.5% of the condyles moved <2 mm with surgery (T1-T2), and 90% moved <2 mm in the short-term (T2-T3) and in the total evaluation (T1-T3), while the rami showed a <3 mm change with surgery in 72.5% of the cases, and a <2 mm change in 87.5% (T2-T3) and in 82% (T1-T3). **Conclusions:** Expected displacements with surgery were observed and post-surgery changes suggested a short-term adaptive response toward recovery of condyle and ramus displacements. The changes on the chin following splint removal suggested an acceptable adaptation, but with considerable individual variability.

Keyword: Cone-Beam Computed Tomography. Image processing. Computer-assisted surgery. Computer simulation. Orthodontics. Oral surgery.

Editor's abstract

It seems that changes occur in condylar position after bilateral sagittal split ramus osteotomy

(BSSO) to advance the mandible,⁴ and both rotation and transverse displacement of the condyles related to ramus surgery have been described.¹

* Access www.dentalpress.com.br/journal to read the full article.

** DDS, MS, PhD; Professor, Department of Orthodontics, Fluminense Federal University (UFF/Niterói, RJ, Brazil); Visiting Scholar, University of North Carolina at Chapel Hill (UNC).

*** DDS, MS; PhD Student, Department of Orthodontics, State University of Rio de Janeiro (UERJ), Visiting Scholar (UNC).

**** DDS, MS, PhD; Professor, Department of Orthodontics (UNC/Chapel Hill).

***** DDS, MS, PhD; Professor and Chair, Department of Orthodontics (UERJ), Post-doctoral Fellow (UNC).

Otherwise, the extent to which mandibular structures rotations/displacements and bone remodeling/resorption contribute to posttreatment instability are poorly understood at present. Previous studies based in standardized norms and bidimensional (2D) representation of 3D changes could not answer many questions related to factors influencing treatment response and skeletal remodeling.³ Investigations using cone-beam computed tomography (CBCT)⁵ in Orthodontics and Oral-Maxillofacial Surgery have shown that this new tool can improve the identification of different patterns of rami and condyles positioning after orthognathic surgery.² The purpose of this study was to evaluate the displacements at the chin, condyles and rami between presurgery, postsurgery, and splint removal through 3D models superimposition.

Twenty patients presenting skeletal Class II and consecutively treated at the Dentofacial Deformities Program at the School of Dentistry, University of North Carolina (UNC), were recruited for this study, and underwent orthodontic treatment and had mandibular advancement surgery by means of a bilateral sagittal split osteotomy (BSSO). The scans were taken one week before surgery (T1), one week after surgery (T2), to assess changes with the surgical procedure, and six weeks after surgery (T3), immediately after splint removal to assess short-term adaptive changes. Image segmentation of the anatomic structures of interest and the 3D graphic rendering were done by using the InsightSNAP software (<http://www.itksnap.org/>). The pre-surgery and post-surgery models were registered based on the cranial base, since this structure is not altered by surgery. A fully automated voxel-wise rigid registration method was used through the Imagine free software (<http://www.ia.unc.edu/dev/download/>). The software compares both images using the intensity of grayscale for each voxel of the region, so that the pre-surgical cranial base (T1) was used as ref-

erence for the superimposition of post-surgery models (T2 and T3). To control the cropping for a quantitative analysis of regions of interest such as the condyles, the posterior border of the rami and chin, the 3D models at different time points of each patient were combined also with the *Imagine* tool. Each region of interest of each phase was prepared for pair comparisons, and was then analyzed separately with MeshValmet (<http://www.ia.unc.edu/dev/download/>), where measurements of the surface distances between two different time points within the same subject allowed quantification of rami, condyles and chin displacements that accompanied mandibular surgery. The visualization of the directions of displacement was done through color maps and semitransparencies methods (Fig 1). Descriptive statistics was done and illustrated in graphics of direction and amount of displacement for each anatomic region.

In this short-term observation 25% of the patients showed some posterior movement at the chin after splint removal. These few cases showed less than 3 mm displacements between T2-T3, and when compared to superimpositions T1-T2 and T1-T3 a high similarity in the color maps (area and intensity of red surfaces corresponding to mandibular advancement) could be visually observed, as well as in the difference between solid white and transparent red in the semi-transparencies (Fig 2). Rami and condyles displacements were considered clinically relevant, even so were concentrated under 3 mm and 2 mm, respectively, and chin position was kept stable. Actually, the results suggest that an important recovery tendency toward preoperative positions occurred after splint was removed and mandibular function resumed. Otherwise, some cases showed a larger displacement in the proximal segment that could be maintained even after a long-term follow-up. Since condylar displacements concentrated under 2 mm, clinical effects are questionable and long-term

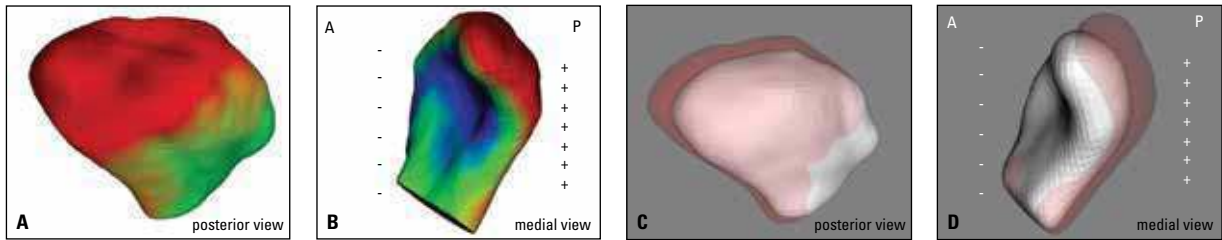


FIGURE 1 - Visualization of a right condyle displacement between T1 and T2. **A, B**) Color coded maps indicate outward displacements in red and inward displacements in blue. **C, D**) Semi-transparencies with T1 in solid white and T2 in transparent red (A = anterior, P = posterior).

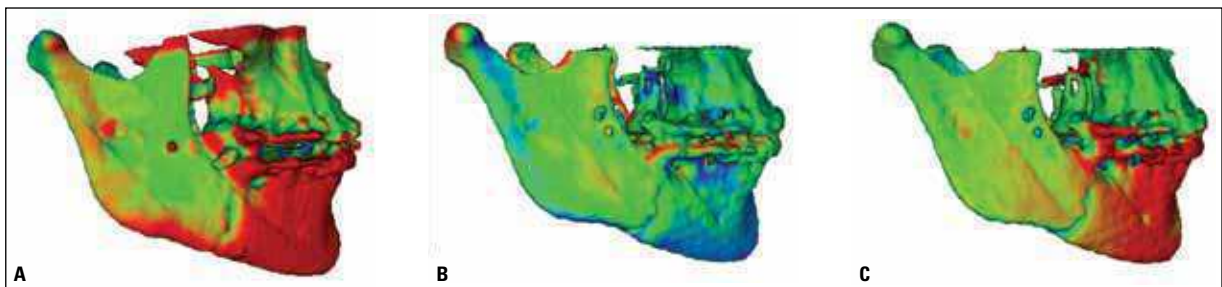


FIGURE 2 - Superimpositions between pre-surgery to immediately post-surgery with splint in place (**A**), immediately post-surgery to splint removal (**B**), and pre-surgery to splint removal (**C**). Some posterior (inward) movement of the chin is noted in B, shown by the blue color code. It can also be noted by the comparison between different area and density of red surfaces representing the anterior (outward) displacement in A and C. Still, the resultant superimposition in C shows an acceptable maxillomandibular relation at splint removal, considered a short-term stability. The right ramus shows a slight lateral movement in A (outward), a recovery tendency in B (inward), and green surfaces in C confirming the adaptive response.

follow-ups are needed to show if changes were small enough to allow adaptive remodeling without side effects. Condyles latero-posterior and rami latero-posterior-inferior changes between T1-T2 could result from pressure during the BSSO, fragment sliding and rigid fixation, followed by medio-anterior and medio-anterior-superior displacements between T2-T3 as a recovery toward initial positions due to muscular stretch.

Important displacements with surgery were observed in the rami and condyles, but changes at splint removal suggested an adaptive response toward recovery of pre-surgery positions, especially the medio-lateral movement of the rami. The changes on the chin after six weeks suggested an overall acceptable adaptation, but with considerable individual variability.

Questions

1. Which are the advantages and benefits of cone beam computed tomography as a study methodology in Orthodontics?

Some advantages have been described in the literature and could be also noted during this experiment. Primarily, advantages of CBCT over radiographic projections can be mentioned, acquiring a complete image set of all the craniofacial complex with only one scan, without superimposed or distorted structures. Also, differently from 2D radiographic projection acquisitions which require head positioning standardization, tomographic slices can be obtained without such standards as the whole 3D craniofacial complex is captured. A favorable spatial resolution and tooth/bone contrast recommend this method for Dentistry needs. Depending on the equipment, radiation

dose can be comparable to a complete periapical exam, and is considerably smaller than reported doses for conventional CT.

Overall CBCT applications can be divided in: (1) Analysis of tomographic slices, allowing navigation through them using any software running DICOM files; (2) Radiographic emulation using commercial softwares, generating lateral and frontal cephalometric, panoramic or submentovertex images; (3) Study of 3D rapid reconstructions or volume segmentations generated from commercial or public software; (4) 3D cephalometry, calculating measurements from landmarks established on tomographic slices or on 3D model surfaces; (5) Facial analysis, using soft tissue segmentation on 3D models or linking 3D camera photography and volume rendering; (6) 3D superimposition, using the methodology from this study, thoroughly described in our paper in press.⁶

Cone-beam CT images allow clinical observation of: impacted teeth and ectopic eruption; pathologies among radicular spaces; third molars proximity to noble structures such as the alveolar inferior nerve; alveolar bone width and height; arch size and form for orthodontic movement; condylar findings, i.e. anatomic asymmetries; determination of ideal microimplant sites, etc. Preliminary studies have suggested CBCT applications in analysis of the dentition, building of virtual dental casts without impressions and planning with virtual set-up.

2. Are there limitations associated to tridimensional image manipulation?

Working with 3D images on research purposes can be difficult and challenging, especially regarding the generation of accurate volumetric reconstructions that should include all the anatomic regions of orthodontic and surgical interest. Mandibular condyles, for example, are really hard to segment because of its anatomic shape and bone density, thus requiring specific procedures, more manual and less automatic, to determine reliable

surfaces. Some maxillary surfaces can be also difficult to reconstruct, especially those around the sinuses, because of its thin trabecular bone. Rapid reconstructions generated from the available commercial softwares (VRT, volume rendering technique) are precise enough for visualization purposes, and can also allow 3D measuring based on landmarks established on tomographic slices. Otherwise, the current methodology requires the segmentation of virtual models with 3D surfaces (SSD, shaded surface display) that allow superimposition and quantification of displacements throughout different time-points, so voxels of the tomographic image should be "filled out", i.e., the tomographic slices are actually built into volumetric images. Besides the drawbacks, the use of three-dimensional images can represent a step forward in Orthodontics, where many studies carried out before with 2D methods will be revalidated through more complete and complex observations, highlighting important information never seen due to methodological limitations.

REFERENCES

1. Becktor JP, Rebellato J, Becktor KB, Isaksson S, Vickers PD, Keller EE. Transverse displacement of the proximal segment after bilateral sagittal osteotomy. *J Oral Maxillofac Surg.* 2002 Apr;60(4):395-403.
2. Cevidanes LH, Bailey LJ, Tucker GR Jr, Styner MA, Mol A, Phillips CL, Proffit WR, Turvey T. Superimposition of 3D cone-beam CT models of orthognathic surgery patients. *Dentomaxillofac Radiol.* 2005 Nov;34(6):369-75.
3. Harrell WE Jr, Hatcher DC, Bolt RL. In search of anatomic truth: 3-dimensional digital modeling and the future of Orthodontics. *Am J Orthod Dentofacial Orthop.* 2002 Sep;122(3):325-30.
4. Harris MD, Van Sickels JE, Alder M. Factors influencing condylar position after the bilateral sagittal split osteotomy fixed with bicortical screws. *J Oral Maxillofac Surg.* 1999 Jun;57(6):650-4.
5. Mozzo P, Procacci C, Tacconi A, Martini PT, Andreis IA. A new volumetric CT machine for dental imaging based on the cone-beam technique: preliminary results. *Eur Radiol.* 1998;8(9):1558-64.
6. Motta AT, Carvalho FR, Oliveira A, Cevidanes LHS, Almeida MA. Superposição automatizada de modelos tomográficos tridimensionais em cirurgia ortognática. *Dental Press J Orthod* (in press).

Contact address

Alexandre Trindade Simões da Motta
Av. das Américas, 3500 - Bloco 7/sala 220 – Ed. Hong Kong 3000
CEP: 22.640-102 – Barra da Tijuca – Rio de Janeiro/RJ
E-mail: alemotta@rjnet.com.br