

Analysis of skeletal maturation in patients aged 13 to 20 years by means of hand wrist radiographs

Yasmine Bitencourt Emílio Mendes*, Juliana Roderjan Bergmann**, Marina Fonseca Pellissari**, Sérgio Paulo Hilgenberg***, Ulisses Coelho****

Abstract

Objectives: Evaluate an alternative and simplified radiographic method that will enable implantologists and orthodontists to keep track of bone growth completion as well as differences between genders in a sample of individuals from 13 to 20 years of age. **Methods:** A hand wrist radiograph was acquired with the use of occlusal radiographic film to assess the maturation of the radius bone. One hundred and sixty patients of both genders were divided into groups of 10 individuals. The radiographs were examined by five raters using applicable rating standards, all specialists in orthodontics. **Results:** The results showed that there was a positive correlation between the chronological age of the patients and their biological age, whereas female bone maturation occurs earlier than in males. **Conclusion:** This method can determine the stage of maturation of the radius bone, allowing an affordable means of diagnosis and rapid determination of bone age for correct installation of an implant and/or orthodontic appliance.

Keywords: Maturity. Tooth movement. Dental implant.

INTRODUCTION

Understanding the events of craniofacial growth is of paramount importance in dental practice.¹⁰ Knowing the patient's exact stage of maturity and the period of occurrence of the pubertal growth spurt (PGS) may influence not only diagnosis and prognosis, but also the development of a treatment plan.²⁴ Thus, this knowledge is considered convenient for orthodontic treatments that

require the use of devices influenced by the stage of maturation of the craniofacial complex.²⁸ This growth stage also helps in preparing the treatment plan, especially in defining surgical procedures.¹⁵

It was recognized long ago that the chronological age of an individual does not necessarily coincide with their maturational age. A person's skeletal development may be delayed or advanced in various degrees of divergence from their actual

* Master's candidate in Dentistry; area of concentration Restorative Dentistry, Universidade Estadual de Ponta Grossa (UEPG).

** Surgeon Dentists.

*** Master of Dentistry; area of concentration Integrated Clinical Practice – UEPG. Postgraduate student specializing in Orthodontics - (UEPG).

**** Adjunct Professor of Orthodontics - UEPG. Orthodontics Specialist from Universidade de São Paulo (USP-Bauru); Master and Doctor of Orthodontics from Unesp - Araraquara/SP.

current chronological age.⁹ Therefore, chronological age is not always a good parameter for the correct evaluation of the body's maturation stage because, for example, the PGS does not occur at the same time in all individuals.²⁰ Biological age is more reliable since it is reported as the body's development towards maturity, which encompasses anatomical changes, dental and skeletal maturation, development of secondary sexual characteristics, hormonal function and enzyme activity, even if those mechanisms are influenced by genetic factors, socio-economic, environmental, nutritional and gender-related conditions.⁴

According to Rigertz and Eklöf,⁸ Caffey (1961) consider that the ideal method for assessing skeletal maturity should include a study of the whole skeleton. However, these authors⁸ affirm that due to practical and economic reasons this is not only impossible but also incompatible with the efforts to reduce exposure to radiation. The difficulties in finding a procedure that combines a simple and accurate definition of normal variations with reasonable statistical confidence have surfaced in the design of different methods.^{1,3,5,8,19,27}

In contemporary Orthodontics, early correction of various types of malocclusion is rendered easier when it is possible to take advantage of the moments of maximum increment in an individual's facial and overall growth occurring during the PGS.²¹ A patient's growth stage, therefore, proves essential in establishing accurate diagnoses and reliable prognoses.²¹ The stage of bone development can be estimated by means of hand wrist radiographs and through skeletal maturation as visualized in lateral cephalometric radiographs of the cervical vertebrae.²¹

Orthodontic treatment should be performed preferably in very young patients or during their PGS, as it is during this period that facial structures respond more efficiently to the stimuli provided by orthodontic mechanics.²³ Moreover, cases that are treated in later stages do not usually undergo significant skeletal changes as a result

of treatment, with the exception of surgical interventions in the bone bases.²³

The hand wrist has been widely studied and used as an area that helps to determine bone maturation with scientifically proven efficacy. Furthermore, it is a complementary exam that can be easily obtained with an X-ray and used for diagnosis and orthodontic treatment planning.^{12,27} Several investigations have shown that these areas represent the overall maturity of the skeleton and thus are suitable for such evaluation.¹² Similarly, other specialties require knowledge of skeletal maturation, especially Implantology since the aesthetic and functional success of an implant is associated with complete bone maturation.¹³

Therefore, considering the importance of PGS, this study aims to establish an affordable radiographic methodology that will allow dental professionals to assess skeletal maturation and monitor craniofacial growth and the alveolar process, focusing on adolescents aged 13 to 20 years. Additionally, it also seeks to establish the best time for dental implant placement and the most convenient moment to begin orthodontic treatment in this age group.

MATERIALS AND METHODS

This study was approved by the Ethics Committee of the Universidade Estadual de Ponta Grossa - COEP - UEPG, Protocol No. 03569/06, Opinion No. 16/2006.

Hand wrist radiographs were performed with the use of occlusal films on 80 male patients and 80 female patients 13 to 20 years of age, further divided into 10 subjects for each age group totaling 8 groups for each gender. The radiographs allowed an assessment of the degree of maturation and the fusion of the epiphysis with the diaphysis of the radius bone.

The technique consisted of an occlusal film positioned under the wrist, with the palm facing down. With an exposure time of 0.8 seconds, a

40 cm cone was positioned perpendicular to the position of the hand and the film, and the radiographs were acquired. The films were processed using the time and temperature method and, after complete drying and identification, were stored for evaluation.

The evaluation was performed by five specialists in Orthodontics using applicable rating standards, who observed and scored (Fig 1) the stage of maturation of the radius bone. When the epiphysis and diaphysis of the radius bone were either smaller or equal in width, a zero score was assigned; a score of 1 was given when the epiphysis was larger than the diaphysis; a score of 2 when the epiphysis was starting to merge with the diaphysis; a score of 3 when the epiphysis and diaphysis were bound together by a slight radiolucent line; and a score of 4 to indicate the complete and final maturation of bone growth, with no significant difference between epiphysis and diaphysis.

The results obtained by each rater were analyzed by Kappa statistics to establish the Kappa coefficient of agreement. The non-parametric Mann-Whitney test was performed to see if both genders had the same distribution of results. The Spearman correlation test was used to assess the correlation between chronological age and the relative gender scores.

RESULTS

A statistical analysis of the data showed that the average level of inter-rater agreement was considered good ($\kappa = 0.66$) (Table 1).

The nonparametric Mann-Whitney test yielded a p value of 0.0011, which shows a statistically significant difference between groups due to the fact that the distribution of scores occurred differently in females, with men showing faster results.

The Spearman correlation test showed a value of $p < 0.001$ for both females and males, i.e., scores increased with age (Table 2).

Whereas there was good inter-rater agreement and a statistically significant difference between males and females, and considering that as chronological age advances, the scores will also increase, the next step consisted in evaluating—for both genders—at what age stage 4 (complete fusion of the epiphysis with the diaphysis of the radius bone) occurred significantly. For this the authors used the median values for each age considering the analysis of all raters. The occurrence of stage 4 is significant in females aged 16 years and in males aged 18 years (Graphs 1, 2).

DISCUSSION

The planning and clinical conduct for rehabilitation of patients with partial anodontia, especially






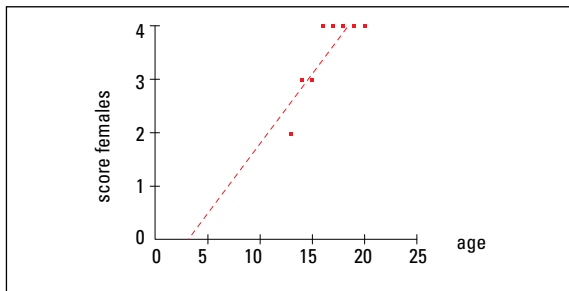
SCORE 0	SCORE 1	SCORE 2	SCORE 3	SCORE 4
				
The epiphysis and diaphysis of the radius bone are equal or smaller in width	The epiphysis is larger than the diaphysis of the radius bone	The epiphysis is starting to merge with the diaphysis of the radius	A slight radiolucent line appears between the epiphysis and diaphysis of the radius bone	The complete maturation and final bone growth are indicated with no significant difference between the epiphysis and diaphysis

FIGURE 1 - Kappa inter-rater agreement coefficient.

TABLE 1 - Kappa inter-rater agreement coefficient.

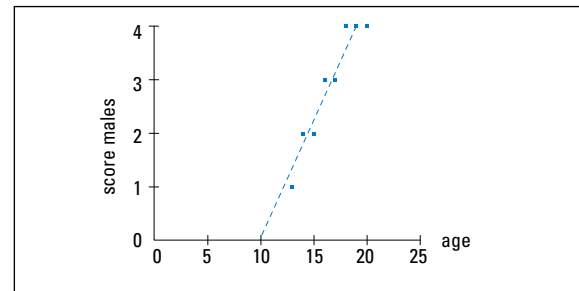
RATER	KAPPA VALUE
rater 1 x rater 2	0.63
rater 1 x rater 3	0.71
rater 1 x rater 4	0.66
rater 1 x rater 5	0.66
Mean Kappa value	0.66



GRAPH 1 - Graphical representation of the relationship between chronological age and female scores.

TABLE 2 - Representation of the Spearman correlation test results for males and females.

	FEMALES	MALES
Spearman coefficient(rs)	0.7314	0.8599
p-value	< 0.001	< 0.001



GRAPH 2 - Graphical representation of the relationship between chronological age and male scores.

multiple partial anodontia, is hampered by the decision of when to start treatment and what techniques to adopt.¹³ Thus, as the patient is born with missing teeth, prosthetic rehabilitation should be undertaken as soon as the patient's development is complete.

The patient's bone development can be tracked in various ways, but the use of hand wrist radiographs can provide information on the patient's growth and maturity, which are clinically important in the application of dentofacial diagnosis and orthopedic therapy,^{10,11,14} and more recently, the installation of dental implants. Another way to assess skeletal maturation is accomplished through an analysis of the cervical vertebrae in lateral radiographs, which are part of the orthodontic documentation.²⁶ However, it is suggested that professionals exercise caution in considering cervical vertebrae examination as an absolute method to evaluate skeletal maturation in growing patients for as long as professionals have not yet developed enough familiarity with this method.^{1,7} Thus, it

is believed that carpal index is the most reliable resource for bone assessment given the fact that most professionals are very comfortable using the method, which is not only easy to obtain but involves less radiation exposure.

The patient's exact stage of maturation has been the target of research, which has sought to facilitate its assessment, reduce costs and reduce the exposure of patients to ionizing radiation.^{1,5,18,19,24} Silva Filho et al²⁷ evaluated a simplified alternative method consisting of an X-Ray of the metacarpophalangeal joint area of the thumb, using a radiographic periapical film. In this film the presence of the ulnar sesamoid bone can be observed, in a clear indication that PGS onset will occur within a 1-year period, thereby signaling the correct time for the installation of the orthodontic appliance.

In this study, the authors have attempted to find a fast and secure way for dentists to detect, in their own office, the patient's stage of maturation for the placement of a dental implant and assess

the most suitable time to begin orthodontic treatment of patients aged 13 to 20 years. This was achieved by acquiring an X-ray—using occlusal film—of the radius bone region, which indicates the end of the alveolar bone growth. It should be underscored that in establishing the bone age diagnosis of a patient who will undergo a dental implant surgery, the exclusion of the carpal and metacarpal bones does not significantly influence bone age determination.²⁷ Moreover, this method readily addresses a clinical issue while ensuring less patient exposure to radiation.²⁵

A literature review has revealed a growing concern by orthodontists to establish parallels between a patient's chronological and biological ages.^{9,15} As can be observed in this study, there is a positive correlation between biological age and chronological age, i.e., in this sample, chronological age progressed in tandem with biological age.

Regarding gender differences in terms of bone maturation, the results endorse other studies^{6,16,19,22} which concluded that all events and stages of skeleton growth occur earlier in female than in male individuals.

In this study, most women's readiness to undergo dental implant installation or orthodontic treatment depended on the time of maturation, on their chronological age (16 years) and on complete ossification (score 4) of the radius bone, while most men were able to undergo the same

procedure only at 18 years of age. However, we must consider that some of the individuals—although being the same age—had not completed their growth. Thus, this finding should not be generalized, requiring the mandatory implementation of radiographic examination in all patients who are subjected to such treatment. Nevertheless, the method used in this study has proven an effective alternative to address routine clinical issues related to skeletal maturation.

CONCLUSION

Based on the results and the methodology employed, the authors have concluded that:

1) The method is effective in predicting the skeletal age of the patient. Furthermore, it consists of a practical, quick and accessible method that can assist in the planning of dental implants and orthodontic treatment.

2) There are individual differences for each group, indicating that each individual—regardless of their chronological age—may have a different biological bone age.

Submitted: February 2007
Revised and accepted: August 2009

REFERENCES

1. Armond MC, Castilho JCM, Moraes LC. Estimativa do surto de crescimento puberal pela avaliação das vértebras cervicais em radiografias cefalométricas laterais. *Ortodontia*. 2001;34(1):51-60.
2. Björk A, Helm S. Prediction of the age of maximum puberal growth in body height. *Angle Orthod*. 1967 Apr;37(2):134-43.
3. Bosco VL, Silva RHH. Relação entre crescimento e erupção dentária. *RGO*. 1991;39(3):189-90.
4. Carvalho PL, Ando T, Reis HSM, Pannunzio E. Considerações sobre metodologias de avaliação das idades dental e óssea, em pacientes com idades cronológicas de 3 a 14 anos. *JBP – Rev Ibero Am Odontopediatr Odontol Bebê*. 2005;8(45/46):312-20.
5. Castriota-Scanderbeg A, Sacco MC, Emberti-Gialloreti L, Fraracci L. Skeletal age assessment in children and young adults: comparison between a newly developed sonographic method and conventional methods. *Skeletal Radiol*. 1998 May;27(5):271-7.
6. Chaves AP, Ferreira RI, Araújo TM. Maturação esquelética nas raças branca e negra. *Ortodontia Gaúcha*. 1999 jan/jul;3(1):45-52.
7. Damian MF, Woitichunas FE, Cericato GO, Cechinato F, Moro G, Massochin ME, Castoldi FL. Análise da confiabilidade e da correlação de dois índices de estimativa da maturação esquelética: índice carpal e índice vertebral. *Rev Dent Press Ortod Ortop Facial*. 2006 set/out;11(5):110-20.
8. Eklöf O, Ringertz H. A method for assessment of skeletal maturity. *Ann Radiol*. 1967;10(3-4):330-36.
9. Fishman LS. Chronological versus skeletal age, an evaluation of craniofacial Growth. *Angle Orthod*. 1979;49(3):181-89.
10. Fishman LS. Radiographic evaluation of skeletal maturation. A clinically oriented method base on hand-wrist films. *Angle Orthod*. 1982;52(2):88-112.
11. Fishman LS. Maturational patterns and prediction during adolescence. *Angle Orthod*. 1987 Jul;57(3):178-93.
12. Flores-Mir C, Nebbe B, Major PW. Use of skeletal maturation based on hand-wrist radiographic analysis as a predictor of facial growth: a systematic review. *Angle Orthod*. 2004 Feb;74(1):118-24.
13. Francischone CE, Vasconcelos IW. Osseointegração e as próteses unitárias. 1a ed. São Paulo: Artes Médicas; 1998.
14. Franco AA, Santana AH, Santana IS, Melo MFB, Santos Júnior JH. Determinação radiográfica da maturidade esquelética e sua importância no diagnóstico e tratamento ortodôntico. *Ortodontia*. 1996;29(1):53-9.
15. Guzzi BSS, Carvalho LS. Estudo da maturação óssea em pacientes jovens de ambos os sexos através de radiografias de mão e punho. *Ortodontia*. 2000;33(3):49-57.
16. Hägg U, Taranger J. Skeletal stages of the hand and wrist as indicators of the pubertal growth spurt. *Acta Odontol Scand*. 1980;38(3):187-200.
17. Hägg U, Taranger J. Maturation indicators and the pubertal growth spurt. *Am J Orthod*. 1982 Oct;82(4):299-309.
18. Hamui T, Prata C. Estudo do crescimento maxilar e mandibular na fase de aceleração do surto de crescimento puberal. *Rev Dent Press Ortod Ortop Facial*. 2001 jul/ago;6(4):19-31, 2001.
19. Hilgenberg S, Pinto SCS, Pinheiro JC, Jimenez EEO, Coelho U. Comparação entre as idades óssea, dentária e cronológica por meio de método radiográfico simplificado. *Rev Odonto*. 2008 jul/dez;16(32):31-8.
20. Lejarraga H, Guimarey L, Orazi V. Skeletal maturity of the hand and wrist of healthy Argentinian children aged 4-12 years, assessed by the TW II. *Ann Hum Biol*. 1997;24(3):257-61.
21. Martins EG, Simone JL, Reis RRB. Estudo comparativo de dois métodos de avaliação da maturação esquelética utilizando radiografias carpais e telerradiografias em norma lateral. *RGO*. 2006;54(4):322-27.
22. Moraes MEL, Medici Filho EM, Moraes LC. Surto de crescimento puberal. Relação entre mineralização dentária, idade cronológica, idade dentária e idade óssea – método radiográfico. *Rev Odontol UNESP*. 1998;27(1):111-29.
23. Moraes, MEL, Morosolli ARC, Moraes LC, Castilho JCM. Comparação dos métodos de Martins & Sakima e de Fishman para avaliação do surto de crescimento puberal. *J Bras Ortodon Ortop Facial*. 2005;10(57):255-62.
24. Prata THC, Moraes Filho E, Moraes LC, Moraes MEL. Estudo do crescimento maxilar e mandibular na fase de aceleração do surto de crescimento puberal. *Rev Dent Press Ortod Ortop Facial*. 2001;6(4):19-31.
25. Santos SCBN, Almeida RR. Estudo comparativo de dois métodos de avaliação da idade esquelética utilizando telerradiografias em norma lateral e radiografias carpais. *Ortodontia*. 1999;3(2):33-45.
26. Schusterchitz T, Haiter NF. Estudo comparativo entre a maturação óssea das vértebras cervicais e a região carpal. *Ortodontia*. 2002;35(3):33-41.
27. Silva Filho OG, Sampaio LL, Freitas JAS. Avaliação de um método simplificado para estimar a maturação esquelética. *Ortodontia*. 1992;25(1):21-36.
28. Vieira CL, Oliveira AEF, Ribeiro CCC, Lima AASJ. Relação entre os índices de maturação das vértebras cervicais e os estágios de calcificação dentária. *Rev Dent Press Ortod Ortop Facial*. 2009 mar/abr;14(2):45-53.

Contact address

Yasmine Bitencourt Emilio Mendes
 Rua Jaime Rosas, 180 – Jardim Carvalho
 CEP: 84.015-600 – Ponta Grossa / PR
 E-mail: yasminemendes@hotmail.com