



Associated dental anomalies: The orthodontist decoding the genetics which regulates the dental development disturbances

Daniela Gamba Garib*, Bárbara Maria Alencar**, Flávio Vellini Ferreira***, Terumi Okada Ozawa****

Abstract

This article aims to approach the diagnosis and orthodontic intervention of the dental anomalies, emphasizing the etiological aspects which define these developmental irregularities. A genetic inter-relationship seems to exist determining some dental anomalies, considering the high frequency of associations. The same genetic defect may give rise to different phenotypes, including tooth agenesis, microdontia, ectopias and delayed dental development. The clinical implications of the associated dental anomalies are relevant, since early detection of a single dental anomaly may call the attention of professionals to the possible development of other associated anomalies in the same patient or in the family, allowing timely orthodontic intervention.

Keywords: Genetics. Dental anomalies. Tooth agenesis. Etiology. Orthodontics.

* DDS, MSc, PhD. Assistant Professor of Orthodontics. Rehabilitation Hospital of Craniofacial Anomalies, Bauru Dental School, University of São Paulo - Bauru/SP, Brazil.

** Master of Orthodontics, São Paulo City University (Unicid), São Paulo/SP, Brazil.

*** Head of the Masters Course in Orthodontics of the São Paulo City University, Unicid, São Paulo/SP, Brazil.

**** Professor of the Postgraduate Program in Rehabilitation Science, Rehabilitation Hospital of Craniofacial Anomalies - Bauru Dental School, University of São Paulo, Bauru/SP, Brazil.

INTRODUCTION

The transition from the deciduous to the permanent dentition is a complex biological process rich in details and represents one of the nature's expressions of perfection. However, as all natural processes, the dental development can show imperfections and during the mixed dentition, the professional can face some irregularities: The dental anomalies. Dental anomalies may be expressed with different degrees of severity. From the mildest to the most severe manifestation, represented respectively by the developmental delay and by the tooth agenesis, there is a myriad of expressions, including microdontia, changes in dental morphology and ectopias. This article is related to the nature's errors applied to dental development and discusses the etiology of the dental anomalies, the details for an accurate diagnosis, as well as some therapeutic approaches to intercept them appropriately.

The influence of genetic and environmental factors in the etiology of malocclusions represents a subject of great importance in Orthodontics. The higher the genetic contribution in the etiology of a dentofacial irregularity, the lesser the possibility of prevention and, generally, worse is the prognosis for orthodontic/orthopedic treatment.²² And the new directions of dental research are toward the knowledge of the human genotype.³⁰ Several studies have suggested a genetic and hereditary background in the etiology of dental anomalies of number, size, position, as well as timing of development.^{2,4,13,14,15,17,18,20,23,24,25,30} Such evidences come from studies in families,^{17,18,30} monozygotic twins²⁰ and from the frequent observation of associations of certain dental anomalies.^{2,4,13,14,15,23,24,25}

When a particular irregularity shows an increased prevalence in families of affected patients compared to the frequencies expected for the general population, genetics has an important influence in the etiology of the problem. The mandibular prognathism in the imperial

Austro-Hungarian family of the Hapsburgs represents the most classic example of a genetic characteristic of orthodontic interest, transmitted by successive generations.²² Many of the dental anomalies that will be discussed in this article showed an increased prevalence in the family of affected patients (Figs 1 to 7).^{17,18,30} Currently, molecular biology studies can isolate mutant genes in families, since several members express the same irregularity.³⁰

Monozygotic twins share almost identical genetic codes. Therefore, genetically defined features are similarly expressed in both twins. A high correlation for a particular irregularity in pairs of monozygotic twins is an evidence that genetics is an important etiology of such abnormality. Unlikely, dizygotic twins which have different genotypes would show a lower correlation for the same irregularity. Previous studies in twins constitutes important evidences of the genetic etiology of some dental anomalies.^{20,22}

Certain dental anomalies appear often associated in the same patient, more than expected by chance. This occurs because a same genetic defect can determine different manifestations or phenotypes, including agenesis, microdontia, ectopias and delayed tooth development.^{2,4,13,14,15,23,24,25} A simplistic explanation is that a "defective" or mutant gene can express differently in distinct permanent teeth. The association between the unilateral agenesis of the maxillary lateral incisor and the microdontia of its antimere, often observed in clinical routine, well illustrates this condition. In this case, the same genetic defect which determined the agenesis has an incomplete expression in the opposite side of the dental arch, causing microdontia. However, the associations between the dental anomalies are not restricted to this classic example. There are many more interactions between different dental anomalies, which are exposed along this article. The clinical implications are important because the early diagnosis

of a given dental anomaly can alert the professional to the possible development of other associated dental anomalies in the same patient or family, permitting early diagnosis and timely orthodontic intervention.

The aim of this article is to help the clinicians

in recognizing the main genetic dental anomalies, discussing important features of diagnosis and early orthodontic treatment of these abnormalities. Additionally, it aims to promote a comprehension of the pattern of associated dental anomalies.

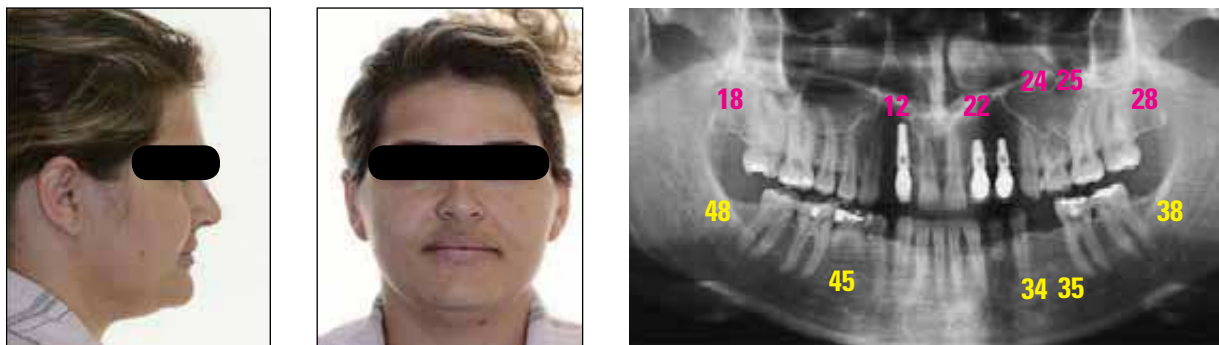


FIGURE 1 - Thirty-year-old female patient showing agenesis of eleven permanent teeth, representing a typical case of oligodontia.

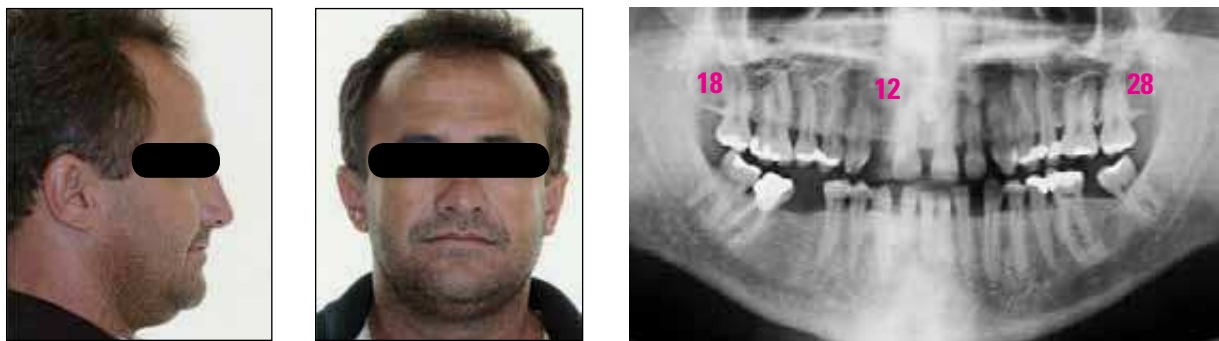

FIGURE 2 - First cousin of the patient illustrated in figure 1. Observe the agenesis of three permanent teeth in the maxillary arch. The mandibular first molars were lost due to extractions.

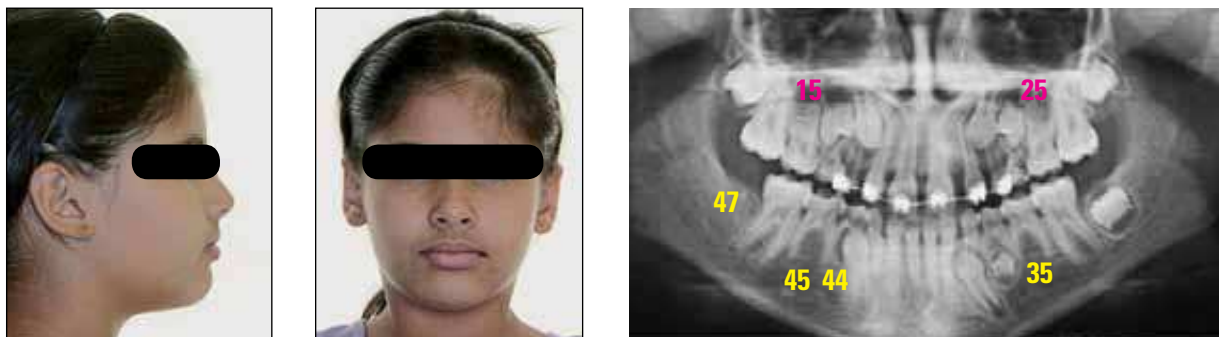

FIGURE 3 - Daughter of the couple illustrated in figures 1 and 2. This 9-year-old child has agenesis of all second premolars, of the right mandibular first premolar and right mandibular second molar. The absence of the third molars cannot be confirmed due to patient early age.

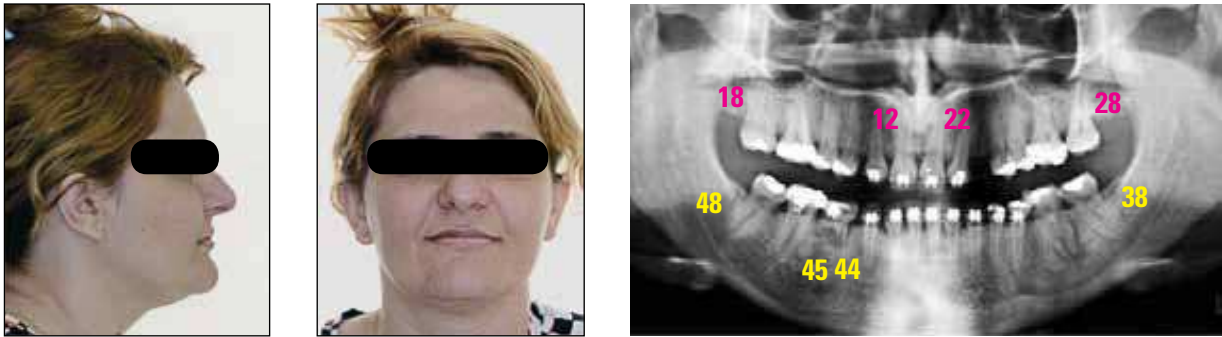


FIGURE 4 - Aunt of the patient illustrated in figure 1. Observe the agenesia of eight permanent teeth including premolars, maxillary lateral incisors and third molars.

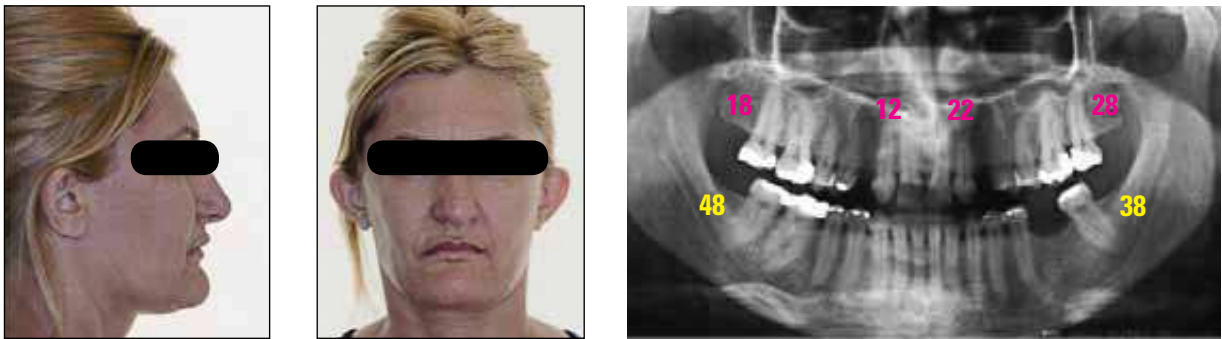

FIGURE 5 - Older sister of the patient illustrated in figure 4 showing a similar agenesia pattern.

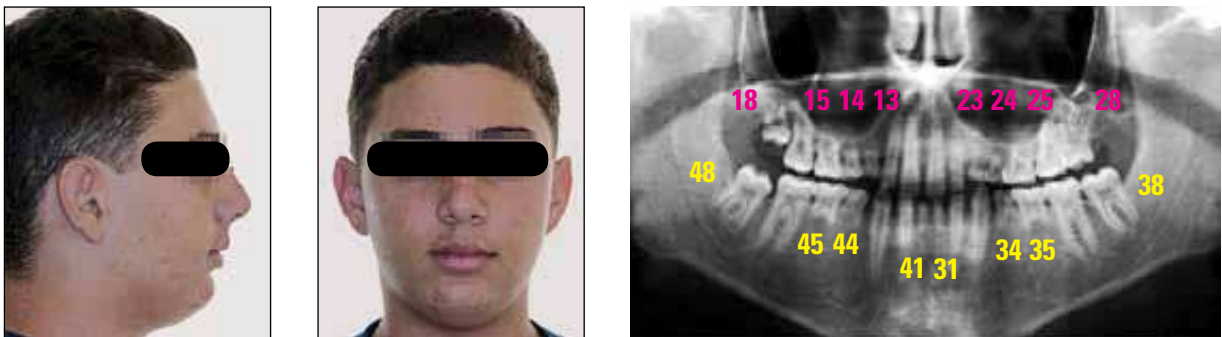


FIGURE 6 - This 15-year-old male patient is nephew of the patient illustrated in figure 1. He presents agenesia of sixteen permanent teeth including mandibular central incisors, maxillary canines, all the premolars and third molars.

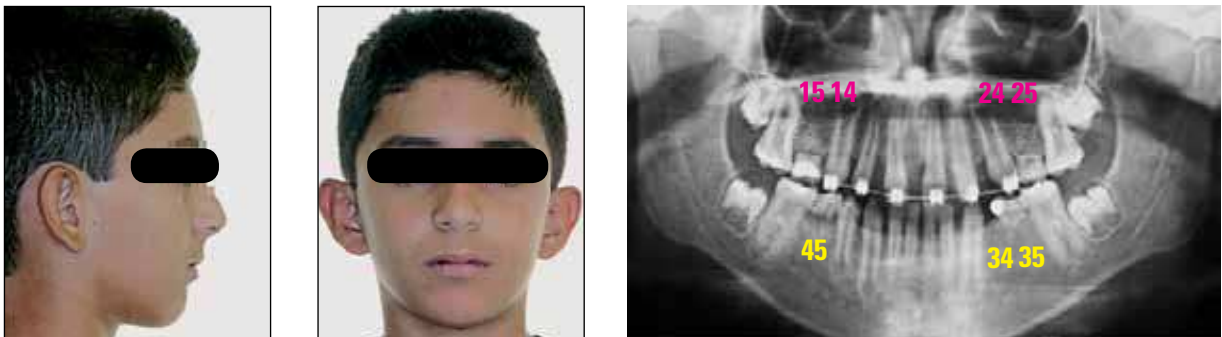

FIGURE 7 - Younger brother of the patient showed in figure 6. With 10 years of age, he presents agenesia of seven permanent teeth, excluding the third molars.

TOOTH AGENESIS

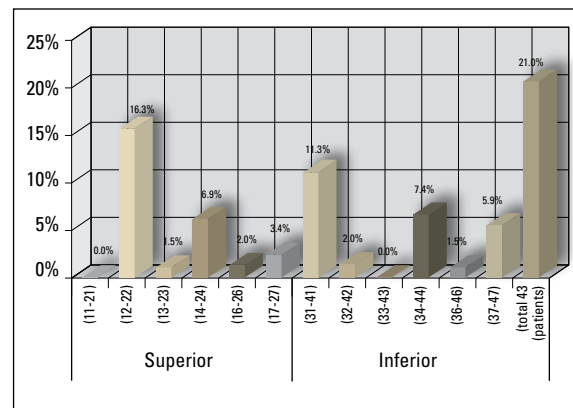
Tooth agenesis constitutes the most common developmental anomaly of the human dentition, occurring in approximately 25% of the population.¹³ Third molars represent the most affected tooth, showing a prevalence of agenesis of 20.7%.¹³ Excluding third molars, the prevalence of tooth agenesis is approximately 4.3 to 7.8% and the mandibular second premolars are the most commonly missing teeth, followed by the maxillary lateral incisors and maxillary second premolars.²⁶ In White patients, the frequency of tooth agenesis can be classified as *usual*, when it affects mandibular second premolars, maxillary lateral incisors and maxillary second premolars; *less usual* which includes in a descending order of occurrence the mandibular central incisors, the mandibular lateral incisors and maxillary first premolars, maxillary canines and mandibular second molars; and *rare* comprising, in a descending order of frequency, the agenesis of maxillary first and second molars, mandibular canines, mandibular first molars and maxillary central incisors.²⁶ It is important to highlight the ethnical differences in the prevalence of tooth agenesis. Epidemiological studies showed a lower prevalence of agenesis in Blacks compared to Whites, while the Asians tended to show an increased prevalence of agenesis.²⁶ Even comparing White subjects from distinct continents, the frequencies of agenesis are slightly different.²⁶ For example, European and Australian Caucasians present a higher prevalence of tooth agenesis than North-American Caucasians.²⁶ There are also sexual differences in the prevalence of tooth agenesis. In general, women are more affected than men.²⁶ The great majority of patients with agenesis (76 to 83%) has the absence of only one or two permanent teeth.²⁶ The unilateral occurrence is predominant, except for the maxillary lateral incisor agenesis, which bilateral occurrence is more common than the unilateral one.²⁶

Genetics probably represents the primary

etioloical factor of tooth agenesis. The prevalence of agenesis is higher in families of affected patients.²² Figures 1 to 7 show members of a large Brazilian family with consanguineous marriage showing agenesis of multiple permanent teeth. Recently, a mutation in gene *MSX1* of the chromosome 4 was identified in a large family whose all members showed agenesis of second premolars and third molars.³⁰

An interesting study in twins showed a high frequency of agreement for tooth agenesis in monozygotic twins, while pairs of dizygotic twins showed disagreement for this dental anomaly.²⁰

In the 60's, Garn and Lewis¹⁴ observed that patients with third molar agenesis presented higher prevalence of agenesis of other permanent teeth. The prevalence of agenesis of other permanent teeth in patients with third molar agenesis was 13-fold higher than the same prevalence in patients with all third molars. Even very stable teeth, such as central incisors, canines and first premolars were absent in the sample with third molar agenesis. The explanation is that one genetic defect can give rise to many dental anomalies. In other words, two or more tooth agenesis in a same patient can have a



GRAPH 1 - Prevalence of agenesis of permanent teeth, excluding third molars, in patients with second premolar agenesis (Source: Garib, Peck, Gomes,¹³ 2009).

common genetic origin.

Similar results were observed in orthodontic patients with second premolar agenesis¹³ (Graph 1). In this sample, the frequency of occurrence of other permanent tooth agenesis, excluding third molars, was 5-fold increased (21%) compared to the general population. The prevalence of third molar agenesis was more than 2-fold increased (48%) in comparison to the general population. Interestingly, the higher the number of missing second premolars, the higher was the prevalence rate of agenesis of other permanent teeth. Patients with one or two missing second premolars presented an approximate prevalence rate of 15% of agenesis of one or more other permanent teeth. Conversely, nearly 50% of patients in the sample with three or four missing second premolars presented agenesis of other permanent teeth.

Tooth agenesis is frequently associated with other dental anomalies, including microdontia,¹⁵ ectopias (ectopic eruption of maxillary canines towards the palate, tooth transpositions, distoangulation of mandibular second premolars and maxillary first molar ectopic eruption),^{2,4,13,14,15,23,24,25} infraocclusion of deciduous molars,^{2,13} delayed dental development¹ and generalized enamel hypoplasia.² These evidences highlight the importance of genes in the etiology of tooth agenesis, as well as help the clinician to better understand their patients. In summary, when a dental anomaly is identified, the professional should be attentive and look for the development of other dental anomalies.

Microdontia

Tooth agenesis is frequently associated with small teeth.^{2,13,15} A reduction in tooth size represents an incomplete expression of the same genetic defect which defines tooth agenesis. This explains the classical association between the unilateral agenesis of the maxillary lateral incisor and the microdontia of its antimere (Fig 8).

Approximately 20% of the patients with second premolar agenesis also present small upper lateral incisors^{2,13} (Fig 9).

Patients with tooth agenesis show a generalized and significant reduction of tooth size. This reduction is not homogeneous, once the anterior teeth (incisors and canines) are smaller than the posterior teeth (premolars and molars).¹⁵ In patients with multiple tooth agenesis (oligodontia), the reduction of tooth size is even more remarkable¹⁵ (Fig 10).

This information presents important clinical implications. Rarely an orthodontist observes crowding in patients with tooth agenesis, while spacing is a common finding. In this way, the comprehensive orthodontic treatment hardly evolves tooth extractions. The major challenge in these patients will be closing the generalized spaces, mainly when the facial profile dictates that posterior tooth mesial movement should be performed instead of anterior tooth retractions.

Ectopic eruption of maxillary first molars

During the initial stages of the mixed dentition, the permanent first molars erupt in the dental arch using the distal aspect of the deciduous second molars as an eruption guide. Maxillary first molars show an occlusal and mesial eruption path. In this way, the distoangulation of the tooth germ in the maxilla is corrected during eruption and the maxillary first molars erupt in a upright position related to the occlusal plane. However, in 4% of children the maxillary first molars overdeviate its eruption path toward mesial, stimulating a partial root resorption of the adjacent deciduous second molar⁵ (Fig 11). This eruption disturbance is known as ectopic eruption of permanent first molars.⁵ Approximately half of the cases are reversible and the first molars erupt spontaneously in the dental arch. In irreversible cases, the maxillary first molars are unable to resorb deciduous second molar enamel, remaining retained.⁵

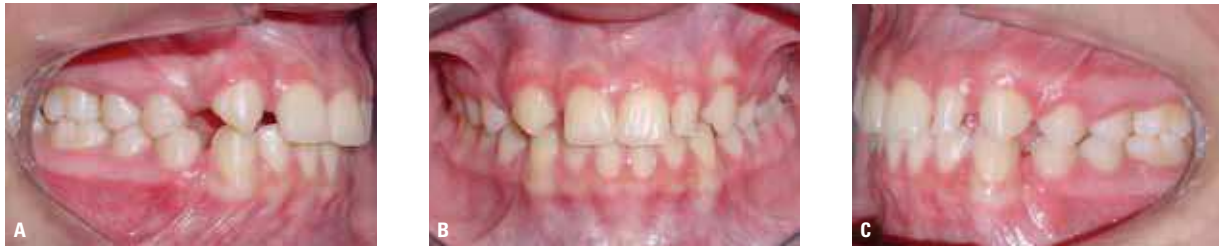

FIGURE 8 - Association between unilateral agenesis of maxillary lateral incisor and the microdontia of its antimere.

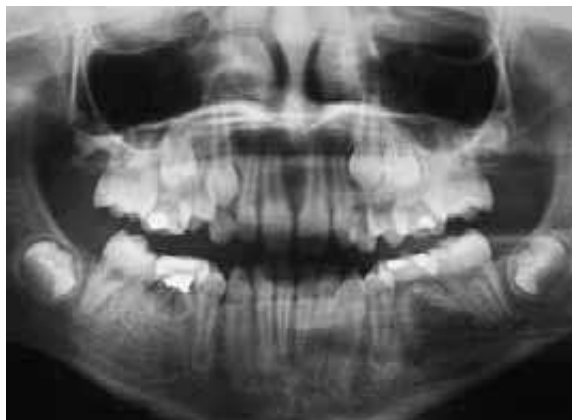

FIGURE 9 - Panoramic radiograph of a patient presenting association between multiple tooth agenesis and microdontia of the maxillary lateral incisors.

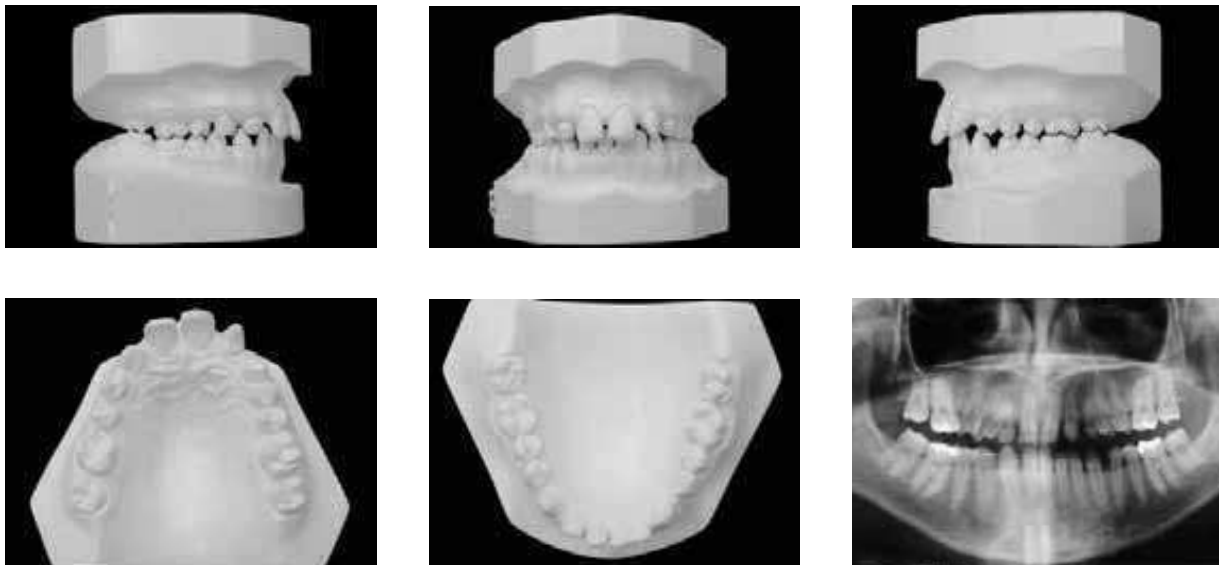


FIGURE 10 - Case presenting associated tooth agenesis, including the third molars, the maxillary lateral incisors and the right maxillary canine. Note the generalized reduction in the size of the permanent teeth.

What is the etiology of this eruption disturbance? During the 80's, the ectopic eruption of permanent first molars was related to space deficiency in the posterior region of the maxilla. However, Kurol and Bjerklin¹⁷ showed that the prevalence of this dental anomaly in the family of affected patients corresponded to approximately 20%, a higher prevalence compared to the general population (4%). These evidences denounced a genetic background in the etiology of first molar ectopic eruption. Almost 10 years later, Bjerklin, Kurol and Valentin⁴ have confirmed these evidences when they demonstrated the association between the ectopic eruption of permanent first molars and other dental anomalies of genetic etiology such as second premolar agenesis, palatally displaced canines (PDC) and infraocclusion of deciduous molars. The prevalence of these anomalies in patients with ectopic eruption of maxillary first molars was 6.5%, 5.4% and 20.7%, respectively, a higher frequency than the expected for the general population. Shifting the focus of observation, Baccetti² showed that patients with infraocclusion of deciduous molars, agenesis of second premolars or upper lateral incisor microdontia had two to three fold higher prevalence of ectopic eruption of maxillary first molars. With all these evidences, the ectopic eruption of first molars was added to the list of the genetically determined dental anomalies.

The frequency of occurrence of permanent first molar ectopic eruption justifies that the professional follow the eruption path of these teeth in patients during the first transitional period of the mixed dentition. During this stage, the clinical sign represented for the partial eruption of the maxillary first molar (Fig 11A) and the radiographic aspect of early root resorption of the deciduous second molar associated with a mesioangulation of the permanent first molar (Fig 11B) infer the ectopic eruption path of the first molar. This dental anomaly should be

treated early in order to avoid premature loss of second deciduous molars and arch perimeter reduction. The intervention is simple and brief requiring a distal light force on the first molar crown (Fig 11C). The goal is to obtain a slight tipping movement of the maxillary first molar. A diversity of appliances can be used with this purpose. After treatment, the prognosis of maintenance of the deciduous second molar in the dental arch is good, even in face of the atypical and early root resorption.

Mandibular lateral incisor-canine transposition

Tooth transposition is a tooth ectopia defined as an inversion in the natural position of adjacent teeth.⁶ Two types of tooth transpositions are reported in the literature as having a genetic background and therefore are commonly associated with other dental anomalies: Maxillary canine-first premolar transposition and mandibular lateral incisor-canine transposition.²⁵

An incomplete mandibular lateral incisor-canine transposition results from a distal ectopic eruption of the mandibular lateral incisor, during the first transitional period of the mixed dentition. In these circumstances, the ectopic tooth is the lateral incisor. The permanent mandibular canine shows a normal eruption path. When the mandibular lateral incisor "misses" its eruption path it deviates distally showing a remarkable distoangulation, with the crown presenting a mesiolingual rotation close to first deciduous molars while the apex is normally located close to its normal position (Fig 12). At the end of the second transitional period of the mixed dentition, the mandibular canine erupts in its normal position, defining a tooth transposition.

This dental anomaly is rare showing a prevalence of approximately 0.03% and affects mostly female patients (75% of the cases). The bilateral expression corresponds to 17%, and in the unilateral expression cases, the right side (68%) is

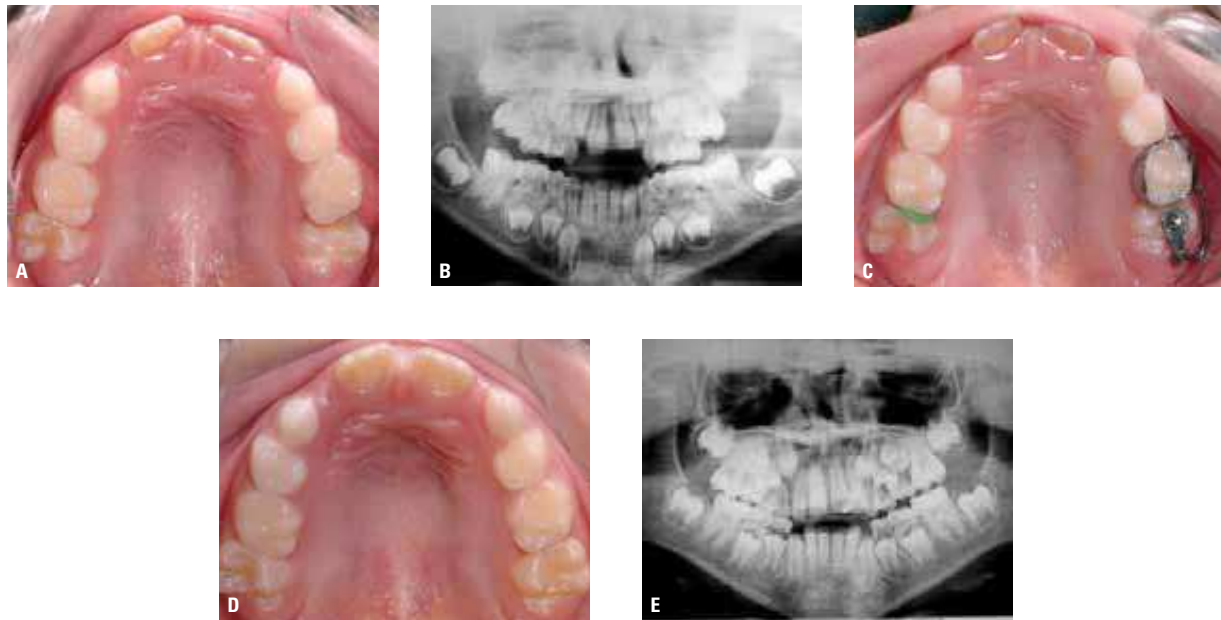


FIGURE 11 - Ectopic eruption of maxillary first molars. **A)** Clinical aspect showing partial eruption of the right first molar. **B)** Panoramic radiograph reveals the premature root resorption of the adjacent second deciduous molar besides the mesioangulation of the permanent first molar. **C)** Treatment with partial fixed space maintainer appliance. **D)** Posttreatment clinical aspect. **E)** Posttreatment panoramic radiograph. Observe the consequences of first molar ectopic eruption, represented by the partial and irreversible root resorption of the deciduous second molar.

more affected than the left side (32%).²³

There are some evidences that the etiology of mandibular lateral incisor-canine transposition present a genetic background.^{23,25} Peck, Peck and Kataja,²³ in a remarkable sample of 60 patients showing this type of transposition, found an increased prevalence of associated permanent tooth agenesis and conical upper lateral incisors (Table 1). More specifically, this modality of tooth transposition was associated with a high prevalence of second premolar and third molar agenesis, while the prevalence of maxillary lateral incisor agenesis was not different from the prevalence expected for the general population.²³

In the permanent dentition, the orthodontic treatment of mandibular lateral incisor-canine transposition is restrict to tooth alignment, maintaining the interchanged position of

evolved teeth.²³ Two reasons justifies this therapeutic approach. The first one is the presence of a more parallel position between the roots of mandibular canine and lateral incisor in transposition.²³ Other morphologic feature which prevents attempting to correct the tooth order is the thin faciolingual alveolar width in the mandible. Differently, when the ectopic eruption of mandibular lateral incisors is identified early, in the mixed dentition, an early orthodontic intervention may prevent the establishment of tooth transposition. Before the eruption of the mandibular canine, only the crown of lateral incisor is malpositioned, while the apex is in the normal position.^{23,29} In this stage, the orthodontic upright of mandibular lateral incisor with a 2 by 4 mechanics can prevent the lateral incisor-canine transposition²⁹ (Fig 13).

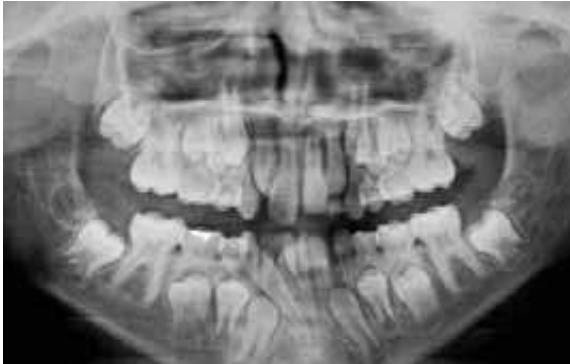

FIGURE 12 - Radiographic image illustrating the ectopic eruption of a mandibular lateral incisor in the right side. Note the remarkable distoangulation of the mandibular lateral incisor in the panoramic radiograph.

TABLE 1 - Prevalence of tooth agenesis and conical shape maxillary lateral incisor in patients with mandibular lateral incisor-canine transposition (n = 60) compared to population reference values (Source: Peck S, Peck L, Kataja,²³ 1998).

DENTAL ANOMALIES	PREVALENCE IN PATIENTS WITH MANDIBULAR LATERAL INCISOR-CANINE TRANSPOSITION	REFERENCE VALUES
Tooth agenesis (including third molars)	40%	25%
Third molar agenesis	37%	21%
Tooth agenesis (excluding third molars)	12%	5%
Agenesis of second premolars	8%	2%
Agenesis of maxillary lateral incisors	2%	2%
Conical shape lateral incisors	10%	2%

Ectopic eruption of permanent maxillary canines

Permanent maxillary canines represent the teeth which develop more distant from the dental arch, close to nasal cavity, and therefore they have the longest eruption path compared to other permanent teeth. For this reason, their root has the greatest length. During eruption, the bulging crown of maxillary canines can be felt on the facial aspect of alveolar ridge above the deciduous canines.¹⁰ When the palpation is positive, it means that maxillary canines have a good prognosis of spontaneous eruption.¹⁰ However, in approximately 1.5% of population, the canines show an ectopic eruption path towards the palate relatively to the lateral incisors, remaining retained.¹³

The palatally displaced canine (PDC) repre-

sents a dental anomaly which raises orthodontic concern due to two biologically relevant aspects. Besides preventing the canines to erupt spontaneously, in a significant number of cases, the maxillary canine ectopic eruption leads to root resorption of neighboring teeth.¹¹

The question is: What is the etiology of PDC? What conducts the canines to an unusual eruption path?

The buccal retention of maxillary canines relates to arch size deficiency and is one of the clinical manifestations of crowding.¹⁶ On the other hand, the majority of cases of PDC shows enough space in the dental arch for the permanent tooth alignment.¹⁶ In the 90's, Peck et al²⁴ compiled some evidences from the literature that PDC present an essentially genetic etiology. The authors have listed strong evidences

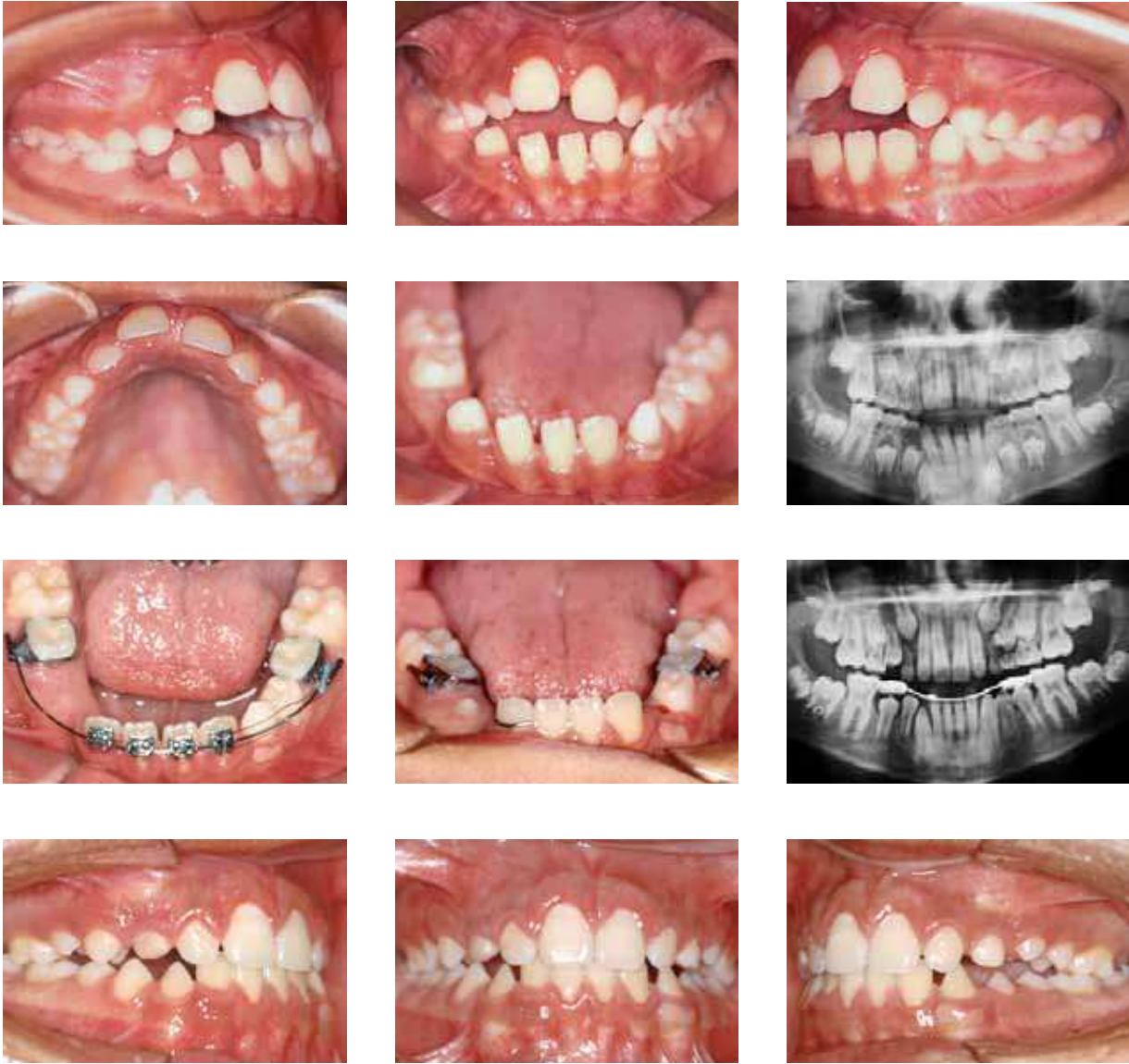

FIGURE 13 - Early treatment of an ectopic right mandibular lateral incisor (Source: Silva Filho, Zinsly, Okada and Ferrari Junior,²⁹ 1996).

to sustain such hypothesis, as the frequent observation of associated anomalies, family history, bilateral occurrence and the distinct prevalence of PDC between the genders and among different ethnical populations. Such assertive produced indignation from the orthodontists which believed in the hypothesis that maxillary canines show an ectopic eruption path because of local factors, as the morphology of lateral incisor root, the absence of maxillary lateral incisors or due to a “resistance” of the deciduous canines to be resorbed.³

A few years later, the same authors found that patients with PDC present a higher frequency of permanent tooth agenesis (17% excluding third molars), and the second premolars are the teeth most affected (14% of the cases).²⁵ Additionally, the authors observed that PDC is associated with maxillary lateral incisor microdontia in 17% of the cases, not necessarily at the same side of PDC. These researchers concluded that PDC, tooth agenesis and microdontia are biological co-variables which share a common genetic origin.

Additional evidence of the genetic background of PDC was the observation that patients with this anomaly can present delayed tooth development and generalized reduction in tooth size. The later can inform why the majority of patients with PDC does not show crowding and receive a nonextraction orthodontic treatment.

In an inverse association, there is evidence that patients with tooth agenesis, maxillary lateral incisor microdontia, deciduous molar infraocclusion and generalized enamel hypoplasia present a higher prevalence of PDC.^{2,13} These data present extreme clinical relevance when the early diagnosis of PDC is considered. The clinician should be aware that generally, a child has a risk of 1.5% of developing maxillary canine ectopic eruption towards the palate, while a child with second premolar agenesis has a 5-fold increased probability to develop the same dental

anomaly¹³ (Fig 14). The association of PDC with microdontia is even greater. A study in the Italian population showed that 34% of the patients with conical shaped upper lateral incisors has PDC.² The infraocclusion of deciduous molars (Fig 15), as well as the generalized enamel hypoplasia (Fig 16) also are risk indicators for PDC.² This information undoubtedly refines the ability for PDC early diagnosis. Taking into account that the ectopic eruption of maxillary canines can be treated early,⁹ preventing root resorption of adjacent incisors and canine impaction, it is imperative that the clinician be attentive to the maxillary canine development during the mixed dentition, especially in children who present any dental anomaly associated with PDC. These dental anomalies work as early risk indicators for PDC development.

Maxillary canine-first premolar transposition

Excluding third molars, the maxillary canines constitute the permanent teeth which more frequently show eruption disturbances. Besides PDC, another important but less frequent ectopia of maxillary canines is the canine-first premolar transposition. The typical picture shows the permanent maxillary canine buccally erupting between two premolars. Frequently, the canine is distally rotated and the first premolar is mesially rotated showing a distoangulation of its crown. This is the most common type of tooth transposition in humans with a frequency of 0.03 to 0.25%. Approximately ¼ of the cases show bilateral expression and the occurrence in females is higher (female-male proportion is 1.5:1).²⁵

The etiology of maxillary canine-first premolar transposition correlates to genetic factors.²⁵ Many case reports in the literature showed one or more family members presenting the same feature, without history of trauma in the dentofacial region. Patients with maxillary canine-first premolar transposition present

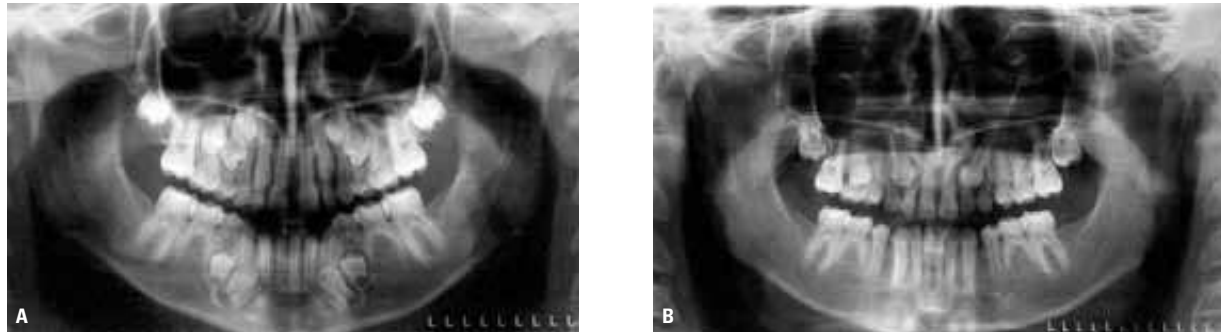


FIGURE 14 - Patient showing agenesis of mandibular second premolars and second molars at 10 year of age (A) and at 14 years of age (B). Observe the development of an ectopic pathway of eruption of maxillary canines (towards the palate). It is important to highlight the dentition developmental delay at 10 years of age.

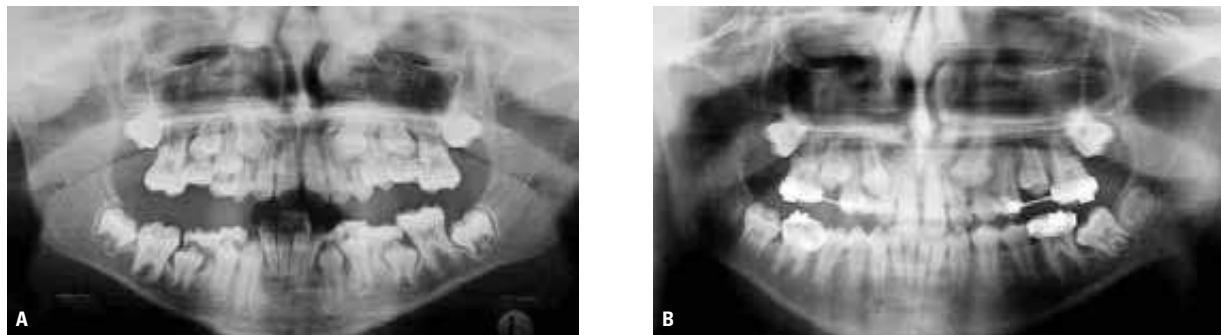


FIGURE 15 - Patient showing infraocclusion of deciduous molars during the intertransitional period of the mixed dentition (A). The longitudinal follow up of the dental development permitted the early diagnosis of the ectopic eruption of the left maxillary canine, during the late mixed dentition (B). In the second radiograph, the permanent mandibular left second molar showed mesioangulation.

an increased prevalence of permanent tooth agenesis excluding third molars corresponding to 37-40%²⁵ (Fig 17). This type of transposition is associated with a high prevalence of agenesis of second premolars (12%) and maxillary lateral incisors (26%), while the prevalence of third molar agenesis is not different from the reference values for the general population.²⁵ The maxillary lateral incisor microdontia represents another dental anomaly frequently associated to maxillary canine-first premolar transposition, observed in 16% of the cases.²⁵

In the permanent dentition, when the aim is to correct the inverted position of the related teeth, the orthodontic approach for this type of transposition is challenging.⁶ It demands a

more complex orthodontic mechanics and a longer period of treatment. For this reason, maxillary canine-first premolar transpositions are generally treated with tooth position maintenance, moving first premolars toward mesial and leveling the canine between premolars.⁶ The frequent association with tooth agenesis and microdontia makes the treatment planning even more difficult.

Maxillary canine-first premolar transposition may be treated early in the mixed dentition. The most ideal period for intervention is very specific: right after maxillary first premolar eruption and before canine eruption. In these cases, the first step consists in the correction of the tipping of the first premolar with fixed appliance.

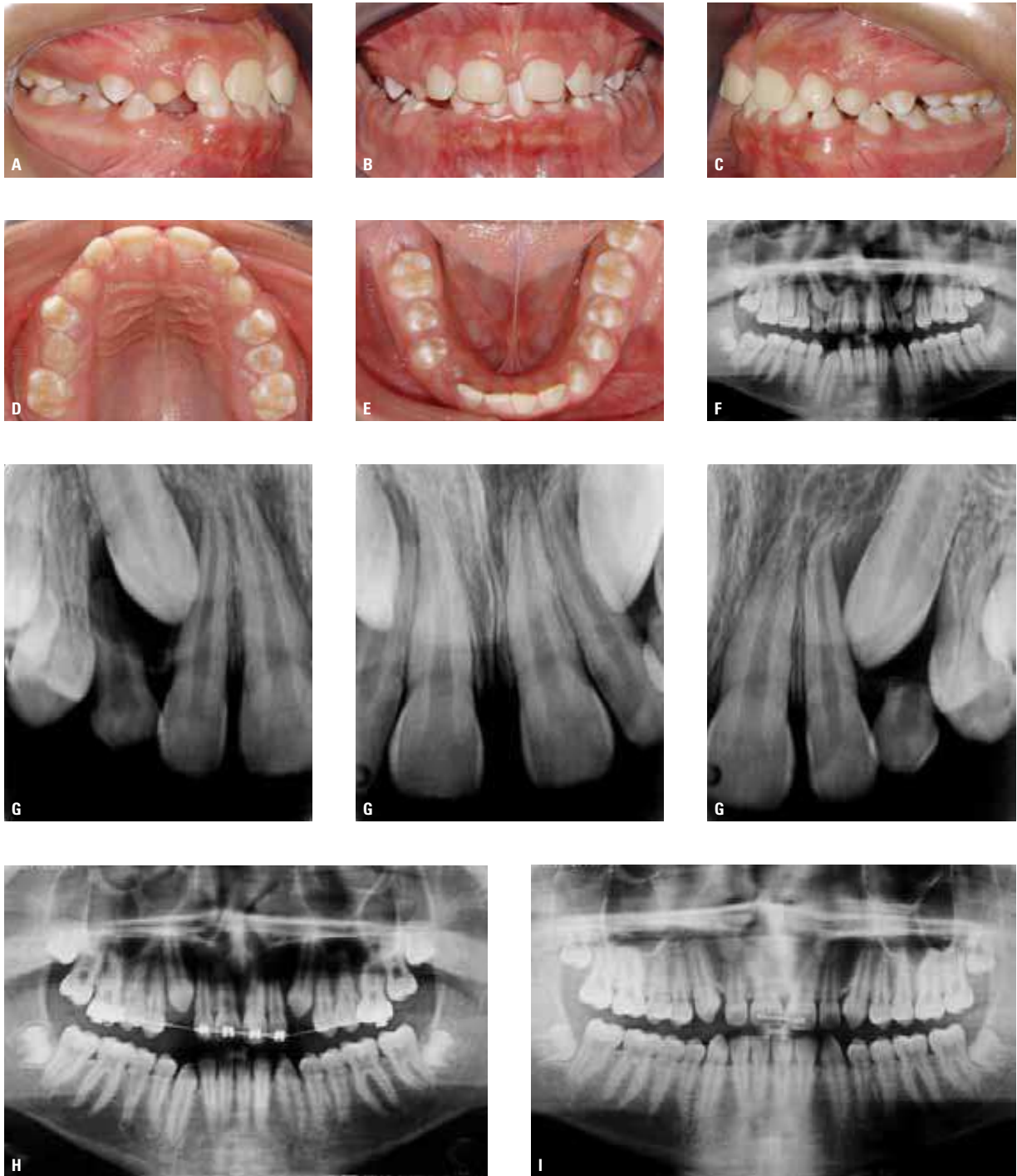


FIGURE 16 - Association between generalized enamel hypoplasia (A to E) and palatally displaced canine (F, G). The enamel hypoplasia represents a clinical red flag for an increased risk of developing PDC. After early diagnosis and early intervention with deciduous canine extraction, the eruption path of the tooth #13 was normalized (H) and the tooth has erupted spontaneously in the dental arch (I).

The procedure is possible due to the buccal position of the germ of the maxillary canines. After the correction of first premolar position, the deciduous canines are extracted at the same side and closed mesial traction is placed on the permanent canine.

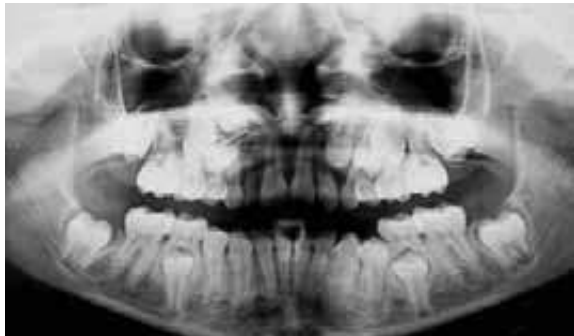

FIGURE 17 - Panoramic radiograph of a patient presenting maxillary first premolar-canine transposition in the right side associated with agenesis of the maxillary right lateral incisor.

Distoangulation of mandibular second premolars

The most common ectopia related to mandibular second premolars is the distoangulation of the germ.¹⁹ Such ectopia is associated with the agenesis of the contralateral second premolar²⁸ (Fig 18). Shalish et al,²⁸ using a sample of patients with unilateral agenesis of mandibular second premolar, showed that the contralateral germ presented a mean of more than 10° distal angulation, compared to a control group without agenesis. The authors concluded that distoangulation of mandibular second premolars represents a different phenotype or an incomplete expression of the same genetic defect which causes second premolar agenesis. This association is similar with the classical clinical picture including unilateral agenesis of a maxillary lateral incisor and the microdontia of its antimere.

The frequency of distoangulation of mandibular second premolar in the general population is rare, considering the prevalence of 0.19%.¹⁹ Differently, patients with agenesis of

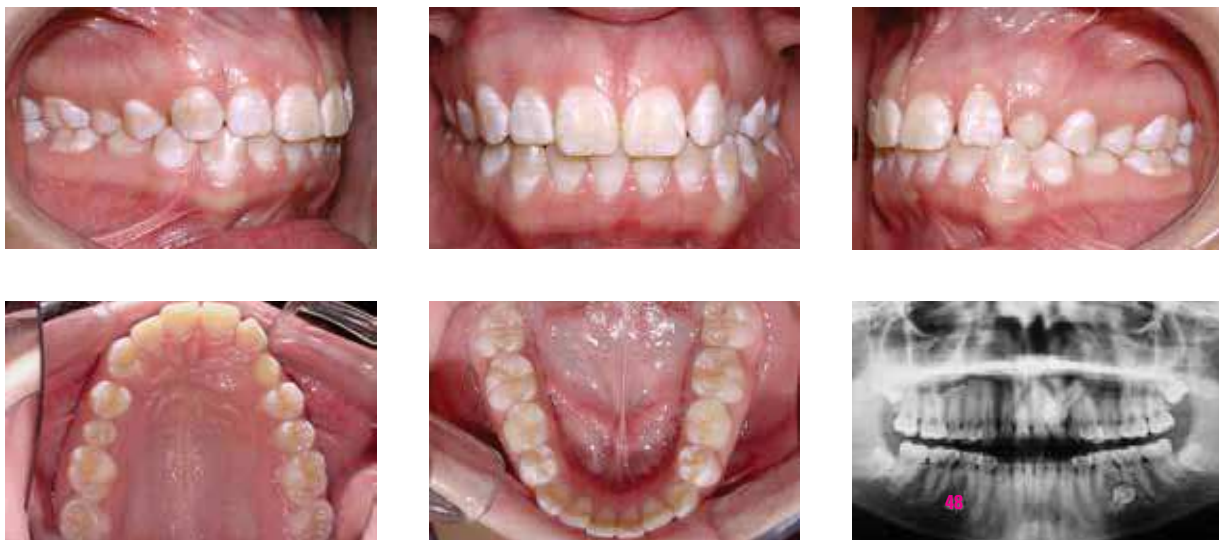

FIGURE 18 - Association between mandibular second premolar agenesis and palatally displaced canines. The patient also presented distoangulation of the mandibular left second premolar and a generalized enamel hypoplasia.

at least one second premolar show a prevalence of 7.8% of distoangulation of mandibular second premolars.¹³ Therefore, the relative risk of patients with second premolar agenesis to demonstrate this dental anomaly would be 45-fold increased. An interesting information is that distoangulation of mandibular second premolars is not only observed in patients with unilateral agenesis of mandibular second premolars but also in patients with agenesis of maxillary second premolars.¹³ Approximately 25% of the patients with distoangulation of mandibular second premolars had only maxillary second premolar agenesis while 75% of these patients presented absence of one mandibular second premolar.¹³ In summary, the clinician should not be surprised to find this dental anomaly in patients with tooth agenesis.

The mandibular second premolar distoangulation frequently self-corrects and do not demand intervention.¹² This ectopia is defined at early stages of the dental development. During root formation, tooth germ spontaneously uprights and erupts in the dental arch (Fig 19).

The longitudinal follow up of dental development is the only need in these cases. However, when the distoangulation is severe, showing a more horizontal position of tooth germ, the spontaneous eruption becomes unpredictable (Fig 20). In these cases, distoangulation is frequently associated with delayed tooth development and may need orthodontic traction.¹²

Infraocclusion of deciduous molars

Infraocclusion of deciduous molars occurs in approximately 8.9% of children and is characterized by the location of deciduous molar occlusal surface below the occlusal plane.¹⁸ It is suggested that infraocclusion of deciduous molars is a consequence of tooth ankylosis. In any point of the periodontal ligament, a bridge of mineralized tissue can establish a linkage between the alveolar bone and the cement. From this moment, the tooth is unable to erupt showing a progressive infraocclusion while the face grows.

A sequence of evidence has pointed that genetics has an important role in the etiology of infraocclusion. Kurol¹⁸ verified that the prevalence

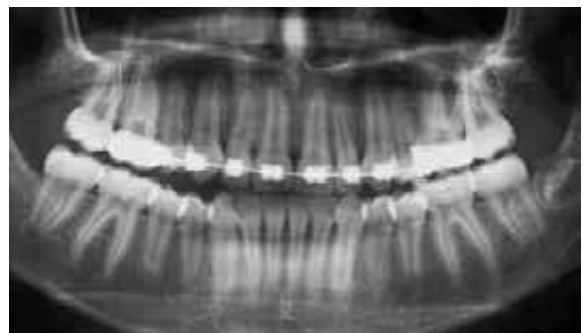
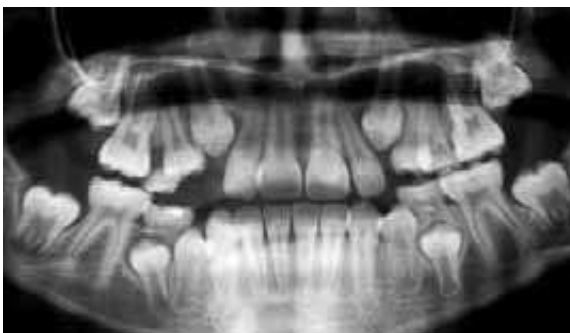
FIGURE 19 - Longitudinal follow up of a mandibular second premolar with distoangulation. Observe the association of this ectopia with the agenesis of the contralateral tooth. The ectopic tooth germ of 35 has uprighted gradually during dental development and erupted spontaneously in the dental arch.

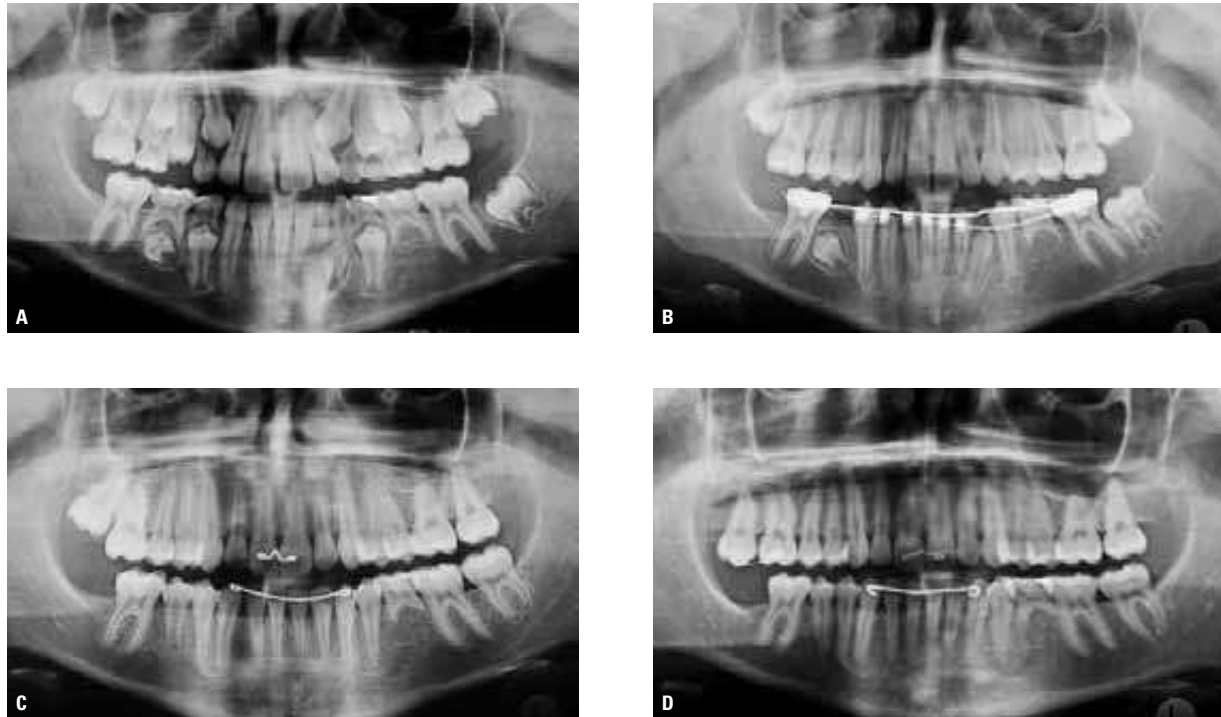


FIGURE 20 - Patient presenting association between agenesia of the mandibular left second premolar and a severe distoangulation of its antimere (A). After 1.5-year follow up of tooth #45 (B), orthodontic traction was performed. At the end of orthodontic treatment (C), tooth #45 is upright and 5 years after the end of treatment (D), its root formation is complete.

of infraocclusion is increased among siblings of affected patients being 2-fold higher compared to the general population (20%). Bjerklin, Kurol and Valentin⁴ found an association of deciduous molar infraocclusion with the ectopic eruption of maxillary first molars, PDC and second premolar agenesia. Baccetti² observed that patients with deciduous molar infraocclusion present a significantly increased prevalence of second premolar agenesia (14%), small maxillary lateral incisor (13%), first molar ectopic eruption (18%) and PDC (14%). Besides, this researcher verified a reciprocal association once subjects selected for one of these dental anomalies presented higher prevalences of deciduous molar infraocclusion. Garib, Peck and Gomes¹³ showed that 25% of the patients with second premolar agenesia presented infraocclusion of deciduous molars.

This prevalence was significantly increased compared to the prevalence of the general population (8.9%). This means that subjects with second premolar agenesia present a 3-fold increased probability to show infraocclusion than the general population.

Infraocclusion of deciduous molars do not interfere with the tooth development of the permanent successor tooth which generally erupts in the expected time, with a maximum of 6 months delay. Therefore, slight or moderate infraocclusion requires only longitudinal follow up. Conversely, severe infraocclusion needs intervention because the occlusal aspect of the deciduous molar is below the interproximal contact with the adjacent teeth (Fig 15A). In these conditions, the deciduous molar cannot work as a space maintainer and there is a risk of arch perimeter loss. Besides, the

deciduous molar can become covered below the gingival tissue with the infraocclusion progression. Under this light, the most reasonable therapeutic approach is the extraction of the affected deciduous molar followed by the placement of a space maintainer appliance (Fig 15B).

Delayed dental development

Patients with tooth agenesis can show a slower dental development and the dental age delayed compared to the chronological age.¹ This information may be explained by an inter-relationship in the causality of these dental anomalies and deserves the professional attention. In general, subjects with tooth agenesis reach occlusal maturity later. The permanent dentition can be completed years later than the usual age (Fig 14). Based on this knowledge, phase two of the orthodontic treatment should be postponed. Early diagnosis and late comprehensive orthodontic treatment is the perfect combination for patients with a pattern of associated dental anomalies.

Besides the generalized delayed dental development commonly observed in patients with tooth agenesis, a specified tooth can show a remarkable delay in tooth development: The second premolars. The second premolars present a great developmental instability. Besides the high

prevalence of agenesis, these teeth commonly show delayed development, especially when there is agenesis of other permanent teeth (Figs 21 and 22). It seems that the developmental delay of second premolars represent an incomplete expression of the same genotype of tooth agenesis. The initial mineralization of mandibular second premolars occurs in a mean age of 3 years (ranging from 2 years and 3 months to 3 years and 7 months),²¹ however these teeth can appear later.²⁷ The delayed appearance of second premolars occurs until age 6,²⁷ and some case reports showed the radiographic appearance of second premolars in a more advanced age, after 9 or even at 13 years of age.⁸ When the second premolars appears later, they also erupt later, frequently after the eruption of the second molars which are the last teeth to reach the occlusal plane excluding the third molars.

Under the light of this knowledge, the observation of non-erupted second premolars after the adolescence should not be a reason for orthodontic concern (Figs 21 and 22). If the tooth germs are well positioned and there is no local pathology, it means that second premolars are only delayed. The longitudinal follow up will permit the clinician to observe its spontaneous eruption in the dental arch, even though the remarkable delay.

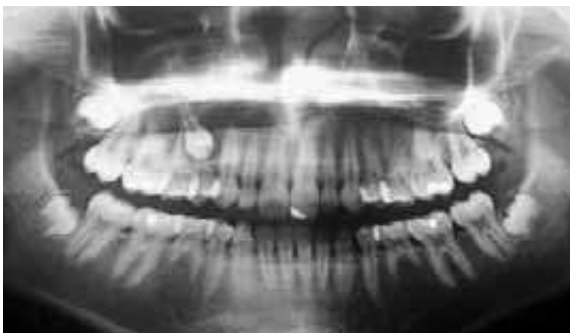

FIGURE 21 - Delayed development of a maxillary right second premolar. Note an association of this anomaly with the agenesis of other second premolars.

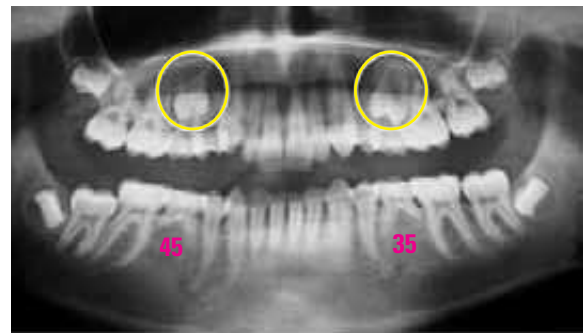


FIGURE 22 - Delayed development of maxillary second premolars in a patient with mandibular second premolar agenesis.

Enamel hypoplasia

Although it is not very explored in the literature, there is some evidences that generalized enamel hypoplasia is in the list of genetically regulated dental anomalies (Figs 16 and 18). The enamel hypoplasia is frequently diagnosed associated to other dental anomalies, most commonly than randomly expected.² Besides, in a sample of subjects selected for the presence of enamel hypoplasia, a higher prevalence of tooth agenesis, microdontia and ectopias including PDC was observed.²

Therefore, the observation of generalized white spots in the enamel of permanent teeth,

decoupled with environment causes as fluorosis and history of antibiotic intake, can work as a clinical alert for the development of other dental anomalies during childhood.

CONCLUSION

The clinical implications of associated dental anomalies patterns are very important, since the early diagnosis of a particular dental anomaly as the agenesis of a second premolar or a small maxillary lateral incisor may alert the professional to the possible development of other associated anomalies in the same patient or in the family, allowing early diagnosis and timely orthodontic intervention.

REFERENCES

1. Baba-Kawano S, Toyoshima Y, Regalado L, Sa'do B, Nakasima A. Relationship between congenitally missing lower third molars and late formation of tooth germs. *Angle Orthod.* 2002 Apr;72(2):112-7.
2. Baccetti T. A controlled study of associated dental anomalies. *Angle Orthod.* 1998 Jun;68(3):267-74.
3. Becker A. In defense of the guidance theory of palatal canine displacement. *Angle Orthod.* 1995;65(2):95-8.
4. Bjerklin K, Kurol J, Valentin J. Ectopic eruption of maxillary first permanent molars and association with other tooth and developmental disturbances. *Eur J Orthod.* 1992 Oct;14(5):369-75.
5. Bjerklin K, Kurol J. Prevalence of ectopic eruption of the maxillary first permanent molar. *Swed Dent J.* 1981;5(1):29-34.
6. Ciarlantini R, Melsen B. Maxillary tooth transposition: correct or accept? *Am J Orthod Dentofac Orthop.* 2007 Sep;132(3):385-94.
7. Collett AR. Conservative management of lower second premolar impaction. *Aust Dent J.* 2000 Dec;45(4):279-81.
8. Coupland MA. Apparent hypodontia. *Br Dent J.* 1982 Jun 1;152(11):388.
9. Ericson S, Kurol J. Early treatment of palatally erupting maxillary canines by extraction of the primary canines. *Eur J Orthod.* 1988 Nov;10(4):283-95.
10. Ericson S, Kurol J. Longitudinal study and analysis of clinical supervision of maxillary canine eruption. *Community Dent Oral Epidemiol.* 1986 Jun;14(3):172-6.
11. Ericson S, Kurol PJ. Resorption of incisors after ectopic eruption of maxillary canines: a CT study. *Angle Orthod.* 2000 Dec;70(6):415-23.
12. Garib DG, Zanella NLM, Peck S. Associated dental anomalies: case report. *J Appl Oral Sci.* 2005.13(4):431-6.
13. Garib DG, Peck S, Gomes SC. Increased occurrence of dental anomalies in patients with second premolar agenesis. *Angle Orthod.* 2009 May;79(3):436-41.
14. Garn SM, Lewis AB. The relationship between third molar agenesis and reduction in tooth number. *Angle Orthod.* 1962;32(1):14-8.
15. Garn SM, Lewis AB. The gradient and the pattern of crown-size reduction in simple hypodontia. *Angle Orthod.* 1970 Jan;40(1):51-8.

16. Jacoby H. The etiology of maxillary canine impactions. *Am J Orthod.* 1983 Aug;84(2):125-32.
17. Kurol J, Bjerklin K. Ectopic eruption of maxillary first permanent molars: familial tendencies. *ASDC J Dent Child.* 1982 Jan-Feb;49(1):35-8.
18. Kurol J. Infraocclusion of primary molars: an epidemiologic and familial study. *Community Dent Oral Epidemiol.* 1981 Apr;9(2):94-102.
19. Matteson SR, Kantor ML, Proffit WR. Extreme distal migration of the mandibular second bicuspid. A variant of eruption. *Angle Orthod.* 1982 Jan;52(1):11-8.
20. Markovic M. Hypodontia in twins. *Swed Dent J Suppl.* 1982;15:153-62.
21. Moorrees CF, Fanning EA, Hunt EE Jr. Age variation of formation stages for ten permanent teeth. *J Dent Res.* 1963 Nov-Dec;42:1490-502.
22. Mossey PA. The heritability of malocclusion: part 2. The influence of genetics in malocclusion. *Br J Orthod.* 1999 Sep;26(3):195-203.
23. Peck S, Peck L, Kataja M. Mandibular lateral incisor-canine transposition, concomitant dental anomalies, and genetic control. *Angle Orthod.* 1998 Oct;68(5):455-66.
24. Peck S, Peck L, Kataja M. The palatally displaced canine as a dental anomaly of genetic origin. *Angle Orthod.* 1994;64(4):249-56.
25. Peck S, Peck L, Kataja M. Concomitant occurrence of canine malposition and tooth agenesis: evidence of orofacial genetic fields. *Am J Orthod Dentofacial Orthop.* 2002 Dec;122(6):657-60.
26. Polder BJ, Van't Hof MA, Van der Linden FP, Kuijpers-Jagtman AM. A meta-analysis of the prevalence of dental agenesis of permanent teeth. *Community Dent Oral Epidemiol.* 2004 Jun;32(3):217-26.
27. Ravin JJ, Nielsen HG. A longitudinal radiographic study of the mineralization of 2nd premolars. *Scand J Dent Res.* 1977 May;85(4):232-6.
28. Shalish M, Peck S, Wasserstein A, Peck L. Malposition of unerupted mandibular second premolar associated with agenesis of its antimeres. *Am J Orthod Dentofacial Orthop.* 2002 Jan;121(1):53-6.
29. Silva Filho, OG, Zinsly SR, Okada CH, Ferrari Junior, FM. Irrupção ectópica do incisivo lateral inferior: diagnóstico e tratamento. *Rev Dental Press Ortodon Ortop Facial.* 1996;1(1):75-80.
30. Vastardis H. The genetics of human tooth agenesis: new discoveries for understanding dental anomalies. *Am J Orthod Dentofacial Orthop.* 2000 Jun;117(6):650-6.

Submitted: November 2009
 Revised and accepted: December 2009

Contact address

Daniela Gamba Garib
 Faculdade de Odontologia de Bauru
 Al. Octávio Pinheiro de Brisola 9-75
 CEP: 17.012-901 – Bauru/SP, Brazil
 E-mail: dgarib@uol.com.br