

# Relationship between mandibular growth and skeletal maturation in young melanodermic Brazilian women\*

Irene Moreira Serafim\*\*, Gisele Naback Lemes Vilani\*\*, Vânia Célia Vieira de Siqueira\*\*\*

## Abstract

**Objective:** To assess the degree of correlation between mandibular growth and skeletal maturation in young melanodermic Brazilian women. **Methods:** The authors examined 140 lateral cephalometric radiographs and an additional 140 radiographs of hands and wrists of young female Brazilian melanodermic subjects aged 8 to 14 years with normal occlusion or Angle Class I malocclusion, who had not been subjected to previous orthodontic treatment. Using the hand and wrist radiographs, the authors evaluated the development of ossification centers in the proximal phalanx of the 3rd finger and the distal epiphysis of the radius bone, by tracing according to the method described by Eklöf and Ringertz. The lateral cephalometric radiographs enabled an analysis of frontal sinus pneumatization according to the method described by Ruf and Pancherz, and of the cephalometric measurements representative of mandibular growth, namely, Co-Go, Co-Gn, Go-Gn, Fg-Pg. The data were statistically analyzed using Pearson's Correlation to determine the degree of relationship between variables. **Results and Conclusions:** A highly significant correlation was found between ossification centers observed on the hand and wrist radiographs and cephalometric measurements representative of the mandibular growth ( $r = 0.777$ ). Although statistically significant, there was a low correlation between frontal sinus pneumatization and the progression of skeletal maturity ( $r = 0.306$ ), as well as a relationship between frontal sinus pneumatization and the cephalometric measurements representative of mandibular growth ( $r = 0.218$ ).

**Keywords:** Skeletal maturation. Melanodermic subjects. Hand and wrist radiographs. Mandibular growth. Frontal sinus.

\* Summary of a Master's dissertation presented at the postgraduate course in Orthodontics of the Pontifical Catholic University of Minas Gerais (PUC-Minas).

\*\* MSc in Orthodontics, Pontifical Catholic University of Minas Gerais - PUC/Minas.

\*\*\* Full Professor and PhD in Orthodontics, Piracicaba School of Dentistry (Unicamp).

## INTRODUCTION AND LITERATURE REVIEW

Knowledge of events related to craniofacial growth and development has been of paramount importance in orthodontics because the selection of a therapeutic goal that ensures maxillomandibular growth must be based on an assessment of each patient's skeletal maturation.<sup>16,25</sup> This information is crucial for orthodontists as an aid in the prevention, diagnosis, planning and early treatment of anomalies since the success or failure of orthodontic treatment is inextricably entwined with craniofacial growth and development.<sup>19,25</sup>

The methods often used to identify skeletal maturation include chronological age, dental age, height, weight,<sup>11</sup> manifestations of secondary sexual characteristics,<sup>22,25</sup> and an assessment of ossification center development.<sup>3,5,6,8,20,21,22,25,27</sup> However, the first four methods are ineffective while the assessment of bone age using primarily hand and wrist radiographs provides the most accurate information about skeletal age. The close relationship between the age at which the body growth rate is at its peak and the period of mineralization of ossification centers in the hand and wrists has been firmly established in the literature.<sup>2-11,13,20,25,27</sup>

Due to concern about the radiographic exposure that patients undergo to produce the necessary orthodontic documentation and also deterred by the costs involved, some practitioners tend to reduce the number of radiographs. Due to this concern, research has been undertaken to enable the use of the structures typically present in radiographs that are part of routine orthodontic documentation, such as lateral radiographs, to assess skeletal maturity.<sup>9,10,18,25</sup> Some have used the analysis of cervical vertebrae<sup>18</sup> while others have studied evaluations of frontal sinus development.<sup>20-24,29</sup>

Anteroposterior mandibular growth during pubertal growth spurt (PGS) is a determining factor in the correction of some sagittal skeletal

disharmonies, thereby contributing to a more balanced facial pattern. However, although increased mandibular dimensions appear more conspicuously during PGS, there is great individual variability in terms of quantity, speed and onset. Professionals must then use diagnostic resources to assist them in predicting how this growth is likely to unfold.<sup>16-20,26,28</sup>

The importance of establishing skeletal maturity during orthodontic diagnosis should not be based solely on the evaluation of the existing structure and function but also on the observation of pubertal growth. If one is to take full advantage of growth, orthodontic treatment needs to start prior to the PGS phase.<sup>9,10,13</sup>

Researchers have investigated the occurrence of PGS in facial dimensions, which would be similar to body height PGS, and have agreed that the processes of skeletal growth and development are influenced by a wide range of mechanisms, especially genetic, endocrine, functional and environmental.<sup>11,16,17</sup>

Some investigations have confirmed the existence of facial growth spurt and have found that it coincides chronologically with the phase of height growth spurt.<sup>11,18</sup> Other studies endorsed this correlation, but an evaluation in boys showed that height growth spurt occurred slightly before facial growth spurt,<sup>17</sup> whereas height growth spurt in girls occurred earlier than maximum mandibular growth.<sup>28</sup> The findings revealed that increases and decreases in the rate of skeletal maturation are accompanied by similar fluctuations in some aspects of facial growth, particularly in the mandible.

Most authors agree that the evaluation of hand and wrist radiographs is the most widely used method for the observation of bone age and skeletal maturation.<sup>2,9,10,13,25</sup> Other studies, however, used the degree of frontal sinus pneumatization as a skeletal assessment method, noting that this anatomical structure correlated with skeletal maturity assessed by means of

hand and wrist radiographs.<sup>20-23</sup>

In light of the above, the need was felt to evaluate the possible association of mandibular growth with these maturational changes in young melanodermic women. Our intent is to contribute additional information to the knowledge base on the this subject.

## PROPOSITION

Based on the obtained information and since this is a cross-sectional study, we evaluated:

1. Changes in mandibular growth in young melanodermic subjects aged 8 to 14 years.
2. Changes in frontal sinus height, width and pneumatization between 8 to 14 years of age.
3. Changes in hand and wrist ossification centers, specifically the development of the proximal epiphysis of the 3rd finger and of the radius bone from 8 to 14 years of age.
4. The degree of correlation between ossification centers as viewed on hand and wrist radiographs and cephalometric measurements representative of the mandibular growth; between frontal sinus pneumatization and the development of ossification centers observed on hand and wrist radiographs; and between frontal sinus pneumatization and cephalometric measurements representative of mandibular growth.

## MATERIAL AND METHODS

### Material

This study was conducted after submitting the project to the Committee of Research Ethics at the Pontifical Catholic University of Minas Gerais and securing their approval No. 00890213-05.

The sample consisted of 140 lateral cephalometric radiographs and 140 hand and wrist radiographs of 140 young female melanodermic subjects with normal occlusion or Angle Class I malocclusion. All featured facial balance. None had been subjected to previous orthodontic

treatment and their ages ranged from 8 years and 0 month to 14 years and 11 months. Sample distribution followed the age brackets, thus: 20 subjects at the age of 8 years, 20 at 9, 20 at 10, 20 at 11, 20 at 12, 20 at 13 and finally 20 were 14 years old.

## Methods

### Sample selection and acquisition

Subjects were classified as melanodermic based on some of the anthropological features mentioned by Bastos de Ávila<sup>1</sup> such as skin color (presence of melanin pigmentation in the skin), spiral hair (curly), a unique morphology of the nose (broad nose base) and mouth (thick and centered lips) and parents and grandparents (ancestry).

Exclusion factors encompassed inadequate general health and oral hygiene, the presence of deep cross and/or open bite, missing teeth and/or respiratory disorders.

To perform the lateral cephalometric radiographs, heads were positioned in a cephalostat with the Frankfurt plane parallel to the ground. We used a Mind Tome Ceph model X x-ray machine, manufactured by Orion Corporation Soredex calibrated at 70 kVp and 10 mA, with exposure time ranging from 0.32 to 0.64 seconds. We used Kodak film, size 18 x 24 cm, equipped with a Lanex intensifier screen. For film development an automatic film developing machine was employed with transport motor compatible with Multi X 36 film spools, keeping chemical solutions at a temperature of 36°C and dry-to-dry development time at 3 minutes and 26 seconds.

The same equipment described above was used to obtain the left hand and wrist radiographs with hands outstretched and centered on the film. The x-ray machine was calibrated to operate at 60 kVp and 10 mA and 0.32 tenths of seconds exposure time using Kodak film, size 18 x 24 cm.

All cephalometric and hand and wrist ra-

diographs were obtained at the same location by a single operator. Only radiographs featuring sufficient clarity and contrast were used to allow good visualization and identification of bone structures and with less than 6% distortion.

A digital gauge (Starret™) with 0.01 mm precision was used to perform all measurements.

#### Evaluation of mandibular dimensions

After identifying the relevant dentoskeletal and tegumental structures landmark definition was based on findings by McNamara Jr.<sup>15</sup> and Wylie<sup>30</sup> (Fig 1):

- Me (Mentum),
- Go (Gonion),
- Pg (Pogonion),
- Gn (Gnathion),
- Co (Condyle),
- Fg (Located in the posterior-most region of the mandibular condyle).

According to the precepts by McNamara Jr.<sup>15</sup> and Wylie<sup>30</sup> the following linear distances were measured (Fig 1):

1. Co-Gn: Effective mandible length (obtained by joining Co to Gn).
2. Co-Go: Mandibular ramus height (obtained by joining Co to Go).
3. Go-Gn: Mandibular body length (obtained by joining Go to Gn).
4. Fg-Pg: Total mandibular length (obtained through the orthogonal projection of both the pogonion and the posterior-most point of the mandibular condyle onto the Go-Me mandibular plane).

#### Evaluation of frontal sinus pneumatization

Based on Rűf and Pancherz,<sup>21,22,23</sup> the following landmarks were selected (Fig 2):

1. Sh - Upper frontal sinus, located in the uppermost region of the frontal sinus.
2. Si - Lower frontal sinus, located in the lowermost region of the frontal sinus.

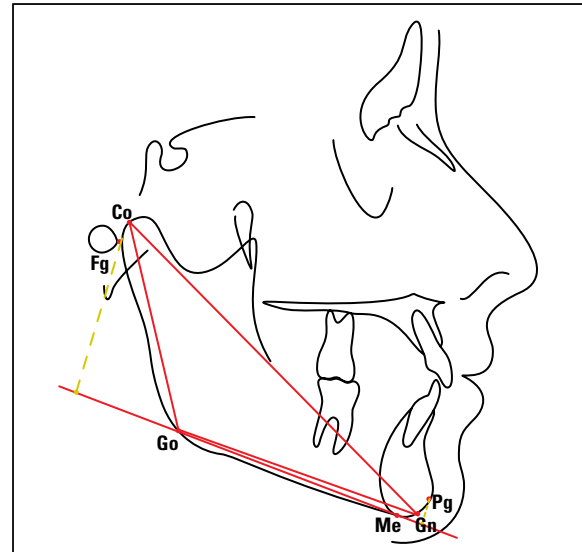


FIGURE 1 - Demarcation of anatomical landmarks and linear measurements.

After landmark identification the following lines were drawn (Fig 2):

1. Sh-Si line - Determined by the junction of Sh and Si.
2. Frontal sinus width - Determined by a line perpendicular to Sh-Si.

Linear distances used for evaluation of the frontal sinus pneumatization (Fig 2):

1. Sh-Si - Distance between Sh and Si representing frontal sinus height.
2. Perpendicular to Sh-Si - Distance at the greatest frontal sinus width, representing the width of the frontal sinus.

#### Evaluation of hand and wrist radiographs

With the purpose of determining skeletal age hand and wrist radiographs were evaluated using the method described by Eklöf and Ringertz<sup>5</sup> due to their widespread application in clinical practice, ease of use and interpretation.<sup>5,25,29</sup> Subsequently the proximal phalanx of the 3rd finger and the distal epiphysis of the radius bone were identified (Fig 3).

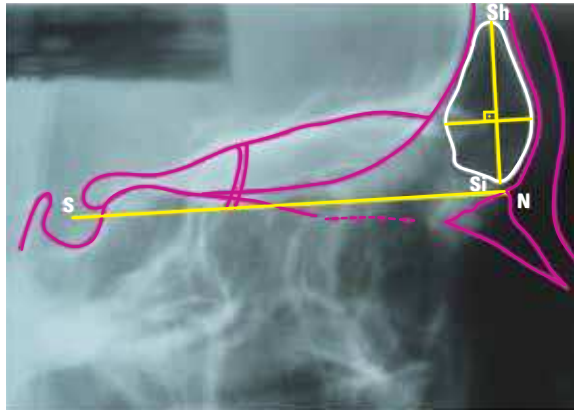


FIGURE 2 - Identification and demarcation of cephalometric landmarks, lines and frontal sinus magnitudes.

After tracing, the length of the proximal epiphysis of the 3rd finger and the width of the epiphysis of the radius were measured, using a digital gauge (Fig 3).

Measurements and tracings were performed twice by the same researcher in 20% of the sample, randomly selected and at intervals of about 30 days, resulting in two measurements of all magnitudes in order to minimize method error. Student's t test was applied, which allowed us to ascertain that there were no statistically significant differences between the first and second measures of all variables (Table 1).

#### Statistical methodology

Statistical analysis was performed on data pertaining to skeletal maturation observed in ossification centers present in the hand and wrist and frontal sinus radiographs as well as mandibular data observed in the lateral cephalometric radiographs. At first, our purpose was to establish a descriptive analysis of the data, obtain the mean, median, standard deviation and minimum and maximum values for each variable and each of the age groups.

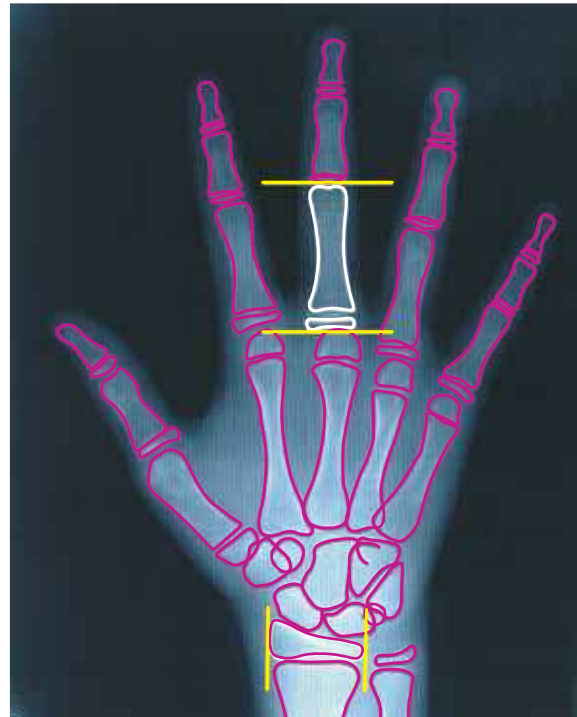


FIGURE 3 - Schematic drawing of the hand and wrist, highlighting the height of the proximal phalanx of the 3rd finger and the width of the epiphysis of the radius.

The data were compared to detect the presence or absence of correlations between frontal sinus variables, mandibular growth variables and those of the hands and wrists. Pearson's Correlation to check for a linear relationship was applied between these variables.

Factor Analysis was applied to find linear combinations between frontal sinus, mandibular measurements and hand and wrist measurements, i.e., frontal sinus height was the first variable, mandibular growth measurements the second variable, and the width of the distal epiphysis of the radius bone in conjunction with the height of the proximal phalanx of the 3rd finger represented the third variable. These three variables were also correlated with one another by using Pearson's Correlation.

All results were considered significant at a 5% significance level ( $p < 0.05$ ).

TABLE 1 - Student's t test to assess method error.

	MEASUREMENTS	MEAN	P-VALUE
<b>Mandibular Length</b>	Co-Gn (1)	102.90	0.142
	Co-Gn (2)	102.94	
	Co-Go (1)	46.47	0.241
	Co-Go (2)	46.44	
	Go-Gn (1)	68.87	0.334
	Go-Gn (2)	68.90	
	Fg-Pg (1)	96.86	0.328
	Fg-Pg (2)	97.11	
<b>Frontal Sinus</b>	Frontal Sinus Height (1)	21.44	0.293
	Frontal Sinus Height (2)	21.40	
	Frontal Sinus Width (1)	7.46	0.060
	Frontal Sinus Width (2)	7.51	
<b>Phalanx of 3rd finger Radius Bone</b>	Height of proximal phalanx of 3rd finger (1)	35.86	0.070
	Height of proximal phalanx of 3rd finger (2)	35.95	
	Width of distal epiphysis of Radius (1)	21.88	0.164
	Width of distal epiphysis of Radius (2)	21.95	

## RESULTS

The results achieved after statistical analysis are shown in Figures 4 to 10 and in Table 2.

Frontal sinus height and width at age 8 were 21.01 mm and 6.75 mm; at 9 years, 21.86 mm and 8.18 mm; at 10, 25.03 mm and 8.93 mm; at 11, 22.41 mm and 8.35 mm; at 12, 26.37 mm and 8.71 mm; at 13, 28.35 mm and 9.45 mm; at 14, 26.15 mm and 8.25 mm, respectively.

At 8 years of age, the subjects' mean height of the proximal phalanx of the 3rd finger was 34.82 mm and the width of the epiphysis of the radius measured 21.30 mm; at age 9, 36.89 mm and 22.46 mm; at 10, 40.01 mm and 25.85 mm; at 11, 40.97 mm and 27.38 mm; at 12, 42.54 mm and 27.67 mm; at age 13, 42.12 mm and 27.30 mm; at 14, 43.11 mm and 29.39 mm, respectively.

At 8 years of age, the following subject mea-

surements were found: Co-Gn = 100.76 mm, Co-Go = 45.68 mm, Go-Gn = 67.50 mm and Pg-Fg = 94.43 mm; at 9, 105.04 mm, 47.26 mm, 70.25 mm and 99.29 mm; at 10, 108.46 mm, 48.58 mm, 73.31 mm and 102.55 mm; at 11 years, 111.72 mm, 51.35 mm, 73.24 mm and 105.68 mm; at 12, 114.25 mm, 52.09 mm, 76.61 mm and 107.88 mm; at 13, 115.31 mm, 54.65 mm, 77.83 mm and 107.84 mm; at 14, 118.03 mm, 55.79 mm, 79.43 mm and 110.29 mm, respectively.

## DISCUSSION

In the present study, we sought to correlate changes in the proximal phalanx of the 3rd finger and in the epiphysis of the distal radius (as assessed with the aid of hand and wrist radiographs), with frontal sinus pneumatization (as evaluated with the aid of lateral cephalometric

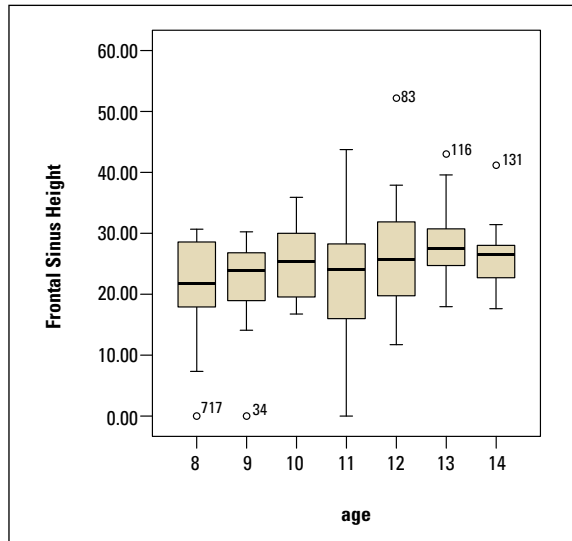


FIGURE 4 - Distribution of frontal sinus height and width by age groups.

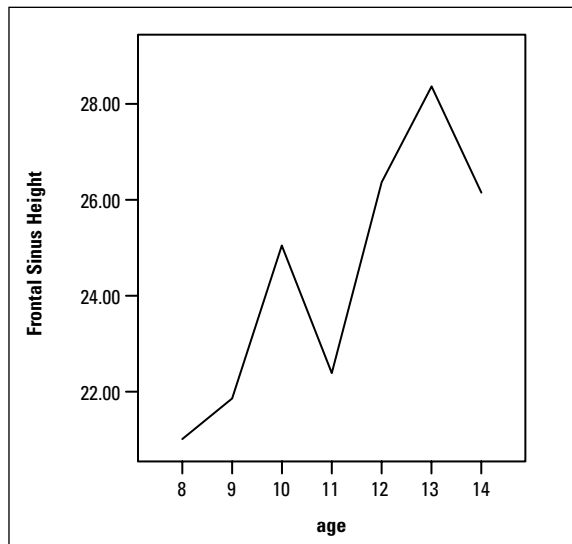
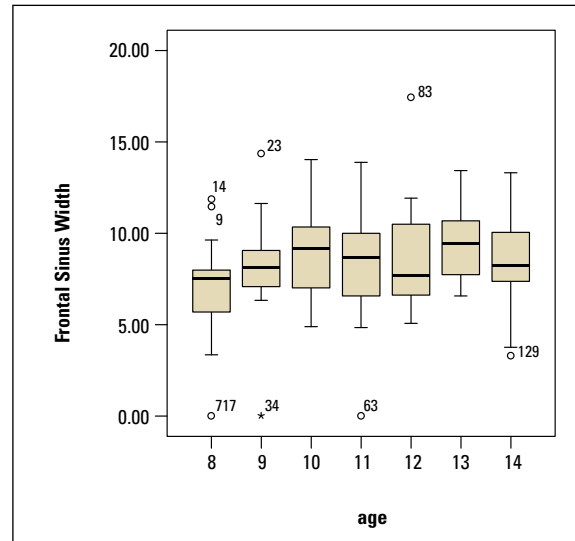
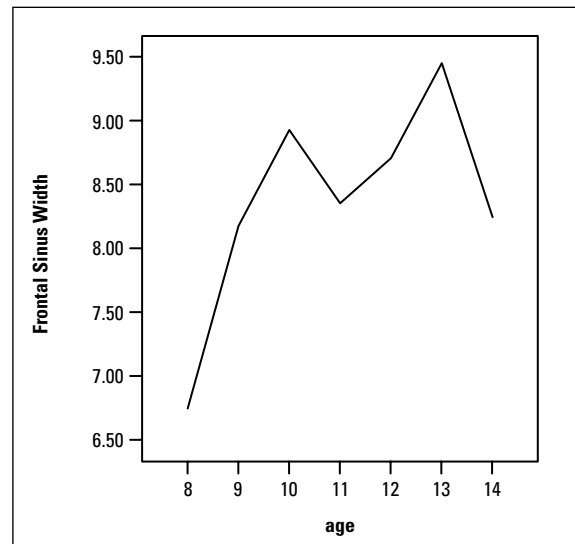


FIGURE 5 - Graph showing frontal sinus height and width means.



radiographs) and with anteroposterior mandibular growth.

To evaluate pubertal growth, hand and wrist radiographs were used given the accuracy afforded by this area. The methodology developed by Eklöf and Ringertz<sup>5</sup> was selected because it is

suitable for the evaluation of Brazilian patients. It is also reliable and easily reproducible by different examiners using well defined parameters.

This study revealed that pubertal growth spurt began between 9 and 10 years of age and peaked at age 12. Figures 6 and 7 suggest

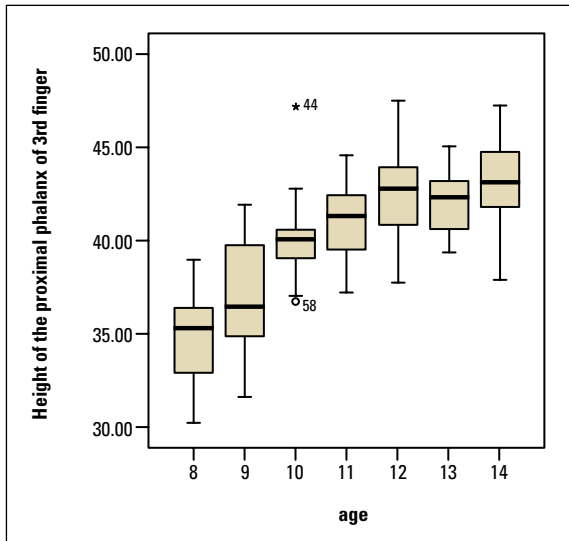


FIGURE 6 - Distribution of hand and wrist measurements by age groups.

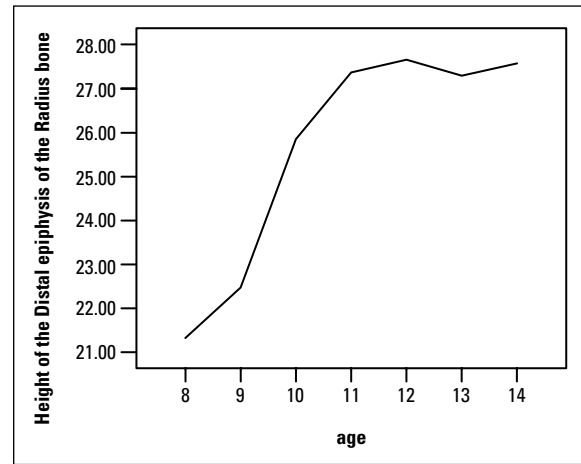
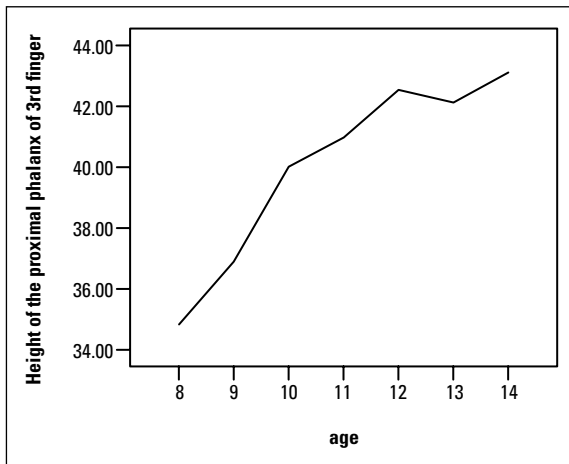
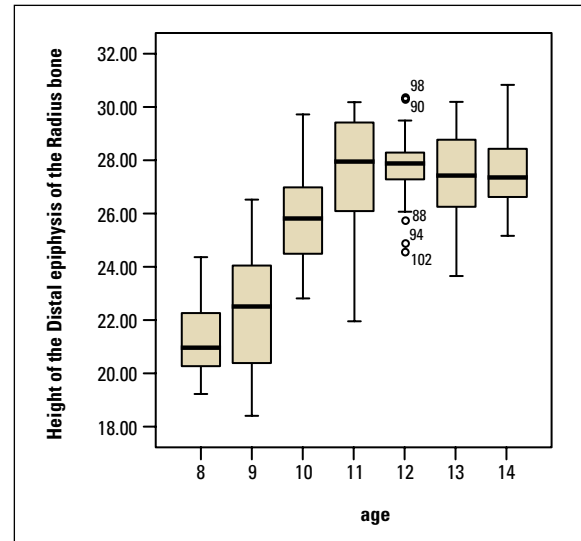


FIGURE 7 - Graph showing hand and wrist measurement means by age groups.

that young melanodermic women tend to experience premature skeletal maturation, which agrees with previous findings in the literature.<sup>4,29</sup> A research conducted to evaluate young leucodermic women showed that the onset of pubertal growth spurt occurred at a mean age of 10.5 years and pubertal growth speed peaked on average 2 years after spurt onset<sup>2,9,10</sup> or later,

between ages 13 and 14.<sup>27</sup>

Frontal sinus pneumatization was also assessed as an indicator of bone age since the frontal sinus is significantly correlated with skeletal maturation—as assessed by hand and wrist radiographs<sup>7,20-23,29</sup> and the time of maximum pneumatization nearly coincides with puberty in both genders.<sup>14,24</sup>



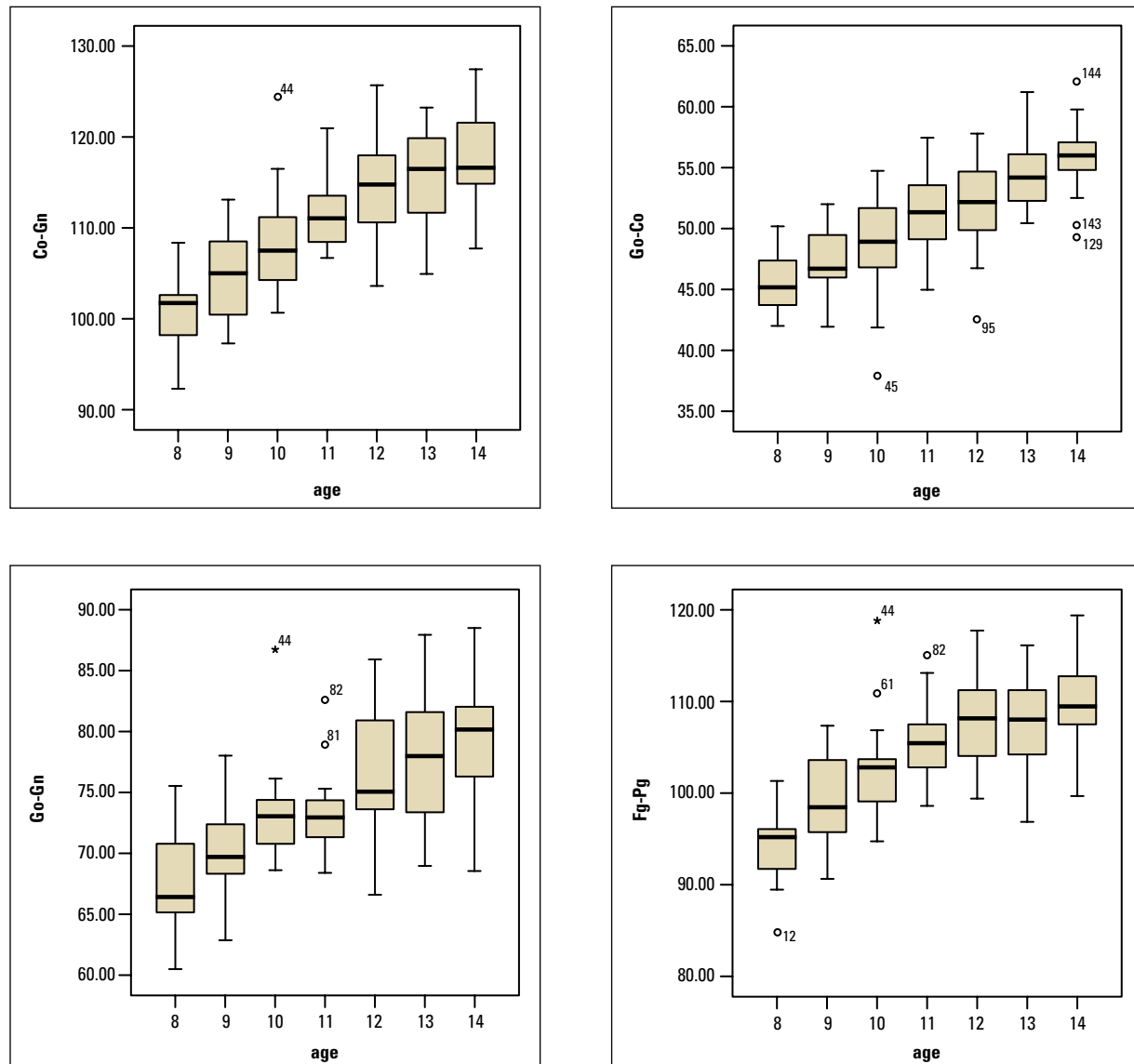


FIGURE 8 - Distribution of mandibular variables by age.

The maximum dimensions of frontal sinus height and width occurred at the age of 13 years confirming findings from previous studies.<sup>14,24,29</sup>

Figures 4 and 5 illustrate the variations in frontal sinus height and width by age groups. It was noted that frontal sinus height and width experienced the highest increase at age 13, whereas the major increases in both variables

occurred between ages 9 and 10 and between 12 and 13. This study found a statistical correlation of 0.306 ( $p < 0.001$ ) between frontal sinus height and width and the measurements obtained from hand and wrist radiographs, as seen in Table 2, which corroborates previous studies.<sup>29</sup>

Figures 6 and 7 show the data pertaining to

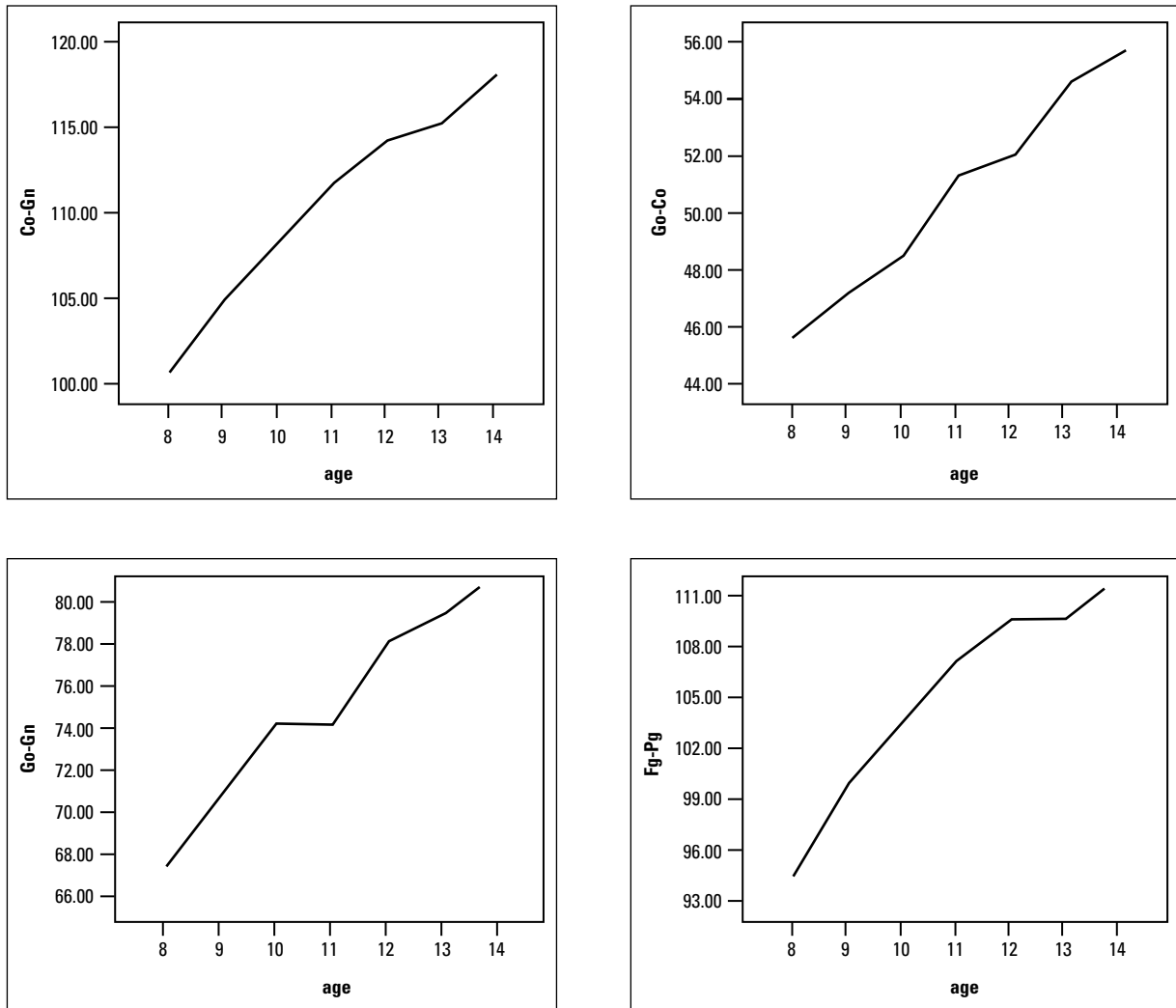


FIGURE 9 - Graph showing means for mandibular variables.

the width of the distal epiphysis of the radius bone and the height of the proximal phalanx of the 3rd finger. It was found that the width of the distal epiphysis of the radius and the height of the proximal phalanx of the 3rd finger increased with age. The only decrease was found in the mean of ages 12-13 whereas meaningful increases were found between ages 9 and 10. This information attests to the progression of phenomena related to skeletal maturation, as determined by changes in hand and wrist ossification

centers.<sup>2,3,6,9,10,13,27</sup>

Figures 8 and 9 show an increase with age of all mandibular variables evaluated in this study, i.e., Co-Go, Co-Gn, Go-Gn and Pg-Fg. A progressive growth trend was found to exist in all variables. The variable Go-Gn demonstrated greater variability between age groups showing very similar means at ages 10 and 11 while variable Pg-Fg showed similar means at ages 12 and 13. This study corroborates previous investigations<sup>11,18,19,28</sup> in terms of mandibular growth.

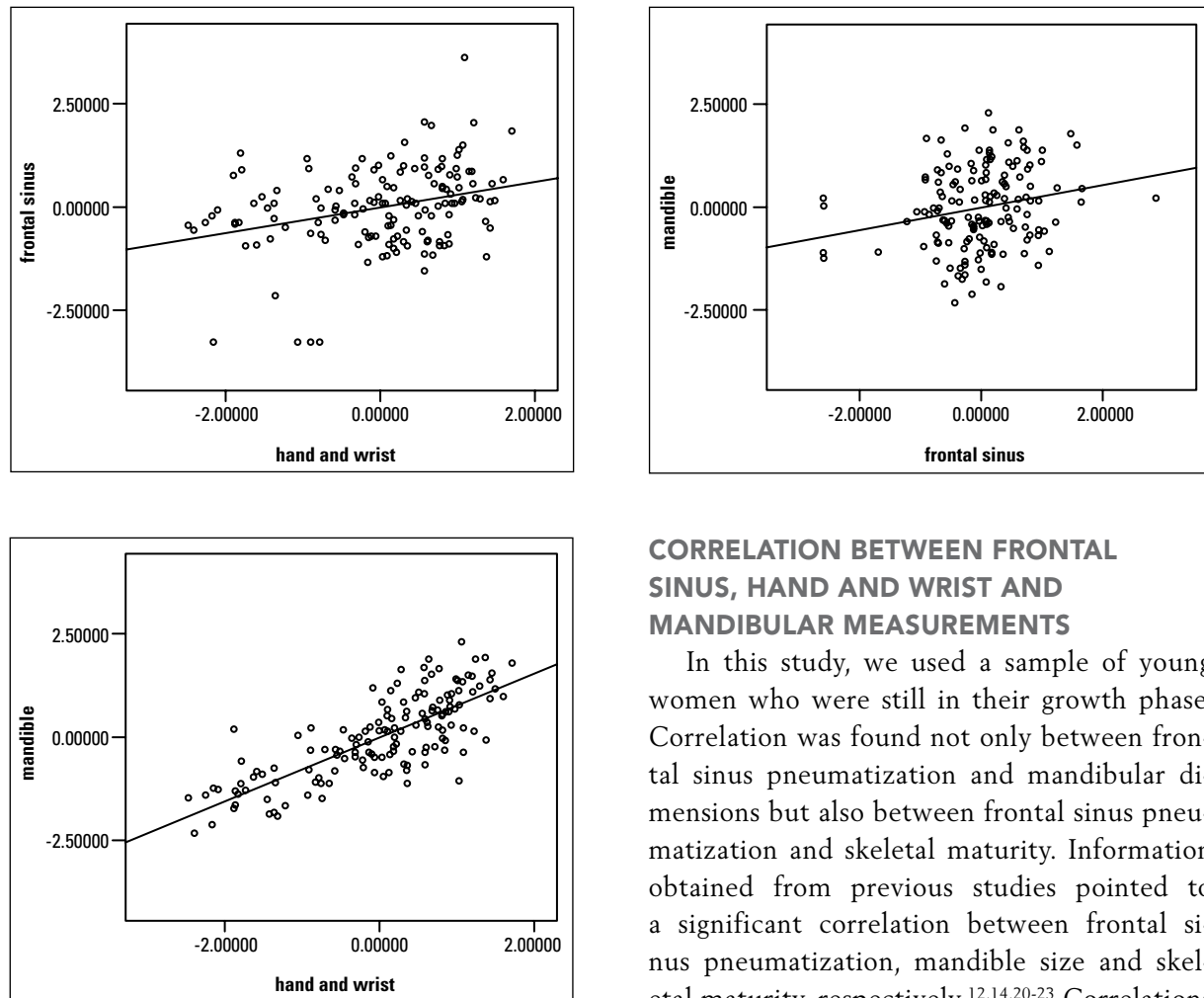


FIGURE 10 - Graphs showing dispersion of mandible, frontal sinus and hand and wrist indices.

### CORRELATION BETWEEN FRONTAL SINUS, HAND AND WRIST AND MANDIBULAR MEASUREMENTS

In this study, we used a sample of young women who were still in their growth phase. Correlation was found not only between frontal sinus pneumatization and mandibular dimensions but also between frontal sinus pneumatization and skeletal maturity. Information obtained from previous studies pointed to a significant correlation between frontal sinus pneumatization, mandible size and skeletal maturity, respectively.<sup>12,14,20-23</sup> Correlations were also found between height and mandibular growth.<sup>18,26</sup> Other studies found no significant correlation between bone age and mandibular growth.<sup>16,19</sup>

As can be observed in Table 2 and in the scatterplots of Figure 10, there was a significant and positive linear correlation between frontal sinus height and width, the height of the proximal phalanx of the 3rd finger and the width of the epiphysis of the radius bone, as well as with the mandibular length measurements, i.e., Co-Go, Go-Gn and Fg-Pg.

Also in Table 2, we found a correlation between mandibular growth features and pubertal growth features. Such correlation was found through an analysis of skeletal maturity based

TABLE 2 - Pearson's Correlation matrix for mandible, frontal sinus and hand and wrist dimensions.

		MANDIBLE	FRONTAL SINUS	HAND AND WRIST
<b>Mandible</b>	Correlation	1.000	0.218*	0.777*
	p-value		0.008	0.000
<b>Frontal Sinus</b>	Correlation		1.000	0.306*
	p-value			< 0.001
<b>Hand and Wrist</b>	Correlation			1.000
	p-value			

\*p < 0.05.

on the evaluation of hand and wrist radiographs and frontal sinus pneumatization.

Table 2 shows that Pearson's correlation was found between mandibular, frontal sinus and hand and wrist indices. A significant correlation was found between the three indices ( $p > 0.05$ ). In other words, as the hand and wrist indices increased so did frontal sinus indices. Hand and wrist indices increased side by side with mandibular indices. Finally, frontal sinus indices increased as mandibular indices also increased.

The correlations found between frontal sinus height and width, height of the proximal phalanx of the 3rd finger, width of the epiphysis of the radius and mandibular measurements were positive and significant at 5% probability.

## CONCLUSIONS

In light of sample characteristics, methodology and the results and information obtained in this study, it is safe to conclude that:

A highly significant correlation was found between ossification centers observed on the hand and wrist radiographs and cephalometric measurements representative of the mandibular growth ( $r = 0.777$ ). Although statistically significant, there was a low correlation between frontal sinus pneumatization and the progression of skeletal maturity ( $r = 0.306$ ), as well as a relationship between the frontal sinus pneumatization and the cephalometric measurements representative of mandibular growth ( $r = 0.218$ ).

## REFERENCES

1. Bastos de Ávila J. Antropologia física. 10 ed. Rio de Janeiro: Agir; 1958. 324p.
2. Bowden BD. Epiphysial changes in the hand/wrist area as indicators of adolescent stage. *Aust Orthod J*. 1976 Feb;4(3):87-104.
3. Chapman SM. Ossification of the adductor sesamoide and adolescent growth spurt. *Angle Orthod*. 1972 Jul;42(3):236-44.
4. Chaves AP, Ferreira RI, Araújo TM. Maturação esquelética nas raças branca e negra. *Ortodontia Gaúcha*. 1999 jan-jun;3(1):45-52.
5. Eklöf O, Ringertz H. A method for assessment of skeletal maturity. *Ann Radiol*. 1967 May;10(3/4):330-6.
6. Fishman LS. Radiographic evaluation of skeletal maturation. A clinically oriented method on hand-wrist films. *Angle Orthod*. 1982 Apr;52(2):88-112.
7. Gagliardi A, Winning T, Kaidonis J, Hughes T, Townsend GC. Association of frontal sinus development with somatic and skeletal maturation in Aboriginal Australians: a longitudinal study. *Homo*. 2004;55(1-2):39-52.
8. Greulich WW, Pyle SI. Radiographic atlas of skeletal development of the hand and wrist. 2nd ed. Stanford, Califórnia: Stanford University Press; 1959.
9. Hägg U, Taranger J. Skeletal stages of the hand and wrist as indicators of the pubertal growth spurt. *Acta Odontol Scand*. 1980;38(3):187-200.
10. Hägg U, Taranger J. Maturation indicators and the pubertal growth spurt. *Am J Orthod*. 1982 Oct;82(4):299-309.
11. Hunter CJ. The correlation of facial growth with body height and skeletal maturation at adolescence. *Angle Orthod*. 1966 Jan;36(1):44-54.
12. Maresch MM. Paranasal sinuses from birth to adolescence. *Am J Dis Child*. 1940; 60:55-78.
13. Martins JCR. Surto de crescimento puberal e maturação óssea em Ortodontia. [Dissertação]. Universidade de São Paulo (SP); 1979.
14. McLaughlin RB Jr, Rehl RM, Lanza DC. Clinical relevant frontal sinus anatomy and physiology. *Otolaryngol Clin North Am*. 2001 Feb;34(1):1-22.
15. McNamara JA Jr. A method of cephalometric evaluation. *Am J Orthod*. 1984 Dec; 86(6):449-69.

16. Mitani H, Sato K. Comparison of mandibular growth with other variables during puberty. *Angle Orthod.* 1992 Fall;62(3):217-22.
17. Ochoa BK, Nanda RS. Comparison of maxillary and mandibular growth. *Am J Orthod Dentofacial Orthop.* 2004 Feb;125(2):148-59.
18. Prata THC, Medici Filho E, Moraes LC, Moraes MEL. Estudo do crescimento maxilar e mandibular na fase de aceleração do surto de crescimento puberal. *Rev Dental Press Ortod Ortop Facial.* 2001 jul-ago;6(4):19-31.
19. Prates NS. Crescimento crânio-facial e maturação óssea. [Dissertação]. Universidade Estadual de Campinas (SP); 1976.
20. Rossouw PE, Lombard CJ, Harris AM. The frontal sinus and mandibular growth prediction. *Am J Orthod Dentofacial Orthop.* 1991 Dec;100(6):542-6.
21. Rüt S, Pancherz H. Frontal sinus development as an indicator for somatic maturity at puberty? *Am J Orthod Dentofacial Orthop.* 1996 Nov;110(5):476-82.
22. Rüt S, Pancherz H. Can frontal sinus development be used for the prediction of skeletal maturity at puberty? *Acta Odontol Scand.* 1996 Nov;54(4):229-34.
23. Rüt S, Pancherz H. Development of the frontal sinus in relation to somatic and skeletal maturity. A cephalometric roentgenographic study at puberty. *Eur J Orthod.* 1996; 18(5):491-7.
24. Shah RK, Dhingra JK, Carter BL, Rebeiz EE. Paranasal sinus development: a radiographic study. *Laryngoscope.* 2003 Feb;113(2):205-9.
25. Siqueira VCV de, Martins DR, Canuto CE, Janson GRP. O emprego das radiografias da mão e punho no diagnóstico ortodôntico. *Rev Dental Press Ortod Ortop Facial.* 1999 maio-jun;4(3):20-9.
26. Thiesen G, Rego MVNN, Lima EMS. Estudo longitudinal da relação entre o crescimento mandibular e o crescimento estatural em indivíduos com Classe II esquelética. *Rev Dental Press Ortod Ortop Facial.* 2004 set-out; 9(5):28-40.
27. Tibério S, Vigorito JW. O estudo da maturação esquelética de crianças brasileiras leucodermas, de 8 a 15 anos, em referência à ossificação dos ossos psiforme, gancho, falanges média e proximal dos dedos 2 e 3. *Ortodontia.* 1989 maio-ago;22(2):4-19.
28. Tofani MI. Mandibular growth at puberty. *Am J Orthod.* 1972 Aug; 62(2):176-95.
29. Vilani GNL. A utilização do seio frontal como indicador de maturidade esquelética. [Dissertação]. Universidade Católica de Minas Gerais (BH); 2003.
30. Wylie WH. The assessment of anteroposterior dysplasia. *Angle Orthod.* 1947 Oct; 17(314):97-109.

Submitted: May 2007  
Revised and accepted: December 2009

---

**Contact Address**

Vania C. V. Siqueira  
Rua José Corder 87 – Jardim Modelo  
CEP: 13.400-010 – Piracicaba/SP, Brazil  
E-mail: [siqueira@fop.unicamp.br](mailto:siqueira@fop.unicamp.br)