

# Angle Class I malocclusion treated with extraction of first permanent molars\*

Ivan Tadeu Pinheiro da Silva\*\*

## Abstract

Angle Class I malocclusion is characterized by normal anteroposterior molar relationship, which may or may not be accompanied by skeletal changes—in the vertical or transverse planes—or dental changes. Bimaxillary dental protrusion, characterized by pronounced labial inclination of maxillary and mandibular incisors combined with excessive overjet, expose patients to dental trauma and compromise aesthetics. In deciding which teeth to extract for Class I correction the first or second premolars are usually selected due to their location in the dental arch. However, the extraction of a first permanent molar compromised by caries or extensive restoration may be an alternative that ensures the preservation of a healthy tooth instead of one that has already been manipulated. This case, treated in an unusual manner by the extraction of four first permanent molars, was presented to the Brazilian Board of Orthodontics and Dentofacial Orthopedics (BBO) as representative of category 2, as part of the requirements for obtaining the BBO diplomate title.

**Keywords:** Angle Class I malocclusion. Tooth extraction. Corrective Orthodontics.

## HISTORY AND ETIOLOGY

The patient, a Caucasian male, 13 years and four months old, presented for initial examination with the chief complaint of maxillary incisor protrusion. He was in good general health and reported a medical history of bronchitis and allergy. He had no sucking or postural habits and had normal swallowing and speech. Regarding oral health, his mandibular first molar crowns were significantly destroyed. The mandibular second molars and maxillary first molars showed carious lesions on the occlusal surface and the presence of dental calculi and gingivitis was observed.

## DIAGNOSIS

The patient's facial aesthetics was compromised by a convex profile, lip protrusion, lack of passive lip seal and lower lip eversion. He presented a mesofacial pattern, Class I molar relationship, slightly altered canine relationship with a Class II tendency, a 6 mm overjet, 4 mm overbite, severely projected maxillary incisors, a 1.4 mm Bolton discrepancy with excess in the mandibular anterior teeth and developing third molars (Figs 1, 2 and 3).

Cephalometric evaluation revealed a Class I skeletal pattern ( $ANB = 4^\circ$ ) with slight maxillary protrusion ( $SNA = 84^\circ$ ) and a well posi-

\* Case Report, category 2, approved by the Brazilian Board of Orthodontics and Dentofacial Orthopedics.

\*\* Specialist in Pediatric Dentistry, EAP - Brazilian Dental Association, Ponta Grossa/PR. Specialist in Orthodontics and Facial Orthopedics, EAP - Brazilian Dental Association, Curitiba/PR. Diplomate of the Brazilian Board of Orthodontics and Dentofacial Orthopedics.

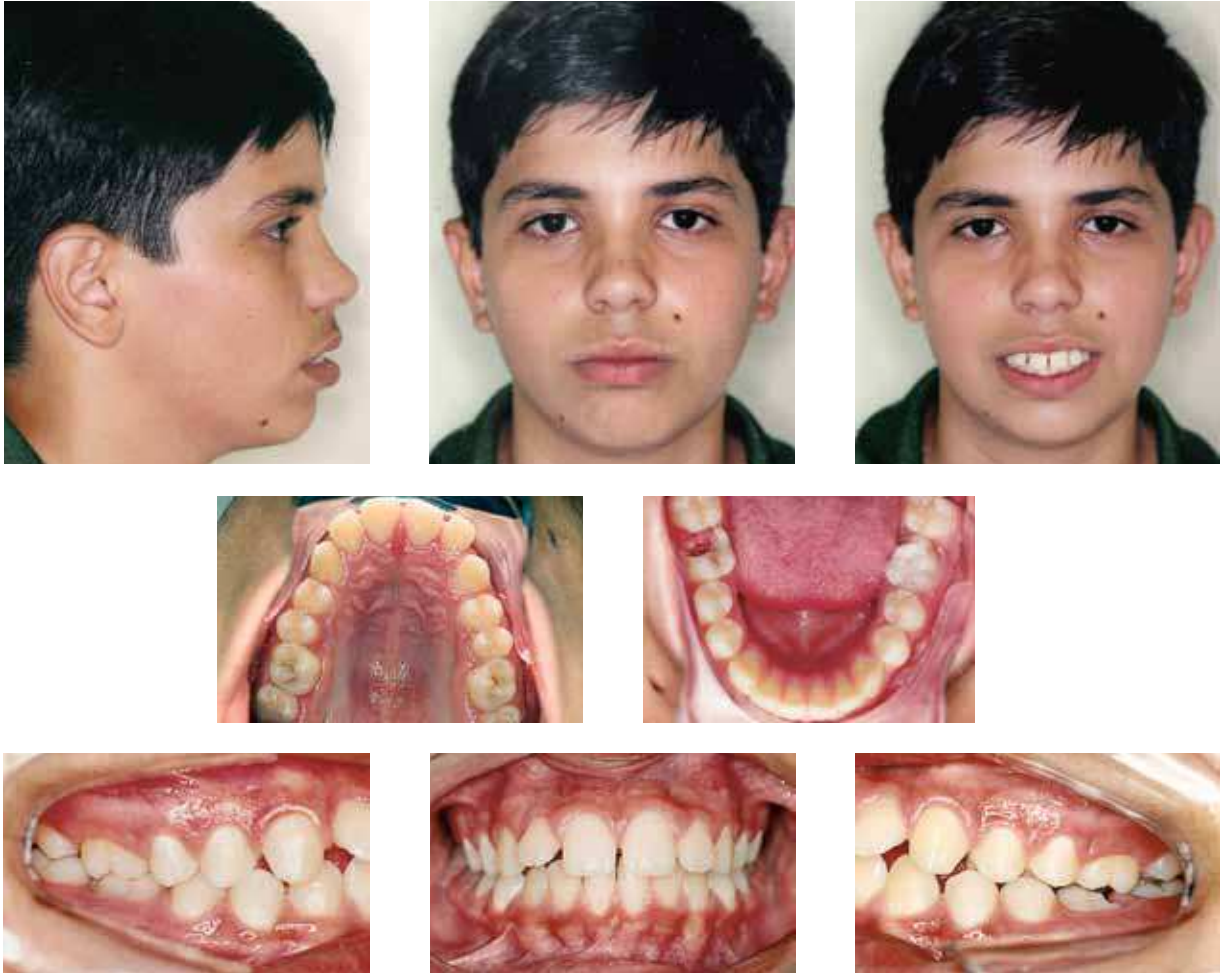

FIGURE 1 - Initial facial and intraoral photographs.

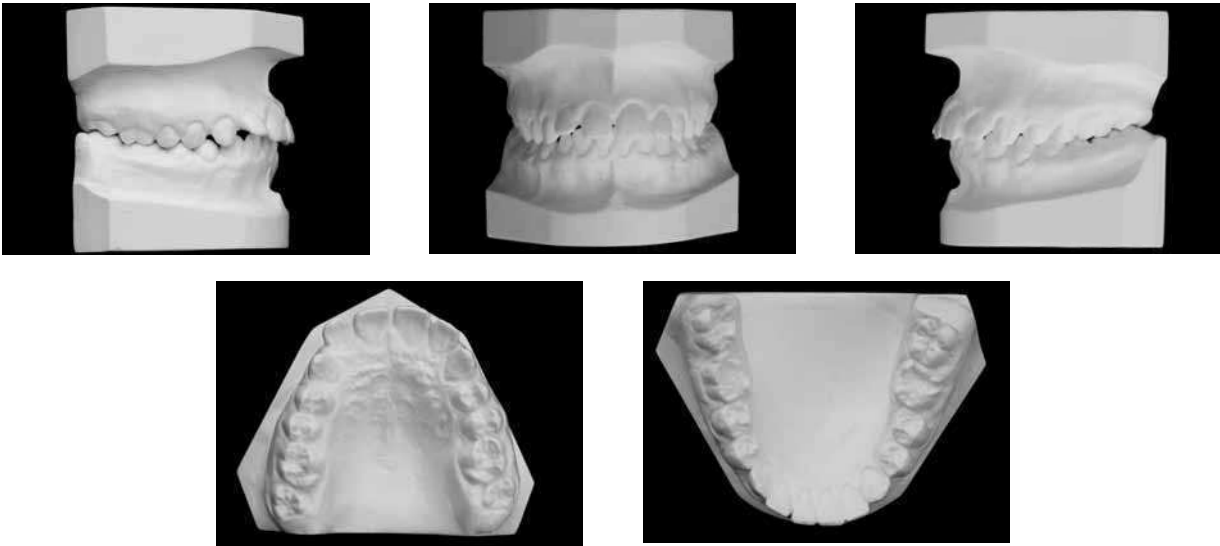


FIGURE 2 - Initial dental casts.

tioned mandible relatively to the cranial base (SNB=80°). He presented a divergent growth pattern (SN-GoGN = 38.5°) and a marked facial convexity (Convex. angle = 9.5°). His skeletal and cephalometric features can be evaluated in Figure 4 and Table 1.

### TREATMENT GOALS

Treatment goals included improvement of facial aesthetics, obtaining a balanced labial musculature and a stable occlusion from the functional point of view, maintaining the existing

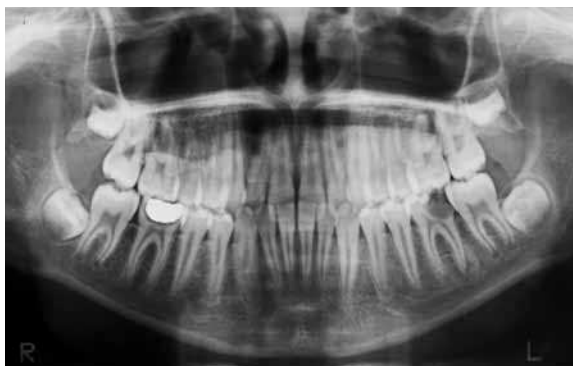
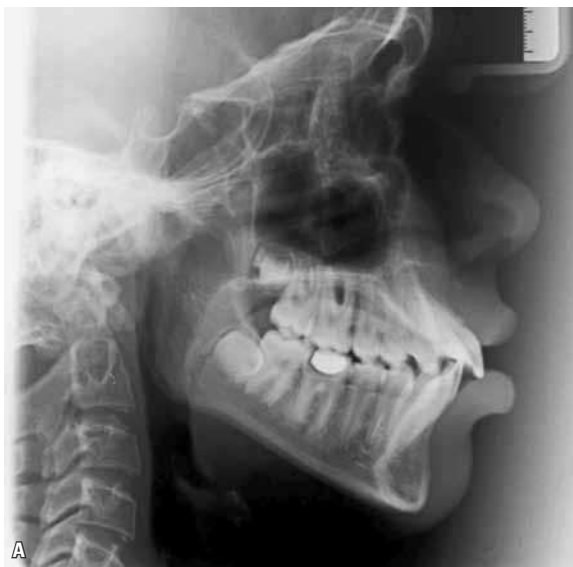
FIGURE 3 - Initial panoramic radiograph.



relationship between molars, improvement in the relationship between canines, correction of maxillary incisor protrusion, reduction of overbite and overjet, maintaining healthy teeth and eliminating any teeth with destroyed crowns.

### TREATMENT PLAN

The treatment plan provided for extraction of the mandibular first molars given their crown destruction, and need of endodontic treatment and prosthetic rehabilitation, which would be convenient to avoid in such a young patient. In order to maintain mechanics symmetry while not depending heavily on patient compliance, maxillary first molar extractions were also planned.

The planned retention consisted of a removable maxillary retainer and an canine to canine bonded lingual retainer in the mandibular arch.

### TREATMENT PROGRESS

At first, the patient was referred for periodontal treatment, restorations in the maxillary and mandibular second molars and extraction of the four first permanent molars. A 0.022-in Roth straight wire fixed orthodontic appliance was then

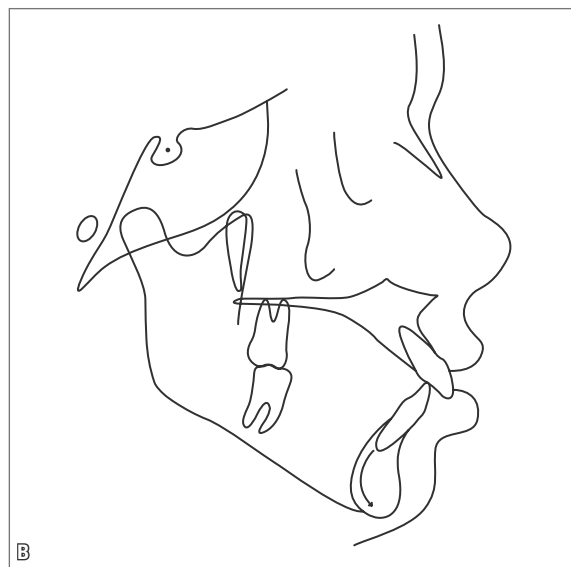


FIGURE 4 - Initial lateral cephalometric radiograph (A) and cephalometric tracing (B).

installed on both arches. Leveling and alignment were performed with round 0.012-in to 0.016-in nickel-titanium archwires followed by round stainless steel 0.018-in and 0.020-in archwires, and finally rectangular stainless steel 0.019 X 0.025-in archwire for space closure using sliding mechanics. Intermaxillary Class II elastics were used to control anchorage. During treatment, the patient was evaluated and monitored by the bimanual technique aimed at achieving coincidence of centric relation (CR) and maximal habitual intercuspation (MHI). At the end of treatment neuromuscular deprogramming was performed using transcutaneous

electrical neuromuscular stimulation (TENS), confirming the coincidence of RC and MHI.<sup>10</sup>

After finishing the orthodontic treatment and ascertaining that all planned objectives had been achieved, the fixed appliances were removed. A removable maxillary retainer was used for retention, to be used 24/7 in the first year, only nights in the second year, and three nights a week after that period, for an unlimited period of time. In the mandibular arch, a 0.036-in stainless steel lingual retainer was bonded to the canines.

Considering that orthodontic treatment was performed with extraction of the first perma-

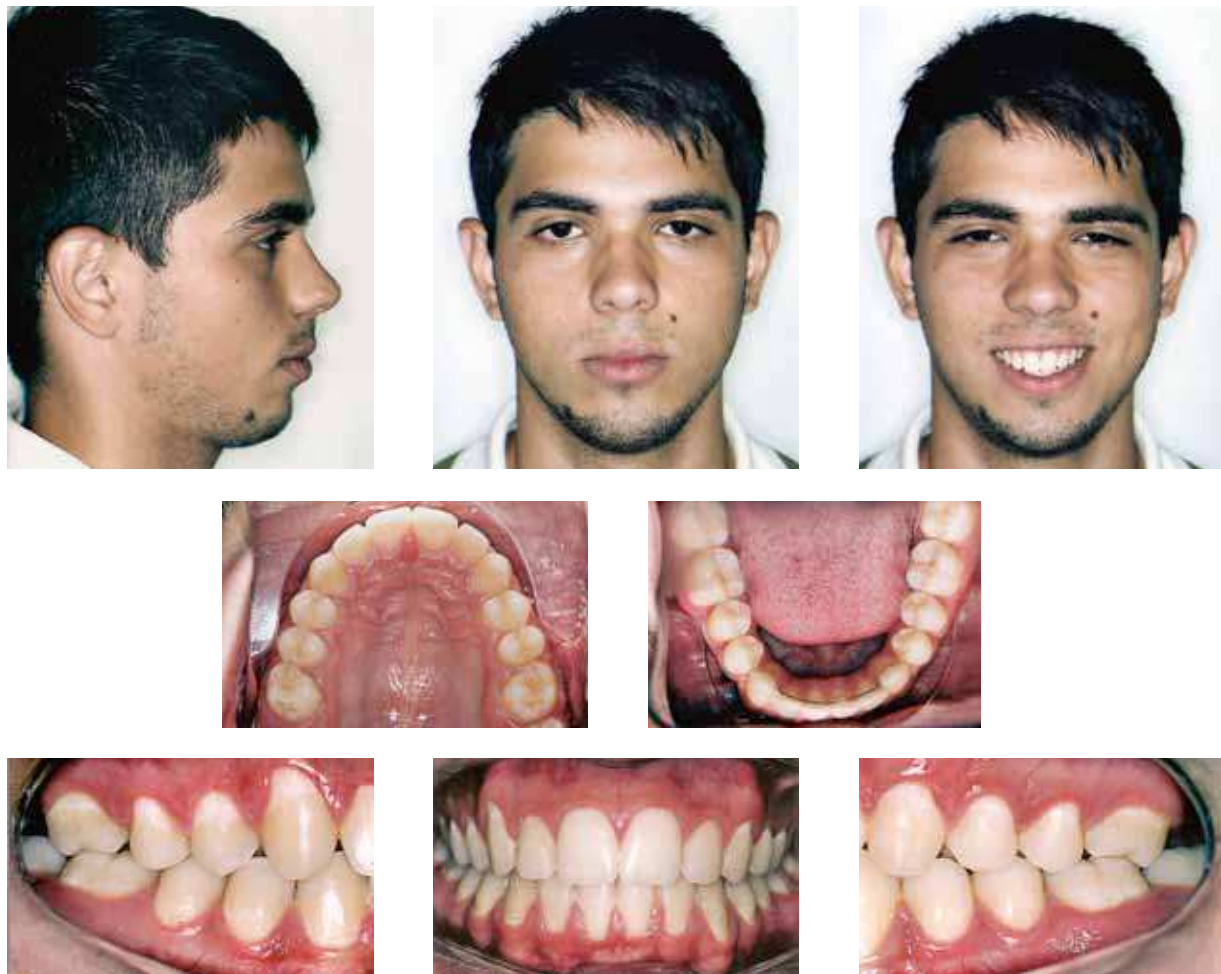


FIGURE 5 - Final facial and intraoral photographs.



ment molars, the space remaining for eruption of maxillary and mandibular third molars was increased, thereby reducing the likelihood of impaction.<sup>3</sup> Thus, the patient was instructed to return periodically for monitoring third molars development and eruption.

## RESULTS

After evaluating the patient's final examinations, it was found that the planned treatment goals had been achieved. From an aesthetic point of view, the facial profile was balanced with competent lip seal, reduced facial convexity and

a pleasing smile line (Figs 5, 6, 7, 8, 9 and 10). Therefore, the profile improved substantially, in contrast to what Stalpers et al<sup>6</sup> reported, describing that orthodontic treatment involving extraction of maxillary first permanent molars exerts a minor effect on profile soft tissue.

The maxilla and mandible maintained their anteroposterior relationship, with the ANB angle remaining at 4°. Maxillary dentition improved with the correction of incisor protrusion and reduction of overjet. As can be seen in Table 1, the angular value of 1-NA decreased from 32° to 23° and its linear value fell from 9 mm to 4 mm.

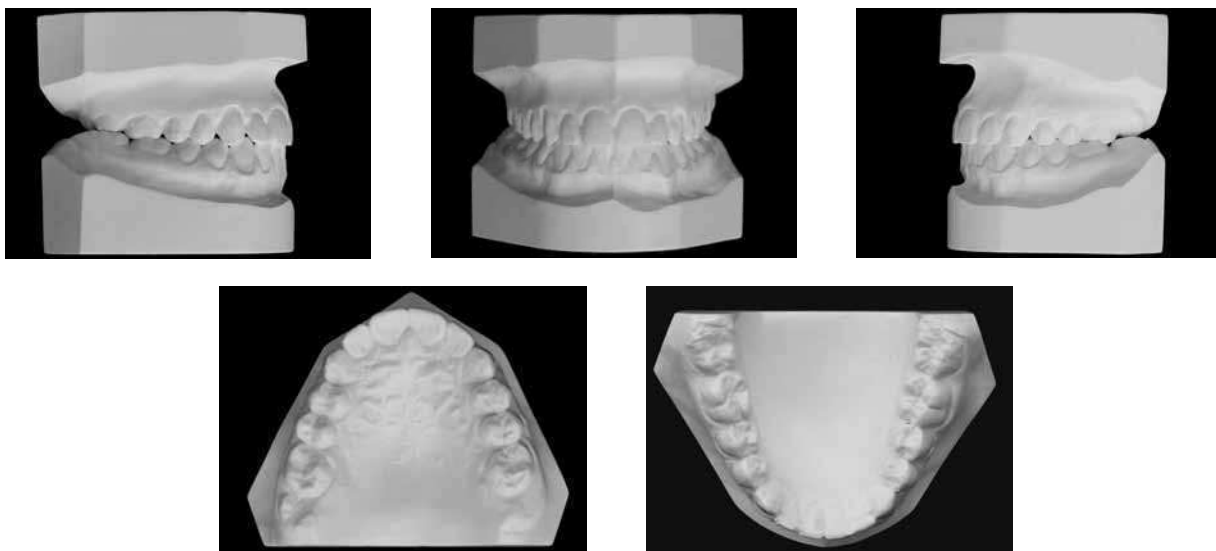


FIGURE 6 - Final dental casts.

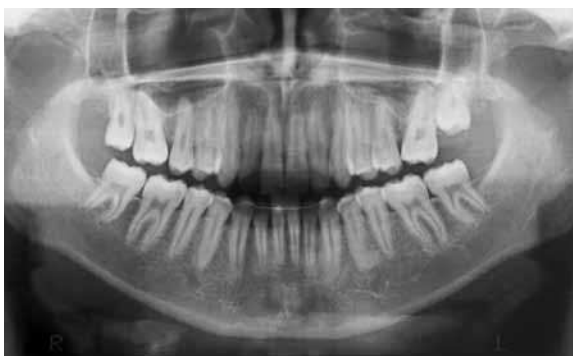

FIGURE 7 - Final panoramic radiograph.

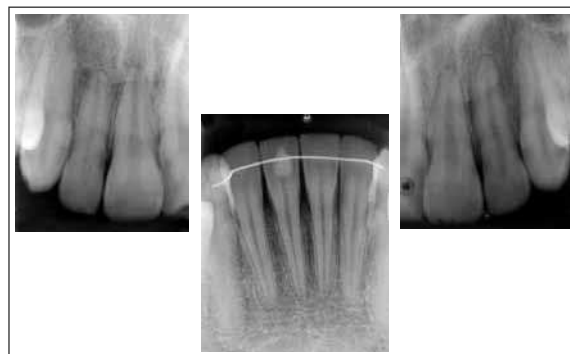

FIGURE 8 - Final periapical radiographs of maxillary and mandibular incisors.

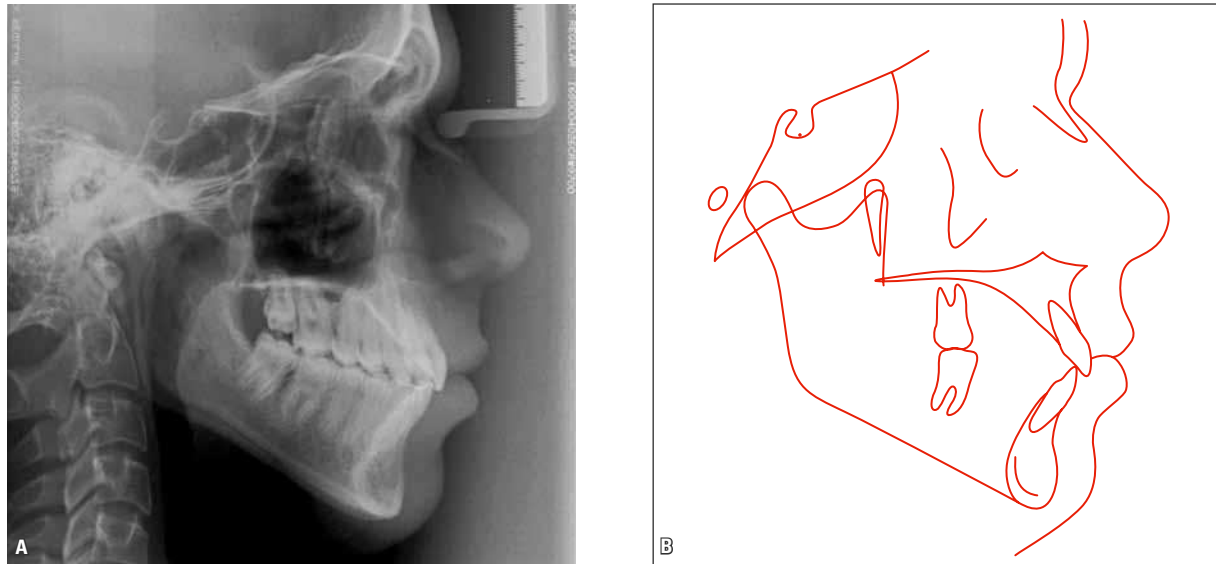


FIGURE 9 - Final lateral cephalometric radiograph (A) and cephalometric tracing (B).

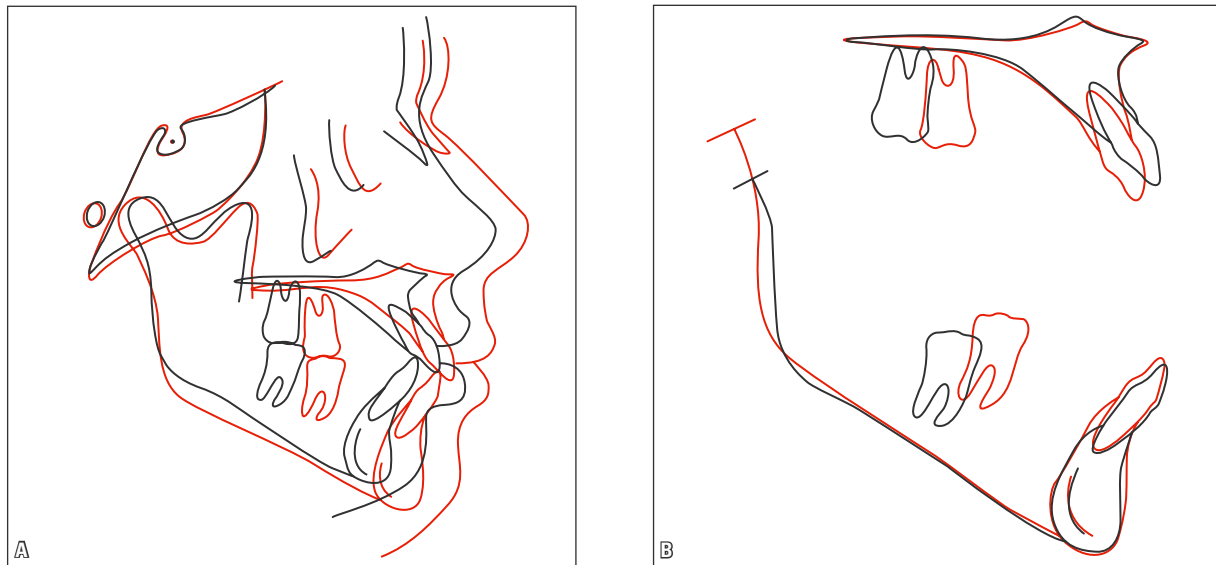


FIGURE 10 - Total (A) and partial (B) superimpositions of initial (black) and final (red) cephalometric tracings.

In the mandibular incisors a slight tipping decrease occurred, which caused a reduction in the IMPA and I-NB angles, as well as in the I-NB and I-APo linear measurements. By reducing the interincisal angle and thereby decreasing the distance between the S line and the upper and lower lips, the

profile was improved. The incisors were retracted and uprighted. Overbite was reduced as a result of mandibular molar extrusion. However, thanks to favorable vertical growth, a slight mandibular rotation occurred in the counterclockwise direction, with the SN-GoGn angle decreasing from 38.5°

to 36° (Table 1, Figs 11 and 12). The maxillary second molars, occupying the position of the first molars were not fully upright, but this inclination secured a greater settlement in the mesial marginal ridge of the mandibular third molar, occupying the second molar position, as described by Andrews,<sup>1</sup> and thus improving stability. The maxillary third molars, in the position of the second molars, were not placed in occlusion with their antagonists to avoid extending treatment time.

It should be stressed that the teeth used in the cephalometric tracings (initial, final and two years

after treatment) were the second permanent molars (Figs 4, 9, 10, 15 and 16). Thus, maxillary molars were moved mesially by translation (bodily movement) and maxillary incisors retracted. Mandibular second molars were moved mesially by translation to occupy the space of the first molars, as reported by Hom and Turley<sup>7</sup> in their analysis of the effects of space closure on the area of mandibular first molars in adults.

The relationship between the arches was maintained at normal molar occlusion with the second molars occupying the position of the

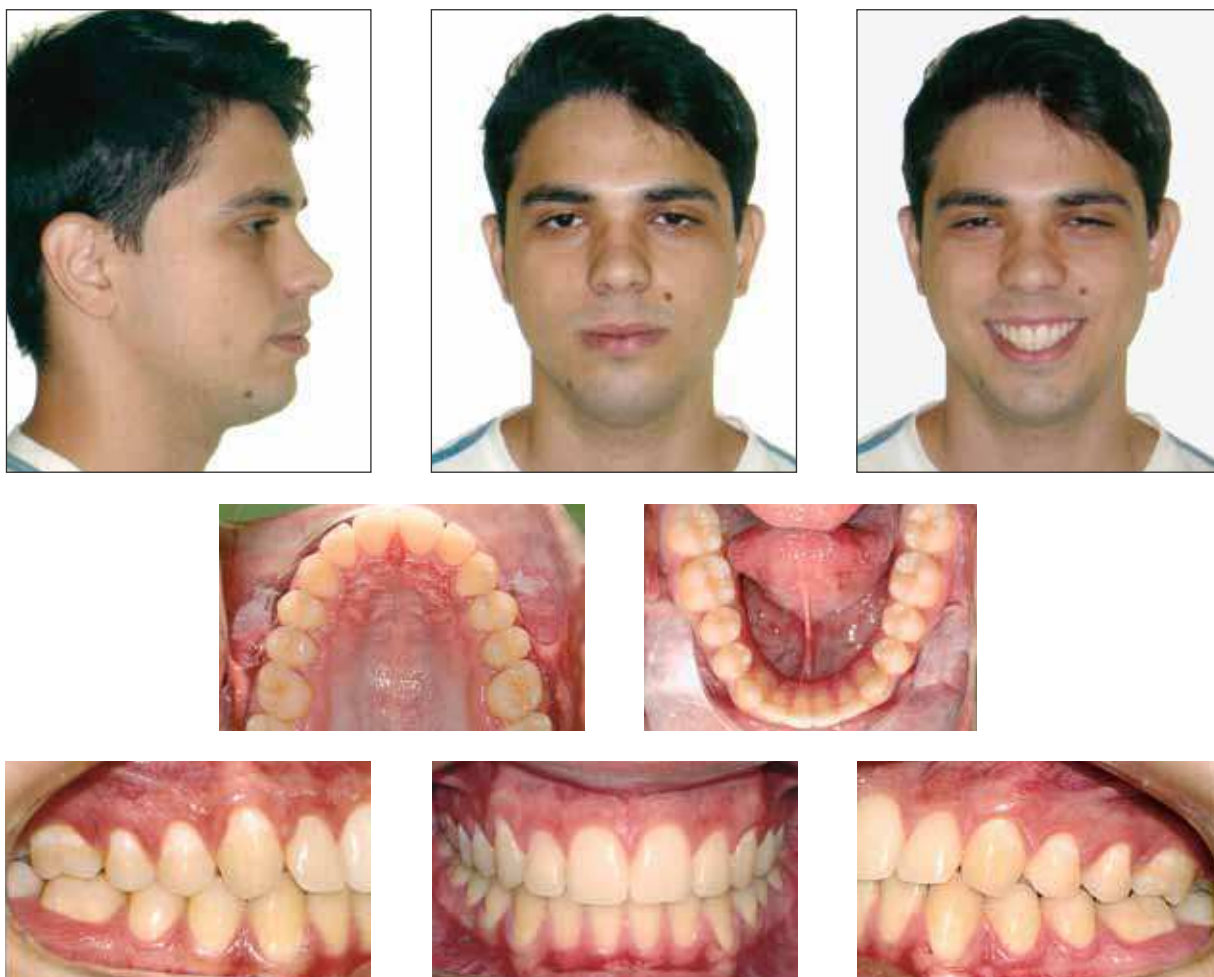


FIGURE 11 - Facial and intraoral control photographs taken two years after treatment completion.

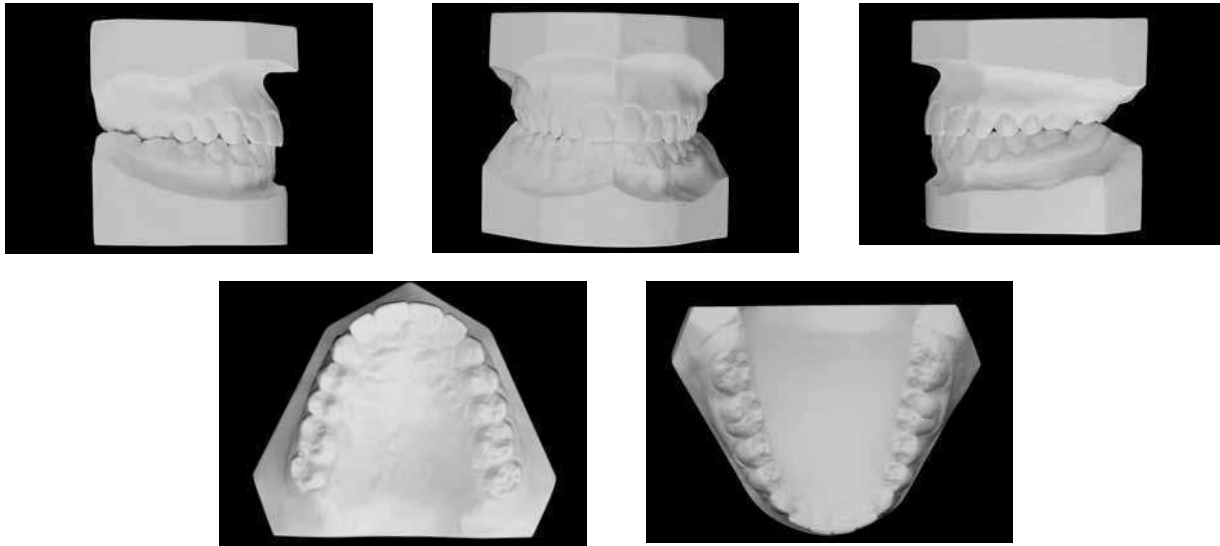


FIGURE 12 - Dental casts after two years.

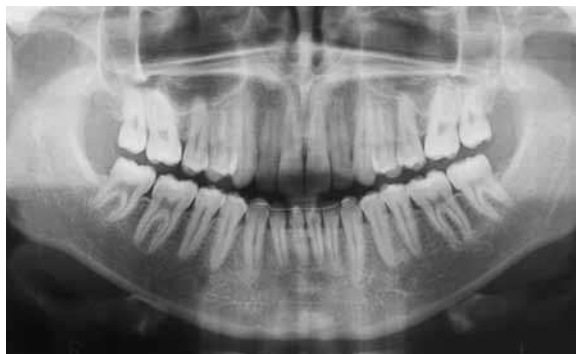

FIGURE 13 - Panoramic radiograph two years after treatment completion.

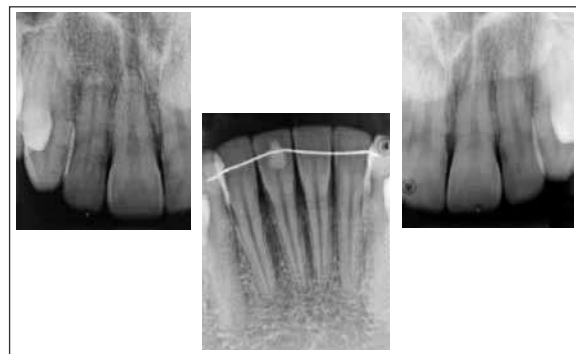

FIGURE 14 - Periapical radiographs two years after treatment completion.

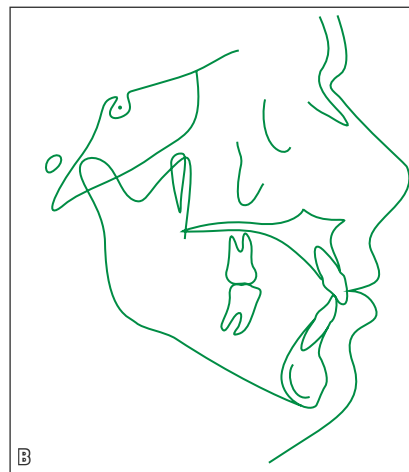
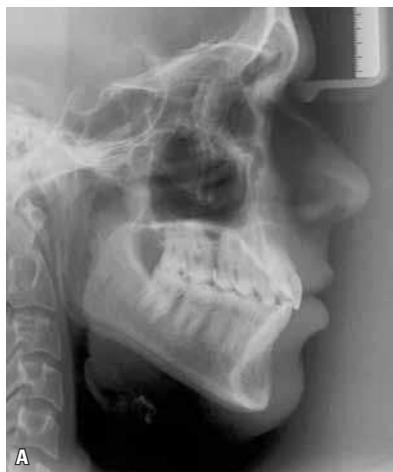

FIGURE 15 - Lateral cephalometric radiograph (A) and cephalometric tracing (B) two years after treatment completion.



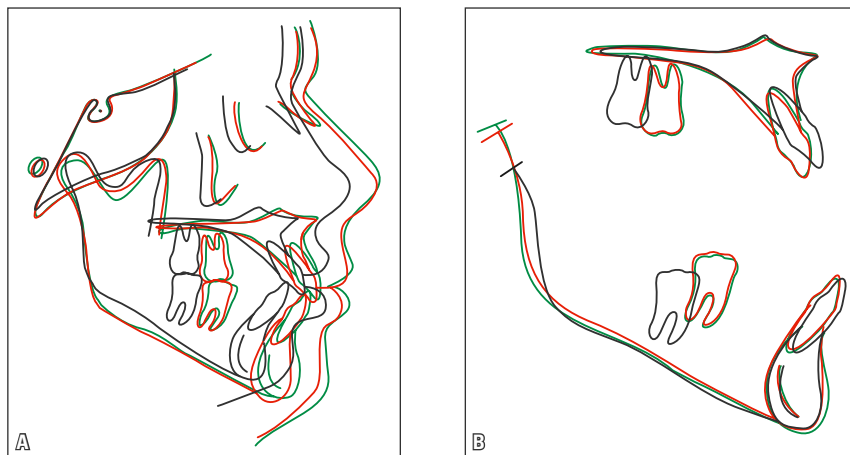


FIGURE 16 - Total (A) and partial (B) superimpositions of initial (black), final (red) and two-year posttreatment (green) cephalometric tracings.

TABLE 1 - Summary of cephalometric measurements.

		MEASUREMENTS	Normal	A	B	A-B DIFFERENCE	C
Skeletal Pattern	SNA (Steiner)	82°	84°	85°	0	85°	
	SNB (Steiner)	80°	80°	81°	1	82°	
	ANB (Steiner)	2°	4°	4°	0	3°	
	Convexity Angle (Downs)	0°	9.5°	8°	1.5	6°	
	Y axis (Downs)	59°	61°	60°	1	58.5°	
	Facial Angle (Downs)	87°	86.5°	89°	2.5	90°	
	SN-GoGn (Steiner)	32°	38.5°	36°	2.5	36°	
	FMA (Tweed)	25°	32°	30°	2	28.5°	
	IMPA (Tweed)	90°	97°	94°	3	93°	
Dental Pattern	$\perp$ - NA (degrees) (Steiner)	22°	32°	23°	9	21.5°	
	$\perp$ - NA (mm) (Steiner)	4 mm	9 mm	4 mm	6	6 mm	
	$\bar{\perp}$ - NB (degrees) (Steiner)	25°	37°	33°	4	31°	
	$\bar{\perp}$ - NB (mm) (Steiner)	4 mm	9 mm	6.5 mm	2.5	7 mm	
	$\frac{1}{\bar{\perp}}$ - Interincisal angle (Downs)	130°	108°	121°	13	123.5°	
	$\bar{\perp}$ - APo (mm) (Ricketts)	1 mm	6 mm	3 mm	3	2.5 mm	
Profile	Upper Lip - S Line (Steiner)	0 mm	3 mm	0.5 mm	2.5	1 mm	
	Lower Lip - S Line (Steiner)	0 mm	7 mm	2 mm	5	3 mm	

TABLE 2 - Maxillary and mandibular intercanine and intermolar widths.

MEASUREMENTS (cm)	A	B	A-B	C
Maxillary intercanine width	39	38	1	38
Mandibular intercanine width	27.5	27	0.5	27
Maxillary intermolar width	50	52	2	52
Mandibular intermolar width	45	44	1	44

first molars and canines in normal occlusion. As a result, adequate stability would be expected given the adequate intercuspation that was achieved. In Table 2 it can be observed that the intermolar and intercanine distances were maintained. Figures 11, 12, 13, 14, 15 and 16 depict that the final facial, skeletal and dental results obtained with treatment were stable two years after treatment.

### FINAL CONSIDERATIONS

Angle Class I malocclusion<sup>2</sup> is characterized by skeletal changes—in the vertical or transverse planes—, or dental changes. Bimaxillary dental protrusion, when coupled with excessive overjet, increases patient exposure to dental trauma while compromising aesthetics. When extractions are indicated the choice often falls on premolars due to their strategic position in the transition zone between the anterior and posterior segments. However, other approaches should be considered, especially when the patient presents with caries, extensive restorations, periapical lesions or prostheses.<sup>4</sup> Despite advances in prevention, first

molar loss rate is still high, affecting nearly 35% of children with mixed dentition.<sup>9</sup> The characteristics of malocclusion in this patient, with his significant mandibular first molars coronal destruction resemble those found by Normando,<sup>5</sup> who reported an increased frequency of Class II canine relationship in patients with this teeth missing. Hom and Turley<sup>7</sup> believe that space closure in the region of missing mandibular first permanent molars should be regarded as a therapeutic approach. In 1899, Angle<sup>2</sup> defined first permanent molars as “the key to normal occlusion,” considering them essential for dentition stability, probably because these teeth are the first permanent teeth of the posterior segment and thus provide guidance for the eruption of the others.

In 1973, Jensen<sup>8</sup> asserted that the extraction of the four first premolars followed by the extraction of the four third molars is equivalent to the loss of 25% of the total dental material. In his view, the latter was unnecessary since most of the space left by the third molar is not used to accommodate the remaining teeth. Moreover, the extraction of four first molars is equivalent to 12.5% of the dental material, and virtually the entire space is used.

It can therefore be concluded that this case was successful for both the patient and his legal guardians. Treatment goals were achieved, with the establishment of a normal occlusion in canines and second molars, in the position of the first molars. Maxillary incisors protrusion was eliminated while overjet and overbite were reduced, thereby improving facial aesthetics. Teeth with destroyed crowns were eliminated, which would otherwise require endodontics and prosthetics, and healthy teeth were preserved. Muscle balance and functionally stable occlusion were accomplished.

---

## REFERENCES

1. Andrews LF. The six keys to normal occlusion. *Am J Orthod.* 1972 Sep;62(3):296-309.
2. Angle EH. Classification of malocclusion. *Dental Cosmos.* 1899; 41(2):248-64.
3. Bayram M, Ozer M, Arici S. Effects of first molar extraction on third molar angulation and eruption space. *Oral Surg Oral Med Oral Pathol Oral Radiol Endod.* 2009 Feb;107(2):e14-20.
4. Diaz MCA, Pinzan A, Freitas MR. Extração de primeiros molares permanentes – apresentação de um caso. *Ortodontia.* 1992;25(1):47-53.
5. Normando DCA. Alterações oclusais espontâneas decorrentes da perda dos primeiros molares permanentes inferiores. *Rev Dental Press Ortod Ortop Facial.* 2003 maio-jun;8(3):15-23.
6. Stalpers MJ, Boonij JW, Bronkhorst EM, Kuijpers-Jagtman AM, Katsaros C. Extraction of maxillary first permanent molars in patients with Class II Division 1 malocclusion. *Am J Orthod Dentofacial Orthop.* 2007 Sep;132(3):316-23.
7. Hom BM, Turley PK. The effects of space closure of the mandibular first molar area in adults. *Am J Orthod.* 1984 Jun;85(6):457-69.
8. Jensen ID. Extraction of first molars in discrepancy cases. *Am J Orthod.* 1973;64(2):115-36.
9. Silva OG Filho, Freitas SF, Cavassan AO. Oclusão: prevalência de oclusão normal e má oclusão na dentadura mista em escolares da cidade de Bauru (São Paulo). Parte I: relação sagital. *Rev Odontol Univ São Paulo.* 1990 abr-jun;4(2):130-7.
10. Silva ITP, Telles FS, Moro A. Diagnóstico ortodôntico em relação cêntrica: comparação de medidas cefalométricas em relação cêntrica obtida pela "TENS" com medidas em máxima intercuspidação habitual. *Rev Dental Press Ortod Ortop Facial.* 2001 maio-jun;6(3):7-24.

Submitted: May 2010  
Revised and accepted: June 2010

---

### Contact address

Ivan Tadeu Pinheiro da Silva  
Rua Nove, nº 1519 – Q E 12 L10 / Setor Marista  
CEP: 74.150 - 130 – Goiânia / GO, Brazil  
E-mail: ortodontia@ortoevidente.com