

# Orthodontic traction: Possible consequences for maxillary canines and adjacent teeth

## Part 1: Root resorption in lateral incisors and premolars

Alberto Consolaro\*

Some professionals are reluctant to indicate orthodontic traction, especially for upper canines. Among the most common reasons for restricting the indication of orthodontic traction are:

- 1) Root resorption in lateral incisors and premolars.
- 2) External cervical resorption of the canines under traction.
- 3) Alveolodental ankylosis of the canine(s) involved in the process.
- 4) Calcific metamorphosis of the pulp and aseptic pulp necrosis.

These conditions do not result primarily and specifically from orthodontic traction, and can be avoided if certain technical precautions are followed. For a better understanding of what these technical precautions are and how they work preventively against the possible consequences of orthodontic traction, we need a biological foundation. This is the goal of this series of studies on orthodontic traction, especially of upper canines, and its possible consequences.

### **Development, structure and functions of the dental follicle**

The dental follicle occupies the radiolucent space around the crowns of unerupted teeth (Figs 1 and 2). It is firmly attached to the surface of the crown by the reduced epithelium of the enamel organ (Fig 3). This thin and delicate epithelial component is sustained and nourished by a thick layer of connective tissue with a variable density of collagen, sometimes loosely, sometimes even hyalinized. The outer portion of dental follicles binds to the surrounding bone (Figs 2 and 3). In measurements of the pericoronal space in periapical radiographs and orthopantomographs, or panoramic radiographs, the thickness of the dental follicle can reach up to 5.6 mm and still maintain normal structure and organization<sup>2,4</sup> (Fig 3).

By removing the follicle and detaching it from the surrounding bone a tissue fragment is obtained which is organized like a thin film and is therefore also known as pericoronal membrane. The isolated tissue fragment represented

\* Full Professor of Pathology, FOB-USP and FORP-USP Postgraduate courses.

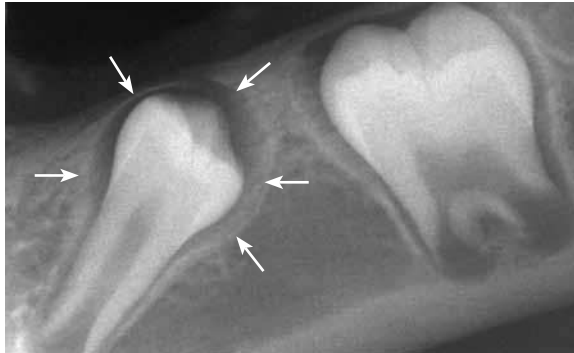

FIGURE 1 - Typical image of the pericoronal space and normal follicle: homogeneous radiolucency with no overlapping radiopaque or radiolucent points; clear bone limit with solid, uniform line (arrows); uniform thickness, regular contour with maximum thickness ranging between 1 and 5.6 mm.<sup>24</sup>

by the dental follicle has the appearance of a sack containing the dental crown and is thus also called pericoronal pouch.

In the middle of the collagen fibers and other components of the extracellular matrix of follicular connective tissue there are islands and cords of epithelial cells, remnants of the dental lamina (Fig 3), whose number varies according to patient age.<sup>2</sup>

### Gubernacular cord development

The dental lamina gives rise to tooth germs in the deepest parts of what will become the

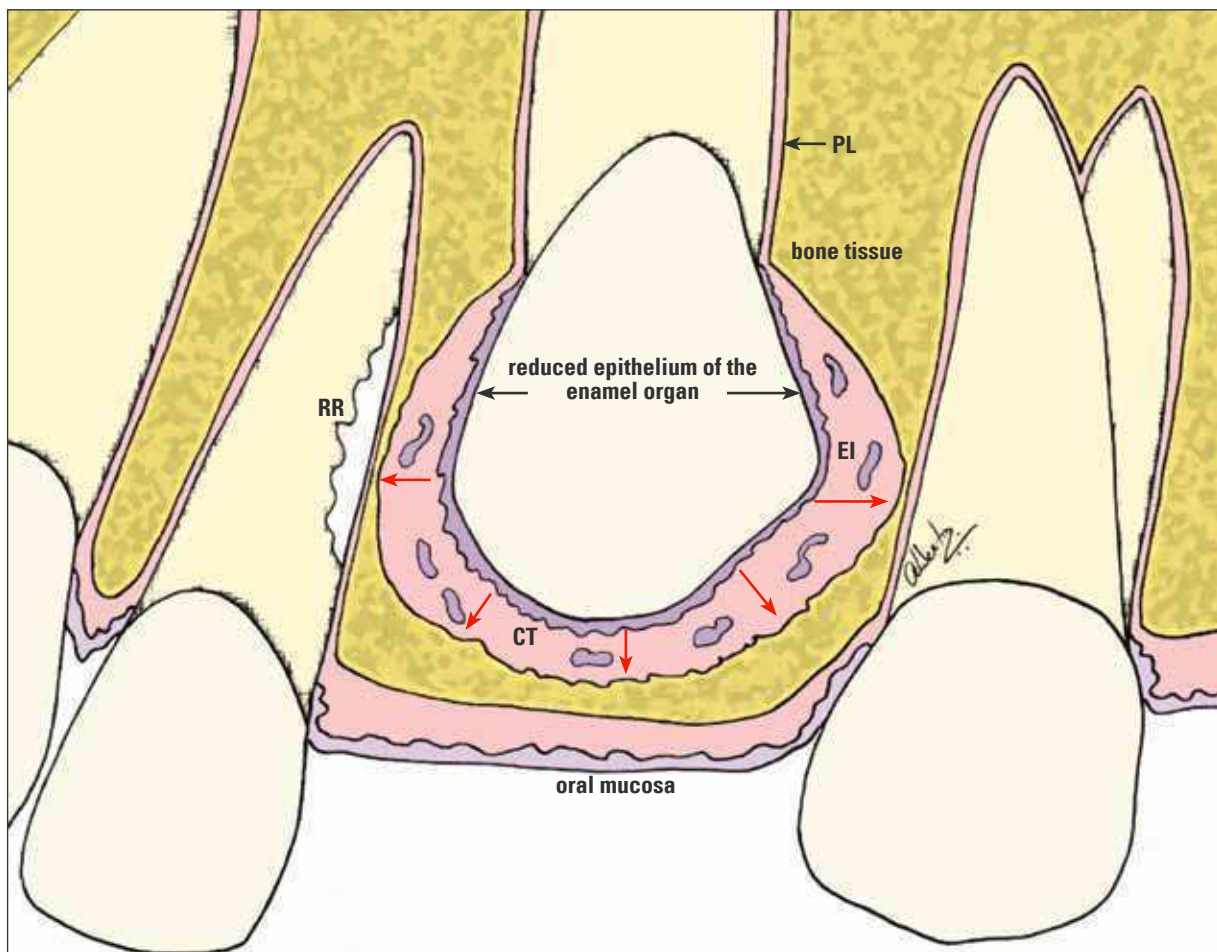


FIGURE 2 - Epithelial structures of the dental follicle—such as the reduced epithelium of the enamel organ and the epithelial islands/cords remnants of the dental lamina (EI)—constantly release epidermal growth factor (EGF, red arrows) in the connective tissue (CT). This mediator, along with other EGF-activated mediators, induces pericoronal bone resorption, an essential phenomenon in the occurrence of tooth eruption. When the path of an unerupted tooth compresses the vessels of the periodontal ligament (PL) of adjacent teeth—with or without orthodontic traction—cementoblasts die on the spot and the root is resorbed (RR) to give rise to the follicle and its moving crown.

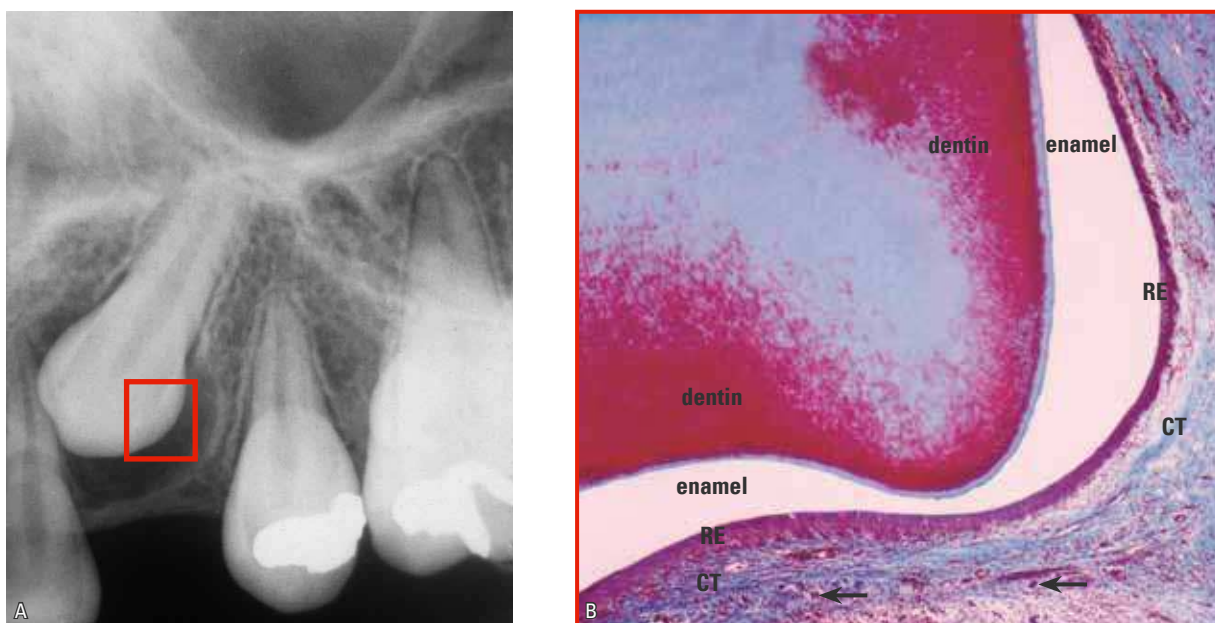


FIGURE 3 - The pericoronary space and dental follicle of upper canines are more laterally bulging due to the coronary anatomy, as shown in **A**. The reduced epithelium of the enamel organ (RE) is firmly adhered to the enamel of unerupted teeth, while the epithelial islands remnants of the dental lamina and gubernaculum cord (arrows) are distributed across the connective tissue (CT) of the dental follicle.

future mandible or maxilla. Soon thereafter, it is fragmented by apoptosis, but some of these cells persist on a scheduled basis. The remnants of dental lamina cells are organized in the form of islands and epithelial cords forming a veritable single row that rises from the reduced epithelium of the enamel organ toward the oral mucosa. This epithelial cord is called the gubernaculum dentis, or gubernaculum cord.

Once the tooth germs have become established and the dental lamina has undergone fragmentation, the neighboring mesenchyme gives rise to bone tissue. The tooth germs and the cord of epithelial islands remain unscathed as bone forms around them into the alveolar crypt. Around the gubernaculum cords, a delicate bony canal develops, called the gubernaculum canal.

The function of the gubernaculum canal and cord lies in directing the tooth—once the crown is fully developed—toward the occlusal-most region of the alveolar process. As the tooth erupts towards the mucosa, the dental follicle will incorporate the islands and cords of the epithelial

cells of the gubernaculum cord into its connective tissue, while increasing the presence of its epithelial component in this region (Fig 3).

### Development of the alveolar crypts and gubernaculum canal

The epithelial cells need to be in constant proliferation and synthesis given their constant desquamation in skin and mucosal linings and also because of its intense production of secretions such as milk, saliva and tears. This constant proliferation stimulus is provided by individual epithelial cells, which release to their neighbors—via specific receptors—what is called the Epidermal Growth Factor (EGF) mediator. Although bone cells have EGF receptors, in these cells EGF stimulates bone resorption. Other mediators have their action triggered by EGF (Fig 1), such as TGF-beta, which stimulates the formation of clasts, and CSF-1 and IL-1, which recruit their precursors.

The bone tissue is maintained at a distance from the epithelial tissues because the released EGF stimulates bone resorption, as occurs in the

case of the epithelial rests of Malassez, which maintain the periodontal space without allowing the bone to reach the surface of the tooth root.<sup>3</sup>

When bone is formed by the mesenchyme, the tooth germs are circumscribed. The alveolar crypts and the gubernacular canal are simultaneously established, since the tooth germs and gubernacular islands and cords are epithelial tissues that release EGF, which constantly stimulates bone resorption in the neighboring tissues.

The foregoing explanation allows us to assert that:

1. The follicle is an epithelial component comprised of (a) the reduced epithelium of the enamel organ, firmly adhered to the crown, and (b) the cords and islands of odontogenic cells derived from the dental lamina (Figs 2 and 3).
2. The connective tissue comprises the largest volume of follicles and, outside the pericoronal space, it takes on the form of a membrane and/or pouch.
3. The epithelial component continuously releases EGF and thus preserves the pericoronal space by stimulating bone resorption and thus keeping the bone away from the enamel (Fig 2).
4. The cascading release of EGF and other mediators is essential for the mechanism of tooth eruption. The forces derived from the development of teeth and growth vectors stimulate increased secretion of EGF and promote bone resorption, directing tooth eruption in the occlusal direction (Fig 2).

When a tooth root is experimentally removed<sup>1</sup> but the crown and dental follicle are preserved, the tooth will erupt normally. Likewise, the tooth will erupt when the crown is removed and the dental follicle and tooth root are left in its place. When metal or silicone replicas replace unerupted teeth but the follicle is preserved, the artificial teeth or replicas will still erupt. The dental follicle is an essential and

fundamental structure of tooth eruption, although for decades the tooth root was believed to be the essential structure in this process.

#### **Criteria for evaluating pericoronal space images: image, thickness, contour and boundaries**

The image of the pericoronal space (Figs 1, 3, 4 and 7) should:

- (a) Be homogeneously radiolucent, devoid of radiopaque points or radiolucent micro lodge type areas, as these may denote a source of odontogenic tumors.
- (b) Have its boundaries with the adjacent bone defined by a uniform and continuous radiopaque line. If this line is discontinued and/or riddled with images that resemble the gnawing of a mouse, it may represent a source of odontogenic cysts and tumors.
- (c) Have its contour characterized by uniform pericoronal space thickness, positioned symmetrically to the dental crown. When some areas grow thicker than others, in the form of embroidery and wavy contours, this may characterize a source of odontogenic cysts and tumors.
- (d) Have a thickness ranging from 1 mm to less than 5.6 mm.<sup>2,4</sup> Beyond these limits, one should suspect the presence of a dentigerous cyst or some other follicular disease.

In assessing the image of the pericoronal space, one should note that:

- 1) Diseases derived from the dental follicle can go unnoticed and may be present even when the pericoronal space displays normal apparent thickness.
- 2) Changes derived from the dental follicle take place only occasionally, and are percentage-wise very rare, considering the frequency of unerupted teeth in patients.

#### **The concept of pericoronal folliculopathies**

Any disease that originates from or is located exclusively in the structures of the dental

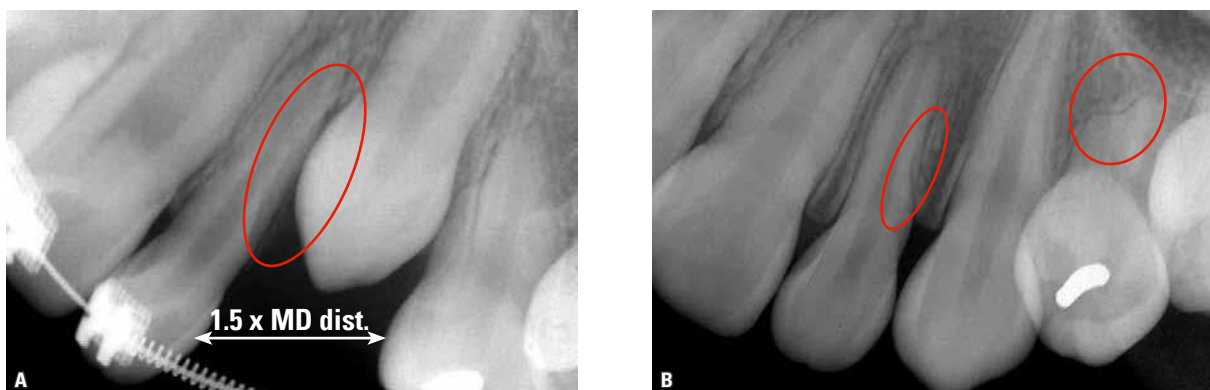


FIGURE 4 - Example of unerupted maxillary canine that did not reach the occlusal plane (A). Once the space in the dental arch reached 1.5 times the mesiodistal distance of the crown—to accommodate the bulging dental follicle typical of the maxillary canine—the tooth moved naturally to its place in the dental arch (B). But the existing proximity of the upper canine and its dental follicle caused lateral resorption (circles) in the roots of the lateral incisor and first premolar.

follicle can be termed pericoronal folliculopathy, namely:

- Acute and chronic pericoronaritis.
- Paradental cyst.
- Inflammatory follicular cyst.
- Dentigerous cyst (Fig 7).
- Eruption cyst.
- Hyperplastic dental follicle.

However, many other odontogenic cysts and tumors also originate from the dental follicle but are not exclusive to that structure or location. Odontogenic keratocysts, ameloblastomas, odontogenic fibroma, odontoma, etc. also originate from the dental follicle.

#### Pericoronal space of unerupted teeth and root resorption of adjacent teeth

The dental follicle is rich in mediators that stimulate bone resorption locally, especially EGF (Fig 2). When maxillary growth vectors and eruptive forces bring the crown of an unerupted tooth close to the root of an erupted tooth, there occur the compression of periodontal vessels and the death of cementoblasts that cover the surface, protecting it from resorption (Figs 5 and 6). Thus, the root surface will be exposed and the amount of local resorption

mediators will be increased, thereby stimulating the organization and function of bone modeling units (BMUs) (Fig 2).

From the standpoint of imaging, if an unerupted tooth is located very close to the root of another tooth and if the former's trajectory is active due to the eruption and the presence of growth vectors, resorption is usually induced (Figs 2, 4, 5 and 6). This scenario is very often found in the relationship between the region of the canines and the upper lateral incisors (Figs 4, 5 and 6), as well as between third molars and the distal surface of second molars.

Extraction of the unerupted tooth triggers process regression and re-covering of the resorbed area by new cementoblasts, with deposition of a new layer of cementoblasts and reattachment of periodontal fibers. This behavior often occurs with the lower third and second molars. Such occurrence will only take place if the environment is not contaminated by bacteria.

In cases of upper canines, orthodontic and/or orthopedic appliances redirect the eruptive path and/or also the growth vectors involved. Root resorption will cease in neighboring teeth, whereas the surface will be repaired by new cementoblasts and renewed cementum

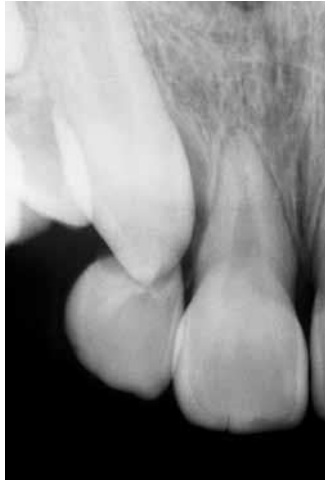

FIGURE 5 - In some cases, detection of the resorption caused by unerupted teeth—including maxillary canines—in adjacent teeth only occurs when it is already too late, as was the case of this upper lateral incisor. But sometimes, it can also involve the central incisors.

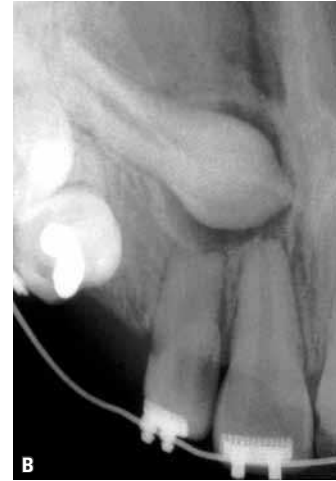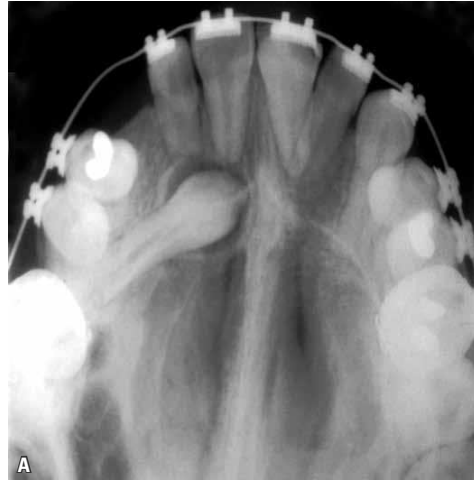


FIGURE 6 - Regardless of the region related to the proximity of the dental follicle of unerupted teeth, root resorption may occur provided that there is compression of periodontal vessels and death of cementoblasts. A comparison between right and left sides shows that the apical resorption is linked to the unerupted canine and not to the orthodontic movement. By moving an unerupted canine through orthodontic traction, whenever possible, the dental follicle is also moved away, which is usually sufficient to stop root resorption and repair the surface.

formation (Fig 4). This situation is often found in the relationship of canines with the upper lateral incisors.

A conduct that must necessarily be adopted to avert the resorption of teeth adjacent to the unerupted tooth—when such unerupted tooth is not being extracted but rather retracted orthodontically—lies in increasing dental arch space so that the unerupted tooth lodges in the area along with its crown and especially its follicle. The opening of space eliminates compression of the periodontal ligament of adjacent teeth while cementoblasts and cementum re-cover the roots of these teeth (Figs 4 and 6). Thus, the dental follicle of the erupted tooth remains farther away from the root surface so that its mediators no longer act as stimulators of resorption. Instead, they only stimulate pericoronal bone resorption to allow eruption to occur in the desired path.

### Size, thickness and shape of follicles in maxillary canines compared with other teeth

The thickness and shape of follicles allow their pericoronal spaces to have a more or less uniform contour of the incisal and occlusal surfaces with their cusps (Fig 1). However, the unique shape of upper canines—with their rather convex lateral surfaces forming a cusp, as it were, at their incisal edge, which ends in an acute angle—provides a very specific pericoronal space shape (Fig 3).

The dental follicle of maxillary canines appears to bulge and widen laterally, more so than the other teeth (Figs 3 and 6). Radiographic images and Computed Tomography (CT) scans clearly show that the lateral thickness of the pericoronal spaces of upper canines is greater than in other teeth, especially if compared with incisors, and even with premolars.

The dental follicle of the upper canines and their resulting pericoronal spaces are so bulging

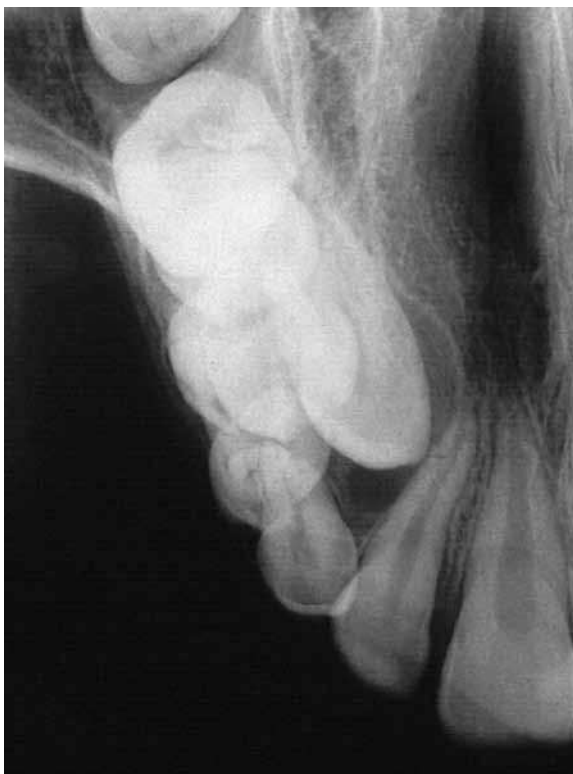

FIGURE 7 - The image of the pericoronar space of the maxillary canine reveals that the criteria adopted for classifying a follicle as normal no longer apply. From a strictly radiographic point of view, the image is not homogeneously radiolucent and its contour and thickness are not uniform, suggesting that it is actually a dentigerous cyst in its early development phase. This scenario does not preclude the use of orthodontic traction, if necessary.

in some cases that added to all the probable image distortion, deciding between a diagnosis of normality or incipient dentigerous cyst poses a challenge (Figs 3, 6 and 7).

In assessing the need to whether or not open the space between upper lateral incisors and premolars to allow upper canines to naturally lodge in the upper arch, this lateral bulging of their pericoronar space should be considered.

This consideration should be emphasized because the dental follicle does not represent only a soft tissue that covers the crown and could be easily compressed under traction, but rather

because it is the tissue or organ responsible for tooth eruption. Thanks to its large number of mediators, the dental follicle stimulates pericoronar bone resorption, actively producing tooth movement in the occlusal direction (Figs 2, 3 and 4).

The follicle is composed of soft tissues and although it can be physically compressed between the canine crown and the roots of the lateral incisors and premolars, this maneuver during traction may impose a biological cost. Resorption of these lateral roots cause, to a lesser or greater degree, structural impairment (Fig 4). Compression of the dental follicle of maxillary canines occurs in conjunction with compression of vessels of the periodontal ligament of adjacent teeth and eventual death of cementoblasts that protect those roots from clasts and other BMU components.

In following the clinical guidelines to determine how much space must be provided to enable unerupted upper canine traction, professionals are encouraged to calculate the mesiodistal distance of the crown and multiply that measurement by 1.5. This action will ensure greater integrity of the lateral roots of adjacent teeth (Fig 4).

One should be aware, however, that creating this space is not clinically possible in all cases. Using any measurement lower than the one aforementioned may result in highly successful traction, with no damage to lateral incisors and premolars, but the risks are greater. The exactness of mathematics cannot always be systematically applied in making biological decisions. The recommended criterion and measurement serve as a starting point for decision making relevant to each case. In cases where it can be applied fully, assurance regarding the preservation of neighboring roots will certainly increase.

In assessing the damage caused by root resorption in maxillary lateral incisors due to the proximity of unerupted canines, it seems appropriate to cite the literature.<sup>5,6</sup> The presence

of root resorption was found in the periapical radiographs of 3,000 patients between 10 and 15 years of age.<sup>5</sup> In fact, 12.5% of their lateral incisors were located close to canines that had remained unerupted for longer than normal. The same cases were evaluated using tomographic sections and reconstructions, and disclosed 25% impairment. CT is the best method to accurately assess the damage caused by canine traction to the roots of upper lateral incisors.

### Dental follicle development and functions

In its early stages, the enamel organ resembles a bell and is lined by what are known as the inner and outer epithelia. Between these epithelia there are two other thicker layers of epithelial cells, which are known as stellate reticulum and intermediate stratum. As the enamel organ forms this mineralized tissue on the inside of the bell, it becomes narrower or thinner and the four epithelial layers will flatten to form a single epithelium that is firmly adhered to the enamel surface and receives the name of reduced epithelium of the enamel organ (Figs 2 and 3).

The reduced epithelium of the enamel organ and, as a result, the dental follicle, have the following main functions:

- a) "Hide" or protect enamel resorption by clastic cells (Fig 3).
- b) Prevent the bone from developing directly on the enamel surface.
- c) Support tooth eruption by releasing mediators that are typical of epithelia, such as EGF. The reduced epithelium of the enamel organ and odontogenic epithelial islands and cords are actively involved in pericoronal bone resorption, essential if tooth eruption is to follow a path that leads to the alveolar mucosal surface, thanks to the release of EGF (Fig 2).
- d) Constitute the primary junctional epithelium by merging with the oral mucosa, and allow teeth to erupt in the oral environment without exposing the internal environment of the body,

represented by the gingival connective tissue, to the highly contaminated oral environment.

### Final considerations

Root resorption of upper lateral incisors and premolars (Figs 4, 5 and 6) is among the possible consequences of unerupted upper canine traction. In planning treatment of unerupted canines, one is advised to assess the thickness of the dental follicle, bearing it in mind when creating space to accommodate it in the dental arch. The aim here is to seek either normal canine eruption or orthodontic traction of said teeth. The lateral compression of the dental follicle during eruption—with or without canine traction—against the roots of the lateral incisors and/or premolars may cause these teeth to resorb, as a result of the compression of periodontal vessels and the death of cementoblasts.

In planning the space to be obtained in the dental arch to ensure that the unerupted tooth fits properly, it must be assumed that the dental follicle of maxillary canines—given their unique anatomy—tend to bulge and broaden laterally, more than any other teeth.

The amount of space in the dental arch that would offer the least risk of root resorption for adjacent teeth during orthodontic traction is equivalent to 1.5 times the mesiodistal distance of upper canines, although this measure is not always amenable to application in all clinical cases.

In forthcoming studies, we will discuss the other possible consequences of orthodontic traction of unerupted teeth, especially canines, among which the following are noteworthy: (1) External cervical resorption in canines under traction, (2) Alveolodental ankylosis of canines, (3) Calcific metamorphosis of the dental pulp and aseptic pulp necrosis.

This approach is aimed at preventing the possible consequences of orthodontic traction, which could be entirely avoided if certain technical precautions are adopted.



---

## REFERENCES

1. Cahill DR, Marks SC Jr. Tooth eruption: evidence for the central role of the dental follicle. *J Oral Pathol.* 1980 Jul;9(4):189-200.
2. Consolaro A. Caracterização microscópica de folículos pericoronários de dentes não irrompidos e parcialmente irrompidos. Sua relação com a idade. [tese]. Bauru (SP): Universidade de São Paulo; 1987.
3. Consolaro A, Consolaro MFMO, Santamaria M Jr. A anquilose não é induzida pelo movimento ortodôntico. Os restos epiteliais de Malassez na fisiologia periodontal. *Rev Clin Ortod Dental Press.* 2010 abr-maio;9(2):101-10.
4. Damante JH. Estudo dos folículos pericoronários de dentes não irrompidos e parcialmente irrompidos. Inter-relação clínica, radiográfica e microscópica. [tese]. Bauru (SP): Universidade de São Paulo; 1987.
5. Ericson S, Kuroi J. Radiographic examination of ectopically erupting maxillary canines. *Am J Orthod Dentofacial Orthop.* 1987 Jun;91(6):483-92.
6. Otto RL. Early and unusual incisor resorption due to impacted maxillary canines. *Am J Orthod Dentofacial Orthop.* 2003 Oct;124(4):446-9.

---

**Contact address**  
Alberto Consolaro  
E-mail: consolaro@uol.com.br