

# Study of the cephalometric features of Brazilian long face adolescents

Omar Gabriel da Silva Filho\*\*, Gleisieli C. Petelinkar Baessa Cardoso\*\*\*, Maurício Cardoso\*\*\*\*, Leopoldino Capelozza Filho\*\*\*\*\*

## Abstract

**Objective:** To set skeletal and dental cephalometric values for Brazilian long face adolescents. **Methods:** The sample comprised lateral cephalograms of 30 long face patients, 17 females and 13 males, and 30 Pattern I adolescent patients, 15 males and 15 females, with permanent dentition. The features that characterize the long face pattern were defined clinically by facial analysis. The following cephalometric measurements were assessed: 1) Sagittal behavior of the apical bases (SNA, SNB, ANB, NAP, Co-A, Co-Gn), 2) Vertical behavior of the apical bases (SN.PP, SN.MP, gonial angle, TAFH, LAFH, MAFH, PFH, TAFHperp, LAFHperp), 3) Dentoalveolar behavior (1-PP, 6-PP, 1-MP, 6-MP, 1.PP, IMPA), and 4) Facial height ratios (LAFHPerp/TAFHPerp, LAFH/TAFH, MAFH/LAFH). **Results and Conclusions:** The vertical error of the long face pattern is concentrated in the lower third. The maxilla exhibits a greater dentoalveolar height and the mandible, given its more vertical morphology, displays greater clockwise rotation. These morphological and spatial features entail sagittal and vertical skeletal changes as well as vertical dentoalveolar changes. The angles of facial convexity are increased in the sagittal direction. Vertically, the total and lower anterior facial heights are increased. The dentoalveolar component is longer.

**Keywords:** Face. Adolescent. Cranial circumference.

\* Access [www.dentalpress.com.br/journal](http://www.dentalpress.com.br/journal) to read the full article.

\*\* MSc - Orthodontist, Hospital for Rehabilitation of Craniofacial Anomalies, University of São Paulo.

\*\*\* Dentistry Graduate - Resident, Department of Corrective Orthodontics, Hospital for Rehabilitation of Craniofacial Anomalies, University of São Paulo (HRAC/USP), Bauru/SP.

\*\*\*\* PhD in Dentistry, Júlio de Mesquita Filho São Paulo State University (UNESP), Araçatuba/SP. Professor of the specialization course in Orthodontics, Sacred Heart University (USC), Bauru/SP.

\*\*\*\*\* PhD in Oral Rehabilitation, area of Periodontics, School of Dentistry of Bauru, São Paulo University (FOB/USP), Bauru/SP. Coordinator of the Specialization Course in Orthodontics, Society for the Social Promotion of Cleft Lip and Palate Patients (PROFIS), Bauru/SP.

### Editor's summary

Excessively vertical faces are referred to as “long faces” and their features reflect a disparity between facial thirds, whereby the lower third is increased, resulting in no passive lip seal, overexposed maxillary incisors at rest, gingival exposure on smiling and double chin in an attempt to seal the lips (Fig 1). As is the case with other frontal errors, long faces cannot be corrected by orthodontics and/or orthopedics alone. Patients and therapists share identical perception of this issue. Orthodontists are therefore aware of the vital role played by orthognathic surgery in reducing the vertical excess that characterizes this facial pattern. Two morphological criteria lead to the indication of orthognathic surgery for long face reduction, i.e., compromised facial aesthetics and inability to treat the existing malocclusion. This research aimed to put into perspective the cephalometric characteristics of the long face pattern in adolescence.

Pretreatment lateral cephalograms of Caucasian patients of both genders were selected, with permanent dentition and excessively vertical faces. Excessive verticality was diagnosed by the presence of incompetent lip seal and exposure of upper incisors with the upper lip at rest, as seen in facial photographs. The control group consisted of pretreatment lateral cephalograms of Caucasian Pattern I

patients of both genders, with permanent dentition.

The maxilla behaved similarly in both the long face and Pattern I groups, regardless of gender. The position of the mandible relative to the cranial base (SNB) exhibited greater retrusion among long face subjects. Facial convexity of long face subjects was reduced. Mandibular angles (gonial angle and mandibular plane angle) were increased in long face subjects while the palatal plane was identical in both facial patterns. Total facial height and lower facial height tended to be higher in long face subjects. Dental arch heights were increased among female long face subjects. Maxillary incisors also behaved identically in long face and Pattern I subjects whereas mandibular incisors were more proclined in long face subjects.

It was concluded that in the long face pattern group the maxilla exhibits a greater dentoalveolar height and the mandible, given its more vertical morphology, shows greater clockwise rotation. These morphological and spatial features entail sagittal and vertical skeletal changes as well as vertical dentoalveolar changes. In the sagittal direction, facial convexity angles are increased due to a posterior displacement of point “B”. Vertically, the total and lower anterior facial heights are increased. The dentoalveolar component is longer.

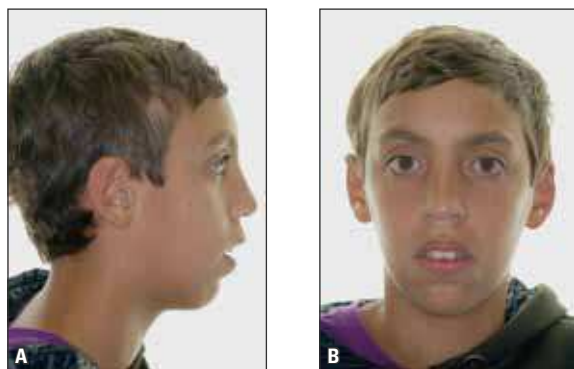


FIGURE 1 - Features of the long face pattern. **A)** In lateral view, the rotation of the mandible downwards and backwards may favor the diagnosis of mandibular deficiency. **B)** In frontal view the diagnosis is unmistakable: a disproportion between the facial thirds, with a disproportionate increase of the lower third, compromises lip seal competence and exposes the upper incisors at rest.

### Questions to the authors

#### 1) What is the essence of morphological changes in long face patients?

Firstly, long face diagnosis is based on the clinical evaluation of the face, that is, facial analysis. Long faces present with a skeletal discrepancy characterized by vertical excess in the lower third of the face in both front and side view. Although facial analysis is subjective in nature and vertical excess features a wide range of individual degrees of severity, it is not difficult to identify vertical excess in the lower third of the face, since its clinical consequences can be perceived by both orthodontists and patients.

The changes caused by vertical excess in the lower third of the face are: Lip seal incompetence; presence of double chin in an attempt to preserve lip seal, in which case lip seal is forced; excessive exposure of the upper incisors at rest; and gummy smile. This article was designed to cephalometrically establish the numerical errors which are responsible for these morphological changes in Caucasian adolescents since these cephalometric features have already been defined in adults. Interpretation of cephalometric measurements in adolescents allowed us to conclude that the vertical error in the long face is concentrated in the lower third of the face (LAFH). Cephalometric measurements were consistent with the morphological and clinical diagnosis of the face. The maxilla exhibits greater dentoalveolar height and the mandible, given its more vertical morphology, displays greater clockwise rotation. These morphological and spatial features entail sagittal and vertical skeletal changes as well as vertical dentoalveolar changes. The angles of facial convexity are increased in the sagittal direction. Vertically, the total and lower anterior facial heights are increased. The dentoalveolar component is longer and the symphysis appears narrower.

## 2) What motivated you to study the cephalometric characteristics of these patients?

The desire to evaluate the cephalometric features of the long face pattern in adolescent males and females arose from previous studies of adult long face patients, also conducted in Bauru, São Paulo State, Brazil. The idea was to repeat these cephalometric studies in a younger age group during the growth period of adolescence. Our expectation was to determine whether the numerical characteristics of the face change from adolescence to adulthood, or whether these characteristics would be present even before skeletal maturity. The results suggest that if you have a long face pattern, you will always be a long face. The cephalometric characteristics of the long face pattern are already present in adolescent boys and girls before skeletal maturity.

## 3) Is there a link between long face pattern and mouth breathing?

Long face pattern and mouth breathing are different problems. We could say that the long face pattern refers to a morphological condition of the facial skeleton and reflects a predominantly vertical facial growth. On the other hand, mouth breathing refers to some obstruction in the nasal respiratory tract that reduces the permeability of the upper airways, forcing the individual to supplement the airflow through the mouth. Given these different situations, one is a morphological condition and the other is a functional condition, diagnosis also involves different professionals and instruments. The diagnosis of mouth breathing should be made instrumentally by an otorhinolaryngologist. However, these conditions may overlap in a single patient. Long face morphology is likely to reduce nasal airway patency. For example, the morphological configuration of the long face pattern is also narrower and shallower. The design of the respiratory tract with this type of bone architecture would be more vulnerable to soft tissue obstructions along the respiratory tract. This should explain, for example, why mouth breathers tend to have a long face pattern. The cause/effect relationship in this case is determined by the morphology of the face and the individual's breathing. The long face pattern promotes oral breathing. Orthodontists are therefore more often concerned with the airways of long face patients. When mouth breathing is confirmed in a long face individual, the obstructions that reduce airway patency should be eliminated. However, a patent airway will not guarantee any changes in facial morphology.

### Contact address

Omar Gabriel da Silva Filho  
Rua Rio Branco, 20-81 – Altos da Cidade  
CEP: 17.014-037 – Bauru / SP, Brazil  
E-mail: ortoface@travenet.com.br