

# Non-neoplastic proliferative gingival processes in patients undergoing orthodontic treatment

Irineu Gregnanin Pedron\*, Estevam Rubens Utumi\*\*, Ângelo Rafael Calábria Tancredi\*\*\*, Flávio Eduardo Guillin Perez\*\*\*\*, Gilberto Marcucci\*\*\*\*\*

## Abstract

**Introduction:** Orthodontic appliances render oral hygiene difficult and may contribute to the development of gingival lesions such as non-neoplastic proliferative gingival processes. These lesions, depending on such factors as development time, histopathological components and oral conditions may be reversible in some cases, through oral hygiene advice and basic periodontal therapy. In most cases, however, surgical treatment is required. **Objectives:** The purpose of this paper is to report the case of a patient using fixed orthodontic appliance who presented with two distinct gingival lesions diagnosed as pyogenic granuloma and inflammatory gingival hyperplasia. The clinical and histopathological features, incidence and frequency, treatment modalities and prevention of both lesions were discussed, highlighting the importance of submitting the material collected from the lesions to histopathological examination given the possibility of different diagnostic hypotheses. Surgical excision was performed on both lesions. The upper arch lesion, diagnosed as pyogenic granuloma, relapsed, which led us to provide basic periodontal therapy and repeat the surgical procedures. **Results:** The lesion in the lower arch, diagnosed as gingival hyperplasia, was surgically removed and followed up clinically, whereas the patient was instructed to perform proper oral hygiene.

**Keywords:** Pyogenic granuloma. Gingival hyperplasia. Periodontal diseases. Orthodontics. Gingiva.

## INTRODUCTION

The effects of fixed and removable orthodontic appliances on the periodontium have been widely investigated. Orthodontic appliances usually hinder proper oral hygiene, contributing to the development of gingival inflammation,

more evident in children, adolescents and young adults. This situation is exacerbated when a patient already presents with periodontal changes and, especially, if they are not undergoing periodontal maintenance and, as a result, become a patient at risk.<sup>1,15</sup>

\* Specialist in Periodontics and MSc in Dental Sciences (Area of concentration: General Dentistry), School of Dentistry, University of São Paulo. Lieutenant, Brazilian Air Force Dentist - Brazilian Air Force Hospital of São Paulo (HASP).

\*\* Specialist in Oromaxillofacial Surgery and Traumatology. MSc in Dental Sciences (Area of concentration General Dentistry), School of Dentistry, University of São Paulo. Lieutenant, Brazilian Air Force Dentist - Brazilian Air Force Hospital of São Paulo (HASP).

\*\*\* Specialist in Stomatology. MSc in Oral Diagnosis (subarea: Semiology), School of Dentistry, University of São Paulo.

\*\*\*\* Professor and PhD, Discipline of General Dentistry, School of Dentistry, University of São Paulo.

\*\*\*\*\* Head Professor, Discipline of Oral Diagnosis (subarea: Semiology), School of Dentistry, University of São Paulo.

Gingival hyperplastic and inflammatory responses during orthodontic treatment are common and can lead to complications that require periodontal therapy.<sup>1,5,15</sup>

Pyogenic granuloma and inflammatory gingival hyperplasia are tissue growths of inflammatory origin with varying degrees of granular and fibrous inflammatory tissues, possibly caused by low intensity chronic irritation.<sup>2,9,11,12</sup>

Both occur frequently in clinical dentistry and are clinically characterized by exophytic, sessile or pedunculated tissue growths, of pale pink to erythematous color, which may manifest ulceration and spontaneous bleeding.<sup>3,6,7,11,12,17-20</sup> They are most prevalent in the female gender during the second decade of life, possibly due to vascular effects exerted by feminine hormones.<sup>9</sup> Treatment often consists of surgical excision associated with the removal of local irritating factors.<sup>2-7</sup> However, recognition and identification of these factors are not always possible and the recurrence rate of lesions is relatively high.<sup>12,17</sup>

The purpose of this study was to report the case of a patient using fixed orthodontic appliance who presented with two distinct lesions—pyogenic granuloma and inflammatory gingival hyperplasia. The development of these conditions

is related to chronic low intensity trauma. We encourage orthodontists and dentists to routinely submit any material collected from the lesions to histopathological examination after surgery.

## CASE REPORT

Black female patient, aged 20 years, after 6 months of orthodontic treatment presented to our private clinic complaining of gingival changes.

On examination, a tumor-like lesion was observed, of erythematous color, irregularly shaped, with a smooth surface and pedunculated base, located in an edentulous region between teeth 23 and 25, under occlusion trauma. The condition had been developing for a week, starting with a node in the aforesaid region. The diagnostic hypotheses were pyogenic granuloma, gingival hyperplasia and peripheral giant cell lesion (Fig 1). Tooth 24 had been extracted 4 months earlier with no history of postoperative complication. The other lesion was observed between teeth 41 and 42. It was characterized by moderate gingival enlargement, pale pink in color, sessile base, smooth surface extending from the papilla to the brackets. The hypothetical diagnosis was inflammatory gingival hyperplasia (Fig 2). Radiographs of the lesions yielded no significant findings.

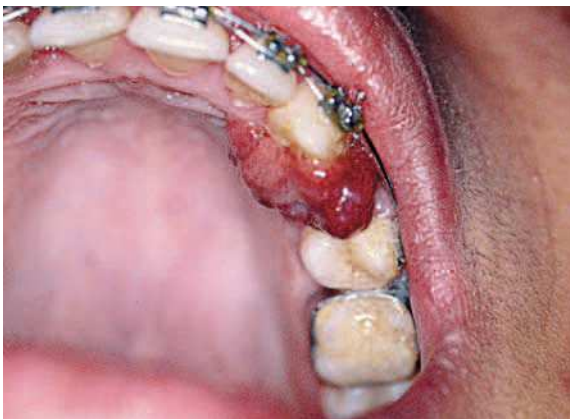

FIGURE 1 - Erythematous tumor mass with heavy bleeding to the touch, resembling pyogenic granuloma.

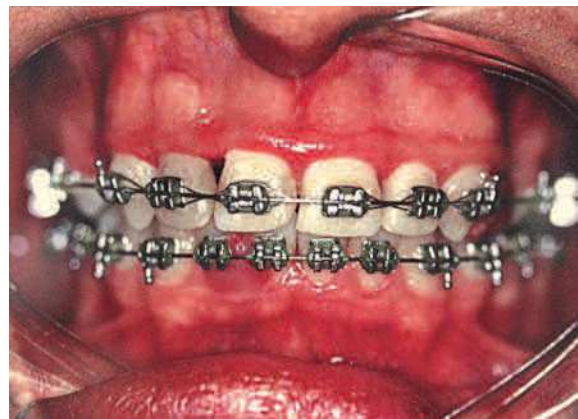

FIGURE 2 - Hyperplastic lesion between teeth 42 and 43 stemming from the keratinized gingiva and indicative of inflammatory gingival hyperplasia.

Under local anesthesia, excisional biopsy of the lesion was performed in tooth 24 region by incising it by the pedicle, from which a wedge was removed as a safety measure and tissue was removed from the edentulous area. The region was sutured and surgical cement added and maintained for 7 days, aided by the orthodontic appliance. The removed part was fixed in 10% formalin and submitted for laboratory analysis. Histopathological examination showed fragments of mucosa lined by parakeratinized stratified squamous epithelium exhibiting areas of spongiosis and acanthosis, and an ulceration area covered with fibrin-haemorrhagic exudate and bacterial colonies. In the lamina propria—permeating the dense connective tissue—we observed the proliferation of endothelial cells delimiting sometimes congested vascular spaces. There was exuberant hemorrhagic exudate and intense mononuclear and polymorphonuclear inflammatory infiltration in the ulceration areas. The histopathological diagnosis was pyogenic granuloma (Fig 3). In the same consultation excisional biopsy of the lesion in the region of teeth 41 and 42 was performed, and the removed piece was

also prepared and treated histologically. Light microscopy disclosed fragments of mucosa lined by parakeratinized stratified squamous epithelium, showing acanthosis, exocytosis and hyperparakeratosis. In surface areas there were fibrin-hemorrhagic exudate and bacterial colonies. In the lamina propria we observed intense deposition of collagen fibers forming a dense stroma that sustained intense chronic inflammatory infiltrate. Finally, there were also numerous vascular spaces and areas of hemorrhagic exudate. The histopathological diagnosis was inflammatory gingival hyperplasia (Fig 4).

After a postoperative period of 7 days the surgical cement and remaining sutures were removed. The patient was evaluated after 20 days, showing satisfactory repair of the region between teeth 41 and 42 (Fig 5). However, there was recurrence of pyogenic granuloma. Periodontal treatment was then performed and once again excision, submitting the lesion to the same laboratory, which confirmed the diagnosis of pyogenic granuloma. Repair was satisfactory with no signs of relapse (Fig 6). After four years of treatment, the patient is still being monitored and exhibits no signs of recurrence.

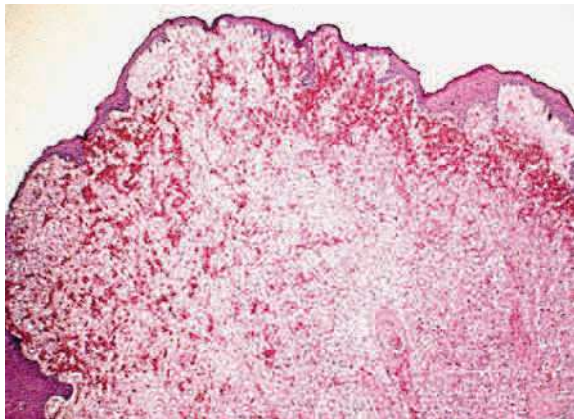


FIGURE 3 - Histological section of pyogenic granuloma (original color: HE; smaller magnification).

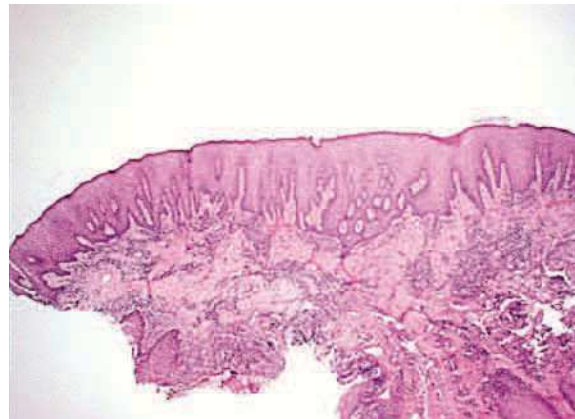

FIGURE 4 - Histological section of inflammatory gingival hyperplasia (original color: HE; smaller magnification).

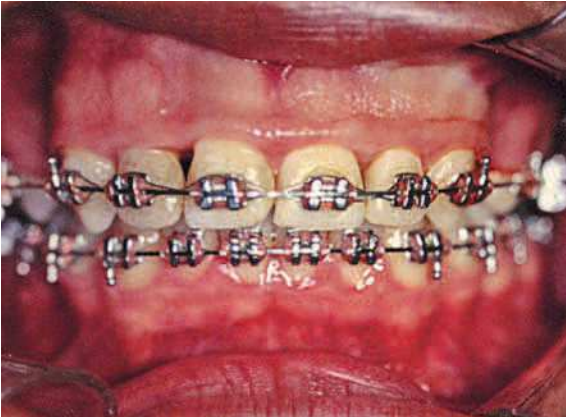


FIGURE 5 - Postsurgical view after 20 days showing satisfactory repair in the region between 41 and 42 teeth.

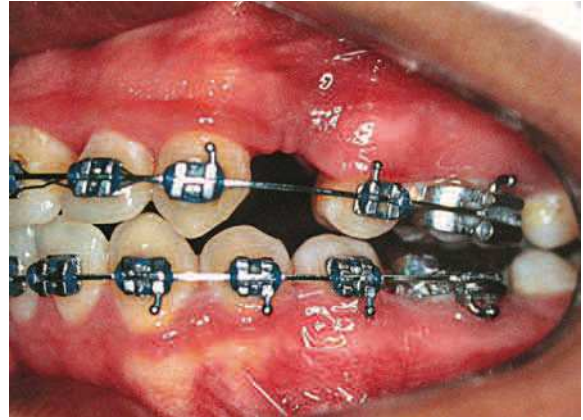


FIGURE 6 - Satisfactory repair with no signs of recurrence after periodontal treatment and second surgical procedure.

## DISCUSSION

Among the most frequent gingival proliferative processes are inflammatory gingival hyperplasia and pyogenic granuloma. Peripheral fibroma, peripheral giant cell lesions and gingival hyperplasia are also part of this group, although not as common.<sup>4</sup>

In order to facilitate lesion exposure the discussion was divided into topics.

### Etiopathogenesis

Etiopathogenesis of both lesions is usually related to chronic low intensity trauma, producing in most cases gingival inflammation and infection (periodontal diseases) caused by difficulty in removing biofilm in patients wearing an orthodontic appliance, which translate into traumatic injuries and hormonal factors.<sup>1,4,6,9</sup> The physical set-up (brackets and bands that could invade the periodontium's biological space) and mechanical set-up (forces delivered by orthodontic and / or orthopedic movement), associated with biofilm, were reported as hypotheses to explain the etiopathogenesis of gingival hyperplasia.<sup>1,9</sup> And so was trauma during placement of the orthodontic appliance, which

causes pressure areas that result in epithelium thickening, connective tissue proliferation and an increased amount of tissue. The possible allergic process triggered by the acrylic resin monomer placed on the base of the removable orthodontic appliances, when associated with the presence of fungi (*Candida albicans*) may also cause a slight increase in plaque and gingival indices. The possibility of an unusual host response against the local irritant (biofilm), exacerbated by the patients' hormonal changes (puberty and menstruation) was also reported.<sup>1</sup>

Local irritants such as excessive restorations and neonatal teeth combined with poor oral hygiene, plaque and dental calculus were also considered in the etiopathogenesis.<sup>2,3,6,7,11,12,17,18,19</sup> Hormonal changes such as menarche, use of oral contraceptives and pregnancy were also reported. During gestation, lesions usually arise in the 2<sup>nd</sup> or 3<sup>rd</sup> quarters, but tend to regress thereafter.<sup>2,6,11,13,19</sup>

Increased levels of progesterone and estrogen produce dilatation and proliferation of gingival microvasculature and destruction of mast cells, which result in an increased release of vasoactive substances in the adjacent tissue, inducing

the formation of pyogenic granuloma.<sup>17</sup> A decrease in keratinization of the epithelium of the attached gingiva, rendering it more vulnerable to trauma and triggering a tendency towards growth of vascular tumors in the gingiva and alveolar mucosa has also been reported. The development of pyogenic granuloma depends on factors such as sufficient amount of tissue, degree of gingival inflammation, degree of vulnerability to trauma, presence of teeth and dentures, and level of oral hygiene. Low intensity tissue trauma could facilitate the invasion of nonspecific low virulence saprophytic microorganisms, causing a tissue response characterized by excessive proliferation of vascular-type connective tissue.<sup>3</sup>

### Clinical Features

Non-neoplastic proliferative processes are generally characterized by gingival tissue growth, either well defined, such as nodules, or diffuse, like tissue masses; fibrous or flaccid texture (resilient); variable symptoms and ranging from pink to erythematous color; sessile or pedunculated base; usually bleeding to touch; loss of the “orange peel” look on the surface.<sup>1,2,4,5</sup> Gingival growth stems from the interdental papilla and expands to the marginal gingiva.<sup>1,2,4,5,13</sup> Although they have a predilection for the gingiva, they can be found in extraggingival regions with various clinical features that often mimic malignant lesions.<sup>10</sup> Pyogenic granuloma, in particular, differs from inflammatory gingival hyperplasia because it is characterized by well circumscribed papular, nodular or tumoral exophytic soft tissue; erythematous to brownish in color, depending on the maturity of the lesion; hemorrhagic aspect and a bleeding tendency; smooth or lobulated surface; soft and resilient texture when young, and more fibrous when mature due to obliteration of the capillaries; rapid growth; may cause bone resorption. It may be covered with a pus-filled membrane

due to trauma, hence the name of the lesion, despite the absence of a relationship between suppuration and pathological entity. It varies in size from a few millimeters to a few centimeters and as it grows increasingly larger it can interfere with physiological activities in the oral cavity.<sup>2,3,6-8,11,12,17-22</sup>

Both lesions may present with an ulcerated surface under occlusion trauma.<sup>1,2,4,5,13</sup>

There was no incidence of inflammatory gingival hyperplasia. Pyogenic granuloma is more common in the gingiva, in the anterior maxilla. It affects adolescents and young adults, with 60% incidence at ages 11-40 years and no race predilection. Women are two to four times more affected than men.<sup>2,3,6,7,11,12,17-20</sup> Studies have confirmed the incidence of pyogenic granulomas in young adults.<sup>19,21,22</sup>

### Histopathological Features

The histological picture of inflammatory gingival hyperplasia is characterized by parakeratinized stratified squamous epithelium issuing long, thin projections towards the connective tissue. The lamina propria is made up of dense, well cellularized and collagenized connective tissue permeated by an intense mononuclear inflammatory infiltrate,<sup>1</sup> as shown in Figure 4.

Regarded as an inflammatory reaction process with exuberant proliferation of fibrovascular tissue, the histopathological pattern of pyogenic granuloma is composed of ulcerated stratified squamous epithelium similar to granulation tissue with numerous capillaries, lined by endotheliocytes. Other features include fibrinous exudate, inflammatory infiltrate cells (lymphocytes, plasma cells, histiocytes, and neutrophils) and fibroblasts.<sup>2,3,6,7,11,12,17,18</sup> The possibility of invasion by non-specific microorganisms has been reported.<sup>3,7</sup> There is no histopathological distinction between pyogenic granuloma and granuloma gravidarum, except for certain inherent etiopathogenetic conditions.<sup>17,18</sup>

## Differential Diagnosis

Among the lesions that make up the differential diagnosis are peripheral ossifying fibroma, peripheral giant cell lesions and inflammatory gingival hyperplasia.<sup>2,4</sup>

Particularly in the case of pyogenic granuloma, given its clinical aspects and marked vascularization, the differential diagnosis comprises hemangioma, lymphoma, nevus flammeus, Kaposi's sarcoma, metastatic tumor, parulis, hemangioendothelioma, hemangiopericytoma, leiomyoma, cytomegalovirus infection and gingival lesions by bacilli.<sup>3,11,19</sup>

Hemangioma is an important differential diagnosis since some smaller lesions may be indistinguishable<sup>9</sup>. Dyscopia tests are used in case of suspected vascular lesions. Inflammatory fibrous hyperplasia should also be considered as a differential diagnosis of pyogenic granuloma.

Given the breadth of the differential diagnosis, a histopathological examination was suggested as a means to verify and clarify the diagnosis of gingival lesions.<sup>7,8</sup>

## Treatment

Surgical excision has usually been the treatment of choice for both lesions.<sup>1-3,12,16-19</sup>. However, some changes have been suggested, such as curettage,<sup>1,2,7</sup> gingivectomy or gingivoplasty techniques.<sup>2,3,7</sup> The latter is determined by the amount of attached gingiva.<sup>6</sup> Barack et al<sup>1</sup> cited the need for flap procedure (modified Widman technique) in the presence of periodontal pocket with attachment loss. Other modalities have been recommended. Surgical removal using laser (CO<sub>2</sub> or Nd:YAG) has been proposed.<sup>3,4,12,14</sup> The advantages of laser use in these procedures are: Enhanced hemostasis with better visualization of the surgical field, less discomfort or pain, reducing the need for postoperative medication; satisfactory tissue healing, improved patient acceptance, fewer anesthetics, and reduction of postoperative bacteremia in the surgical site.<sup>4</sup>

Cryosurgery was cited in the treatment of pyogenic granuloma.<sup>6</sup> Silverstein et al<sup>13</sup> performed free gingival graft for root coverage and keratinized gingiva loss resulting from surgical excision of pyogenic granuloma. The use of chlorhexidine mouthwashes pre and post-surgically have prevented potential post-surgical infection and inflammation.<sup>11,17</sup> The removal of the base of the lesion in order to avoid recurrence has been recommended.<sup>1,7,16</sup> For cases of pyogenic granuloma, the clinical follow-up and supervision of oral hygiene during pregnancy is recommended if the lesion is small, asymptomatic and not bleeding.<sup>17,18</sup>

The need for removal of causative factors through basic periodontal treatment (scraping sessions, coronoradicular smoothing and polishing and oral hygiene advice) has been advocated.<sup>1-4,6,7,17,18</sup> It is suggested that periodontal treatment be performed prior to surgery in view of a milder inflammatory process and surgery procedure, reducing heavy bleeding and decreasing the chance of recurrence.

## Prognosis

It would be timely to make some considerations regarding the monitoring of gingival lesions in orthodontic patients. Orthodontists should use appropriate orthodontic components that do not put the periodontium at risk. Periodontal changes should be diagnosed and treated as early as possible in order to control periodontal disease (periodontal treatment and reinforcement of basic oral hygiene).<sup>1</sup>

The monitoring of pyogenic granuloma has been cited as showing no relapse within a 6-24 month period.<sup>17,18</sup> Recurrence was related to the non-removal of local irritating factors and the partial removal of the lesion<sup>12,17</sup> and was estimated at around 14-16%.<sup>7</sup> In this study, recurrence was possibly related to a pre-existing periodontal disease. There are reports of increasing recurrence during pregnancy.<sup>2</sup>

## CONCLUSIONS

In view of the foregoing, we may conclude that:

1. Pyogenic granuloma and inflammatory gingival hyperplasia usually exhibit typical clinical and histopathological features.

2. Periodontal disease, usually present due to the difficulty in performing adequate oral hygiene because of the orthodontic appliance, must be treated before surgical removal of the proliferative processes so as to avoid heavy transoperative bleeding and postoperative compli-

cations, such as lesion recurrence itself.

3. Surgical excision is the most widely employed technique today. Regardless of treatment modality, submitting the collected material to histopathological examination is not only enlightening but a sine qua non measure to avoid the underestimation of these lesions and possible errors in the final diagnosis since different diagnostic hypotheses are possible.

4. In following up on these cases, supportive periodontal therapy and oral hygiene control are necessary.

## REFERENCES

1. Barack D, Staffileno H, Sadowsky C. Periodontal complication during orthodontic therapy. *Am J Orthod*. 1985 Dec;88(6):461-5.
2. Binnie WH. Periodontal cysts and epulides. *Periodontol* 2000. 1999 Oct;21:16-32.
3. Campos V, Bittencourt LP, Maia LC, Andrade M, Mascarenhas A. Granuloma piogênico - descrição de dois casos clínicos. *J Bras Odontoped Odontol Bebê*. 2000;3(12):170-5.
4. Coleman GC, Flaitz CM, Vincent SD. Differential diagnosis of oral soft tissue lesions. *Tex Dent J*. 2002 Jun;119(6):484-8, 90-2, 494-503.
5. Convissar RA, Diamond LB, Fazekas CD. Laser treatment of orthodontically induced gingival hyperplasia. *Gen Dent*. 1996 Jan-Feb;44(1):47-51.
6. Falabella MEV, Falabella JM. Granuloma gravídico - caso clínico. *Periodontia*. 1994;3(2):167-70.
7. Graham RM. Pyogenic granuloma: an unusual presentation. *Dent Update*. 1996 Jul-Aug;23(6):240-1.
8. Halliday H, Gordon S, Bhola M. Case report: an unusually large epulis on the maxillary gingiva of a 24-year-old woman. *Gen Dent*. 2007 May-Jun;55(3):232-5.
9. Jafarzadeh H, Sanatkhan M, Mohtasham N. Oral pyogenic granuloma: a review. *J Oral Sci*. 2006;48(4):167-75.
10. Patil K, Mahima VG, Lahari K. Extragingival pyogenic granuloma. *Indian J Dent Res*. 2006;17(4):199-202.
11. Ramirez K, Bruce G, Carpenter W. Pyogenic granuloma: case report in a 9-year-old girl. *Gen Dent*. 2002 May-Jun;50(3):280-1.
12. Rivero ELC, Araújo LMA. Granuloma piogênico: uma análise clínico-histopatológica de 147 casos bucais. *Rev Fac Odontol Univ Passo Fundo*. 1998;3(2):55-61.
13. Romero M, Albi M, Bravo LA. Surgical solutions to periodontal complications of orthodontic therapy. *J Clin Pediatr Dent*. 2000 Spring;24(3):159-63.
14. Satpathy AK, Mohanty PK. Large pyogenic granuloma: a case report. *J Indian Med Assoc*. 2007 Feb;105(2):90-8.
15. Scaramella F, Quaranta M. Hypertrophic and/or hyperplastic gingivopathy during orthodontic therapy. *Dent Cadmos*. 1984 Feb;52(2):65-72.
16. Shenoy SS, Dinkar AD. Pyogenic granuloma associated with bone loss in an eight year old child: a case report. *J Indian Soc Pedod Prev Dent*. 2006 Dec;24(4):201-3.
17. Silva-Sousa YT, Coelho CM, Brentegani LG, Vieira ML, Oliveira ML. Clinical and histological evaluation of granuloma gravidarum: case report. *Braz Dent J*. 2000;11(2):135-9.
18. Silverstein LH, Burton CH Jr, Garnick JJ, Singh BB. The late development of oral pyogenic granuloma as a complication of pregnancy: a case report. *Compend Contin Educ Dent*. 1996 Feb;17(2):192-8; quiz 200.
19. Terezhalmay GT, Riley CK, Moore WS. Pyogenic granuloma (pregnancy tumour). *Quintessence Int*. 2000;31(6):440-1.
20. Vélez LMA, Souza LB, Pinto LP. Granuloma piogênico. Análise dos componentes histológicos relacionados com a duração da lesão. *Rev Gaúcha Odontol*. 1992;40(1):52-6.
21. Zarei MR, Chamani G, Amanpoor S. Reactive hyperplasia of the oral cavity in Kerman province, Iran: a review of 172 cases. *Br J Oral Maxillofac Surg*. 2007 Jun;45(4):288-92.
22. Zhang W, Chen Y, An Z, Geng N, Bao D. Reactive gingival lesions: a retrospective study of 2,439 cases. *Quintessence Int*. 2007 Feb;38(2):103-10.

Submitted: October 2008

Revised and accepted: December 2009

**Contact address**

Irineu Gregnanin Pedron  
 Rua Flores do Piauí, 347  
 CEP: 08.210-200 – São Paulo/SP, Brazil  
 E-mail: igpedron@usp.br