

Angle Class I malocclusion, with anterior open bite, treated with extraction of permanent teeth*

Mírian Aiko Nakane Matsumoto**

Abstract

Open bite is an anomaly with distinct characteristics which, in addition to involving complex, multiple etiologic factors, entails aesthetic and functional consequences. Many alternative approaches have been employed to treat open bite, including palatal crib, orthopedic forces, occlusal adjustment, camouflage with or without extractions, mini-implants or mini-plates, and orthognathic surgery. By determining accurate diagnosis and etiology professionals can set the goals and ideal treatment plan for this malocclusion. This report, describing the two stages treatment of Angle Class I malocclusion with Class II skeletal pattern and anterior open bite, was presented to the Brazilian Board of Orthodontics and Dentofacial Orthopedics (BBO), representative of category 2, as partial fulfillment of the requirements for obtaining the title of BBO diplomate.

Keywords: Angle Class I malocclusion. Open bite. Corrective orthodontics. Tooth extraction.

INTRODUCTION

Patient was a 12-year-old Caucasian girl referred by a speech therapist for orthodontic treatment and presented with a chief complaint of “lack of contact between the anterior teeth and altered position of canines.” During the interview, she reported having had a pacifier sucking habit until 5 years of age and having undergone adenotonsillectomy at age four. She was in good general health, with no history of serious illnesses or trauma.

DIAGNOSIS

Clinical examination revealed an increased lower face, lip incompetence, a slightly convex profile, obtuse nasolabial angle and good cervical-mandibular line (Fig 1).

Intraoral evaluation disclosed low risk for caries, healthy gums, molars and canines in normal occlusion, open bite that extended to the premolar region, maxillary atresia, 6 mm overjet, 2 mm lower midline deviation to the right side, and upper midline coinciding with the mid-palatine raphe (Figs 1 and 2).

* Case report, category 2 - approved by the Brazilian Board of Orthodontics and Facial Orthopedics (BBO).

** Associate Professor, Department of Child Dentistry, Preventive and Social Dentistry, Ribeirão Preto School of Dentistry, São Paulo University. Ph.D. in Orthodontics, School of Dentistry, Rio de Janeiro Federal University. Diplomate of the Brazilian Board of Orthodontics.

From a functional standpoint, she exhibited mixed breathing, predominantly oral, tongue thrusting and adapted swallowing and speech.

Panoramic radiography showed all permanent teeth, third molar crowns in formation, maxillary primary second molars in exfoliation phase and lower right second deciduous molar with ankylosis (Fig 3). It was also noted that the patient was in the stage of maximum pubertal growth spurt (Fig 4).

Cephalometric analysis was performed and revealed that both the maxilla and mandible were retruded in relation to the skull base. She had a Class II skeletal pattern ($ANB = 6^\circ$), predominance of vertical growth ($SN.GoGn = 43^\circ$), protruding upper and lower incisors ($1-NA = 5.5$ mm and $1-NB = 6.0$ mm), with decreased axial inclination ($1.NA = 19.5^\circ$ and $1.NB = 22.5^\circ$) (Fig 5 and Table 1).

TREATMENT GOALS (PHASE 1)

Initially, the goal was to eliminate the orofacial myofunctional disorder (adapted swallowing and speech), redirect facial growth by stimulating mandibular rotation in the counterclockwise direction to counter a growth tendency noted in the lower face and correct the anterior open bite.

TREATMENT PLAN (PHASE 1)

Planning for the first phase consisted in redirecting facial growth, correcting the Class II skeletal pattern and growth tendency in the lower face, using a modified Thurow appliance. This appliance was intended to prevent further vertical alveolar growth and stimulate mandibular rotation in the counterclockwise direction. The installation of a palatal crib was also planned, with

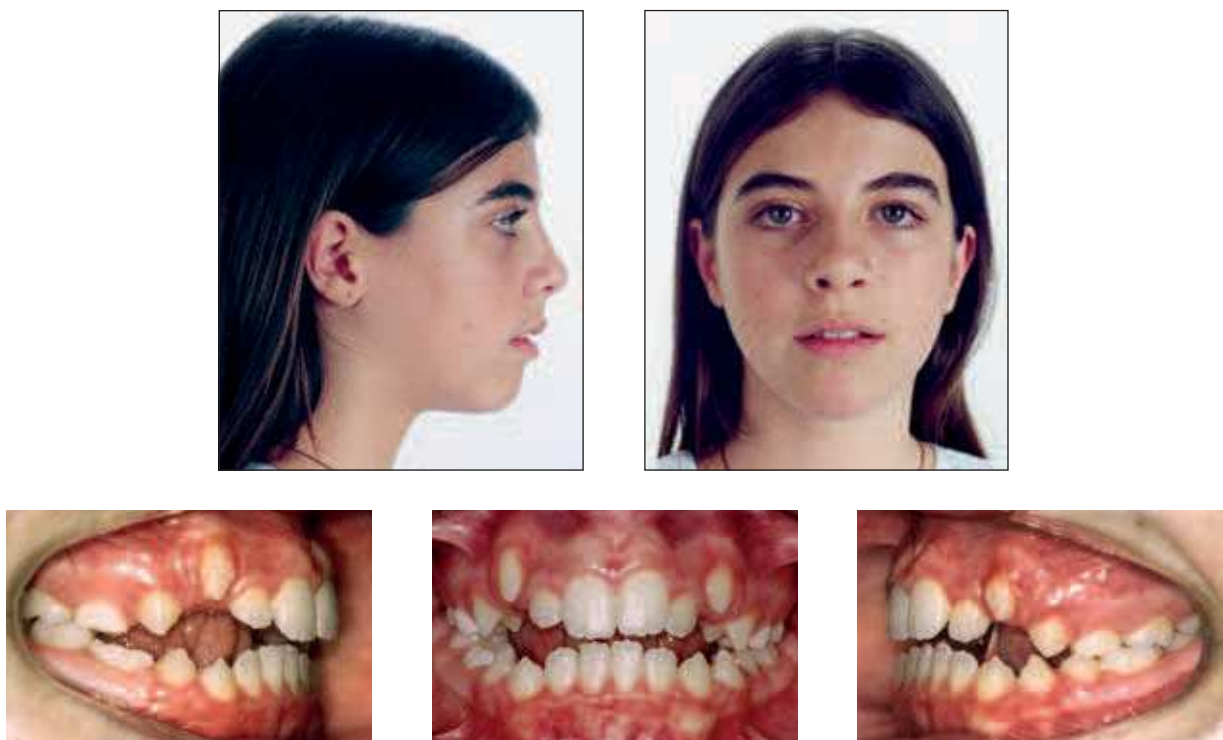

FIGURE 1 - Initial facial and intraoral photographs.

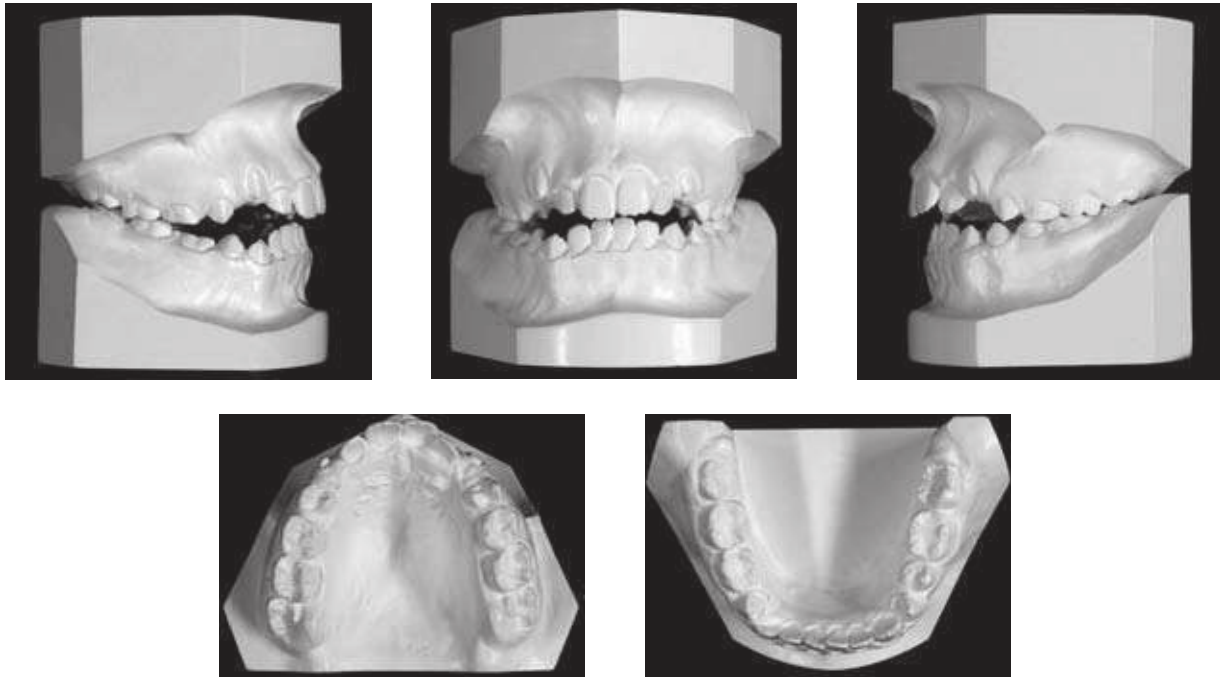


FIGURE 2 - Initial models.

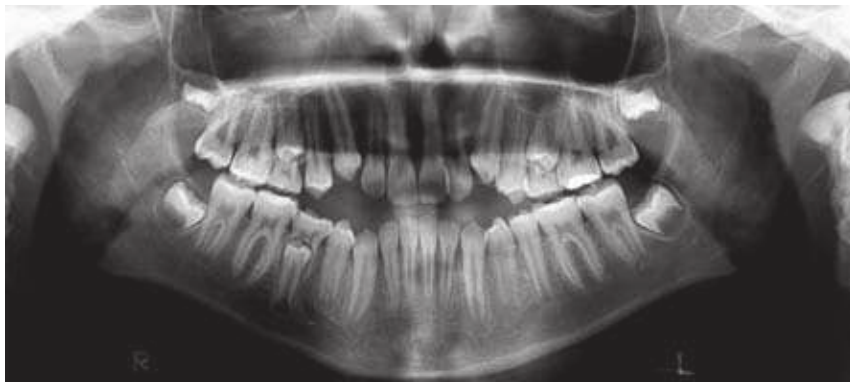


FIGURE 3 - Initial panoramic radiograph.

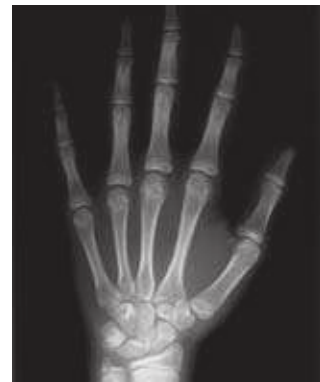

FIGURE 4 - Initial hand and wrist X-ray.

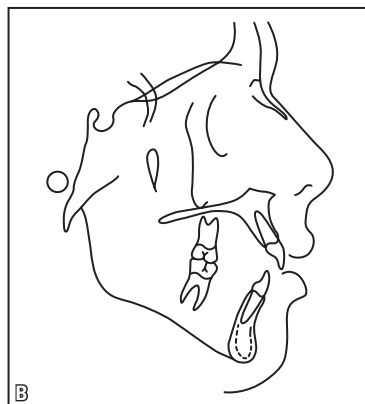
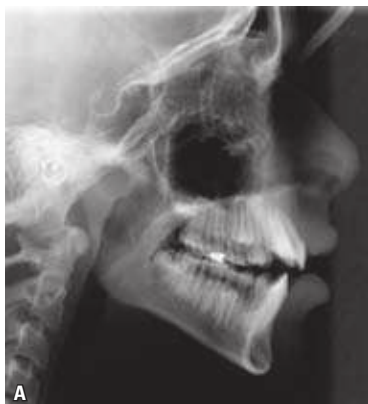

FIGURE 5 - Initial lateral cephalogram (A) and cephalometric tracing (B).

referral of the patient to a speech therapist to intercept the tongue thrusting habit. Additionally, her lower right second deciduous molar was extracted as it showed an abnormal root resorption pattern and ankylosis.

TREATMENT PROGRESS

A modified Thurow appliance was installed, combined with a palatal crib from premolar to premolar to control maxillary vertical growth and prevent the tongue from being placed in the anterior region. In addition, speech therapy was started to treat the orofacial myofunctional disorder. The patient was followed up on a monthly basis during the treatment period, which lasted for twelve months.

The use of a modified Thurow appliance was discontinued when all permanent teeth had erupted.

The Class III molar relationship was evident due to a distalization component in the Thurow appliance, and a slight posterior crossbite which appeared over time.

RESULTS (PHASE 1)

After evaluating all models and radiographs at the end of this phase it was found that the proposed objectives had not been achieved since the bite remained open and vertical growth was not reduced (SN.GoGn rose from 43° to 44°, Y-axis, from 65° to 68°, and FMA, from 33° to 37.5°). This result was probably due to the sharply vertical growth pattern displayed by the patient. Overjet was reduced from 6 mm to 4 mm and a slight improvement was noted in the Class II skeletal pattern, with ANB dropping from 6° to 5.5° (Figs 6 – 10).

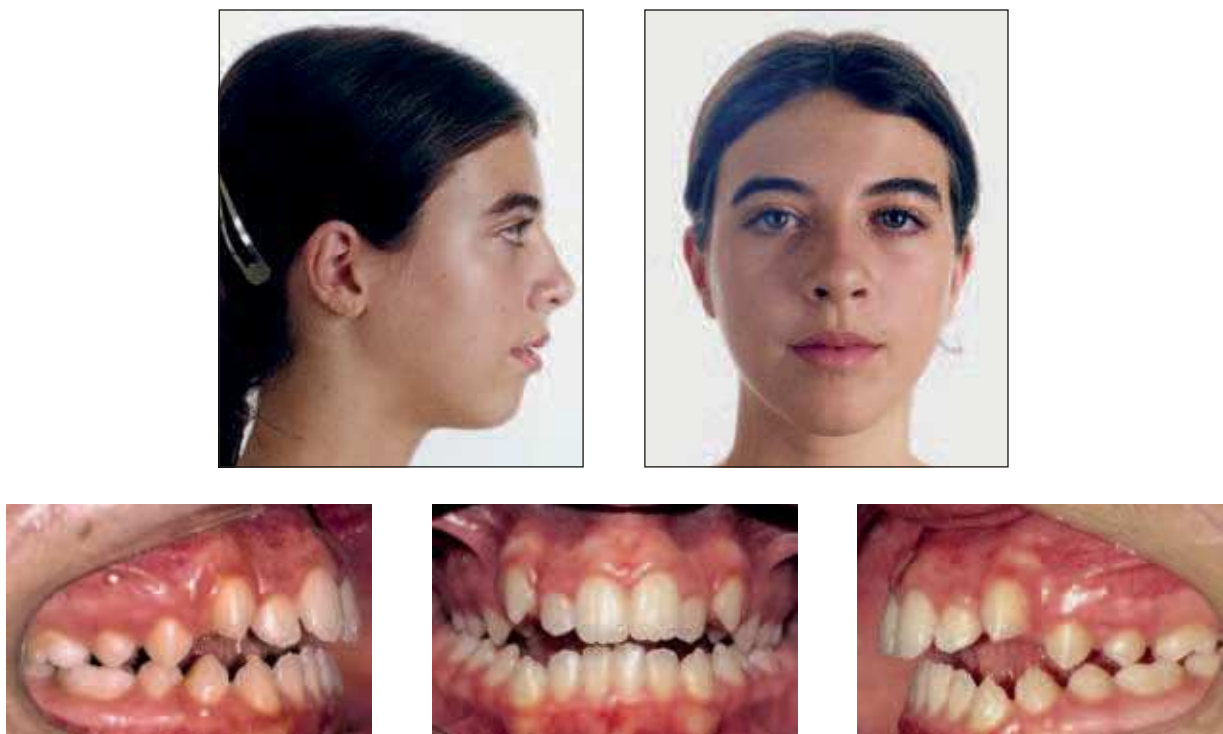

FIGURE 6 - Intermediate facial and intraoral photographs.

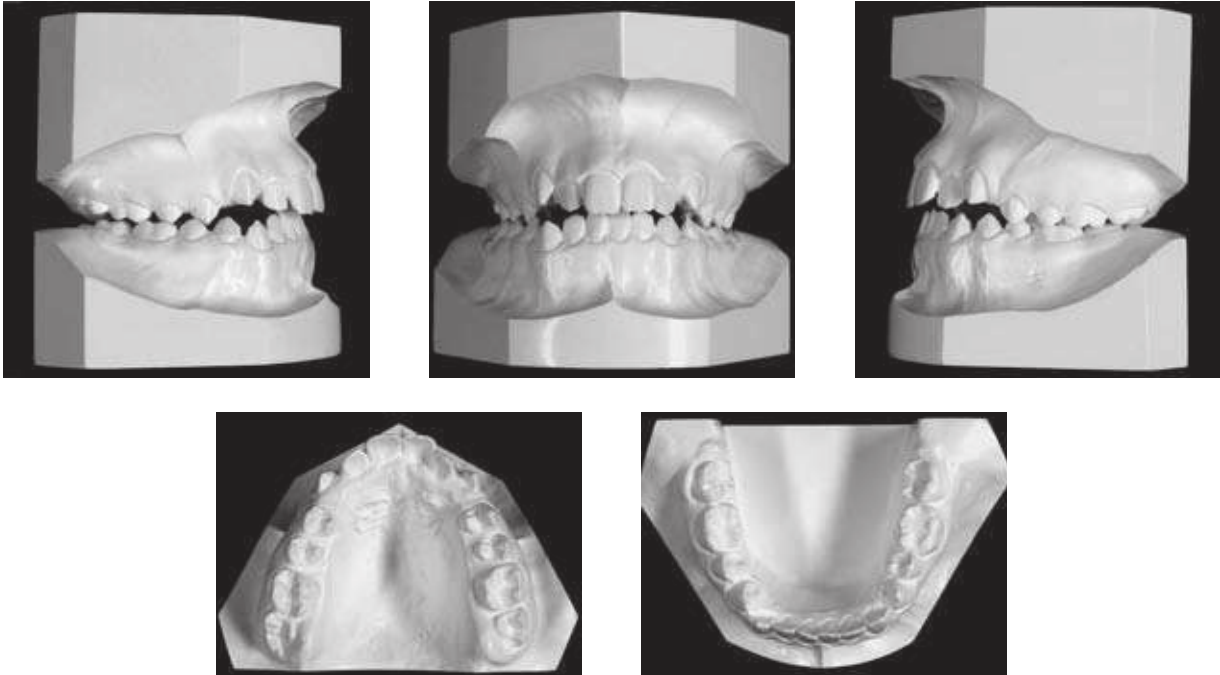


FIGURE 7 - Intermediate models.

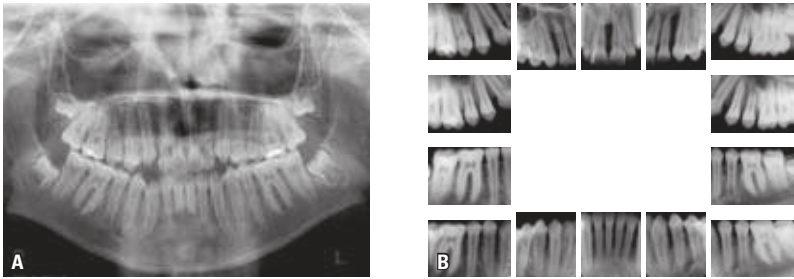


FIGURE 8 - Intermediate panoramic (A) and periapical (B) radiographs.

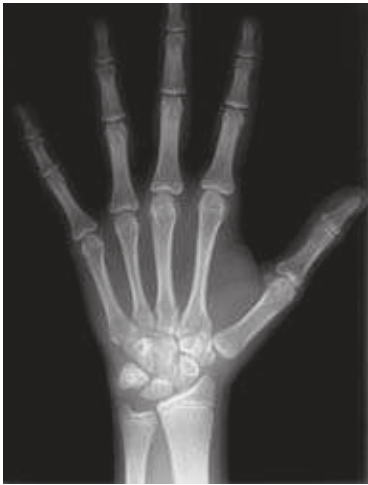

FIGURE 9 - Intermediate hand and wrist X-ray.

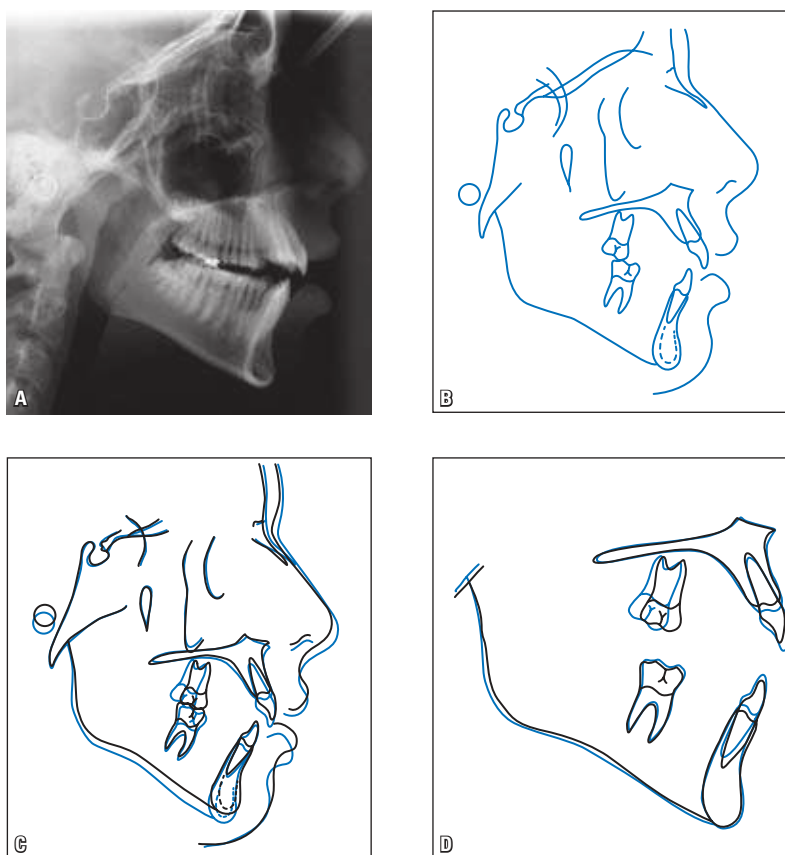


FIGURE 10 - Lateral cephalogram (A) and cephalometric tracing (B). Total (C) and partial (D) superimpositions of initial (black) and intermediate (blue) cephalometric tracings.

TREATMENT GOALS (PHASE 2)

In the second phase, the goal was to correct the mild crossbite that resulted from wearing the modified Thurow appliance, control the clockwise rotational tendency in the mandible and balance the lower face, eliminating the orofacial myofunctional disorder (adapted swallowing and speech) to establish correct overbite and overjet, normal molar and canine occlusion, correct the Class II skeletal pattern, as well as align and level all the teeth, thereby correcting the lower midline.

TREATMENT PLAN (PHASE 2)

At this treatment stage, correction of the slight crossbite was planned by installing a Haas expander. Mandibular growth control was achieved with

an anterior vertical-pull chin cup, while speech therapy was maintained to correct the orofacial myofunctional disorder. Concurrently, fixed orthodontic appliances were set up on both arches to perform corrective treatment with extraction of the first upper and lower premolars.

TREATMENT PROGRESS

The anterior vertical-pull chin cup was installed for night use, with an orthopedic force of 400 g on each side, to redirect mandibular growth. Then a Haas expander was cemented to correct the slight crossbite, with 0.25 mm activation until overcorrection was achieved. A standard Edgewise fixed orthodontic appliance was set up (no torques or angulations, slot 0.022x0.028-in), with bands cemented to

the first upper and lower molars and brackets bonded to the other teeth, except for the first upper and lower premolars, which were extracted.

Alignment and leveling were performed as well as torque correction using nickel-titanium 0.012-in and 0.014-in wires, and stainless steel 0.016-in to 0.020-in wires. From the moment that round 0.020-in wires began to be utilized, elastic chains were inserted for closure of extraction spaces, with anchorage loss. Next, stainless steel 0.019x 0.025-in archwires were fabricated for incisor and canine retraction, with posterior anchorage loss. At this stage, intermaxillary elastics were used to improve intercuspation and finishing. After completion and verification that the main treatment goals had been achieved, the fixed orthodontic appliance was removed. A removable maxillary retainer was installed

with a wraparound-type archwire, in addition to a fixed lingual canine-to-canine retainer made with 0.032-in stainless steel wire. The patient was instructed to wear the upper retainer 24/7 during the first year, and at night during the second year. The mandibular bonded retainer was kept indefinitely.

TREATMENT RESULTS

Crossbite correction was accomplished with the Haas expander, and redirection of mandibular growth performed with anterior vertical-pull chin cup. Upon orthodontic treatment completion, adequate improvement was achieved in lip competence and facial profile (Fig 11). Occlusion was deemed very satisfactory (Figs 11 and 12), showing molars and canines in normal occlusion, adequate overjet and overbite, good dental arch

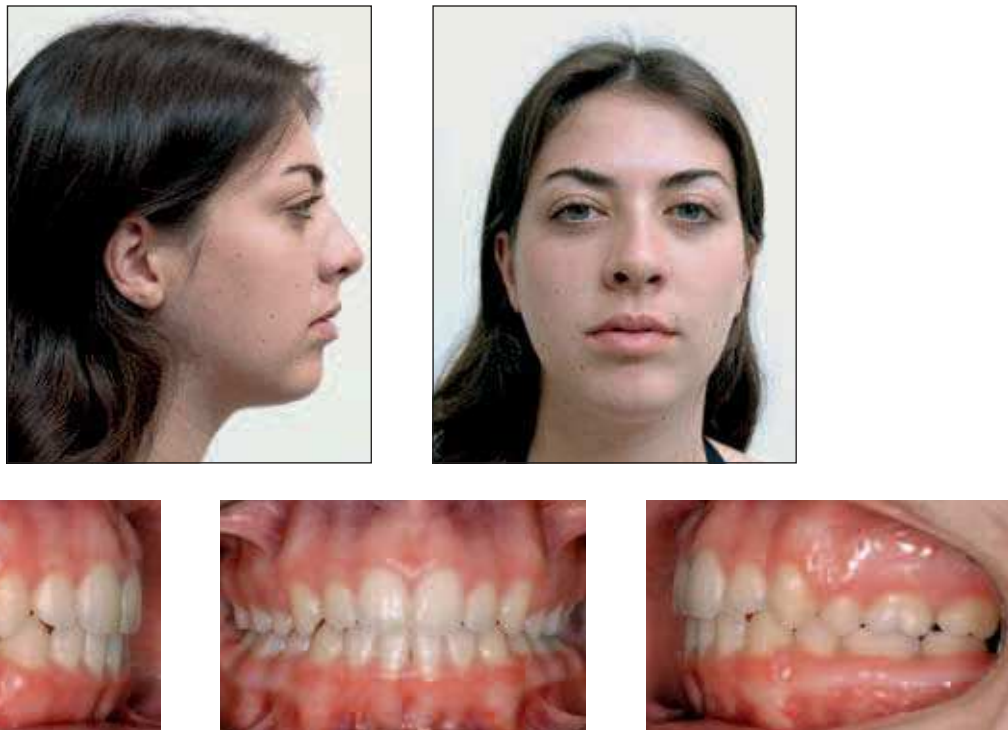

FIGURE 11 - Final facial and intraoral photographs.

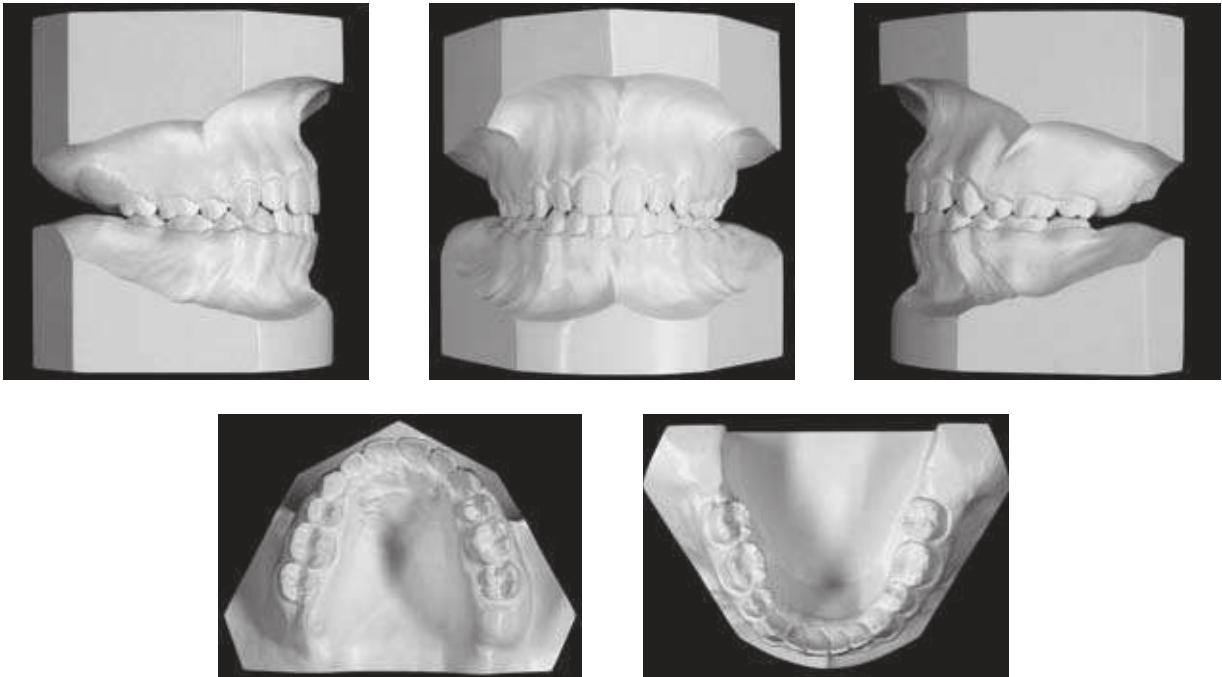


FIGURE 12 - Final models.

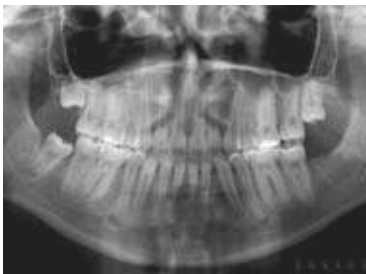


FIGURE 13 - Final panoramic radiograph.

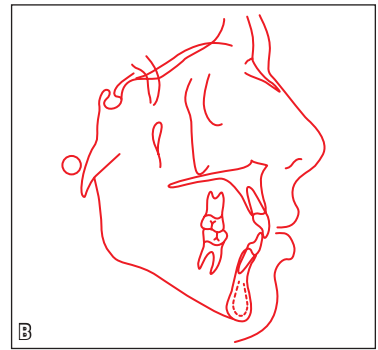
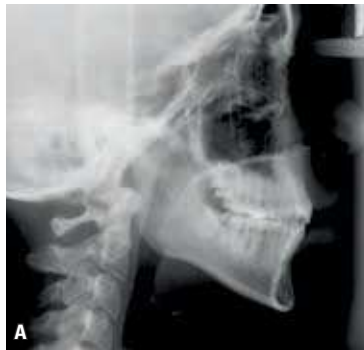

FIGURE 14 - Final lateral cephalogram (A) and cephalometric tracing (B).

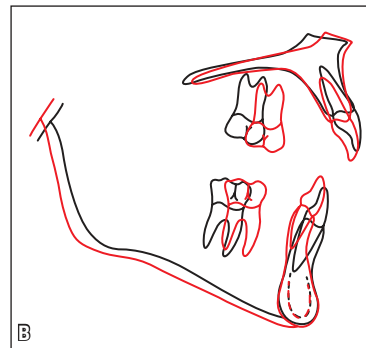
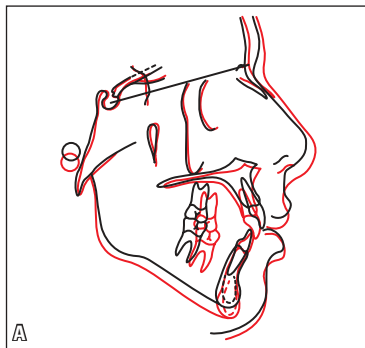


FIGURE 15 - Total (A) and partial (B) superimpositions of initial (black) and final (red) cephalometric tracings.

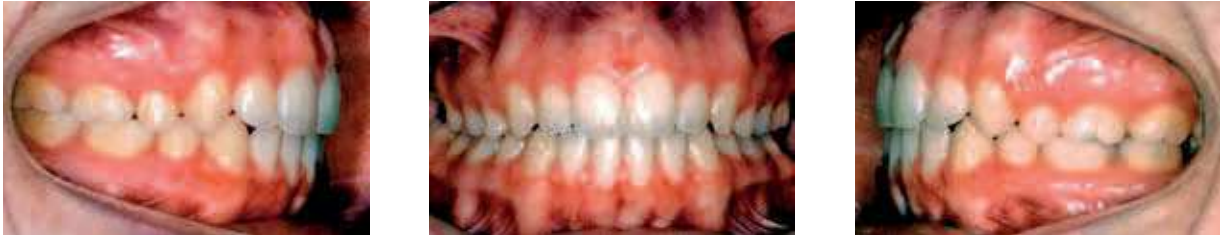
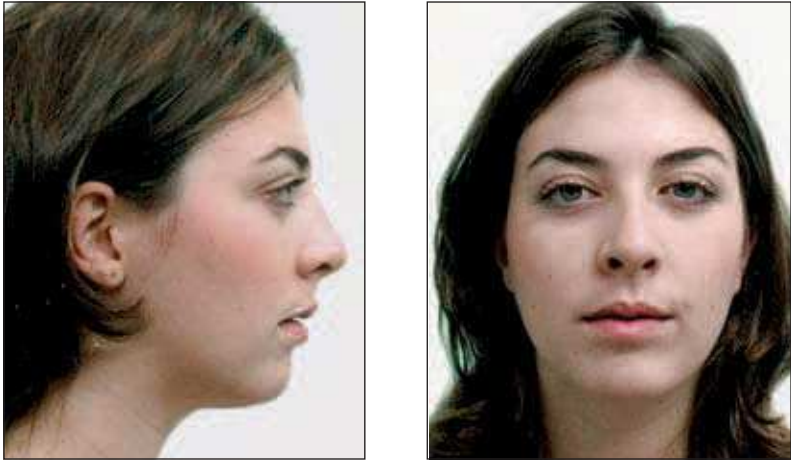
FIGURE 16 - Facial and intraoral control photographs taken two years and three months after treatment completion.

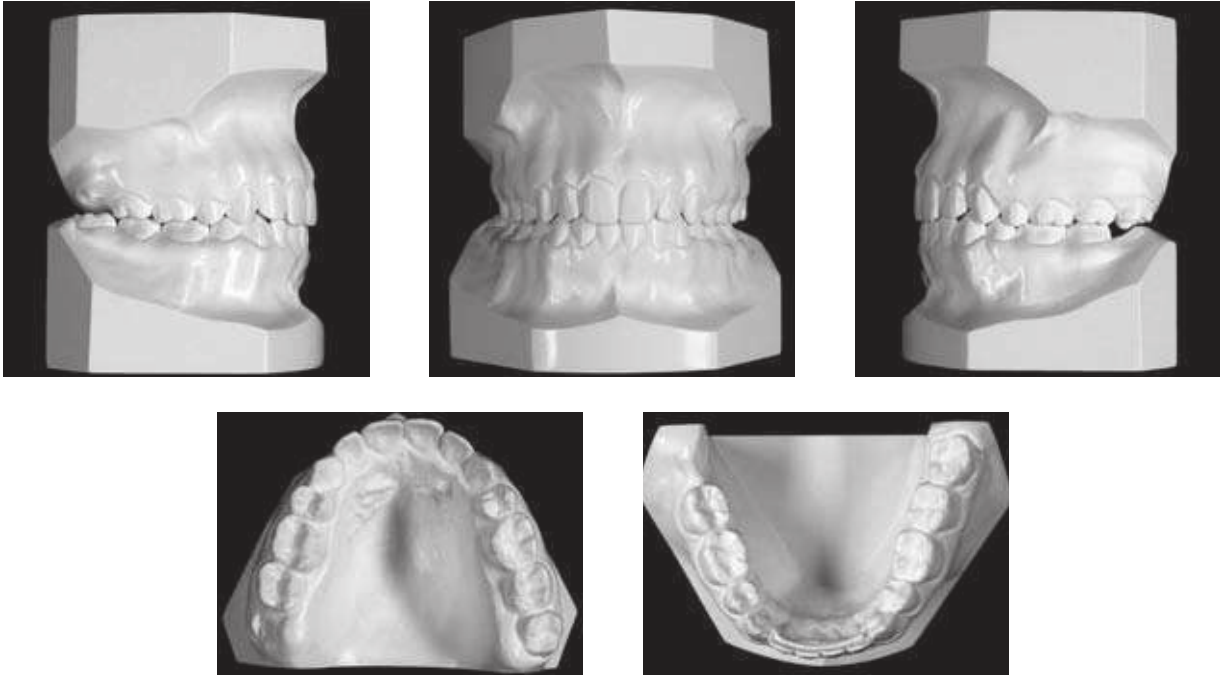


FIGURE 17 - Control models, two years and three months after treatment completion.

form and no undesirable effects to the periodontium. Cephalometric measurements did not experience major changes as ANB remained at 5.5° , SN.GoGn remained at 44° and Y-axis increased from 68° to 70° (Fig 14 and Table 1). Two years and three months after the end of treatment,

cephalometric measurements suffered minimal changes (Table 1) and occlusion remained stable (Figs 16 – 19). It is noteworthy that the patient had been instructed to have maxillary and mandibular third molars extracted, but had hitherto extracted only tooth 38 (Fig 18).

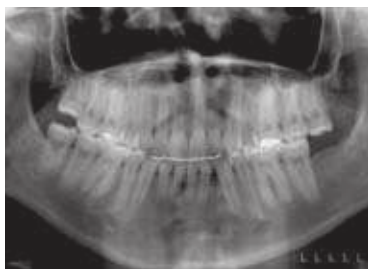


FIGURE 18 - Control panoramic radiograph two years and three months after treatment completion.

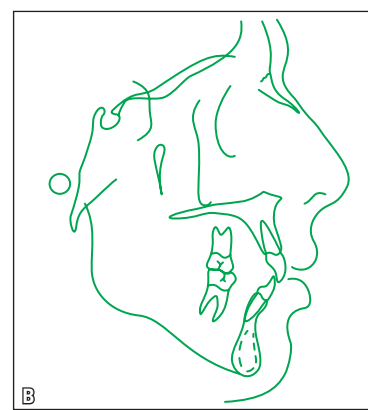
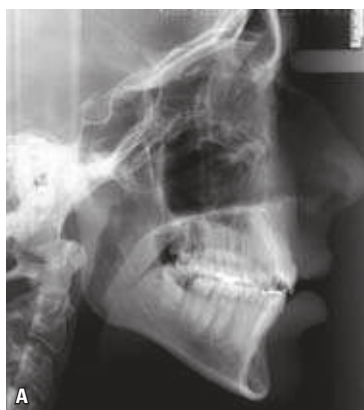

FIGURE 19 - Control lateral cephalogram (A) and cephalometric tracing (B), two years and three months after treatment completion.

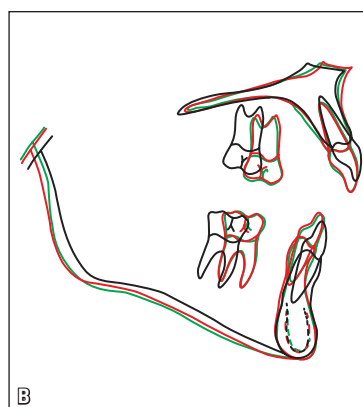
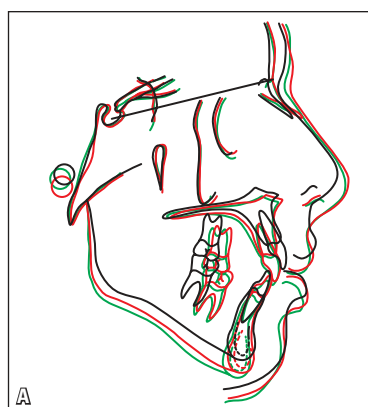


FIGURE 20 - Total (A) and partial (B) superimpositions of cephalometric tracings: initial (black), final (red) and two years and three months after treatment completion (green).

TABLE 1 - Summary of cephalometric measurements.

MEASUREMENTS		Normal	Initial (A)	A ₁	Final (B)	Difference A/B	C
Skeletal Pattern	SNA (Steiner)	82°	79°	77.5°	77°	2°	76°
	SNB (Steiner)	80°	73°	72°	71.5°	1.5°	70.5°
	ANB (Steiner)	2°	6°	5.5°	5.5°	0.5°	6.5°
	Convexity Angle (Downs)	0°	8°	9°	9°	1°	9°
	Y-Axis (Downs)	59°	65°	68°	70°	5°	68°
	Facial Angle (Downs)	87°	84°	80°	79°	5°	82°
	SN – GoGn (Steiner)	32°	43°	44°	44°	1°	44.5°
	FMA (Tweed)	25°	33°	36°	35.5°	6.5°	35°
Dental Pattern	IMPA (Tweed)	90°	86.5°	89.5°	92°	5.5°	94°
	\perp – NA (degrees) (Steiner)	22°	19.5°	19.0°	15°	4.5°	15°
	\perp – NA (mm) (Steiner)	4 mm	5.5 mm	5.5 mm	2.5 mm	3 mm	3 mm
	$\bar{\perp}$ – NB (degrees) (Steiner)	25°	22.5°	25°	28°	5.5°	28°
	$\bar{\perp}$ – NB (mm) (Steiner)	4 mm	6 mm	6.5 mm	7 mm	1 mm	6.5
	$\frac{1}{1}$ – Interincisal Angle (Downs)	130°	132°	131°	133°	1°	131°
	$\bar{\perp}$ – APo (mm) (Ricketts)	1 mm	2 mm	2.5 mm	2 mm	0 mm	2.5
Profile	Upper Lip – S Line S (Steiner)	0 mm	1 mm	1 mm	0 mm	1 mm	0 mm
	Lower Lip – S Line (Steiner)	0 mm	3 mm	3 mm	2.5 mm	0.5 mm	2 mm

FINAL CONSIDERATIONS

Open bite is an anomaly with distinct, easily recognizable features that can be found in 25% to 38% of orthodontic patients.¹⁻⁴ Several etiological factors are involved in this type of malocclusion, such as: Facial growth pattern, sucking habits, tongue posture, mouth breathing, enlarged adenoids, syndromes, occlusal and eruption forces, dental ankylosis and mandibular posture imbalance. Other factors such as case severity and timing of treatment initiation can render correction harder and produce unstable results.^{5,6,7} Palatal crib⁵⁻⁸, bite-block,^{9,10} modified Thurow appliance,¹¹

orthodontic camouflage,^{12,13,14} magnets¹⁵, mini-implants¹⁶, mini-plates^{17,18} and orthognathic surgery.¹⁹ To ensure that the most appropriate therapy is employed, it is necessary to establish a correct diagnosis and treatment plan.^{14,20,21}

With advances in surgical techniques and the growing popularity of mini-implants^{14,16} many patients with anterior skeletal open bite do not favor any options that might subject them to a surgical procedure and prefer to undergo camouflage orthodontic therapy, as was the case with this patient.

When the surgical option is rejected, treatment requires a longer period of time and greater

patient compliance. Some authors, like Subtelny and Sakuda,⁵ and Epker and Fish²² argue that palatal cribs are unable to correct open bite, with the exception of cases with a favorable growth pattern and Class I malocclusion. In this case report, tongue thrusting was treated with a palatal crib combined with a modified Thuro appliance and speech therapy. The modified Thuro appliance has the function of controlling maxillary vertical growth and, consequently, displacing the mandible in the counterclockwise direction. After twelve months, it was observed that the mechanics employed in this case was not effective in closing the bite and was not able to promote cephalometric changes (Table 1), probably due to lack of patient cooperation and her excessive vertical growth.

In general, stability is the most important criterion in choosing the method for treating open bite as this malocclusion can prove difficult to control. Authors such as Goto et al.²³ argue that treatments with extractions do not show stability since retraction of anterior teeth can encroach upon the tongue area. On the other hand, Janson et al.³ and Vaden²⁴ claim that treatments with extractions allow greater stability since retraction, associated

with anchorage loss, promotes bite closure, thereby decreasing the need for vertical elastics and the need to perform correction by extruding anterior teeth. In addition, extractions can often help in achieving lip seal¹⁴ as they allow retraction of the upper and lower incisors.²³

Camouflage orthodontic therapy is a treatment option and as such obviously has indications and contraindications. Factors such as age, bone maturation, facial profile and pattern should be considered before opting for this method.¹⁴ In this case, it could be stated that a successful orthodontic treatment was performed with extraction of upper and lower premolars since normal occlusion of molars and canines, as well as normal overjet and overbite were ultimately achieved. It is noteworthy that the occlusion observed on treatment completion was achieved through controlled orthodontic mechanics and the brief use of intermaxillary elastics limited to finishing rectangular archwires. Restraining the use of vertical elastics was designed to prevent extrusion, uneven teeth and damage to the periodontium, such as gingival recession. The stability achieved in this case can be attested by the control records two years and three months after treatment (Figs 16 and 17).

REFERENCES

1. Lopez-Gavito G, Wallen TR, Little RM, Joondeph DR. Anterior open-bite malocclusion: a longitudinal 10-year postretention evaluation of orthodontically treated patients. *Am J Orthod.* 1985 Mar;87(3):175-86.
2. Katsaros C, Berg R. Anterior open bite malocclusion: a follow-up study of orthodontic treatment effects. *Eur J Orthod.* 1993 Aug;15(4):273-80.
3. Janson GRP, Valarelli FP, Beltrão RTS, Freitas MR, Henriques JFC. Stability of anterior open bite nonextraction treatment in the permanent dentition. *Am J Orthod Dentofacial Orthop.* 2003 Sep;124(3):265-76.
4. Espeland L, Dowling PA, Mobarak KA, Stenvik A. Three-year stability of open-bite correction by 1-piece maxillary osteotomy. *Am J Orthod Dentofacial Orthop.* 2008 Aug;134(1):60-6.
5. Subtenly JD, Sakuda M. Openbite: diagnosis and treatment. *Am J Orthod.* 1964 May;50(5):337-58.
6. Nahoum HI. Vertical proportions and the palatal plane in anterior openbite. *Am J Orthod.* 1971 Mar;59(3):273-82.
7. Spyroulus MN, Askarieh M. Vertical control: a multifactorial problem and its clinical implications. *Am J Orthod.* 1986 Jul;70(1):70-80.
8. Haryett RD, Hansen FC, Davidson PO, Sandilands ML. Chronic thumb-sucking. The psychologic effects and relative effectiveness of various methods of treatment. *Am J Orthod Dentofacial Orthop.* 1967 Aug;53(8):569-85.
9. McNamara JA. An experimental study of increased vertical dimension in the growing face. *Am J Orthod.* 1977 Apr;71(4):382-95.
10. Sehgal V, Chahdna A, Saini M. Use of semifixed posterior bite blocks to open a deep bite. *J Clin Orthod.* 2008 Jun;42(6):358-60.
11. Stuaní MBS, Stuaní AS. Modified Thurow appliance. A clinical alternative for correcting skeletal open bite. *Am J Orthod Dentofacial Orthop.* 2005 Jul;128(1):118-25.
12. Kim YH. Anterior openbite and its treatment with multiloop edgewise archwire. *Angle Orthod.* 1987 Oct;57(4):290-321.
13. Küçükkeles N, Acar A, Dermikaya AA, Evrenoi B, Enacar A. Cephalometric evaluation of open bite treatment with NiTi arch wires and anterior elastics. *Am J Orthod Dentofacial Orthop.* 1999 Nov;116(5):555-62.
14. Denny JM, Weiskircher MA, Dorminey JC. Anterior open bite and overjet treated with camouflage therapy. *Am J Orthod Dentofacial Orthop.* 2007 May;131(5):670-8.
15. Melsen B, McNamara JA Jr, Hoenie DC. The effect of bite blocks with and without repelling magnets studied histomorphometrically in the rhesus monkey (*macaca mullata*). *Am J Orthod Dentofacial Orthop.* 1995 Nov;108(5):500-9.
16. Park YC, Lee HA, Choi NC, Kim DH. Open bite correction by intrusion of posterior teeth with miniscrews. *Angle Orthod.* 2008 Jul;78(4):699-710.
17. Chung KR, Kim YS, Linton JL, Lee YJ. The miniplate with tube for skeletal anchorage. *J Clin Orthod.* 2002 Jul;36(7):407-12.
18. Sugawara J, Baik UB, Umemori M, Takahashi J, Kawamura H, Mitani H. Treatment and posttreatment dentoalveolar changes following intrusion of mandibular molars with application of a skeletal anchorage system (SAS) for open bite correction. *Int J Adult Orthodon Orthognath Surg.* 2002 Winter;17(4):243-53.
19. Denison TF, Kokich VG, Shapiro PA. Stability of maxillary surgery in open bite versus nonopen bite malocclusions. *Angle Orthod.* 1989 Mar;59(1):5-10.
20. Nielsen IL. Vertical malocclusions: etiology, development, diagnosis and some aspects of treatment. *Angle Orthod.* 1991 Dec;61(4):247-60.
21. Vaden JL, Pearson LE. Diagnosis of the vertical dimension. *Semin Orthod.* 2002 Dec;8(4):120-9.
22. Epker BN, Fish LC. Surgical orthodontic corrections of openbite deformity. *Am J Orthod.* 1977 Mar;71(3):278-99.
23. Goto S, Boyd RL, Iizuka T. Case report: nonsurgical treatment of an adult with severe anterior open bite. *Angle Orthod.* 1994;64(4):311-8.
24. Vaden JL. The vertical dimension: The "low-angle" patient. *World J Orthod.* 2005 Summer;6(2):115-24.

Submitted: October 2010
Revised and accepted: December 2010

Contact address
Mírian Aiko Nakane Matsumoto
Faculdade de Odontologia de Ribeirão Preto
Av. do Café, s/n / Monte Alegre
CEP: 14.040-904 – Ribeirão Preto / SP, Brazil
E-mail: manakane@forp.usp.br