

Multiple or severe root resorptions are not associated with systemic factors, individual susceptibility, family tendency or individual predisposition

Alberto Consolaro*, Telma Regina Gobbi Franscischone**, Laurindo Zanco Furquim***

Multiple or severe root resorptions, still often assigned to systemic changes, particularly endocrinopathies, are seen when the severity of alveolar bone loss is great, especially during orthodontic movements.^{18,19,20}

In bone turnover, matrix deposition alternates continuously with bone resorption at different sites and times. This dynamic process enables the bone to adapt to the functional demands of each skeletal area and to actively participate in the maintenance of the mineral homeostasis to control serum calcium and phosphorus concentrations.^{2,3,6,15} The skeleton renews completely at variable time intervals according to the patient's age.²²

Teeth, particularly root structures, do not have bone turnover,^{1,8,12,17} a consequence of the activity of osteoblasts, osteocytes, macrophages and osteoclasts. These cells organize in basic multicellular units (BMUs), or bone remodeling cells, and receive stimuli from systemic and local mediators found in membrane surface receptors of several cell types, particularly osteoblasts and macrophages.^{2,7,22}

Cementoblasts, the cells that populate the root surface, do not have receptors in sufficient number and significance to become bone turnover mediators.^{6,21} Cementoblasts are "deaf" to the messages sent by the bone turnover mediators, even when found in large concentrations in periodontal tissues, as is the case in hyperparathyroidism. In periodontal inflammation, the local levels of mediators that induce bone resorption are also high, but cementoblasts do not respond to them and, therefore, teeth are protected from bone turnover (Figs 1 and 2).

The "absence" of cementoblast surface receptors for bone turnover mediators complicates any attempt to assign a systemic origin, such as endocrinopathies, to root resorptions.²¹ In other words, cementoblasts are not affected by systemic mediators or hormones. Cementoblasts remain on the root surfaces no matter whether the concentration of systemic mediators is high or low.

The causes of root resorption should be associated with the loss of cementoblasts from the root surface, which may have its origin in trauma

* Head Professor of Pathology, FOB-USP and FORP-USP Postgraduate Program.

** Endocrinologist, PhD in Pathology at FOB-USP, Brazil.

*** Professor, Maringá State University. PhD in Pathology at FOB-USP, Brazil.

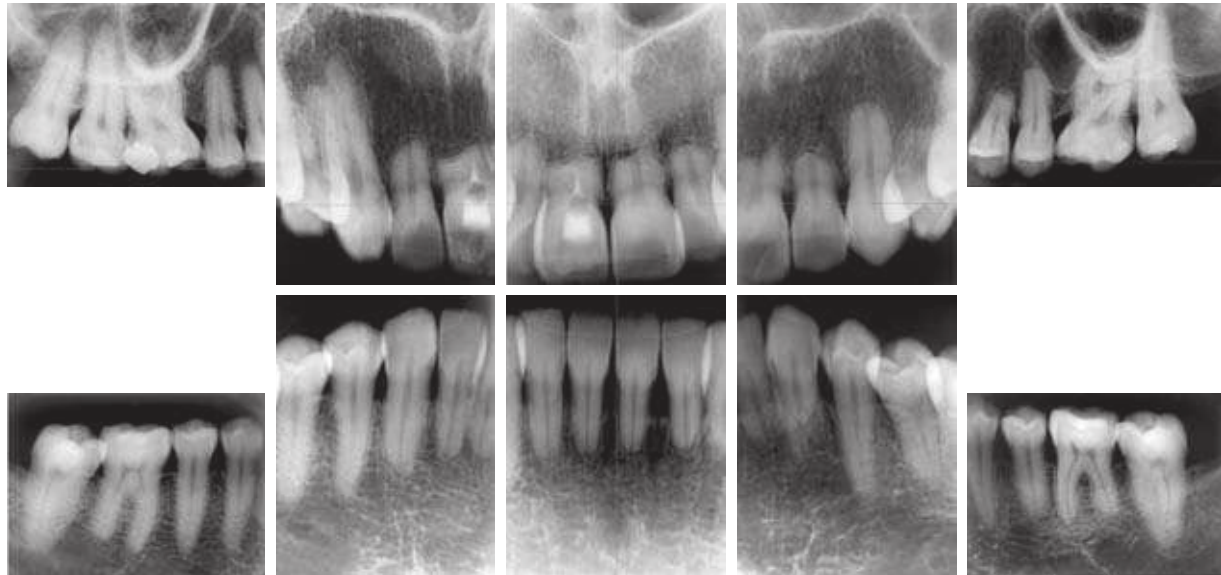


FIGURE 1 - Female patient with anterior open bite underwent orthodontic treatment for 8 years with continuous use of intermaxillary elastic bands. Severe root resorption was first assigned to a systemic cause or individual susceptibility. The continuous use of intermaxillary elastic bands, the constant change in planning and the length of treatment may have been associated with multiple and severe root resorption without any association with systemic changes in the patient.

and chemical or biological processes, but which is a local event⁷ (Figs 1 and 2). In human pathology, the absence or decrease of cementoblasts on the root surface does not characterize any systemic disease. For root resorption to occur, the first necessary step is the removal or local loss of cementoblasts.

The definition of a cause of root resorption requires a careful investigation of the patient's history to retrieve information about previous events, addictions, accidents, types of sports and leisure activities, previous treatments and associated local diseases. In the investigation of history, priority should be assigned to relevant details, such as mild trauma (concussion, subluxation), which the patient does not always remember and which cannot be detected by the clinical examiner. Mild trauma may occur due to several reasons: biting very hard objects during mastication; impact during leisure activities; surgical trauma due to leverage for extraction of neighboring teeth; and laryngoscope impact

during procedures for general anesthesia.

When the local cause of root resorption cannot be determined after all resources have been used, its etiology may be classified as idiopathic, a term which defines the impossibility of detecting the cause without assigning any systemic or iatrogenic origin to it.

In root resorptions assigned to a probable systemic cause, it is necessary to refer the patient to an endocrinologist,^{9,10,16} because endocrinopathies at an advanced stage may lead to death. The dentist is not expected to make an accurate diagnosis of endocrinopathies, but should refer patients to an endocrinologist for evaluation and final identification of the problem when it is suspected (Figs 1 and 2).

When studying the etiology of root resorptions, individual susceptibility, familial tendency and individual predisposition are sometimes mentioned, but no references are made to studies with clearly defined analytical methods. When there are signs or symptoms suggestive

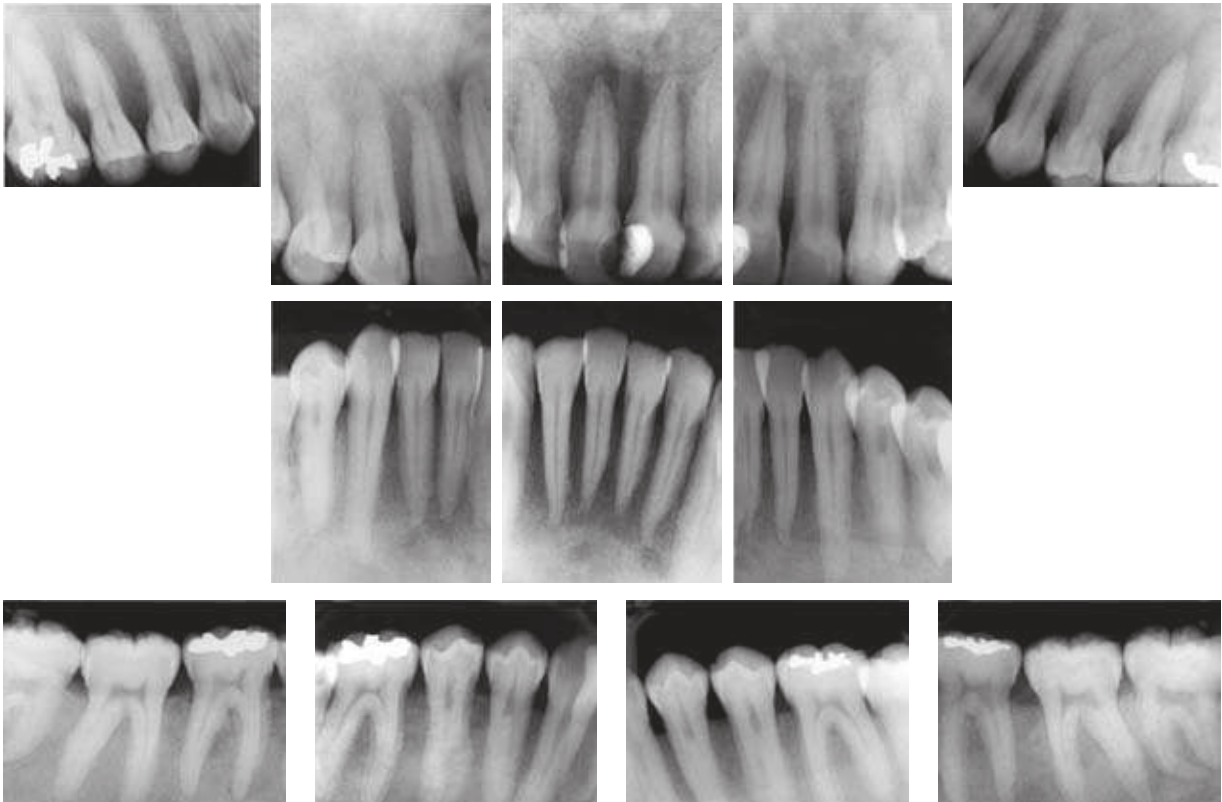


FIGURE 2 - Patient with hyperparathyroidism secondary to renal insufficiency and who underwent hemodialysis for many months. The severity of systemic conditions and their long duration led to involvement of maxillary and severe changes of trabecular bone. The lamina dura was not sufficiently organized to be visible using imaging studies; root structures were preserved and there were no resorptions.

of hereditary involvement or specific genetic changes, the patient should be referred to a geneticist for a careful evaluation and identification of the problem.

In terms of individual susceptibility, family tendencies and individual predisposition, local factors should not be ignored, such as root morphology, root apex shape, shape of the alveolar bone crest and crown-to-root ratio, which substantially affect the prognosis of root resorptions during future orthodontic treatment.¹¹ These morphological factors, which may predict greater or lower root resorption during orthodontic treatment, may be inherited or acquired during odontogenesis due to environmental factors. However, when individual susceptibility, family tendency and individual predisposition are

mentioned in root resorption in orthodontics in general, they are often classified as systemic, and not local, factors.

The publication of the characteristics of large orthodontic samples may be an important contribution to the literature:

1. How many patients are carefully examined during evaluation and diagnosis to check systemic conditions associated with diabetes and the functions of the thyroid, parathyroid, pituitary, ovaries and the other endocrine glands?
2. How many patients are seen by the endocrinologist before orthodontic treatment is started?
3. Numerous patients have asymptomatic endocrinopathies and underwent orth-

odontic treatment, were discharged, and did not have any problems in the amount of bone and rate of root resorptions. How many of these patients underwent systemic evaluations later on, when endocrinopathies were detected?

4. How many had multiple or severe root resorptions, were evaluated by an endocrinologist and had any endocrine disorder?

If there is no evidence that systemic changes, individual susceptibility, family tendency and individual predisposition are causes of root resorptions, to what should the multiple or severe root resorptions seen in orthodontic clinics be assigned?

First explanation

Cementoblasts should be removed, eliminated or simply vanish from the region for root resorption to begin on the root surface. Cementoblasts are closely associated with the cement surface and, simultaneously, are laterally protected by collagen fibers that insert into or fusion with root cement. Trauma, surgical procedures and bacterial and chemical products applied to the root surface may remove cementoblasts.

In injured teeth, the large lesions of the cementoblast layer may be reconstructed, partly with cells from the osteoblastic line, which have receptors for the mediators of bone turnover. They will be cementoblast-like, but start an early local resorption process when there is a local inflammatory stimulus, and promote a greater loss of root structure every time tooth movement is induced than surfaces without cementoblast-like cells.⁷ Therefore, the following assumption may be made: injured teeth, when moved during orthodontic treatment, have a greater chance of more frequent and more severe root resorptions. This does not translate into a contra-indication, but greater care should be taken when applying orthodontic forces to teeth in such conditions, particularly, whenever

possible, their homogeneous distribution along the root and special attention to their intensity.

Second explanation

Cementoblast removal may also occur during induced tooth movement. An excessive force to prevent the periodontal ligament, compressed between the bone and the teeth, to receive blood supply. The cells of this compressed ligament segment, such as the cementoblasts, move away from the region and leave the surface or die before migrating, and consequently the root is exposed. Cell scattering or death leaves only a hyalinized extracellular matrix in the region. The root surface, without the protection of cementoblasts, becomes the site of resorptions in the process of periodontal reorganization in the region after the dissipation of the force applied.

After a few days, reorganization is over and a new layer of cementoblasts is produced and again protects the root from resorption. The surface may acquire an irregular outline, but the periodontal ligament is back to its normal function in the region. This root will not be susceptible to future root resorptions.

After about 21 days, the process described above may resume, and a new loss of mineralized dentinal tissue adds up to the previous loss. However, if the force is adequate and compatible with the life of cementoblasts, new root resorptions will not occur. Root resorption diagnosed at the end of the orthodontic treatment is the sum of the resorptions at each activation time, and does not represent a single process during orthodontic movement (Fig 2).

Every time the orthodontic appliance is activated, great expectation is raised in the cell and tissue community in the periodontal environment: will there be new attacks against cementoblasts or not? When the orthodontic treatment is over and the patient is discharged, all congratulate because the worst is over! And let us hope there is no accidental or occlusal trauma!

Final considerations

Cases of multiple or severe root resorption have been less often assigned to systemic factors or diseases, individual susceptibility, family tendency and individual predisposition. When any of these factors is suspected and affects the appearance and progression of root resorptions, patients should be referred to endocrinologists or geneticists for adequate medical examination. When this approach is adopted, patients usually return with the result that there is no association

between the multiple or severe root resorption and their systemic status or family history.

Although there are no associations of root resorptions with systemic factors, individual susceptibility, family tendencies and individual predisposition, cases of patients with controlled or uncontrolled systemic diseases and who underwent orthodontic treatment should be carefully selected and published to enrich the literature with evidence that root resorptions are not part of the clinical signs and symptoms of endocrinopathies.

REFERENCES

- Albright F, Aub JC, Bauer W. Hyperparathyroidism: common and polymorphic conditions as illustrated by seventeen proved case from one clinic. *J Am Med Assoc.* 1934 Apr;102:1276-87.
- Aurbach GD, Marx SJ, Speegl AM. Parathyroid hormone, calcitonin and the calciferol. In: Wilson JD, Foster DW, editors. *Williams textbook of Endocrinology.* 8th ed. Philadelphia: Saunders; 1992. cap. 27, p. 1397-476.
- Baumrind S, Korn EL, Boyd RL. Apical root resorption in orthodontically treated adults. *Am J Orthod Dentofacial Orthop.* 1996 Sep;110(3):311-20.
- Brezniak N, Wasserstein A. Root resorption after orthodontic treatment: part 1: literature review. *Am J Orthod Dentofacial Orthop.* 1993 Jan;103(1):62-6.
- Brezniak N, Wasserstein A. Root resorption after orthodontic treatment: part 2: literature review. *Am J Orthod Dentofacial Orthop.* 1993 Feb;103(2):138-46.
- Cho MI, Lin WL, Garant PR. Occurrence of epidermal growth-binding sites during differentiation of cementoblasts and periodontal ligament fibroblasts of young rat: a light and electron microscopic radioautographic study. *Anat Rec.* 1991 Sep;231(1):14-24.
- Consolaro A. Reabsorções dentárias nas especialidades clínicas. 2^a ed. Maringá: Dental Press; 2005.
- Fish EW. An experimental investigation of enamel, dentine and the dental pulp. London: John Bale; 1932.
- Francischone PC. Avaliação da perda óssea maxilar pela análise da radiografia panorâmica digitalizada, comparando com a densitometria óssea lombar e femoral [dissertação]. Bauru (SP): Universidade de São Paulo; 1999.
- Francischone TRCG. Reabsorção dentária: determinação de sua frequência em pacientes com endocrinopatias [tese]. Bauru (SP): Universidade de São Paulo; 2002.
- Furquim LZ. Perfil endocrinológico de pacientes ortodônticos com e sem reabsorções dentárias [tese]. Bauru (SP): Universidade de São Paulo; 2002.
- Gies WJ. Studies of internal secretions in their relation to the development and condition of the teeth. *J Nat Dent Assoc.* 1918;5:527-31.
- Harris EF, Kineret SE, Tolley EA. A heritable component for external apical root resorption in patients treated orthodontically. *Am J Orthod Dentofacial Orthop.* 1997 Mar;111(3):301-9.
- Harris EF, Robinson QC, Woods MA. An analysis of causes of apical root resorption in patients not treated orthodontically. *Quintessence Int.* 1993 Jun;24(6):417-28.
- Hill PA, Orth M. Bone remodelling. *Br J Orthod.* 1998 May; 25(2):101-7.
- Krall EA, Dawson-Hughes B, Hannan MT, Wilson PW, Kiel DP. Postmenopausal estrogen replacement and tooth retention. *Am J Med.* 1997 Jun;102(6):536-42.
- Kronfeld R, Boyle PE. *Histopatologia dos dentes.* 3^a ed. Rio de Janeiro: Científica; 1955. p. 37-46.
- Levander E, Malmgren O. Evaluation of the risk of root resorption during orthodontic treatment: a study of upper incisors. *Eur J Orthod.* 1988 Feb;10(1):30-8.
- Levander E, Malmgren O, Eliasson S. Evaluation of root resorption in relation to two orthodontic treatment regimes. A clinical experimental study. *Eur J Orthod.* 1994 Jun;16(3):223-8.
- Levander E, Malmgren O, Stenback K. Apical root resorption during orthodontic treatment of patients with multiple aplasia: a study of maxillary incisors. *Eur J Orthod.* 1998 Aug;20(4):427-34.
- Lindskog S, Blomlöf L, Hammarström L. Comparative effects of parathyroid hormone on osteoblasts and cementoblasts. *J Clin Periodontol.* 1987 Aug;14(7):386-9.
- Manolagas SC. Birth and death of bone cells: basic regulatory mechanisms and implications for the pathogenesis and treatment of osteoporosis. *Endocr Rev.* 2000 Apr;21(2):115-37.
- Miller SC. Hormonal regulation of osteogenesis. In: Davidovitch Z, editor. *Biological mechanisms of tooth eruption and root resorption.* Colombus: Ohio State University; 1988. cap. 8, p. 71-9.

Contact address
 Alberto Consolaro
 E-mail: consolaro@uol.com.br