

Perception of changes in the gingival plane affecting smile aesthetics

Daniela Feu*, Fabíola Bof de Andrade**, Ana Paula Camata Nascimento***, José Augusto Mendes Miguel****, Antonio Augusto Gomes*****, Jonas Capelli Júnior*****

Abstract

Objective: This study investigated how 80 dental professionals and 80 lay persons, patients from private practice offices and from the School of Dentistry, Federal University of Espírito Santo (UFES), perceived the presence of changes in the gingival plane. **Methods:** A photograph of a smiling young woman was digitally modified to produce symmetrical changes in the gingival height of the central incisors and lateral incisors, thereby causing the gingival plane to ascend progressively. Individuals were asked to choose the most pleasant looking picture and thereafter the interviewer questioned each individual to find out if they knew what was being changed in the sequence of pictures, i.e., whether or not they were able to identify changes in the gingival plane. **Results:** The results showed a significant prevalence in the selection of a harmonious gingival plane in the group of dentists and patients ($p < 0.001$ and 0.05 , respectively). Furthermore, there were no significant differences between the specialties comprised in the group of dentists ($p = 0.538$), which was the case in the lay group ($p = 0.05$), showing a greater perception on the part of the group of dental office patients. Identification of changes in the gingival plane was significant in the group of dentists ($p < 0.001$) without significant differences between group specialties. Neither was it significant in the lay group ($p = 0.100$). The results also highlight a significantly higher ability to identify problems in the group of dentists compared to the lay group ($p < 0.001$). **Conclusion:** It was therefore concluded that symmetrical changes greater than 2 mm can be perceived by both dentists and lay people. Moreover, no differences were found in this perception among the dental specialties. Finally, the group of dental office patients was significantly more perceptive than UFES patients.

Keywords: Orthodontics. Dental esthetics. Gingival plane.

* Master and Ph.D student in Orthodontics, State University of Rio de Janeiro (UERJ).

** Master and Ph.D in Public Health by the University of Pernambuco (UPE).

*** Master of Prosthodontics, Federal University of Espírito Santo (UFES) and Adjunct Professor of the discipline of prosthodontics.

**** Doctor and Professor of Orthodontics, FO-UERJ and Associate Professor of Orthodontics at UERJ.

***** PhD in Prosthodontics by the University of São Paulo (USP) and Adjunct Professor of Prosthodontics, Federal University of Espírito Santo.

***** Doctor and Professor of Orthodontics, FO-UERJ and Associate Professor of Orthodontics at UERJ.

INTRODUCTION

The current situation in the field of dentistry is such that many individuals are seeking quality cosmetic improvement for their smiles. Dentists play a key role as they undertake to meet these patients' expectations. To this end, many prosthetic products and services have been developed over the years.⁵ However, it is important to note that in many situations orthodontic treatment can achieve results not attainable by cosmetic dentistry, especially when the problem is related to the patient's gingival margin and heights.²

In many situations, complaint of disproportion between the gingival margins may lead patients to seek treatment, even though they may not be capable of adequately pointing out the issue to the dentist.⁸ However, in other situations it may have been caused by corrective orthodontic treatment such as, for example, when canines are moved mesially to replace missing lateral incisors. More importantly, however, in these two situations one should be aware of the patient's tolerance regarding the discrepancy they wish to address, which, in general, will guide the orthodontist in his/her therapeutic options.⁸

In gingival contours that are considered aesthetic the gingival margin of the lateral incisor is located below and along a tangent drawn from the gingival margin of the central incisor to the corresponding canine region.¹ The ideal gingival height of the lateral incisors is numerically 1 mm below the central incisors and canines.^{3,7} Unightly patterns show the margins of the lateral incisors above the margins of the central incisors and canines—either unilaterally or bilaterally—with overerupted central incisors, and the margins below the lateral incisors and canines creating the appearance of a seagull.¹ These unightly contours are classified as the flat and reverse types of the gingival margin, respectively.¹⁰

In a study on the degree of aesthetic perception of dentists (general practitioners and orthodontists) and lay persons relative to changes in the

gingival margin, it was concluded that none of the three changes, with progressive symmetrical increments of 0.5 mm in the margin height of lateral incisors, totaling up to a 1.5 mm difference, could be statistically perceived by orthodontists, dentists, general practitioners or lay persons.⁶ Moreover, in assessing the perception of asymmetric changes in the gingival margin it was concluded that these changes are easily perceived by orthodontists, who identified unilateral changes in increments of 0.5 mm, and are also perceived by clinical dentists and lay people starting at 1.5 mm.⁷

With the purpose of determining the degree of perception of the aesthetic discrepancies in the gingival height of anterior teeth by dentists, and patients seeking dental treatment, this study aimed to evaluate the perception of symmetrical changes in the gingival plane—based on photographs showing only smiles—by lay persons, orthodontists, periodontists, prosthodontists and general practitioners.

MATERIAL AND METHODS

Characterization of the sampling plan

The sample of dentists consisted of four groups:

- » Group DI: Orthodontists.
- » Group DII: Prosthodontists.
- » Group DIII: Periodontists.
- » Group DIV: General Practitioners.

Each group comprised twenty participants totaling eighty dentists altogether. The dentists were randomly selected from among those registered in the city of Vitória, Espírito Santo State, and the sample was stratified in order to include the same number of dentists by specialty.

The sample of lay individuals was composed of two groups:

- » Group LI: Patients treated at the Integrated Clinic for Adults (UFES).
- » Group LII: Patients treated in private dental offices.

Each group was comprised of forty participants. Patients in group I were randomly selected

from among the patients undergoing treatment at the time of the research at the Integrated Clinic for Adults, Federal University of Espírito Santo. Patients in group II were selected from those present in dental offices visited by the researchers and who met the inclusion criteria (convenience sample).

Inclusion and exclusion criteria

Dentists who were registered as specialists at the Regional Council of Dentistry-ES and whose dental offices were located in Vitória/ES were included, whereas those dentists who had either witnessed or been informed of another dentist's evaluation were excluded from the sample.

Patients undergoing treatment at the Integrated Clinic or in the dental offices visited by the researchers were included and assigned to their respective groups. Patients who had witnessed or been informed about the evaluation of another patient and those who had undergone any training or experience, or who had previously worked in the dental field were excluded.

Variable

To test the aesthetic perception of these professionals and lay persons a female patient was selected, who agreed to participate in the study after signing a form of informed consent. This patient had an aesthetic gingival margin in which the central incisors and canines were at the same height as the gingival margin, and whose lateral

incisors were 1 mm below the tangent that connected the gingival margin of these teeth.

Digital manipulation of the patient's smile was performed using Adobe Photoshop 7.0 by changing the height of the gingival margin of the lateral and central incisors. Changes were measured relative to the canines, which were therefore kept at a constant height. In the first alteration, the margin of the maxillary central incisor was reduced by 2 mm and the lateral incisor was increased by 0.5 mm in relation to the canines. In the second alteration, the margin of the maxillary central incisor was reduced by 4 mm and that of the lateral incisor was increased by 1.0 mm in relation to the canines. During manipulation, the chin and nose were deleted to avert confounding factors, so that only a portion of the patient's skin, her lips and teeth remained apparent.⁴

The evaluators were given an album with photos in the following order:

1. Harmonious gingival margin with the central incisors and canines at the same level, and lateral incisors 1 mm below the tangent between central incisors and canines (Fig 1).
2. Central incisors with margin 4 mm below the margin of the canines, and lateral incisors 1 mm above their original position, in an ascending aspect (Fig 2).
3. Central incisors with margin 2 mm below the margin of the canines, and lateral incisors 0,5 mm above their original position, in a flat aspect (Fig 3).

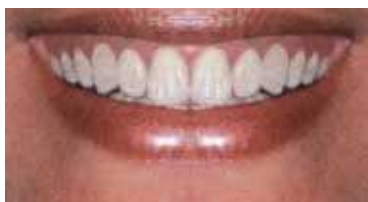

FIGURE 1 - Harmonious gingival margin.

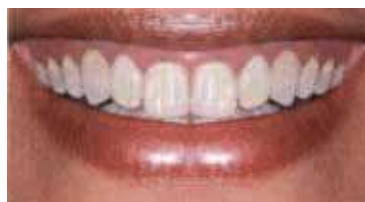

FIGURE 2 - Ascending gingival margin: Central incisors reduced by 4 mm and laterals increased by 1 mm.

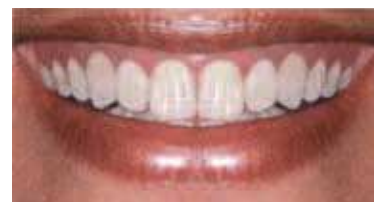

FIGURE 3 - Flat gingival margin: Central incisors reduced by 2 mm and laterals increased by 0.5 mm.

Data collection

After photo manipulation, two albums were created containing the photos that were printed in size 10X15 cm on photographic paper so as to ensure that both albums would be made in the same location and with the same quality.

From then on data collection was started through blind and standardized interviews where two researchers, each responsible for half of the sample from each specialty and lay group, paid visits to show the album.

The evaluators were asked to choose the picture that pleased them most and were thus given a choice of one, all or none, and 90 seconds to assess each picture without the possibility of seeing again any previous pictures. After that, the interviewer questioned each evaluator in an attempt to find out whether or not they perceived what was being changed in the sequence of pictures, i.e., if they were able to identify changes in the gingival plane, with the following question: "What do you think is being altered in these pictures?". Each response was noted but, in order to facilitate statistical data analysis, a "yes" was assigned when changes were perceived (any alteration in the gingival plane) and a "no" when the evaluator responded somewhat differently than expected. Up to 90 seconds were allowed for these questions.

The statistical analysis included descriptive and inferential analyses, using a 5% significance level. Associations between categorical variables were tested using chi-square or Fisher's exact tests.

RESULTS

As regards the selection of the photographs that most pleased the evaluator, in the lay group the choice fell predominantly on the harmonious gingival plane, indicating that differences between the smiles were indeed perceived ($p = 0.05$). Moreover, significant differences were also observed in the overall results exhibited by the groups ($p = 0.05$), with the group of private

patients more prevalent in choosing the harmonious gingival smile than UFES patients (Table 1). Percentage-wise, fewer people in both groups chose the ascending gingival plane, with a significant difference between groups (Table 1).

In the group of dentists there was also a significant prevalence in the selection of the harmonious gingival plane option ($p < 0.001$), no selection of the ascending gingival plane option while a low percentage opted for the flat gingival plane (Fig 1). A higher percentage of subjects in the groups of orthodontists and prosthodontists selected the harmonious gingival plane option without, however, any significant differences between the groups of dentists (Table 2 and Fig 4).

The results showed a statistically significant difference between the groups of dentists and lay persons ($p < 0.001$), indicating a higher aesthetic perception by the group of dentists (Table 3). Furthermore, selection of the harmonious gingival plane option was statistically higher in the group of dentists ($p = 0.01$), and selection of the ascending gingival plane option was observed only in the groups of patients, where a statistically significant difference was also found (Tables 2 and 3).

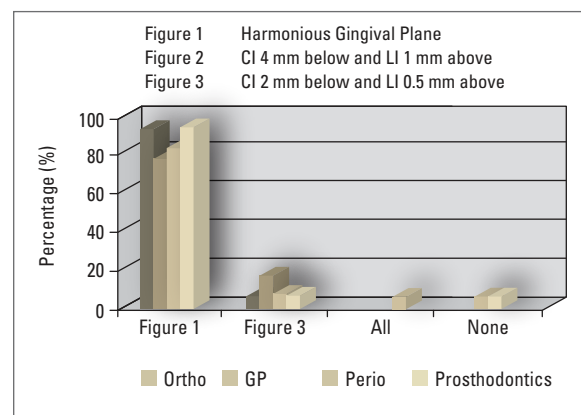


FIGURE 4 - Analysis of the group of dentists.

TABLE 1 - Dental office patients vs. UFES patients.

	Office Patients	UFES Patients	p-value
Harmonious	56.8%	31.1%	0.05
CI 4 mm below and LI 1 mm above	2.6%	18.4%	0.05
CI 2 mm below and LI 0.5 mm above	28.2%	21.6%	0.05
All	12.6%	26.3%	0.05
None	—	2.6%	0.05

TABLE 3 - Dentists vs Patients.

	Dentists	Patients	p-value
Harmonious	88.5%	44.2%	<0.001
CI 4 mm below and LI 1 mm above	—	10.4%	<0.001
CI 2 mm below and LI 0.5 mm above	7.7%	24.7%	<0.001
All	1.3%	19.5%	<0.001
None	2.6%	1.3%	<0.001

TABLE 2 - Analysis of the group of dentists.

	Orthodontists	General practitioners	Periodontists	Prosthodontists	p-value
Harmonious	95%	79%	84.2%	95%	0.538
CI 4 mm below and LI 1 mm above	—	—	—	—	0.538
CI 2 mm below and LI 0.5 mm above	5%	16%	5.3%	5%	0.538
All	—	—	5.3%	—	0.538
None	—	5.3%	5.3%	—	0.538

Identification of changes in gingival plane height

At this point in the interview the researchers wished to determine whether or not dentists and lay people were able to see the changes made in the photos. The chi-square test was performed to measure statistically significant associations between the groups. Statistically significant results were found regarding identification of the presence of a non-harmonious gingival plane in the group of dentists (58.8%, $p < 0.001$). Percentage-wise, prosthodontists were more vigilant in this identification than other groups of dentists, although no statistical significance was found in this group ($p = 0.385$) (Figs 5 and 6).

Values for problem identification in the lay group were not significant (25%, $p = 0.100$), but a significant difference was found between the group of private practice patients and UFES patients ($p = 0.010$) (Table 1 and Fig 6). The difference between the group of dentists and the lay group was statistically significant ($p < 0.001$) (Table 2 and Fig 5).

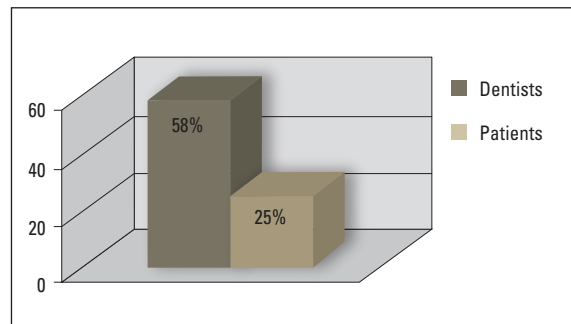


FIGURE 5 - Identification of changes in Gingival Plane height: Dentists vs. Patients.

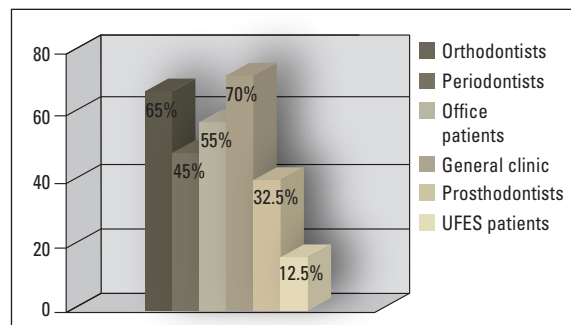


FIGURE 6 - Identification of changes in Gingival Plane height: Evaluation of the groups of Patients and Dentists.

DISCUSSION

The orthodontist's role in the correction and improvement of gingival aesthetic problems has not been adequately explored as it should have been. An innovative approach should be disseminated across all areas of dentistry so that all specialties are made aware of the possibility of achieving aesthetic improvements in gingival contour as well as biological improvements in support tissues by means of orthodontic treatment.²

With the purpose of assessing patients' expectations and the amount of discrepancy in abnormal symmetrical changes made to the gingival plane, a study was conducted which introduced progressive 0.5 mm to 1.5 mm changes in the position of lateral incisors, and concluded that these were not perceived by dentists nor lay persons. This study raised a debate on the possibility that these symmetrical changes are beyond perception at all levels.⁶

The present study, however, demonstrated that changes starting at a 2 mm decrease and a 0.5 mm increase, symmetrically applied to central and lateral incisors, respectively, by modifying the gum contour, would be significantly noticeable to lay people and dentists of all specialties investigated in this study, corroborating other findings in the literature^{1,4,9} and showing that changes in the anterior region, including at the gingival level, would be perceived by most dentists and patients. In the group of dentists, as well as a significant prevalence in the selection of the harmonious gingival plane option ($p < 0.001$), no selection of the ascending gingival plane option was made. Similarly, the significant prevalence of the harmonious smile option and low percentage rates of the options "all" and "no" in the group of lay patients showed that there is indeed the perception of changes in the gingival plane starting from this level of manipulation.

According to the literature symmetrical changes would only be noticeable in large mag-

nitudes.⁷ However, changes made in more than one tooth, which generate a conspicuously unsightly gingival contour,^{1,3} become visible starting from 2 mm. In fact, the reverse gingival margin plane, with its ascending form, is significantly unsightly in the opinion of lay individuals.¹⁰ On the other hand, asymmetrical changes become visible at much lower levels by dentists and lay persons alike.⁷

When it comes to identifying changes in the gingival plane a significant identification by dentists was observed, although with no statistically significant difference among the different specialty groups. In addition, the group of dentists was statistically more perceptive in identifying the changes than the group of lay persons. In the patient group identification was not statistically significant, but it was significantly higher in dental office patients. By the same token, from a statistical standpoint, the latter group predominantly selected the harmonious gingival margin option during the first part of the interview, demonstrating that these patients are more aware and demanding than patients from public institutions in terms of changes in the gingival plane.

These findings showed that symmetrical changes equal to or greater than 2 mm deserve special attention by orthodontists in their daily practice as they are identified as unsightly by the patient, especially in private practice, although the patient is not always capable of defining the problem. Moreover, the dentist who referred such patient can perceive and understand changes in the gingival plane, knowing that such changes can be corrected. Therefore, the options for orthodontic correction of these differences in the gingival margin should be presented cautiously since neglecting these issues might be construed as a treatment failure.

Although the present study shows that patients prefer harmonious gingival margins, it is not clear whether the correction of changes in

the gingival margin would be among the initial expectations of the patient seeking orthodontic treatment, or even if it would be a differentiating factor that could lead him/her to seek treatment. Further studies are required to shed light on these issues.

CONCLUSIONS

The authors concluded that for the population researched in this study:

» Symmetrical changes in the gingival plane

greater than 2 mm can be perceived by dentists and lay people.

- » Dentists were significantly more perceptive to the changes in the gingival plane than lay patients.
- » No differences were found in the perception of the gingival plane among the dental specialties investigated in this study.
- » The group of dental office patients was significantly more perceptive than UFES patients.

REFERENCES

1. Caudill R, Chiche G. Princípios científicos e artísticos aplicados à Odontologia estética. In: _____. Estabelecendo uma aparência gengival estética. 1ª ed. São Paulo: Quintessence Books; 1996. p. 13-32.
2. Chay SH, Rabie AB. Repositioning the gingival margin by extrusion. *Am J Orthod Dentofacial Orthop.* 2002 Jul;122(1):95-102.
3. Chiche G, Kokich V, Caudill R. Diagnosis and treatment planning of esthetic problems In: Pinault A, Chiche G, editors. *Esthetics in fixed prosthodontics.* Quintessence, 1994. p. 33-52.
4. Dong JK, Jin TH, Cho HW, Oh SC. The esthetics of the smile: a review of some recent studies. *Int J Prosthodont.* 1999 Jan-Feb;12(1):9-19.
5. Johnston CD, Burden DJ, Stevenson MR. The influence of dental to facial midline discrepancies on dental attractiveness ratings. *Eur J Orthod.* 1999 Oct;21(5):517-22.
6. Kokich VO Jr, Kiyak HA, Shapiro PA. Comparing the perception of dentists and lay people to altered dental esthetics (reprint). *Advanced Esthetics Interdisciplinary Dent.* 2005;1(1):20-33.
7. Kokich VO, Kokich VG, Kiyak HA. Perceptions of dental professionals and laypersons to altered dental esthetics: Asymmetric and symmetric situations. *Am J Orthod Dentofacial Orthop.* 2006 Aug;130(2):141-51.
8. Sarver DM, Yanosky M. Principles of cosmetic dentistry in orthodontics: Part 2. Soft tissue laser technology and cosmetic gingival contouring. *Am J Orthod Dentofacial Orthop.* 2001;127(2):127-85.
9. Soh J, Chew MT, Chan YH. Perceptions of dental esthetics of Asian orthodontists and laypersons. *Am J Orthod Dentofacial Orthop.* 2006 Aug;130(2):170-6.
10. Yoon ME, Jin TH, Dong JK. A study on the smile in Korean youth. *J Korean Acad Prosthodont.* 1992 Aug;30(2):259-71.

Submitted: May 2007
Revised and accepted: August 2008

Contact address
Daniela Feu
Rua Moacir Ávidos; nº 156/ apto 804
CEP: 29.055-350 – Praia do Canto, Vitória / ES, Brazil
E-mail: danifeutz@yahoo.com.br