

# Serial extraction: Variables associated to the extraction of premolars

Tulio Silva Lara\*, Cibelle Cristina Oliveira dos Santos\*\*, Omar Gabriel da Silva Filho\*\*\*, Daniela Gamba Garib\*\*\*\*, Francisco Antônio Bertoz\*\*\*\*\*

## Abstract

**Objective:** To determine the frequency of patients who require extraction of permanent premolars among those treated with extraction of deciduous teeth for the correction of incisor crowding in the mixed dentition and analyze possible associated variables. **Methods:** The sample was composed of orthodontic records of 70 patients with permanent dentition whose treatment had begun in the mixed dentition phase and involved serial extraction. All records were analyzed by a single examiner to determine whether serial extraction had been performed with extraction of permanent teeth or only deciduous teeth. Associations were investigated between extraction of permanent teeth and lateral facial pattern, sagittal relationship of the dental arches, incisor-mandibular plane angle, size proportion of mandibular second molar/retromolar space, mechanics for space control and tooth-arch size discrepancy (Fisher's exact test for categorical variables and logistic regression for numeric variables,  $p < 0.05$ ). **Results:** Among the patients who had been treated with extraction of deciduous teeth, 70% required the extraction of permanent teeth. The statistical analysis revealed no significant associations between the analyzed variables and the need for permanent tooth extraction, with the exception of tooth-arch size discrepancy. **Conclusion:** Tooth-arch size discrepancy was the main factor determining premolar extraction in a serial extraction program.

**Keywords:** Malocclusion. Mixed dentition. Serial extraction.

**How to cite this article:** Lara TS, Santos CCO, Silva Filho OG, Garib DG, Bertoz FA. Serial extraction: Variables associated to the extraction of premolars. *Dental Press J Orthod*. 2011 Sept-Oct;16(5):135-45.

» The authors report no commercial, proprietary, or financial interest in the products or companies described in this article.

\* PhD in Orthodontics, Araçatuba Dental School – UNESP. Professor, Preventive Orthodontics course, PROFIS. Orthodontist, Craniofacial Anomalies Rehabilitation Hospital – USP/FUNCRAF.

\*\* Specialist in Preventive and Interceptive Orthodontics, PROFIS. Specialist in Orthodontics, Craniofacial Anomalies Rehabilitation Hospital (HRAC-USP).

\*\*\* Head of Preventive and Interceptive Orthodontics course, PROFIS. Orthodontist, HRAC-USP. Professor, Orthodontics Specialization course, PROFIS.

\*\*\*\* Professor of Orthodontics, Department of Pediatric Dentistry, Orthodontics and Collective Health, HRAC-USP and Bauru Dental School.

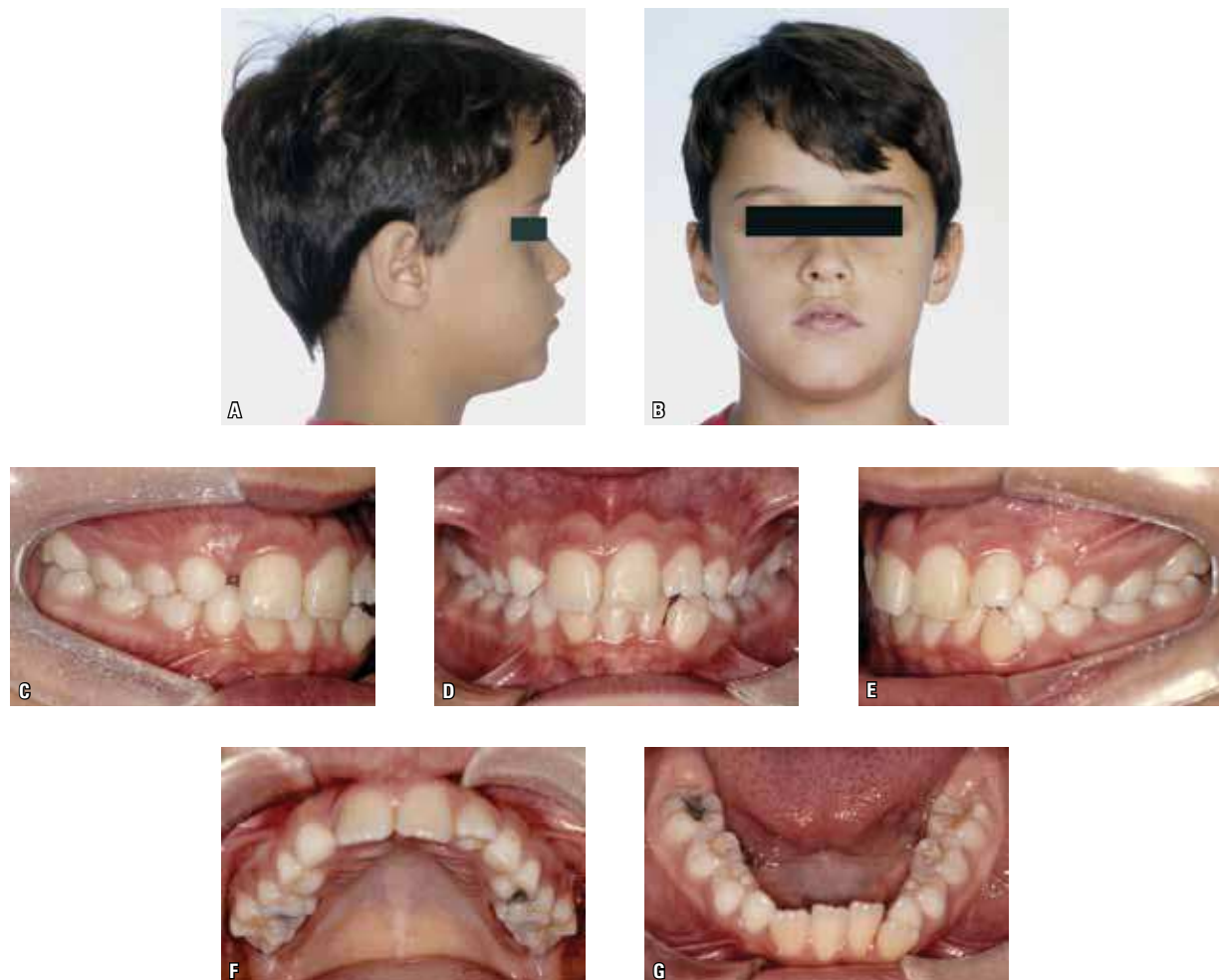\*\*\*\*\* Full Professor of Preventive Orthodontics course and Postgraduation in Orthodontics, Araçatuba Dental School – UNESP.

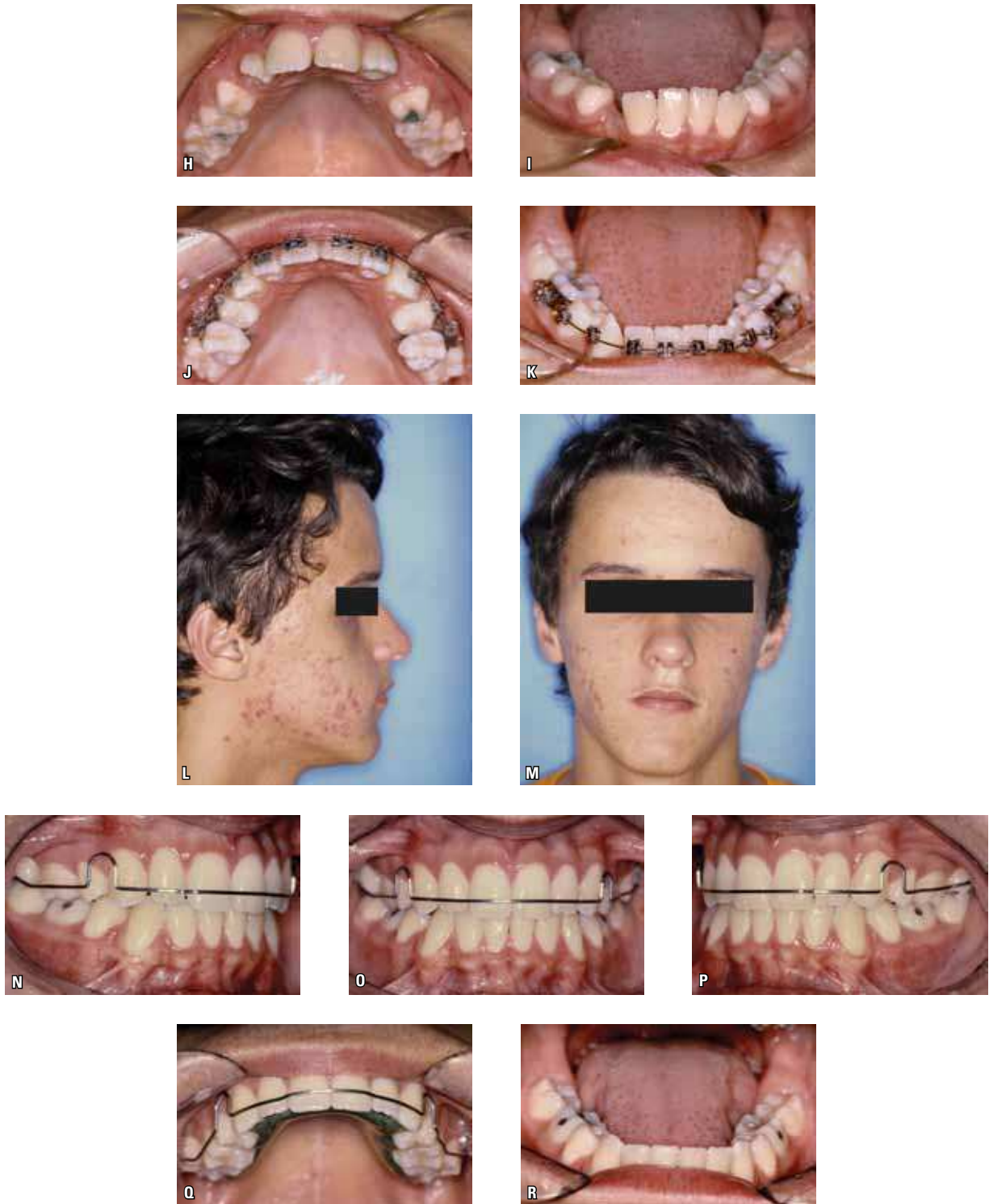## INTRODUCTION

From the orthodontic point of view, crowding of deciduous teeth requires solid, coherent treatment, as it affects approximately 50% of children in the mixed dentition phase.<sup>14</sup> Crowding is a dental irregularity caused by a negative tooth-bone discrepancy. A greater degree of crowding increases the chances of treatment involving a reduction in dental mass.<sup>15,17</sup>

Correction of crowding in the mixed dentition through tooth reduction is achieved through a serial extraction.<sup>4,6,7,16</sup> As its name suggests, serial extraction is the correction of mixed dentition crowding through the strategically programmed

extraction of deciduous and permanent teeth (in that order) for the alignment of the remaining teeth (Fig 1) and foresees extractions in two distinct phases. In the first transitory period, the extraction of anterior deciduous teeth is indicated in order to allow the alignment of the permanent incisors, preferably without orthodontic mechanics. The second phase may or may not be performed and coincides with the second transitory period of the mixed dentition. This phase involves the extraction of permanent teeth (generally the first premolars), which aims at correcting the crowding of the posterior segment, canines and premolars.<sup>16</sup>



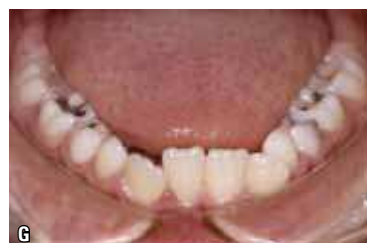
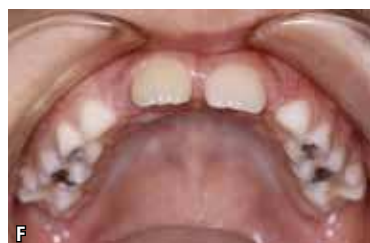
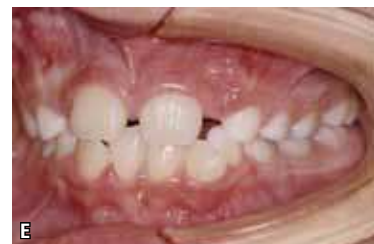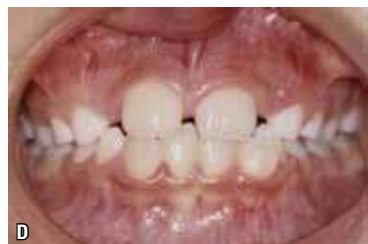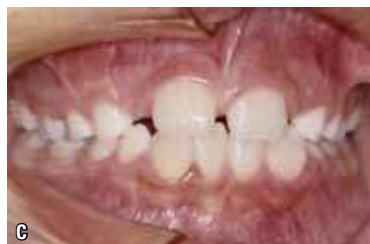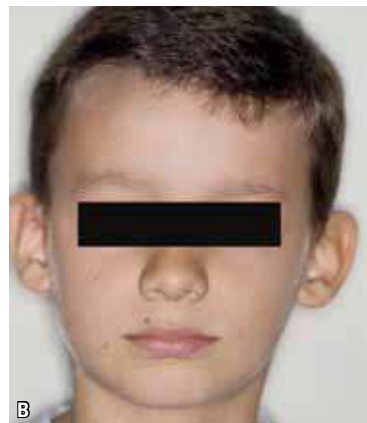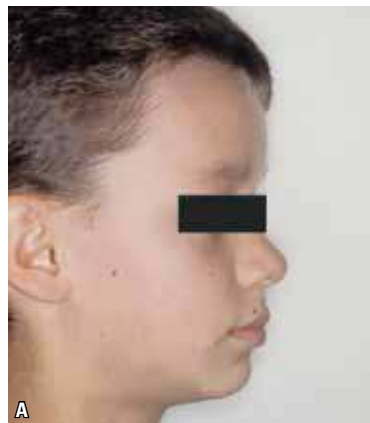**FIGURE 1** - Patient treated with serial extraction orthodontic mechanics. First phase of serial extraction involved extraction of deciduous canines in the first transitory period of mixed dentition. Second phase involved extraction of first premolars in second transitory period. **A)** Profile initial photograph. **B)** Frontal initial photograph. **C, D, E)** Intraoral initial photographs. **F, G)** Occlusal initial views. **H, I)** Occlusal views after deciduous canines extraction. **J, K)** First premolars extracted and fixed orthodontic treatment. **L)** Final profile photograph. **M)** Final frontal photograph. **N, O, P)** Final intraoral photographs with Hawley retainer. **Q, R)** Occlusal final views.

Serial extraction does not necessarily involve the extraction of permanent teeth (Fig 2). Thus, the first extraction phase is known as the reversible phase. The need for the extraction of premolars (nearly always the first premolars) should be assessed after their eruption. In principle, one may deduce that a greater proximity between the permanent lateral incisor and the primary first molar leads to a greater tooth-bone discrepancy and greater likelihood of the extraction of permanent teeth, which is the irreversible phase of serial extraction. In the early mixed dentition

phase, it is not always possible to decide whether or not the premolars will be extracted. Moreover, there is a question as to the percentage of patients that undergo the first serial extraction phase without requiring the extraction of permanent teeth.

The aim of the present study was to determine the percentage of patients initially treated with serial extraction who went through to the irreversible phase (extraction of permanent teeth) and determine possible variables associated to the second phase of treatment.



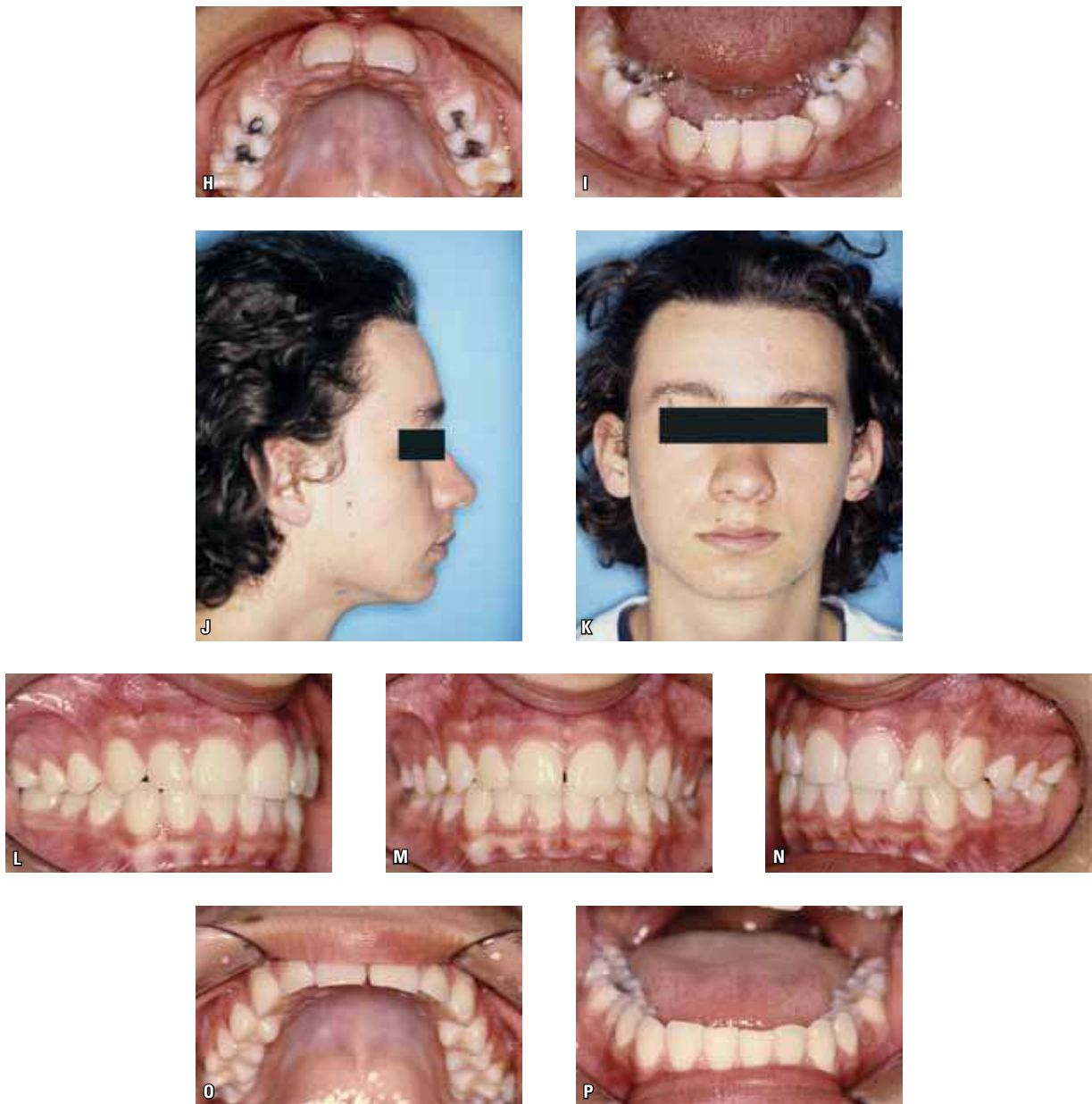

FIGURE 2 - Patient having undergone only extraction of deciduous teeth (reversible phase). The second phase of the serial extraction program was not performed. The patient used headgear at the end of mixed dentition phase, with partial leveling of permanent dentition. **A)** Profile initial photograph, **B)** Frontal initial photograph, **C, D, E)** Intraoral initial photographs. **F)** Initial upper occlusal view. **G)** Initial lower occlusal view. **H, I)** Occlusal views after deciduous canine extractions. **J, K)** Profile and frontal final photographs. **L, M, N)** Final intraoral photographs. **O, P)** Occlusal final views.

## MATERIAL AND METHODS

### Material

A retrospective study was carried out involving the orthodontic records of 70 patients (38 males and 32 females) from the archives of the Profis

Preventive and Interceptive Orthodontics Course (Bauru, SP, Brazil). The patients were selected based on the treatment plan. All had an initial treatment plan of serial extraction and had mature permanent dentition (second permanent mo-

lars erupted) at the time the study was conducted. The following were the inclusion criteria: Crowding at the time of diagnosis; no agensis, with the exception of third molars; absence of interproximal caries that could compromise tooth width or arch length; and orthodontic records with good quality (panoramic radiographs, lateral cephalometric radiographs, plaster models, facial profile photographs). Age of the sample ranged from 8 years and 1 month to 13 years and 11 months.

### Methods

The records of the 70 patients were carefully analyzed by a single examiner for the determination of the percentage of patients who completed the irreversible serial extraction phase (extraction of first premolars). For such, the following variables were investigated to determine whether they were associated to the extraction of permanent teeth:

#### 1) Facial pattern in normolateral position:

The patients were classified as having Patterns I, II or III and divided into two groups: Patterns I and II (Group 1) and Pattern III (Group 2). As a non-significant number of patients had the Long Face pattern, these patients were excluded from the facial pattern analysis. No Short Face pattern was found in the sample.

#### 2) Classification of malocclusion in Classes I, II and III based on the relation of primary canines.

#### 3) Position of lower incisors in symphysis:

Quantified on normolateral radiographs by measuring the incisor-mandibular plane angle (IMPA).

#### 4) Proportion between size of lower second permanent molar and retromolar space:

Panoramic radiographs with dates as close as possible to the time of extraction of the first premolars (if indicated) and those corresponding to patients who were not submitted to premolar extraction were selected.

For the measurement of the retromolar space, a horizontal line was drawn from the tip of the

distal cuspid of the permanent first molar to the retromolar space. A perpendicular line was then drawn from this line on the distal tip of the first molar. A ruler was placed over the anterior limit of the ramus of the mandible in such a way as to touch the greatest number of points on this structure and a third line was drawn, representing the anterior limit of the ramus. The retromolar space was measured as the distance between the line drawn on the distal tip of the first permanent molar and the line representing the ramus of the mandible (Fig 3). This measurement was performed on both the right and left sides. The mesiodistal length of the second molar was measured with a ruler, considering the longest distance between the mesial and distal faces of this tooth.

The proportion between the size of the second permanent molar and the retromolar space was determined by dividing the mesiodistal length of the second molar by the retromolar space on both the right and left sides.

The measurements of the IMPA, retromolar space (both on the cephalometric radiograph) and mesiodistal length of the second molar (panoramic radiographs) were performed by a single, calibrated examiner with the aid of an X-ray viewer in a dark room. The tracings of the lines on the panoramic radiographs were performed with a 0.5 mm graphite pencil, ruler and protractor.

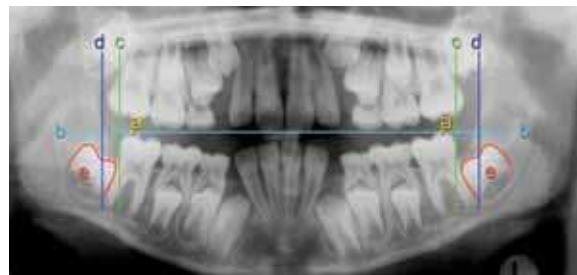


FIGURE 3 - Tracing on panoramic radiograph showing reference lines used to measure retromolar space; (a) tip of distal cusp of first molar; (b) horizontal line drawn from tip of distal cusp of first molar to retromolar space; (c) line perpendicular to horizontal line; (d) line from anterior limit of mandibular ramus; (e) radiographic image of the second permanent molar.

### 5) Use of orthodontics mechanics during serial extraction:

For this variable, three treatment options received codes from 1 to 3: (1) mechanics for space gain; (2) mechanics for space maintenance; and (3) absence of orthodontic treatment during serial extraction.

### 6) Model discrepancy:

Model discrepancy was calculated considering existing space and the space required for the accommodation of all teeth. The existing space was calculated considering three segments measured with a digital caliper (Precision Equipment CO, Boston, MA, USA): Mesial of first permanent molar to distal of lateral incisor, right and left sides, and distal to distal of the lateral incisor. The calculation of space required was performed by measuring the width of the lower incisors directly on the model. The estimate of the mesiodistal width of the teeth of the posterior segment was performed using the Tanaka-Johnston formula for the lower arch:<sup>19</sup>

$X = (Y/2 + A) \times 2$ , where:

- » X is the length of the canines and non-erupted premolars;
- » Y is the width of the four lower incisors;
- » A is the constant for the lower arch (75% probability) equal to 10.5 mm.

### Statistical analysis

Fisher's exact test was used to determine associations between premolar extraction and each of the categorical variables (univariate analysis).<sup>1</sup> A logistic regression model was used for the numeric variables.<sup>10</sup>

## RESULTS

Seventy percent of the patients with serial extraction in the initial treatment plan required the complete treatment with extraction of premolars. The other 30% only required the reversible phase of the program (extraction of deciduous teeth only). There were no statistically significant

associations between the need for the extraction of permanent teeth and the variables studied, with the exception of model discrepancy in the posterior segment (Tables 1 and 2; Fig 4). Due to the absence of some models for the analysis, only 57 patients were assessed for the calculation of model discrepancy. If the initial mean model discrepancy was greater than -6.69 mm (Table 2), the patient was expected to require the extraction of premolars in the serial extraction.

## DISCUSSION

The early extraction of deciduous lateral incisors and canines and subsequent extraction of first premolars favors the spontaneous alignment of the other teeth in the alveolar crest in the period of mixed dentition.<sup>21</sup> This simplifies the corrective mechanics for the permanent dentition and is the principle of serial extraction.<sup>7,16</sup> At times, corrective orthodontics is not even necessary for the finishing of the case.

The total duration of treatment is significantly greater for patients who undergo serial extraction, considering the number of appointments and time in which the development of the occlusion is followed.<sup>20</sup> However, the advantages are related to the self-esteem of children who see their teeth aligned at an early age, with the periodontal condition of teeth erupting spontaneously in the center of the alveolar ridge.

In the present sample, 70% of the patients indicated for serial extraction continued through to premolar extraction, whereas the other 30% only underwent the first phase of the treatment (extraction of deciduous teeth). A number of variables were investigated to determine likely factors that influenced premolar extraction.

Crowding is manifested independently from the sagittal condition between bone bases, and the skeletal pattern affects how an orthodontist considers the crowding, with lower crowding occurring more in patients with a Pattern II face and upper crowding occurring more in those with Pattern III, at least

TABLE 1 - Distribution of patients in need of extraction of deciduous teeth (reversible phase) and permanent teeth (irreversible phase) according to facial pattern, occlusion classification, IMPA, proportion of second permanent molar/retromolar space and orthodontic mechanics.

Variable (Statistical Analysis)	Treatment phase				Total	(%)	p value
	Irreversible	(%)	Reversible	(%)			
<b>Facial Pattern (Fisher's Exact Test)</b>							
I and II	44	(69)	20	(31)	64	(100)	p=0.6607
III	5	(83)	1	(17)	6	(100)	
Total	49	(70)	21	(30)	70	(100)	
<b>Classification (Fisher's Exact Test)</b>							
I	25	(69)	11	(31)	36	(100)	p=1.000
II	22	(69)	10	(31)	32	(100)	
III	2	(100)	-	-	2	(100)	
Total	49	(70)	21	(30)	70	(100)	
<b>IMPA (Simple Regression Logistic)</b>							
< 80	8	(73)	3	(27)	11	(100)	p=0.1221
80  --- 90	25	(81)	6	(19)	31	(100)	
> 90	16	(57)	12	(43)	28	(100)	
Total	49	(70)	21	(30)	70	(100)	
<b>Proportion second permanent molar/left retromolar space (Simple Regression Logistic)</b>							
< 1	12	(60)	8	(40)	20	(100)	p=0.677
1  --- 1.4	27	(79)	7	(21)	34	(100)	
1.4 or +	10	(63)	6	(38)	16	(100)	
Total	49	(70)	21	(30)	70	(100)	
<b>Proportion second permanent molar/left retromolar space (Simple Regression Logistic)</b>							
< 1	15	(65)	8	(35)	23	(100)	p=0.540
1  --- 1.4	24	(73)	9	(27)	33	(100)	
1.4 or +	10	(71)	4	(29)	14	(100)	
Total	49	(70)	21	(30)	70	(100)	
<b>Used Mechanics (Fisher's Exact Test)</b>							
(1) Space Gain	28	(62)	17	(38)	45	(100)	p=0.079
(2) Space Maintenance	8	(100)	-	-	8	(100)	
(3) Absence of Orthodontic Treatment during SEP	13	(76)	4	(24)	17	(100)	
Total	49	(70)	21	(30)	70	(100)	

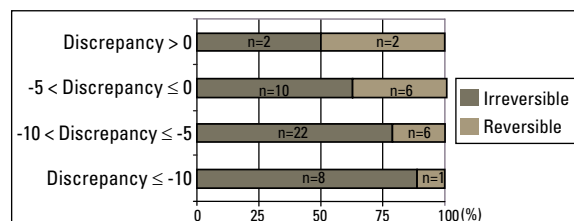


FIGURE 4 - Magnitude of model discrepancy between groups with premolar extraction (irreversible phase) and non-extraction (reversible phase).

TABLE 2 - Mean and standard deviation of tooth-arch size discrepancy in both groups of patients.

	N	Mean	Standard Deviation
Irreversible	42	-6.69	3.44
Reversible	15	-3.58	5.16
<b>Total</b>	<b>57</b>	<b>-5.87</b>	<b>4.15</b>

p=0.02\* (Logistic Regression Model).



in compensatory treatment. It is expected that patients with Pattern II would extract fewer lower teeth in relation to patients with Pattern III in order to compensate for the malocclusion and not further increase overjet. For this reason, facial pattern was studied in the present investigation.

Curiously, the sagittal relationship of the dental arches had no statistically significant influence over the decision to extract premolars. It is likely that facial pattern is more decisive in borderline cases in which there is a deadlock in the second phase serial extraction. With Pattern II accompanied by Class II, Division 1 malocclusion, one must also consider the atresia of the upper dental arch, which can be expanded, especially in treatment involving the orthopedic advancement of the mandible.<sup>18</sup> In the present study, patients with Patterns I and II were grouped together for the statistical analysis and there was a small number of patients with Pattern III (n=6). A study with a broader sample involving the three facial patterns may identify differences in the prevalence of premolar extractions during serial extraction.

Despite the statistically significant result reported here, the treatment for malocclusions is planned for each patient individually based on specific morphological characteristics.<sup>13</sup> An incorrect planning, with teeth extractions, could result in an unpleasing facial profile, affecting the esthetics of both the smile and face.<sup>12</sup> In the present study, there were no statistically significant differences in relation to malocclusion class between patients who only underwent the first phase of serial extraction and those who went through to the irreversible phase.

There was no significant association between protrusion of the lower incisors (assessed here by the IMPA) and the need for premolar extraction, even considering that protruded profiles are more favorable to tooth extraction.<sup>12</sup> Patients with an  $IMPA > 90^\circ$  were evenly distributed between the reversible phase (43%) and irreversible phase (57%). From the facial profile analysis, none of

the patients were considered to exhibit bimaxillary protrusion. It is possible that the protrusion identified in this analysis is more associated to candidates for tooth extraction than the analysis of IMPA alone.

The assessment of the retromolar spaces is important in treatment planning with the aim of having erupted permanent second molars in occlusion. In the present study, the proportion between the size of the second permanent molar and retromolar space did not have a statistically significant association with the decision to extract the premolars (Table 1). It is likely that the analysis of the retromolar space acquires importance in individual planning. In borderline cases, in which there is a risk of impaction of a second molar through the use of a lip bumper due to the limitation of the retromolar space, extraction is the best treatment option.

Appliances such as a Haas expander for the upper arch and a lip bumper for the lower arch are indicated for the definite correction of crowding when the arch is atretic. These appliances provide a more adequate morphology for the dental arches as well as space for the alignment of the teeth. The Nance lingual arch can preserve space in the posterior segment that would otherwise be spontaneously lost with the alignment of the erupting permanent teeth. The Leeway space, together with the dimensional alterations of the mixed dentition, helps to provide space to resolve crowding in the mixed dentition.<sup>8,9</sup> In a study involving 107 patients with crowding of the lower incisors, the Nance lingual arch proved to be effective in maintaining the length of the arch during the transition from the mixed to the permanent dentition.<sup>5</sup> Following treatment with the lingual arch, the space for alleviating the crowding proved to be sufficient in 60% of patients who had mean crowding of 4.85 mm prior to treatment.

For cases of severe crowding in the mixed dentition, the expansion approach has currently given way to serial extraction.<sup>17</sup> In borderline

cases, appliances may be indicated to preserve or gain space. An orthodontist may encounter atretic dental arches even in cases of severe crowding, which suggests the need for transversal mechanics despite tooth extraction. For this reason, the presence of orthodontic mechanics jointly with serial extraction was investigated on the patient records. The results reveal that the use of appliances had no influence over the decision regarding premolar extraction.

Tooth-arch size discrepancy (degree of initial crowding) was the only variable with a statistically significant correlation to premolar extraction. Thus, identifying the amount of error in the intra-arch relation is the primary aspect in the planning for serial extraction. The mean discrepancy for the group that underwent premolar extraction was -6.69 mm, whereas the discrepancy in the group that only underwent the first phase of serial extraction was -3.58 mm, as determined by the Tanaka-Johnston<sup>19</sup> formula for estimating the mesiodistal width of the teeth in the posterior segment. This difference was statistically significant ( $p = 0.02$ ). Thus, a greater initial tooth-arch size discrepancy signifies a greater chance of undergoing the irreversible phase of serial extraction (Table 2). The literature reports that patients

treated with premolar extraction exhibit greater tooth-bone discrepancy.<sup>3</sup> Thus, as demonstrated by the present investigation and previous studies, the degree of tooth-bone discrepancy seems to be a factor of considerable clinical importance (although not the only factor) to the decision as to whether to extract the premolars.<sup>2,3,11</sup>

## CONCLUSIONS

The majority of patients (70%) with an initial plan for serial extraction to resolve crowding completed the entire procedure with the extraction of permanent teeth.

Facial pattern, sagittal relation between the dental arches, IMPA, proportion of second permanent molar/retromolar space and orthodontic treatment during serial extraction had no statistically significant association to the need for premolar extraction.

The tooth-arch size discrepancy (degree of crowding) was significantly associated to the need for premolar extraction ( $p=0.02$ ).

The mean discrepancy was -6.69 mm in the group that underwent premolar extraction and -3.58 mm in the group that only underwent the first phase of serial extraction (only extraction of primary teeth).

## REFERENCES

1. Agresti A. *Categorical Data Analysis*. New York: Wiley; 1990.
2. Baumrind S, Korn EL, Boyd RL, Maxwell R. The decision to extract: part 1 - interclinician agreement. *Am J Orthod Dentofacial Orthop*. 1996;109(3):297-309.
3. Bishara SE, Cummins DM, Zaher AR. Treatment and post-treatment changes in patients with Class II division 1 malocclusion after extraction and nonextraction treatment. *Am J Orthod Dentofacial Orthop*. 1997;111(1):18-27.
4. Boley JC. Serial extraction revisited: 30 years in retrospect. *Am J Orthod Dentofacial Orthop*. 2002;121(6):575-7.
5. Brennan MM, Gianelly AA. The use of the lingual arch in the mixed dentition to resolve incisor crowding. *Am J Orthod Dentofacial Orthop*. 2000;117(1):81-5.
6. Bronzi E, Ramalli EL, Pugliesi E, Paulin RF. Extração seriada: uma alternativa. *Rev Dental Press Ortod Ortop Facial*. 2002;7(5):65-72.
7. Dale JG. Serial extraction... nobody does that anymore! *Am J Orthod Dentofacial Orthop*. 2000;117(5):564-6.
8. Gianelly AA. Crowding: timing of treatment. *Angle Orthod*. 1994;64(6):415-8.
9. Gianelly AA. Treatment of crowding in the mixed dentition. *Am J Orthod Dentofacial Orthop*. 2002;121(6):569-71.
10. Hosmer DR, Lemeshow S. *Applied logistic regression*. New York: John Wiley & Sons; 1989.
11. Howe RP, McNamara JA Jr, O'Connor KA. An examination of dental crowding and its relationship to tooth size and arch dimension. *Am J Orthod*. 1983;83(5):363-73.
12. Isic F, Sayinsu K, Nalbantgil D, Arun T. A comparative study of dental arch widths: extraction and non-extraction treatment. *Eur J Orthod*. 2005;27(6):585-9.
13. McNamara JA. Maxillary transverse deficiency. *Am J Orthod Dentofacial Orthop*. 2000;117(5):567-70.
14. Silva Filho OG, Freitas SF, Cavassan AO. Prevalência de oclusão normal e má oclusão em escolares da cidade de Bauru (São Paulo). Parte I: relação sagital. *Rev Odontol Univ São Paulo*. 1990;4(2):130-7.
15. Silva Filho OG, Garib DG, Freire-Maia BA, Ozawa TO. Apinhamento primário temporário e definitivo: diagnóstico diferencial. *Rev Assoc Paul Cir Dent*. 1998;52(1):75-81.
16. Silva Filho OG, Ozawa TO, Almeida AM, Freitas PZ. Programa de extrações seriadas: uma visão ortodôntica contemporânea. *Rev Dental Press Ortod Ortop Facial*. 2001;6(2):91-108.
17. Silva Filho OG, Garib DG. Apinhamento: diagnóstico e tratamento na dentadura mista. In: Lubiana NF, Silva Filho OG, Garib DG. *PRO-ODONTO/Ortodontia Programa de Atualização em Ortodontia. Ciclo 1 módulo 3*. Porto Alegre: Artmed; 2007. p. 9-56.
18. Silva Filho OG, Ferrari FM Junior, Ozawa TO. Dental arch dimensions in Class II division 1 malocclusions with mandibular deficiency. *Angle Orthod*. 2008;78(3):466-74.
19. Tanaka MM, Johnston LE. The prediction of the size of unerupted canines and premolars in a contemporary orthodontic population. *J Am Dent Assoc*. 1974;88(4):798-801.
20. Wagner M, Berg R. Serial extraction or premolar extraction in the permanent dentition? *J Orofac Orthop*. 2000;61(3):207-16.
21. Yoshihara T, Matsumoto Y, Suzuki J, Sato N, Oguchi H. Effect of serial extraction alone on crowding: Spontaneous changes in dentition after serial extraction. *Am J Orthod Dentofacial Orthop*. 2000;118(6):611-6.

Submitted: November 18, 2008  
 Revised and accepted: March 13, 2009

**Contact address**

Tulio Silva Lara  
 Rua Rio Branco, 20-81 - Altos da Cidade  
 CEP: 17.014-037 - Bauru/SP, Brazil  
 E-mail: tuliolar@hotmai.com