

# A method to re-treat the relapse of dental misalignment

David Normando\*, Leopoldino Capelozza Filho\*\*

## Abstract

The clinician should expect some loss of the dental alignment obtained during orthodontic therapy in the long term in cases in which the orthodontic retainer has been removed by the orthodontist or lost by the patient. In this situation, patients are often reluctant to wear braces again to re-treat anterior misalignment. This report describes the successful use of a simple and effective technique to correct mild changes in the incisor alignment after orthodontic treatment. An innovative and low cost procedure effectively solved the relapse of anterior misalignment in 1-2 months. The force used to realign the teeth is obtained through the use of a clear elastomeric thread tied to multistranded upper and lower retainers.

**Keywords:** Tooth movement. Orthodontic appliances. Incisor. Relapse.

**How to cite this article:** Normando D, Capelozza Filho L. A method to re-treat the relapse of dental misalignment. Dental Press J Orthod. 2011 Sept-Oct;16(5):48-53.

» The authors report no commercial, proprietary, or financial interest in the products or companies described in this article.

\* Professor of Orthodontics, School of Dentistry - UFPA. Coordinator of the Specialization Program in Orthodontics, ABO-PA. MSc in Integrated Clinic, FOUSP. PhD in Orthodontics, Rio de Janeiro State University (UERJ). Specialist in Orthodontics, PROFIS-USP/Bauru.

\*\* PhD Professor, Bauru Dental School, University of São Paulo (USP). Member of the Orthodontic Division of the HRAC-USP.

## INTRODUCTION

Follow-up studies of treated cases have shown that although ideal occlusion and dental alignment have been achieved, there is a tendency for post-treatment relapse toward the original malocclusion.<sup>1-4</sup> Furthermore, patient's satisfaction is moderately associated with the stability of the orthodontic treatment<sup>5</sup> while the use of retainers is one important factor related to treatment stability.<sup>4</sup> Therefore, preserving dental alignment can contribute to a higher level of satisfaction in patients who have undergone orthodontic treatment.

The most effective way to re-treat mandibular anterior crowding or spacing after retention requires the use of brackets and archwires. However, patients are often reluctant to wear braces again for the purpose of aligning the affected teeth. Several alternatives have been proposed for tooth realignment, which may involve the use of an active removable appliance,<sup>6-10</sup> retention with lingual spurs<sup>11</sup> or the use of nickel-titanium archwires as retention devices.<sup>12</sup> An innovative technique that involves an already installed retainer and a clear elastomeric solid thread is presented in this paper.

## TECHNIQUE PRESENTATION

The use of fixed lower retainers is a routine in the orthodontic clinic<sup>14</sup> and its efficiency has been widely reported in the orthodontic literature.<sup>4,13</sup> However, the use of fixed upper retainers does not seem as popular among orthodontists. Thus, orthodontists routinely make use of a removable Hawley plate to retain the alignment of the upper dental arch, while for the lower arch bonded 3X3 retainer seems to be the first option.<sup>14,15</sup> This choice seems to be based on the fact that relapse seems less frequent in the upper arch compared to the lower;<sup>1,4</sup> it is also difficult to maintain the stability of the retainer bonded to the upper teeth because of the vertical overbite and of

the fracture risks due to incisal contact during mastication. Although misalignment is more frequent in the lower arch, it seems reasonable to believe that the instability of the upper arch causes more dissatisfaction for the patient, specially in cases where there is more esthetical exposure during smiling. Moreover, the effective bonding of an upper retainer requires additional care during the placement of the wire, which must be below the proximal contact points. However, a previous study<sup>16</sup> has demonstrated excellent long-term success rates for upper and lower fixed retainers.

The technique presented in this paper requires the use of fixed retainers in both arches. It also seems important the use of multi-stranded wires, co-axial type, made of stainless steel with 0.021-in in diameter due to the excellent stability<sup>15</sup> and surface roughness, which allows the wire to hold the elastomeric solid thread that will generate the necessary force to move the teeth. The direction of this force will be defined by the placement of the elastomeric thread in relation to the fixed retainer. This thread should be changed every two weeks. Thus, it is possible to correct labial displacements (Fig 1), tooth rotation (Fig 2) and spacing (Fig 3) in the upper and/or lower dental arches. However, it should be noted that in most cases of incisor labial displacement, it is necessary to create more space, which can be done by interproximal striping (Fig 1).

## CASE REPORTS

Three clinical cases are used to illustrate the technique presented in this paper. They are representative cases of dental misalignment after fracture or loss of a bonded retainer.

The first clinical case is a labial displacement relapse (Fig 1), the second case involves a lower incisor rotation relapse (Fig 2) and the third case is a retreatment of space opening (Fig 3). The method for tying the elastomeric thread on the retainer is shown and described in Figure 4.

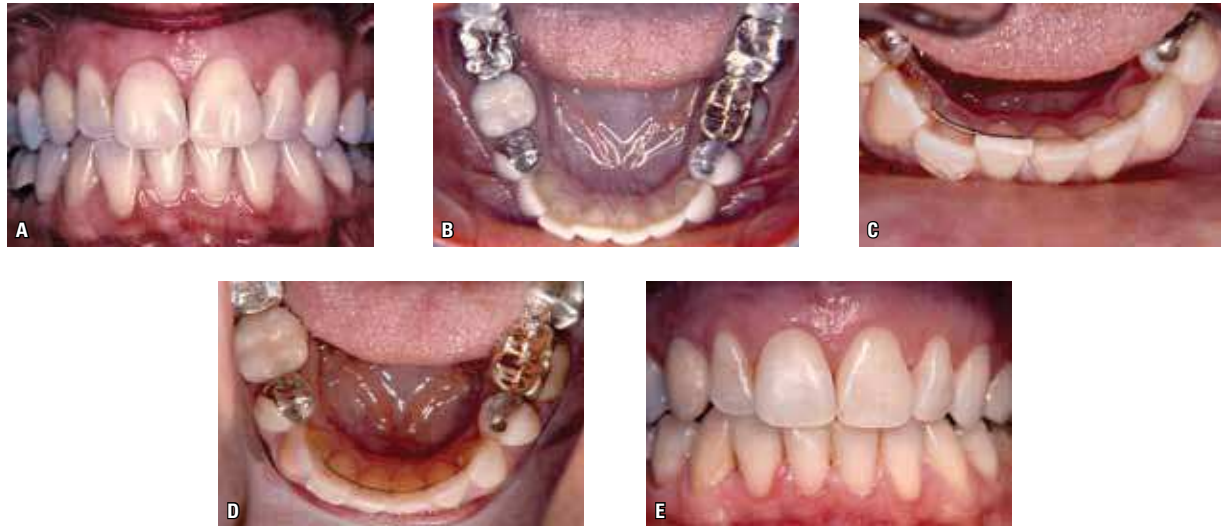


FIGURE 1 - Adult patient, 20 years after the orthodontic treatment, reported a mild labial displacement of tooth 42 (A) causing premature contact in MHI with tooth 12 (B) and consequent wear of its incisal edge. A lingually bonded lower retainer made of stainless steel co-axial multi-stranded wire, 0.0215-in in diameter (Penta-one Masel Orthodontics, Carlsbad, CA) was bonded to all lower anterior teeth except tooth 42. The 0.020-in elastomeric solid thread (Masel Orthodontics, Carlsbad, CA) was tied to tooth 42, which generated a force to move this tooth lingually (C). A slight stripping was necessary in the adjacent teeth in order to provide some space. The tooth was repositioned after 45 days. The solid thread was changed every two weeks (D, E).

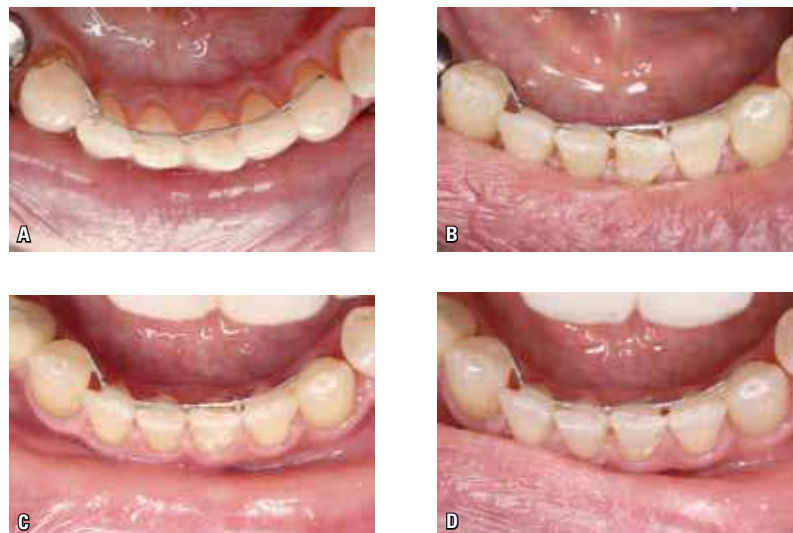

FIGURE 2 - Lower right incisor rotation after bonded retainer failure (A). The solid thread was stretched and bonded with composite just on the distal surface (B). After 10 days, a significant improvement was observed and a new thread was inserted (C). After 20 days the case was finished and the tooth was rebonded to the lower retainer (D).

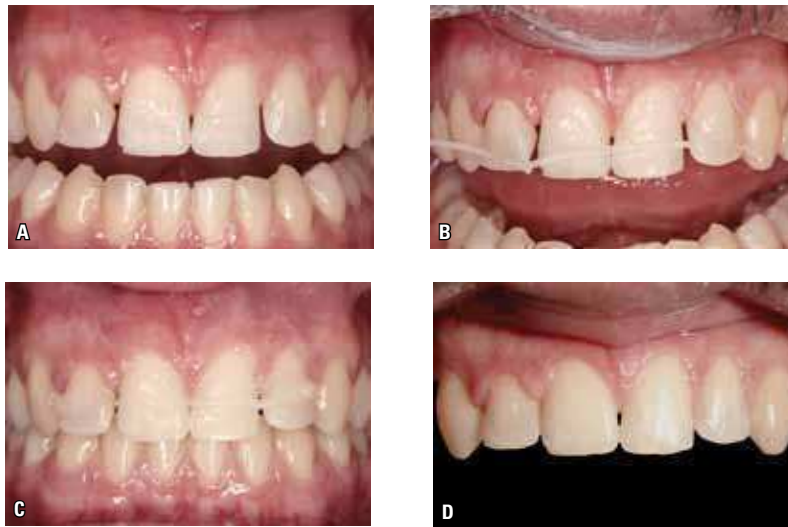

FIGURE 3 - Reopening space at the mesial of the upper lateral incisors after maxillary retainer bonding fracture (A). The retainer was still bonded to the upper canines and upper central incisors. A knot was made at the end of the solid thread (B) and this knot was bonded with composite to the labial surface of the upper left lateral incisor. The elastomeric thread was pulled and bonded to the upper right lateral incisor. The space was closed in just 10 days and the upper lateral incisors were rebonded to the upper retainer.

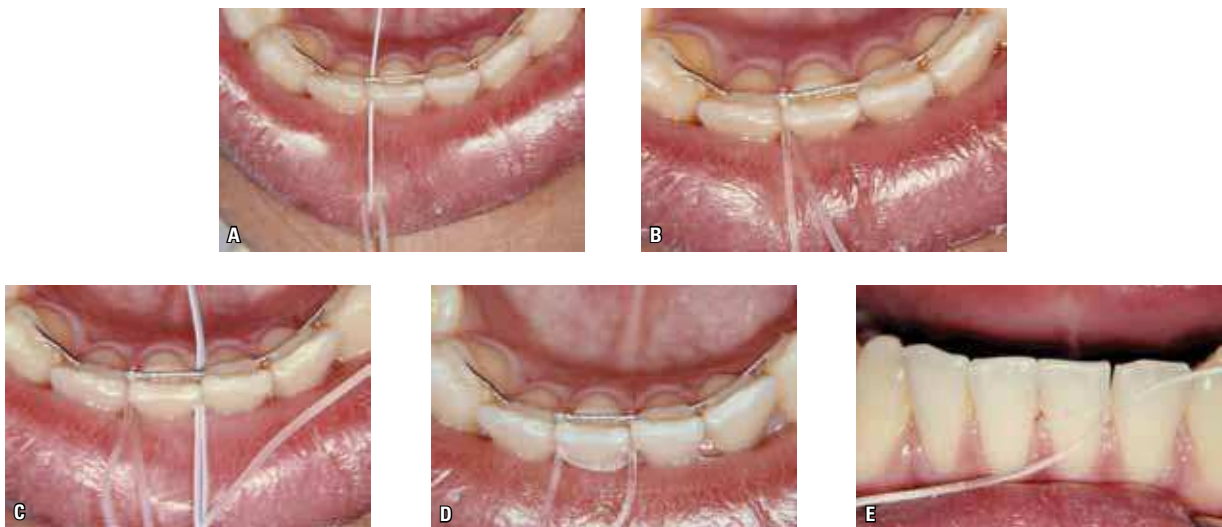


FIGURE 4 - Method used for tying the elastomeric thread when the goal is to produce lingual movement. With the aid of a floss threader, the solid thread is inserted under the retainer and the contact point of the tooth to be moved (A) in a buccolingual direction. The thread returns above the retainer (B). This procedure is repeated on the other proximal contact (C and D). Then, the thread is tied on the tooth labial surface (E). The knot can be bonded with a small amount of composite in order to facilitate its retention and to provide comfort to the patient (Video available at [www.youtube.com/watch?v=sxKR3\\_TNlqc](http://www.youtube.com/watch?v=sxKR3_TNlqc)).

## DISCUSSION

Treatment stability has been the main goal of orthodontics, although it is well known that treatment outcomes are not stable at all since a multiplicity of factors can interfere in the post-treatment occlusal balance leading to undesirable changes. Despite numerous published studies, a systematic review<sup>17</sup> reports that there is insufficient research data on which to base our clinical practice choices on retention.

The risk of relapse in the anterior segment compared to the posterior<sup>4</sup> is the clinical indication for a fixed lower anterior retainer. Multistranded wires has been proposed for the construction of fixed retainers based on their ability to allow for the physiologic movement of the teeth, whereas their surface offers increased mechanical retention for the adhesive.<sup>18,19</sup> Despite multistranded retainers are efficient in preventing relapse of the mandibular anterior teeth,<sup>20</sup> post-treatment changes in the mandibular anterior teeth are expected when bonding failure occurs.<sup>1-4</sup>

Longitudinal studies of orthodontically treated cases have demonstrated a tendency for relapse after treatment<sup>1-4</sup>, even in well finished cases. These changes may occur suddenly in cases of loss or fracture of retainers. Even though the most effective manner for orthodontic retreatment of crowding or diastemas require the use of brackets and wires for leveling, the advantage of using a simpler, faster and cheaper procedure would by itself justify the adoption of this method. The technique described in this paper apart from being effective

seems to be better accepted by the patient because of the little time spent in retreatments and the low impact on esthetics. However, it requires the orthodontist to use fixed retainers for both dental arches. This approach is able to correct several minor changes postretention, such as buccal inclinations of the incisors (Fig 1), anterior rotations (Fig 2) and interincisal diastema (Fig 3) of anterior teeth.

Even though it is efficient for the correction of minor alterations, typical of misalignments in the anterior region of dental arch, it should be emphasized that major changes appear to be handled more efficiently with fixed appliances. In this case, the professional will have to surpass the usual patient resistance, who, generally, fights against using brackets and orthodontic wires or search for other alternative ways to perform re-treatment. Nevertheless, the disadvantage of installing fixed appliances once again for the correction of minor movements seems to perfectly be replaced by the method described in this paper.

## CONCLUSION

The technique presented in this paper seems to be effective to correct mild changes in the anterior teeth alignment that can occur after orthodontic treatment because of the failure of bonded retainer. This simple procedure can be helpful only if the orthodontist has used upper and lower fixed retainers. Prospective studies involving larger samples must be conducted in order to scientifically investigate the rate of success for this clinical procedure.

## REFERENCES

1. Erdinc AE, Nanda RS, Isiksal E. Relapse of anterior crowding in patients treated with extraction and nonextraction of premolars. *Am J Orthod Dentofacial Orthop.* 2006;129(6):775-84.
2. Freitas KM, Freitas MR, Henriques JF, Pinzan A, Janson G. Postretention relapse of mandibular anterior crowding in patients treated without mandibular premolar extraction. *Am J Orthod Dentofacial Orthop.* 2004;125(4):480-7.
3. Little RM. Stability and relapse of mandibular anterior alignment: University of Washington studies. *Semin Orthod.* 1999;5(3):191-204.
4. Maia NG, Normando ADC, Maia FA, Alves MSC, Ferreira MAF. Factors associated with orthodontic stability: a retrospective study of 209 patients. *World J Orthod.* 2010;11(1):61-6.
5. Maia NG, Normando D, Maia FA, Ferreira MA, Alves SCFM. Factors associated with long-term patient satisfaction. *Angle Orthod.* 2010;80(6):1155-8.
6. Warunik SP, Strychalski ID, Cunat JJ. Clinical use of silicone elastomer appliances. *J Clin Orthod.* 1989;23(10):694-700.
7. Sheridan JJ, McMinn R, LeDoux W. Essix thermosealed appliances: various orthodontic uses. *J Clin Orthod.* 1995;29(2):108-13.
8. Rinchuse DJ, Rinchuse DJ. Active tooth movement with Essix-based appliances. *J Clin Orthod.* 1997;31(2):109-12.
9. Cureton SL. Correcting maligned mandibular incisors with removable retainers. *J Clin Orthod.* 1996;30(7):390-5.
10. Bloore JA, Bloore GE. Correction of adult incisor crowding with a new removable appliance. *J Clin Orthod.* 1998;32(2):111-6.
11. McNamara TG, McNamara T, Sandy JR. A new approach to incisor retention-the lingual spur retainer. *Br J Orthod.* 1996;23(3):199-201.
12. Liou EJW, Chen LIJ, Huang S. Nickel-titanium mandibular bonded lingual 3-3 retainer: For permanent retention and solving relapse of mandibular anterior crowding. *Am J Orthod Dentofacial Orthop.* 2001;119(4):443-9.
13. Årtun J, Spadafora AT, Shapiro PA. A 3-year follow-up study of various types of orthodontic canine-to-canine retainers. *Eur J Orthod.* 1997;19(5):501-9.
14. Valiathan M, Hughes E. Results of a survey-based study to identify common retention practices in the United States. *Am J Orthod Dentofacial Orthop.* 2010;137(2):170-7.
15. Singh P, Grammati S, Kirschen R. Orthodontic retention patterns in the United Kingdom. *J Orthod.* 2009;36(2):115-21.
16. Tacken MP, Cosyn J, De Wilde P, Aerts J, Govaerts E, Vannet BV. Glass fibre reinforced versus multistranded bonded orthodontic retainers: a 2 year prospective multi-centre study. *Eur J Orthod.* 2010;32(2):117-23.
17. Littlewood SJ, Millett DT, Doubleday B, Bearn DR, Worthington HV. Retention procedures for stabilizing tooth position after treatment with orthodontic braces. *Cochrane Database Syst Rev.* 2004;(1):CD002283.
18. Zachrisson BU. Clinical experience with direct-bonded orthodontic retainers. *Am J Orthod.* 1977;71(4):440-8.
19. Zachrisson BU. The bonded lingual retainer and multiple spacing of anterior teeth. *J Clin Orthod.* 1983;17(12):838-44.
20. Katsaros C, Livas C, Renkema AM. Unexpected complications of bonded mandibular lingual retainers. *Am J Orthod Dentofacial Orthop.* 2007;132(6):838-41.

Submitted: February 23, 2011  
 Revised and accepted: May 3, 2011

**Contact address**

David Normando  
 Rua Boaventura da Silva, 567, ap. 1201 – Belém / PA, Brazil  
 CEP: 66.0550-090  
 E-mail: davidnor@amazon.com.br