

Dental age as indicator of adolescence

Omar Gabriel da Silva Filho*, Naiara Jordão Souza Parteira**, Tulio Silva Lara***, Francisco Antônio Bertoz****

Abstract

Aim: The purpose of the present study was to analyze the relationship between root formation of the first premolars and skeletal maturation stages identified in hand-wrist radiographs. **Methods:** A cross-sectional study was carried out involving the panoramic and hand-wrist radiographs obtained on the same date of 232 patients, 123 boys and 109 girls aged 4 years and 5 months to 17 years and 12 months. Root formation stages of the first premolars were related to the ossification stages of the sesamoid bone, epiphyseal stages of the phalanx of the thumb and epiphyseal stages of the radius. **Results:** The studied variables demonstrated statistically significant correlations. **Conclusion:** Roots of the lower first premolars do not reach 2/3 of their complete length before adolescence.

Keywords: Age determination by skeleton. Orthodontics. Bone development.

INTRODUCTION

The concepts of corrective and interceptive orthodontics are founded on the development stage of the occlusion. Corrective orthodontics is the mechanical movement imposed on permanent dentition, whereas interceptive orthodontics is treatment prior to the installment of the permanent dentition. Based on these concepts, orthodontists use dental age as a practical parameter for differentiating early and late treatment.

Moreover, dental age is reported to be a determinant of the proper time for treatment, as seen in Figures 2 to 5.

Figure 2 illustrates the extrusion of tooth #21 in the inter-transitory period of the mixed dentition. Figures 3 to 5 illustrate continuous mandibular advancement applied in pre-adolescence in the same period.

Orthodontists do not always need the growth variable for the application of mechanical

How to cite this article: Silva Filho OG, Parteira NJS, Lara TS, Bertoz FA. Dental age as indicator of adolescence. *Dental Press J Orthod.* 2012 Jan-Feb;17(1):85-100.

» The authors report no commercial, proprietary, or financial interest in the products or companies described in this article.

* Head of the Preventive and Interceptive Orthodontics course, PROFIS (Bauru/SP, Brazil). Orthodontist at the Hospital for Rehabilitation of Craniofacial Anomalies, University of São Paulo (HRAC-USP, Bauru/SP, Brazil).

** Resident at the Department of Orthodontics, HRAC-USP.

*** Professor at the Preventative and Interceptive Orthodontics course, PROFIS. Orthodontist at the HRAC-USP/ Funcraf.

**** Full Professor, Araçatuba School of Dentistry, University of the State of São Paulo (UNESP, Araçatuba/SP, Brazil). Professor of Orthodontics, Child and Social Dentistry Department, UNESP, Araçatuba.

movement. For instance, the correction of malocclusions without sagittal error does not require growth (Fig 2). As crowding is an intra-arch problem, its treatment does not depend on growth; nor does growth interfere in the treatment. Crowding can be corrected beginning in the first transitory period of the mixed dentition. The same is true for eruption problems, which should be treated during the eruption of the teeth involved (Fig 2).

The remaining potential of facial growth takes on importance in the treatment of malocclusions with sagittal skeletal error, such as Class II malocclusions with mandibular deficiency (Pattern II).^{1,17,21,26}

Growth is a complex biological phenomenon driven primarily by genetics and, in postnatal life, occurs from birth through the skeletal maturation, with a growth spurt in adolescence.⁴ Locating a patient on his/her growth curve is a well-known task for orthodontists and is mainly performed by bone age.^{4,7,12,24} However, the daily practice of occlusal analysis and the practicality of this diagnostic method, makes, on the part of orthodontists, the underestimated dental age a tempting means to be used as the first option to determine adolescence. Is it possible to locate the patient in adolescence based on dental age? By posing this question, the focus of the present study fuels the discussion on the use of dental age as a biological development parameter in orthodontics.

Day-to-day experience with dental age suggests that the occlusion of the upper and lower first premolars immediately precedes adolescence. As the tooth eruption process is closely related to the degree of root formation,³⁰ panoramic radiography is a convenient means for this evaluation.

Bone age, which is currently determined through radiographic images of the cervical vertebrae,^{2,11,16,22} has historically been identified through hand-wrist radiographs.^{4,7,12}

The use of new diagnostic methods is certainly part of the evolution of science, but does not invalidate classic methods of proven reliability. In hand-wrist radiographs, numerous centers of ossification can be assessed in adolescence, such as the sesamoid bone,^{4,5} epiphysis of the proximal phalanx of the thumb¹⁰ and epiphysis of the radius.⁶

The aim of the present study was to determine associations between dental age analyzed in panoramic radiographs and bone age analyzed in hand-wrist radiographs. A further aim was to demonstrate the degree of agreement of skeletal age and dental age by a single examiner and determine whether sexual dimorphisms exists in the development of the upper and lower first premolars.

MATERIAL AND METHODS

Panoramic and hand-wrist radiographs of 232 patients (123 females and 109 males) taken on the same day were selected from the archives of the Profis Preventive and Interceptive Orthodontics Course in the city of Bauru (Brazil) for analysis. Patient age ranged from 4 years and 5 months to 17 years and 12 months (mean= 8 years and 10 months; standard deviation= 2 years and 3 months) (Fig 1).

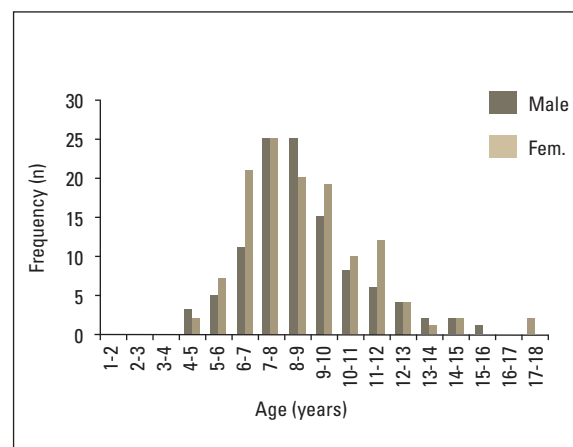


FIGURE 1 - Distribution of the 232 patients of the studied sample, according to age and gender.

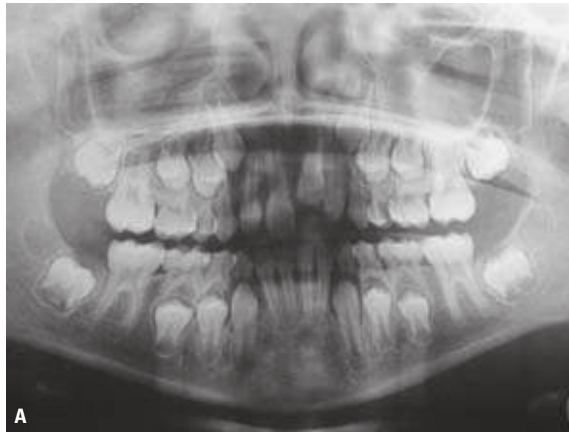


FIGURE 2 - Class I malocclusion with ectopic eruption of tooth #21 diagnosed in inter-transitory period of the mixed dentition. In malocclusions without sagittal error, dental age is determinant of proper treatment time. **A)** Initial panoramic radiograph.

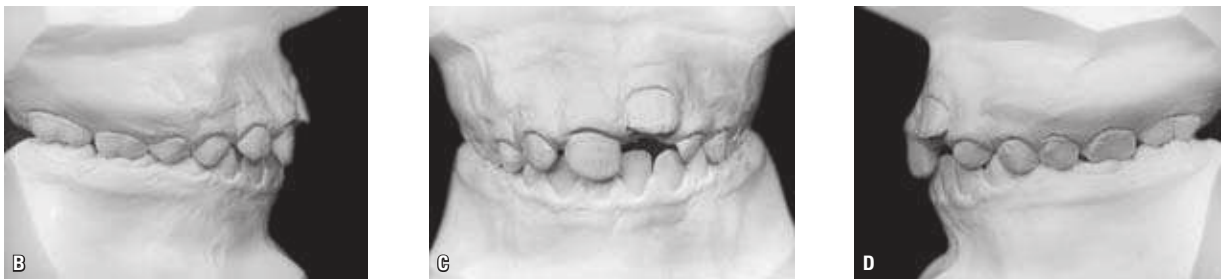

FIGURE 2 (continuation) - Initial dental cast: **B)** right lateral view, **C)** frontal view and **D)** left lateral view.

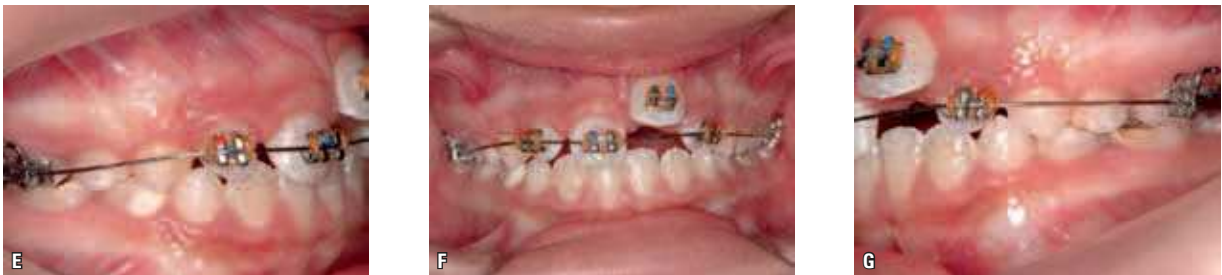

FIGURE 2 (continuation) - 4X2 upper leveling with rectangular steel wire: **E)** right lateral view, **F)** frontal view and **G)** left lateral view.

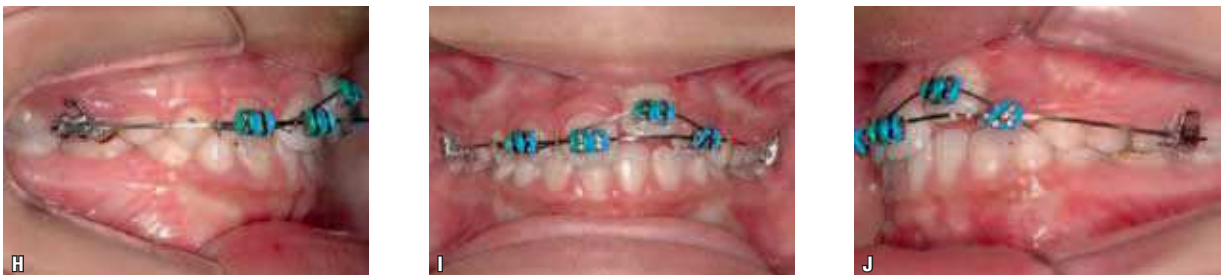

FIGURE 2 (continuation) - Leveling of tooth #21 with NiTi wire anchored on continuous leveling: **H)** right lateral view, **I)** frontal view and **J)** left lateral view.

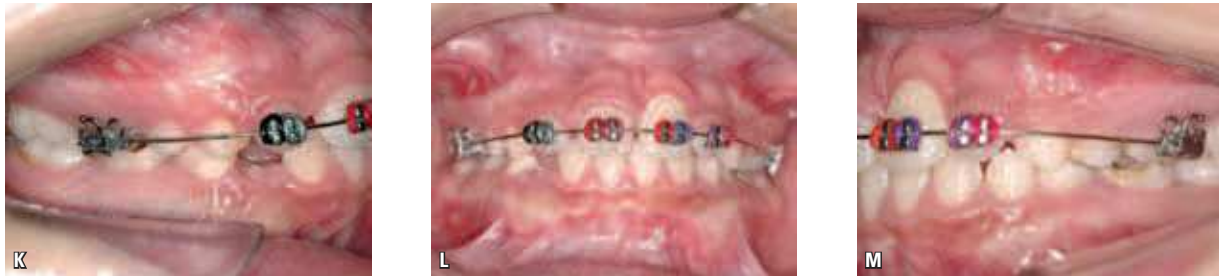

FIGURE 2 (continuation) - Leveling of tooth #21: **K)** right lateral view, **L)** frontal view and **M)** left lateral view.

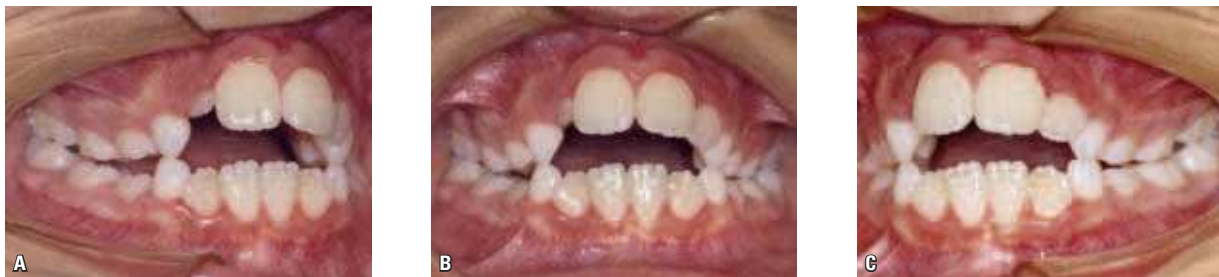

FIGURE 3 - Class II, division I malocclusion, with anterior open bite diagnosed in the first transitory period of the mixed dentition, development stage equivalent to preadolescence: **A)** right lateral view, **B)** frontal view and **C)** left lateral view.

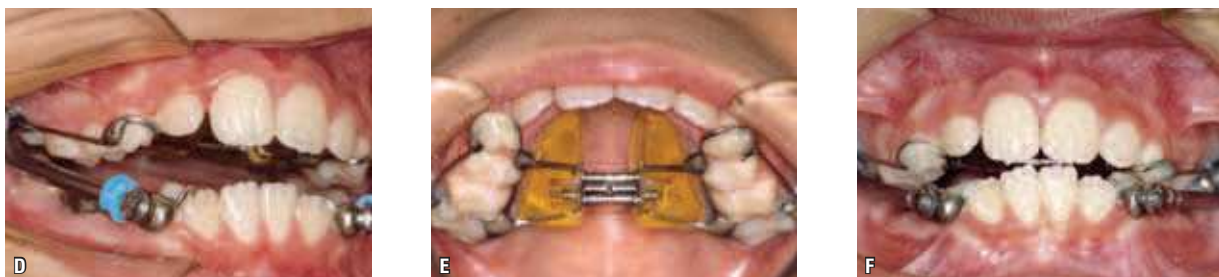

FIGURE 3 (continuation) - Continuous mandibular advancement with Herbst appliance: **D)** right lateral view; **E)** occlusal view of fixed Haas expander modified for Herbst (upper anchorage); **F)** frontal view. The continuous orthopedic mandibular advancement with the Herbst appliance was instituted at this dental age (early treatment protocol).

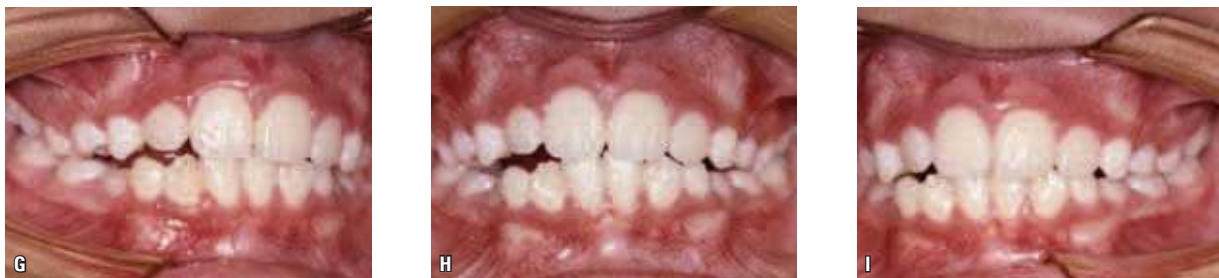

FIGURE 3 (continuation) - Correction of sagittal error: **G)** right lateral view, **H)** frontal view and **I)** left lateral view.

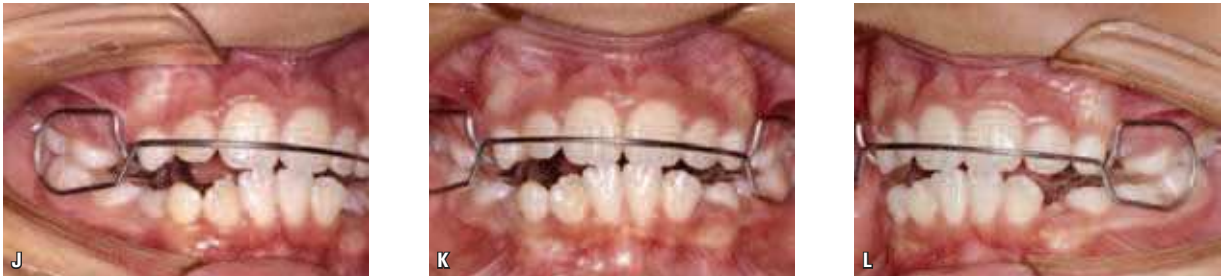

FIGURE 3 (continuation) - Retention performed with intermittent mandibular advancement: **J)** right lateral view, **K)** frontal view and **L)** left lateral view.

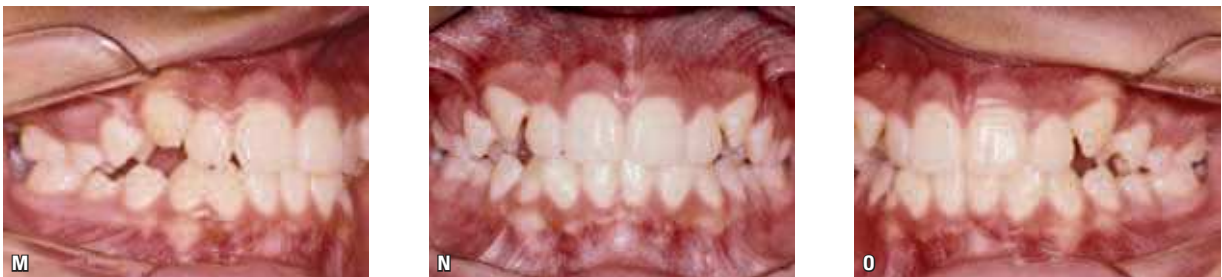

FIGURE 3 (continuation) - Final mandibular advancement phase: **M)** right lateral view, **N)** frontal view and **O)** left lateral view.

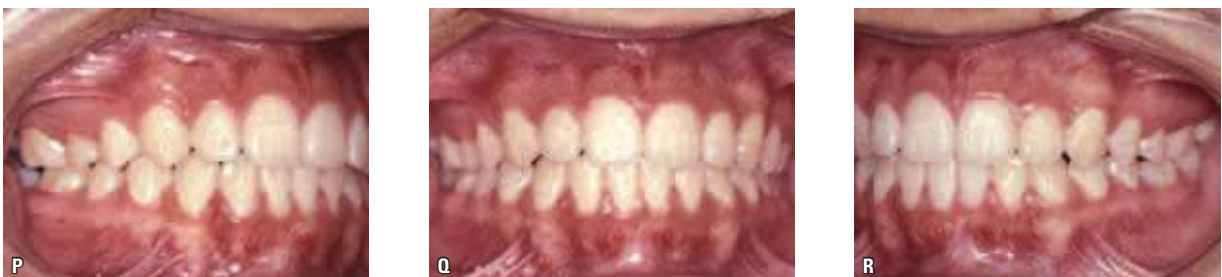

FIGURE 3 (continuation) - End of treatment after removal of fixed orthodontic appliances: **P)** right lateral view, **Q)** frontal view and **R)** left lateral view.

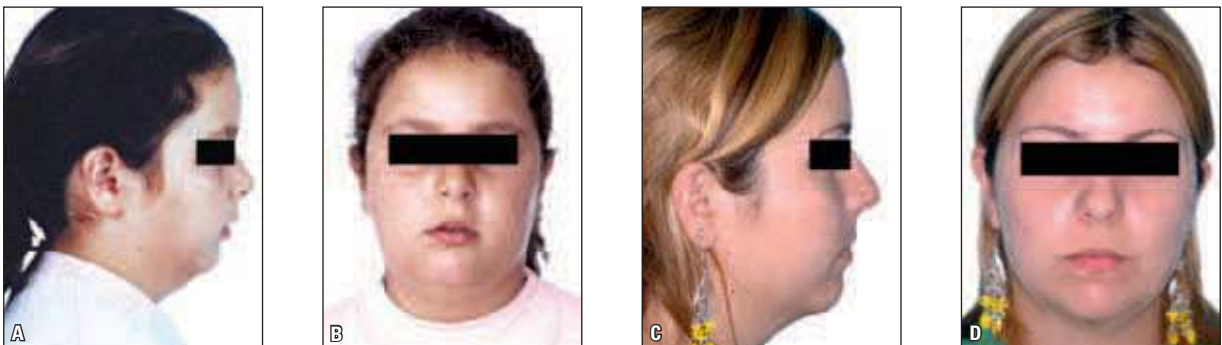

FIGURE 4 - **A)** Initial facial profile analysis revealing mandibular deficiency which follows the Class II malocclusion shown in Figure 3. **B)** Frontal facial analysis. **C)** Orthopedic mandibular advancement had an important facial impact by repositioning the mandible in the face. **D)** Final frontal facial analysis.

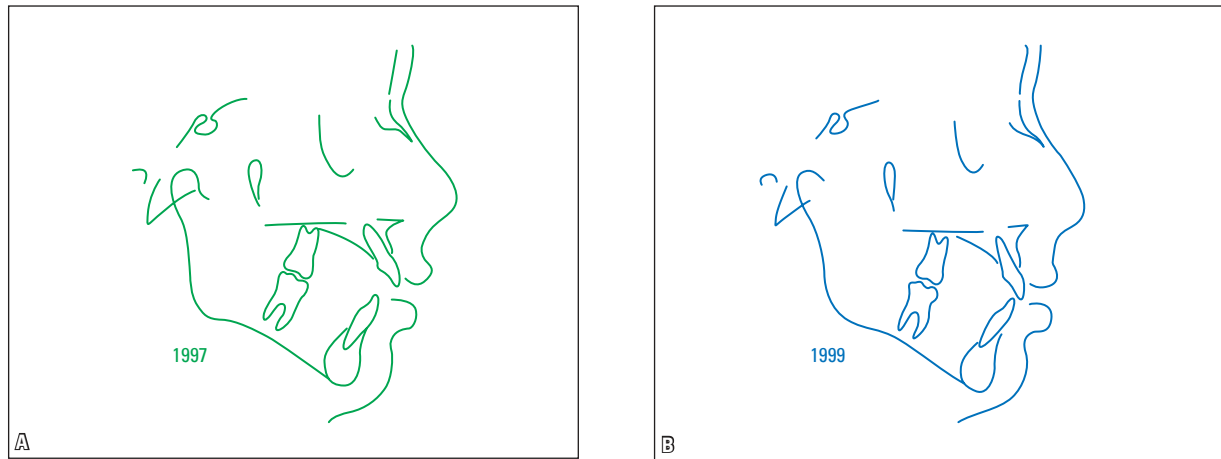


FIGURE 5 - Cephalometric tracings and superimpositions from the patient in Figures 3 and 4 revealing changes in the face and mandible throughout follow-up period (1997 to 2001): **A)** pretreatment; **B)** post-orthopedic mandibular advancement.

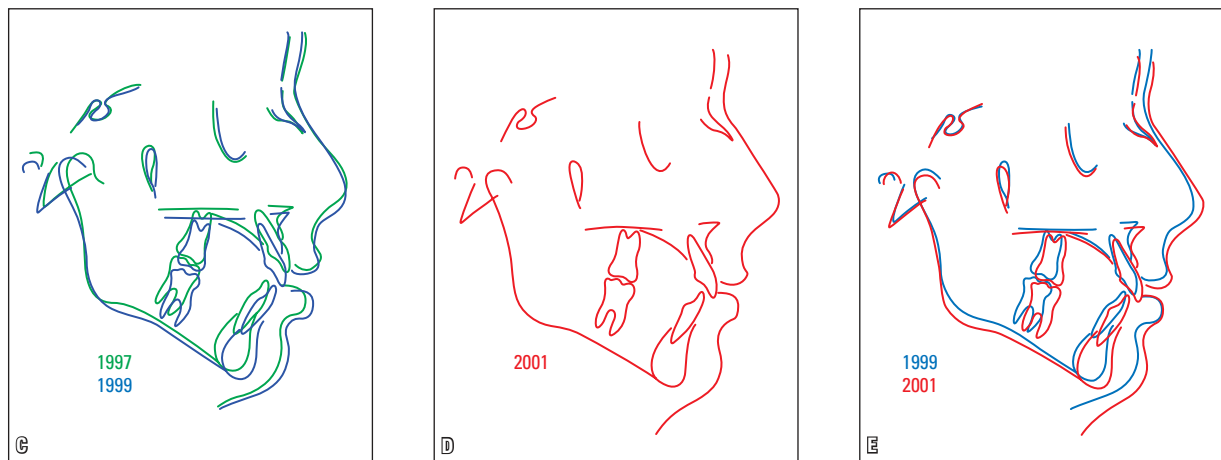


FIGURE 5 (continuation) - **C)** Superimposition 1997-1999, **D)** 2001 (post-corrective orthodontic treatment), **E)** Superimposition 1999-2001.

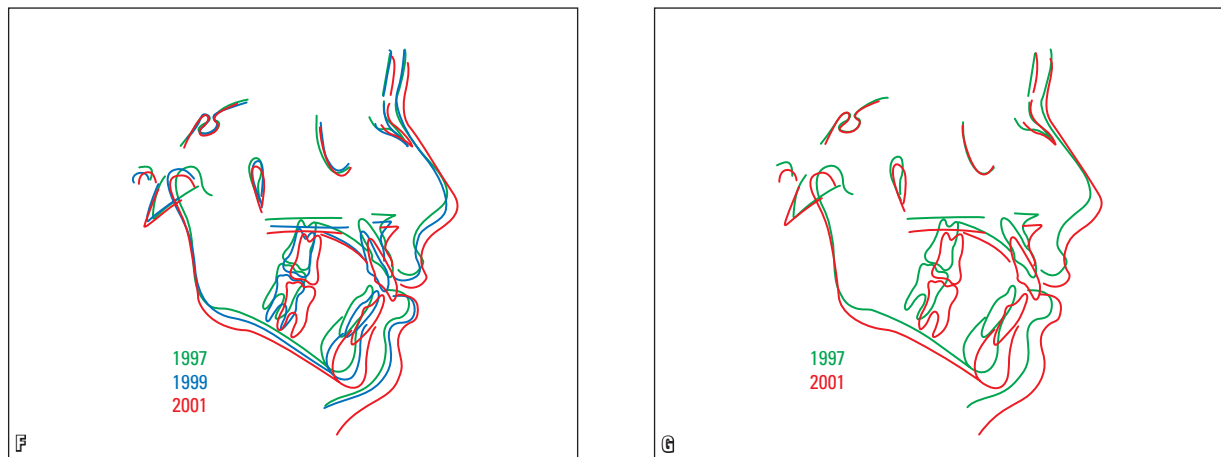


FIGURE 5 (continuation) - **F)** Superimposition 1997-1999-2001, **G)** Superimposition 1997-2001.

Bone age was determined through the evaluation of specific centers of ossification in the hand-wrist radiographs. For such, the degree of ossification of the sesamoid bone, epiphyseal stage of the proximal phalanx of the thumb and epiphyseal stage of the radius were analyzed. A letter from A to M was attributed to each ossification or epiphyseal stage, as illustrated in Figures 6 to 8.

The root development stage of the left upper and lower first premolars was assessed in the panoramic radiographs. For such, the classification system proposed by the authors was used, in which a letter from N to R was attributed to each degree of root formation, as illustrated in Figure 9.

Only radiographs of good quality and no evidence of carious lesions or endodontic problems of the analyzed teeth or their primary predecessors were selected. All panoramic and hand-wrist radiographs were examined separately by a single examiner using an X-ray viewer in a darkened room. The regions of interest, sesamoid bone,

thumb, radius and left upper and lower premolars, were analyzed separately, with the rest of the radiograph covered by a black cardboard. Patient identification such as name, gender and age were also covered on the radiograph, so that the evaluator had no access to this information. After fifteen days, a second analysis was performed of each region of interest in order to determine the reliability of the method (intra-examiner agreement). The Kappa statistic¹⁴ was used as the concordance measure between the first and second evaluations of the radiographs in the identification of the development stage of the left upper and lower first premolars and ossification/epiphyseal stages of the hand-wrist bones.

In cases in which there was no agreement between the first and second evaluations, for the determination of the dental or ossification development stages, a second examiner helped the first examiner determine the stage that best represented the image in the radiograph through a consensus assessment. This only happened in three cases.

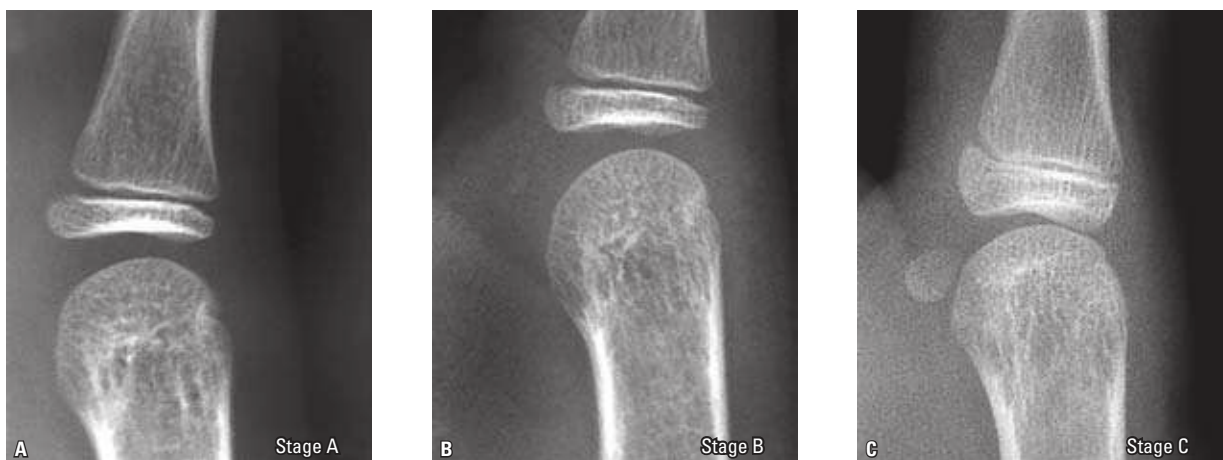

FIGURE 6 - Ossification stages of sesamoid bone identified in hand-wrist radiograph: **A)** Absence of calcification (Stage A); **B)** Onset of calcification (Stage B); **C)** Definite calcification (Stage C).

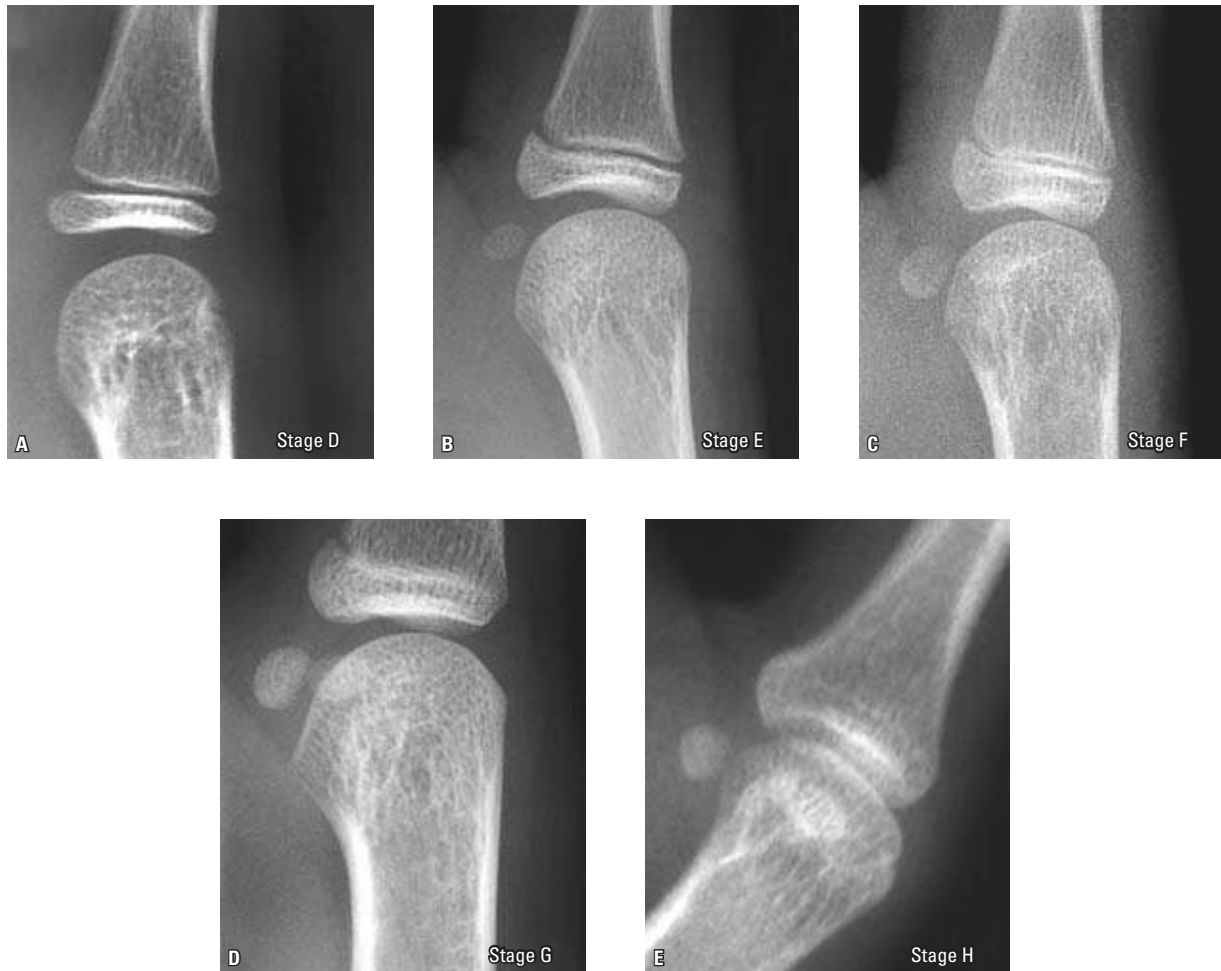

FIGURE 7 - Epiphyseal stages of the proximal phalanx of the thumb identified on hand-wrist radiograph: **A)** Pre-capping (Stage D); **B)** Capping (Stage E); **C)** Fusion onset (Stage F); **D)** Fusion in progress (Stage G); **E)** fusion complete (Stage H).

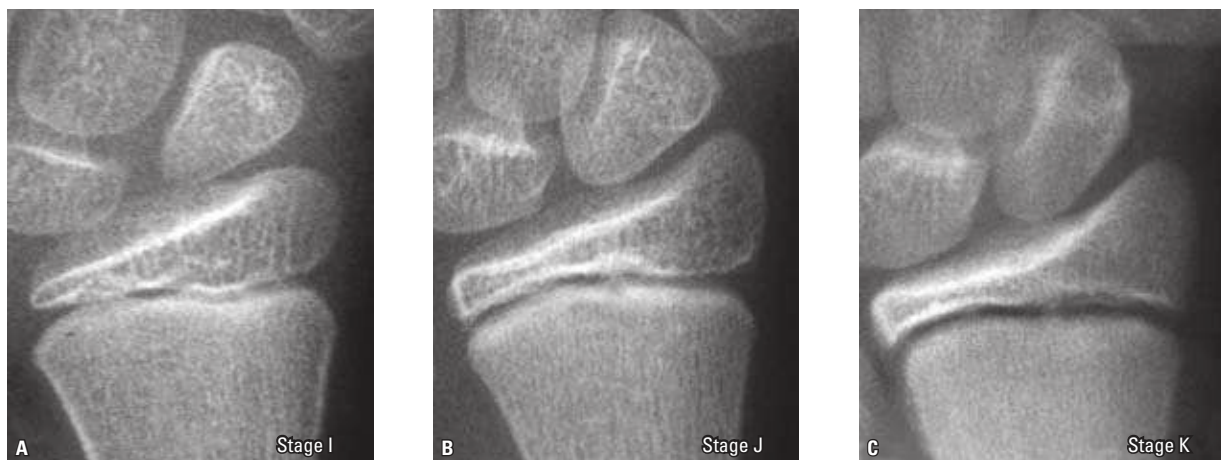

FIGURE 8 - Epiphyseal stages of the radius identified on hand-wrist radiograph: **A)** Less than diaphysis (Stage I); **B)** Same size as diaphysis (Stage J); **C)** Capping (Stage K).

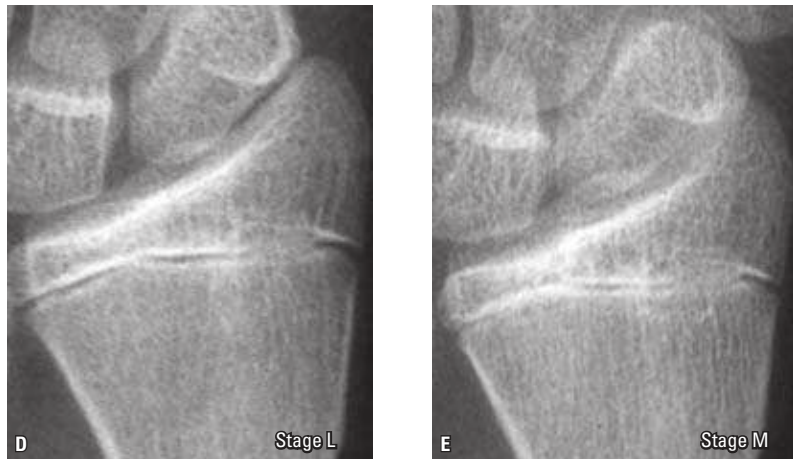

FIGURE 8 (continuation) - **D)** Fusion onset (Stage L); **E)** Fusion in progress (Stage M).

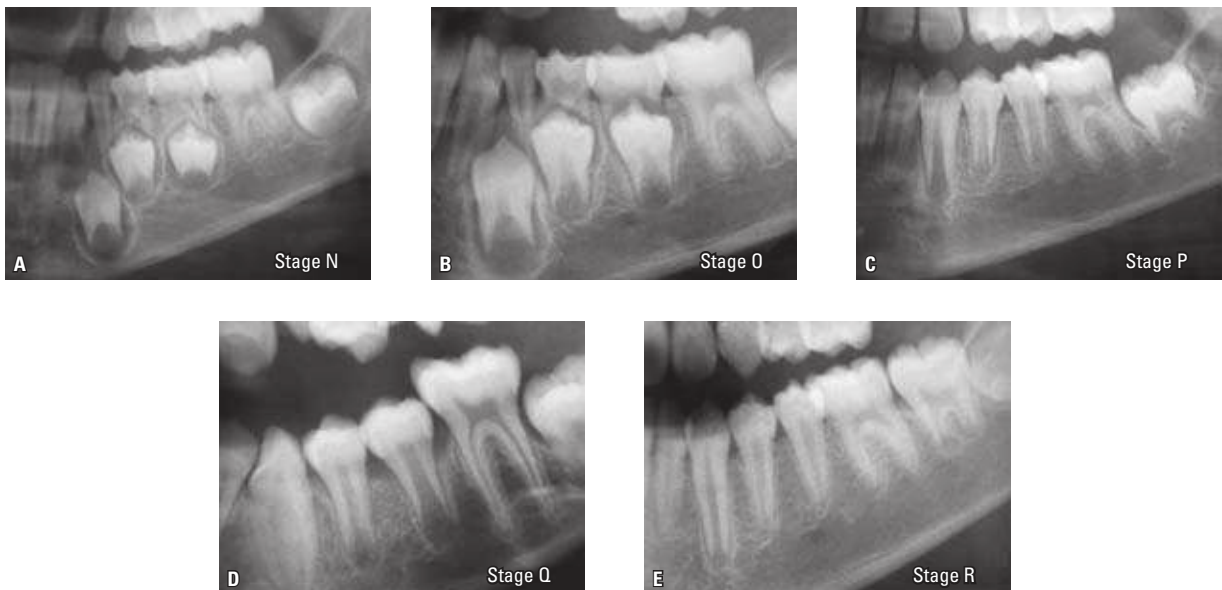


FIGURE 9 - Degrees of root formation of upper and lower first premolars assessed on panoramic radiographs: **A)** Absence of root formation (Stage N); **B)** Root 1/3 complete (Stage O); **C)** Root 1/2 complete (Stage P); **D)** Root nearly complete (3/4) with open apex (Stage Q); **E)** Root complete with closed apex (Stage R).

The existence of sexual dimorphism was evaluated in the development stages of the upper first premolar, lower first premolar and between the upper and lower first premolars. The Mann-Whitney test was used for this evaluation, with a 5% level of significance ($p < 0.05$).

Associations between dental age and bone age were determined by the frequency of dental development stages between different ossification stages. Spearman's correlation coefficients were calculated to determine correlations between these variables.

RESULTS

Table 1 displays the results of the intra-examiner agreement between readings of the radiographs on two separate occasions with a 15-day interval. Kappa values ranged from 0.92 to 1.00, corresponding to nearly perfect agreement.

The Mann-Whitney test revealed no sexual dimorphism in the degree of root formation with regard to the upper first premolar ($p= 0.43$) and lower first premolar ($p= 0.47$) (Table 2).

However, a statistically significant difference was found in the comparison of the formation of the upper and lower first premolars ($p= 0.02$) (Table 2).

TABLE 1 - Intra-examiner test: Percentage of agreement and Kappa index regarding three bone centers assessed on hand-wrist radiographs (sesamoid bone, proximal phalanx of the first finger FP1 and radius) and root formation stages of first lower and upper premolars on panoramic radiographs.

Parameter	% of agreement	K
Sesamoid bone	100.00	1.00
FP1	96.70	0.92
Radius	96.70	0.95
Upper 1 st premolars	97.80	0.97
Lower 1 st premolars	95.60	0.94

TABLE 2 - Sexual dimorphism for the tooth formation degree for upper and lower premolars and the difference in the formation degree among premolars.

Formation degree of upper premolars between genders	Formation degree of lower premolars between genders	Formation degree of upper x lower premolars
p-value = 0.43	p-value = 0.47	p-value = 0.02*

*Statistically significant difference.

TABLE 3 - Relationship between the degree of formation of lower first premolar and bone events of hand-wrist analysis: Spearman's correlation coefficient and p-value.

Comparison	Spearman's	p-value
Lower premolar X sesamoid	0.6299	<0.0001*
Lower premolar X phalanx epiphysis (FP1)	0.4987	<0.0001*
Lower premolar X radius epiphysis	0.5964	<0.0001*

*Significant correlation between variables.

Based on this difference in degree of formation of the premolars, the lower premolar was chosen for comparisons with bone events in the hand-wrist radiographs. Spearman's non-parametric correlation test revealed correlations between the degree of formation of the lower first premolar and hand-wrist bone events (Table 3).

Tables 4, 5 and 6 display the frequencies of the different degrees of lower first premolar formation and different bone events represented by the sesamoid bone, epiphyseal stage of the proximal phalanx of the thumb and epiphyseal stage of the radius.

DISCUSSION

As in the determination of root formation events, the assessment of bone age in hand-wrist radiographs also proved reliable when performed on two separate occasions by the same examiner (Table 1). Thus, there is no doubt regarding the reliability of assessing bone age or dental age, even when employing subjective qualitative methods. The aim of assessing the reliability of the method in the present study was to demonstrate the calibration of the evaluator for the analysis proposed by the authors, classifying different bone stages (sesamoid, epiphysis of the proximal phalanx of the thumb and epiphysis of the radius) and odontogenic stages (degree of root formation of first premolars) using a letter system from A to R (Figs 6 to 9).

The association between the development of the dentition and skeletal maturation has been studied in the literature, with discrepant results reported.^{8,13,15,19,23,29} In the present study, dental age was compared to different ossification events that are determinants of adolescence. The reference chosen for the determination of dental age was root formation of the upper and lower first molars (Fig 9). The choice of these teeth was based on the proximity of their time of eruption to adolescence,^{19,27} which is clinically important information for estimating the

TABLE 4 - Degree of lower first premolar formation and stages of sesamoid ossification.

Sesamoid / Premolar	Absence of ossification	Onset of ossification	Definite ossification	Total
0	74 (31.9%)	-	-	74 (31.9%)
1/3	55 (23.71%)	2 (0.86%)	-	57 (24.57%)
1/2	23 (9.91%)	4 (1.72%)	1 (0.43%)	28 (12.07%)
Open apex (3/4)	25 (10.78%)	11 (4.74%)	14 (6.03%)	50 (21.55%)
Closed apex	3 (1.29%)	3 (1.29%)	17 (7.33%)	23 (9.91%)
Total	180 (77.59%)	20 (8.62%)	32 (13.79%)	232 (100%)

TABLE 5 - Degree of lower first premolar formation and stages of ossification of the epiphysis of the proximal phalanx of the first finger (FP1).

FP1 / Premolar	Pre-capping	Capping	Fusion onset	Fusion in progress	Fusion	Total
0	74 (31.9%)	-	-	-	-	74 (31.9%)
1/3	57 (24.57%)	-	-	-	-	57 (24.57%)
1/2	24 (10.34%)	4 (1.72%)	-	-	-	28 (12.07%)
Open apex (3/4)	37 (15.95%)	9 (3.88%)	1 (0.43%)	1 (0.43%)	2 (0.86%)	50 (21.55%)
Closed apex	8 (3.45%)	4 (1.72%)	3 (1.29%)	1 (0.43%)	7 (3.02%)	23 (9.91%)
Total	200 (86.21%)	17 (7.33%)	4 (1.72%)	2 (0.86%)	9 (3.88%)	232 (100%)

TABLE 6 - Degree of lower first premolar formation and stages of ossification of the epiphysis of the radius.

Radius epiphysis/ Premolar	Smaller	Equal	Capping	Fusion onset	Fusion in progress	Total
0	73 (31.47%)	1 (0.43%)	-	-	-	74 (31.90%)
1/3	54 (23.28%)	3 (1.29%)	-	-	-	57 (24.57%)
1/2	24 (10.34%)	1 (0.43%)	3 (1.29%)	-	-	28 (12.07%)
Open apex (3/4)	27 (11.64%)	13 (5.60%)	3 (1.29%)	5 (2.16%)	2 (0.86%)	50 (21.55%)
Closed apex	3 (1.29%)	4 (1.72%)	2 (0.86%)	7 (3.02%)	7 (3.02%)	23 (9.91%)
Total	181 (78.02%)	22 (9.48%)	8 (3.45%)	12 (5.17%)	9 (3.88%)	232 (100%)

adequate time for the treatment of mandibular deficiency.^{21,26} Although the literature demonstrates that the lower canine has the greatest association with skeletal events,²³ the decision was made to assess the lower first premolar, as a recent study determined that this tooth also does not exhibit considerable variability when compared to bone age.¹⁷

No difference was found between genders in the progression of root formation of the first premolars. Analyzing the eruption chronology of the

permanent teeth, which is directly related to the degree of root formation, there is a difference between genders regarding the time in which these teeth erupt in the oral cavity in both the maxilla and mandible (Fig 10).^{27,30} In the present study, however, sexual dimorphism was found regarding the degree of root formation between the upper and lower first premolar. Thus, the lower first premolar was chosen for comparisons with skeletal events, although the upper first premolar could have been chosen as well.

The sesamoid bone undergoes ossification beginning from a cartilaginous center, which is seen at the beginning of adolescence between the distal portion of metacarpal 1 and the epiphysis of the proximal phalanx of the thumb. The onset of this ossification announces the beginning of the adolescent growth spurt.^{4,12,25} Peak of growth in adolescence is identified by the capping of the epiphysis of the proximal phalanx of the thumb.¹⁰ The final stages of adolescence can be determined on radiographs by indications of fusion or complete fusion of the epiphysis with the diaphysis in either the thumb or radius.^{5,6}

Dental age can be assessed radiographically by the degree of crown and root formation of the teeth²⁰ or clinically by non-erupted teeth.^{3,8} A tooth initiates its eruption after the root reaches 1/4 of its complete length.³⁰ Permanent teeth perforate the gingival tissue and appear in the oral cavity when the roots are approximately 3/4 formed.^{18,20} Eight to ten months elapse between the emergence of an incisor in the oral cavity and its complete eruption.⁹

The proposal of the present study is essentially clinical: The identification of adolescence through the assessment of dental age. For reasons of greater consistency and practicality from the methodological standpoint, dental age was inferred from the degree of root formation (Fig 9) assessed on panoramic radiographs obtained from archival records

(absence of root formation, root 1/3 complete, root 1/2 complete, root 3/4 complete and complete root). With 3/4 of the root formed, the tooth is already in the oral cavity and its complete eruption approximately coincides with its complete formation, though not necessarily with the apex closed.

Most of the patients in the present sample (n= 180) were in pre-adolescence, as identified by the lack of ossification of the sesamoid bone (Table 4), which restricts the analysis of the degree of root formation in adolescence itself. However, it was possible to determine that a larger portion of the patients in the stages prior to adolescence exhibited early degrees of premolar formation (absence of root formation or root 1/3 complete), indicating that these teeth had not yet erupted. Only 1.29% of the patients in pre-adolescence exhibited the R stage (closed apex), which is indicative of completely erupted teeth in occlusion. This result is in agreement with that described by Franchi et al,⁸ who found that the inter-transitory period of the mixed dentition coincides with pre-adolescence. Extrapolating these results to the clinical realm, the first premolars do not erupt in pre-adolescence and first premolars in occlusion announce adolescence. The presence of first premolars in occlusion has been the reference used to determine the proper time for orthopedic mandibular advancement for a Pattern II correction.²⁶

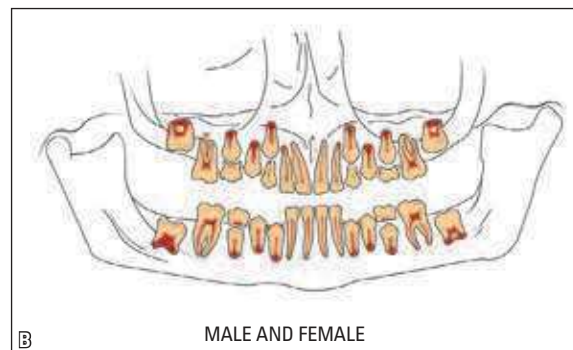
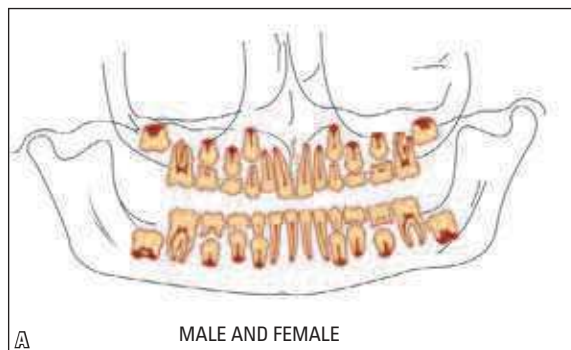


FIGURE 10 - Mean eruption sequence of permanent teeth in the final phase of mixed dentition (second transitory period) in panoramic radiographs (Source: Freitas, 1975), at mean age of 9 years and 3 months (A) and mean age of 10 years and 3 months (B).

Most of the patients who had initiated adolescence, as indicated by the onset of ossification of the sesamoid bone (only 8.6% of the sample) (Table 4), exhibited premolars with 3/4 of the root formed, which coincides with the eruption of these teeth. Patient in adolescence with the sesamoid bone defined (13.8%) exhibited premolars in either the stage of the onset of eruption or with a closed apex and therefore likely in occlusion with the antagonist. Franchi et al⁸ and Tassi et al²⁸ confirmed the end of the mixed dentition (second transitory period), with the exfoliation of the primary second molars and eruption of the premolars, to be an unreliable determinant of adolescence, as the results of these studies demonstrated that only one third of individuals with erupted premolars were in early adolescence and more than half had not left pre-adolescence.

Considering epiphyseal capping as an indicator of peak growth (7.3% of the sample), 1.7% exhibited a 1/2 formed root, 3.9% exhibited a 3/4 formed root and 1.7% had a closed apex. As there were few patients in this skeletal stage, one cannot draw reliable conclusions regarding the association between the degree of root for-

mation and growth peak. When the epiphysis of the radius was smaller than the diaphysis, the patients exhibited the initial degrees of root formation, with the first premolars further along the formation process when the fusion of the epiphysis with the diaphysis began to occur, corresponding to the final stages of adolescence. The few patients with indications of epiphyseal fusion of the radius (onset of fusion or fusion in progress, Table 6), corresponding to 9.05% of the sample, exhibited roots either 3/4 or completely formed.

The variability in the odontogenic stages in relation to bone maturation does not preclude the use of dental age as an initial development parameter in orthodontics or orthopedics, at least in the stages of mixed dentition and prior to the complete eruption of the permanent second molars (occlusal maturity). Surprisingly, due to its immediate clinical nature, dental age seems to suggest the remaining growth potential. Indeed, precise information is not expected.¹⁷ Dental age only reflects the passage to adolescence (Fig 11) and detailed information comes from skeletal age. Thus, dental age constitutes a

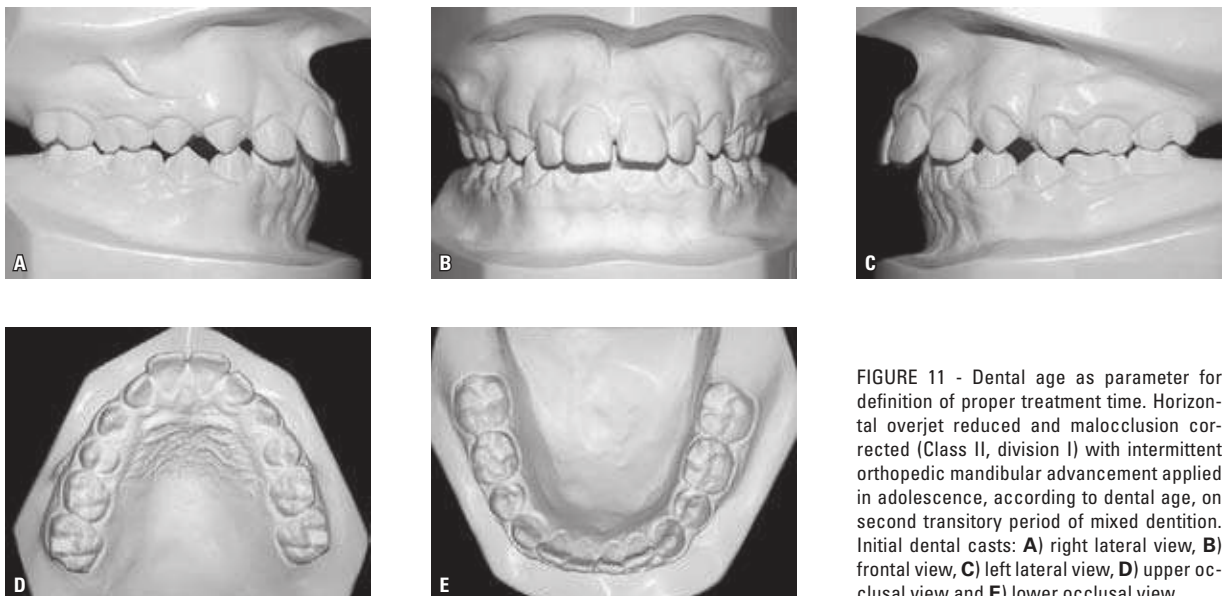


FIGURE 11 - Dental age as parameter for definition of proper treatment time. Horizontal overjet reduced and malocclusion corrected (Class II, division I) with intermittent orthopedic mandibular advancement applied in adolescence, according to dental age, on second transitory period of mixed dentition. Initial dental casts: **A)** right lateral view, **B)** frontal view, **C)** left lateral view, **D)** upper occlusal view and **E)** lower occlusal view.

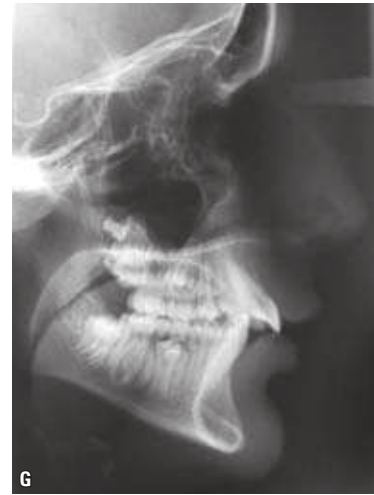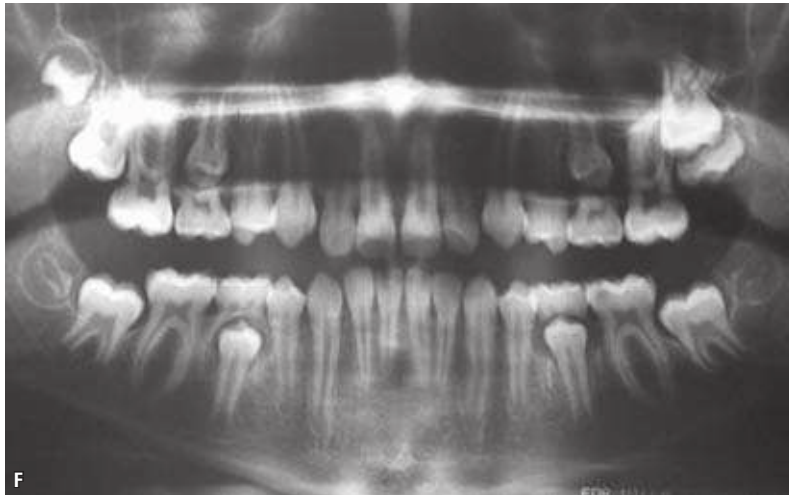


FIGURE 11 (continuation) - Initial panoramic radiograph (F) and lateral cephalometric radiograph (G).

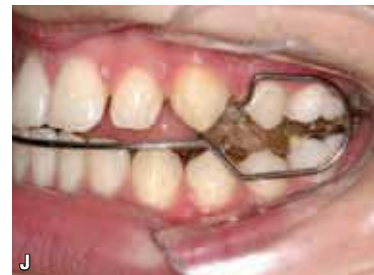
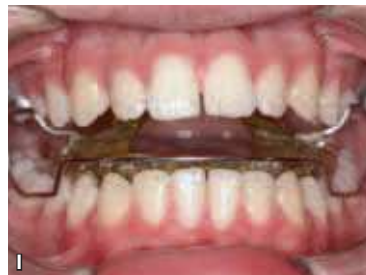
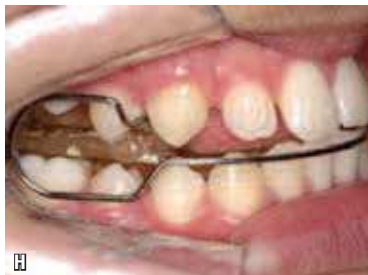FIGURE 11 (continuation) - Intermittent orthopedic mandibular advancement: H) right lateral view, I) frontal view and J) left lateral view.

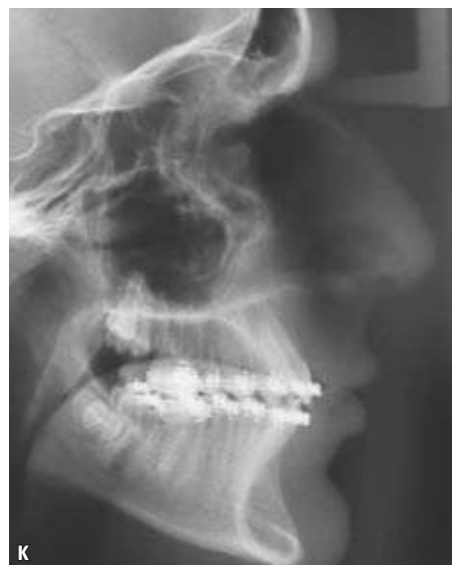

FIGURE 11 (continuation) - K) Lateral cephalometric radiograph during corrective orthodontic treatment.

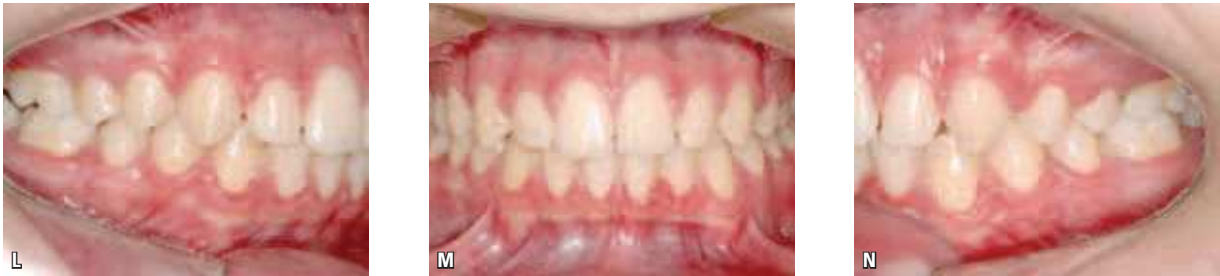

FIGURE 11 (continuation) - Final photographs after appliance removal: **L**) right lateral view, **M**) frontal view and **N**) left lateral view.

line of demarcation from which one may solicit skeletal age in order to locate the patient on the adolescence curve. Based on the present findings, skeletal age should be solicited at the beginning of premolars eruption and not before.

CONCLUSION

Based on the results of the present study, it appears valid to draw the following conclusions:

1) Lower premolars do not erupt in pre-adolescence.

- 2) Lower premolars can emerge in the oral cavity in the beginning of adolescence.
- 3) In adolescence, premolars vary from the clinical appearance all the way to full occlusion.
- 4) Intra-examiner agreement is high in the identification of dental age using panoramic radiographs and skeletal age using hand-wrist radiographs.
- 5) There is no sexual dimorphism in the development of the lower first premolars.

REFERENCES

1. Baccetti T, Franchi L, Toth LR, McNamara JA Jr. Treatment timing for twin-block therapy. *Am J Orthod Dentofacial Orthop.* 2000;118(2):159-70.
2. Baccetti T, Franchi L, McNamara JA Jr. The cervical vertebral maturation (CVM) method for the assessment of optimal treatment timing in dentofacial orthopedics. *Semin Orthod.* 2005;11(3):119-29.
3. Björk A. Timing of interceptive orthodontic measures based on stages of maturation. *Trans Eur Orthod Soc.* 1972:61-74.
4. Björk A, Helm S. Prediction of the age of maximum puberal growth in body height. *Angle Orthod.* 1967;37(2):134-43.
5. Chapman SM. Ossification of the adductor sesamoid and the adolescent growth spurt. *Angle Orthod.* 1972;42(3):236-44.
6. Deicke M, Pancherz H. Is radius-union an indicator for completed facial growth? *Angle Orthod.* 2005;75(3):295-9.
7. Fishman LS. Radiographic evaluation of skeletal maturation. A clinically oriented method based on hand-wrist films. *Angle Orthod.* 1982; 52(2):88-112.
8. Franchi L, Baccetti T, De Toffol L, Polimeni A, Cozza P. Phases of the dentition for the assessment of skeletal maturity: a diagnostic performance study. *Am J Orthod Dentofacial Orthop.* 2008;133(3):395-400.
9. Giles NB, Knott VB, Meredith HV. Increase in intraoral height of selected permanent teeth during the quadrennium following gingival emergence. *Angle Orthod.* 1963;33(3):195-206.
10. Grave KC, Brown T. Skeletal ossification and the adolescent growth spurt. *Am J Orthod.* 1976;69(6):611-9.

11. Hassel B, Farman AG. Skeletal maturation evaluation using cervical vertebrae. *Am J Orthod Dentofacial Orthop*. 1995; 107(1):58-66.
12. Hägg U, Taranger J. Maturation indicators and the pubertal growth spurt. *Am J Orthod*. 1982;82(4):299-309.
13. Krailassiri S, Anuwongnukroh N, Dechkunakorn S. Relationship between dental calcification stages and skeletal maturity indicators in Thai individuals. *Angle Orthod*. 2002;72(2):155-66.
14. Landis JR, Koch GG. The measurement of observer agreement for categorical data. *Biometrics*. 1977;33(1):159-74.
15. Lara TS. Indicadores biológicos maturacionais. In: Lubiana NF. Programa de Atualização em Odontologia Estética (Pro-Odonto/Estética). Ciclo 1 módulo 1. Porto Alegre: Artmed/Panamericana; 2007. p. 93-148.
16. Lara TS, Bertoz FA, Santos ECA, Bertoz APM. Morfologia das 3ª e 4ª vértebras cervicais representativa do surto de crescimento puberal. *Rev Dental Press Ortod Ortop Facial*. 2008;13(6):66-76.
17. Lara TS, Pignatta LMB, Arantes FM, Bertoz APM, Santos ECA, Bertoz FA. Associação entre idade óssea determinada pelas vértebras cervicais e estágios de formação dentária avaliados em radiografias panorâmicas. *Ortodontia SPO*. 2007; 40(2):102-8.
18. Moorrees C FA. The timing of orthodontic treatment in relation to tooth formation. *Trans Eur Orthod Soc*. 1962; 38:1-14.
19. Moraes MEL. Surto de crescimento puberal: relação entre mineralização dentária, idade cronológica, idade dentária e idade óssea. Método radiográfico. [tese]. São José do Rio Preto (SP): UNESP; 1997.
20. Nolla CM. The development of the permanent teeth. *J Dent Child*. 1960;27(4):254-66.
21. Pancherz H, Hägg U. Dentofacial orthopedics in relation to somatic maturation. An analysis of 70 consecutive cases treated with the Herbst appliance. *Am J Orthod*. 1985 Oct;88(4):273-87.
22. Santos ECA, Bertoz FA, Arantes FM, Reis PMP. Avaliação da reprodutibilidade do método de determinação da maturação esquelética por meio das vértebras cervicais. *Rev Dental Press Ortod Ortop Facial*. 2005;10(2):62-8.
23. Sierra AM. Assessment of dental and skeletal maturity. A new approach. *Angle Orthod*. 1987;57(3):194-208.
24. Silva Filho OG; Silva GFB, Lara TS, Santos ECA, Bertoz FA. Idades biológicas aplicáveis na clínica ortodôntica. *Rev Clín Dental Press*. 2007;6(4):79-87.
25. Silva Filho OG, Valladares Neto J, Souza FA. Proposta de um método simplificado para avaliação da maturação esquelética. *Ortodontia*. 1989; 22(3):33-43.
26. Silva Filho OG. Existe uma época ideal para o tratamento da má oclusão Classe II com deficiência mandibular. *Rev Clín Dental Press*. 2008;7(2):17-34.
27. Souza FJA. Estudo antropométrico, dentário e ósseo de brasileiros de 3 a 18 anos de idade da região de Bauru. 1975. [tese]. Bauru (SP): Universidade de São Paulo; 1975.
28. Tassi NG, Franchi L, Baccetti T, Barbato E. Diagnostic performance study on the relationship between the exfoliation of the deciduous second molars and the puberal growth spurt. *Am J Orthod Dentofacial Orthop*. 2007;131(6):769-71.
29. Uysal T, Sari Z, Ramoglu SI, Basciftci FA. Relationships between dental and skeletal maturity in Turkish subjects. *Angle Orthod*. 2004;74(5):657-64.
30. Van der Linden FPGM. Ortodontia: desenvolvimento da dentição. São Paulo: Quintessense; 1986.

Submitted: November 24, 2008
Revised and accepted: June 19, 2009

Contact address

Omar Gabriel da Silva Filho
Av. Rio Branco, 2081 – Altos da Cidade
Zip code: 17.014-037 – Bauru / SP, Brazil
E-mail: ortoface@travelnet.com.br