

# Effectiveness of CO<sub>2</sub> laser in removal of papillary gingival hyperplasia

Sabrina Kívia Correia Gama<sup>1</sup>, Fernando Antônio Lima Habib<sup>2</sup>,  
Antônio Luiz Barbosa Pinheiro<sup>3</sup>, Telma Martins de Araújo<sup>4</sup>

**Introduction:** Laser applications have increased in a variety of dental procedures, especially in surgeries of soft tissues. Radiation is not invasive and is very well tolerated by tissues. CO<sub>2</sub> laser acts in small vessels promoting blood coagulation, making it possible to work in a controlled way. Patients undergoing fixed orthodontic therapy often present injuries of gingival hyperplasia, originating esthetical and functional problems.

**Objective:** This study aimed at evaluating the CO<sub>2</sub> laser effectiveness in removal of hyperplasia lesions in gingival papilla regions of patients with fixed orthodontic appliances. For this, ten patients were chosen and in these 75 teeth with gingival hyperplasia were identified. Measures from the papilla to incisal edge were performed with the use of a digital caliper. Besides that, the individuals were submitted to previous examinations to the surgical procedure with laser: Full blood count, blood coagulation profile and fasting blood glucose. After this, patients were submitted to the surgery for lesion removal, carried out at the Laser Center of FOUFBA, utilizing a CO<sub>2</sub> laser machine (Sharplan 20C, Tel Aviv, Israel).

**Results:** It was showed that laser provided a significant increase ( $p < 0,001$ ) in the distance from the papilla to the incisal edge of the teeth, with no tissue contraction, aspects which were maintained for over two months.

**Conclusion:** It can be concluded that CO<sub>2</sub> laser has proved to be effective in removal of papillary gingival hyperplasia lesions.

**Keywords:** Laser. Gingival hyperplasia. Orthodontics.

<sup>1</sup> PhD in Laser, Dental School, Bahia Federal University (FOUFBA).

<sup>2</sup> Associate Professor, Department of Orthodontics, FOUFBA.

<sup>3</sup> Head Professor, Department of Surgery and Maxillo-Facial Traumatology, FOUFBA.

<sup>4</sup> Head Professor of Orthodontics, FOUFBA. Coordinator of Specialization Course of Orthodontics and Facial Orthopedics Prof. José Édimo Soares Martins, FOUFBA. Director of the Brazilian Board of Orthodontics and Facial Orthopedics.

**How to cite this article:** Gama SKC, Habib FAL, Pinheiro ALB, Araújo TM. Effectiveness of CO<sub>2</sub> laser in removal of papillary gingival hyperplasia. Dental Press J Orthod. 2012 Mar-Apr;17(2):33-5.

**Submitted:** August 27, 2008 - **Revised and accepted:** November 26, 2008

» The authors report no commercial, proprietary, or financial interest in the products or companies described in this article.

» Patients displayed in this article previously approved the use of their facial and intraoral photographs.

**Contact address:** Sabrina Kívia Correia Gama  
Av. Araújo Pinho, 62 – 7º andar – Canela – CEP: 40110-912 – Salvador / BA – Brazil  
E-mail: sabrinakivia@hotmail.com

## Editor's abstract

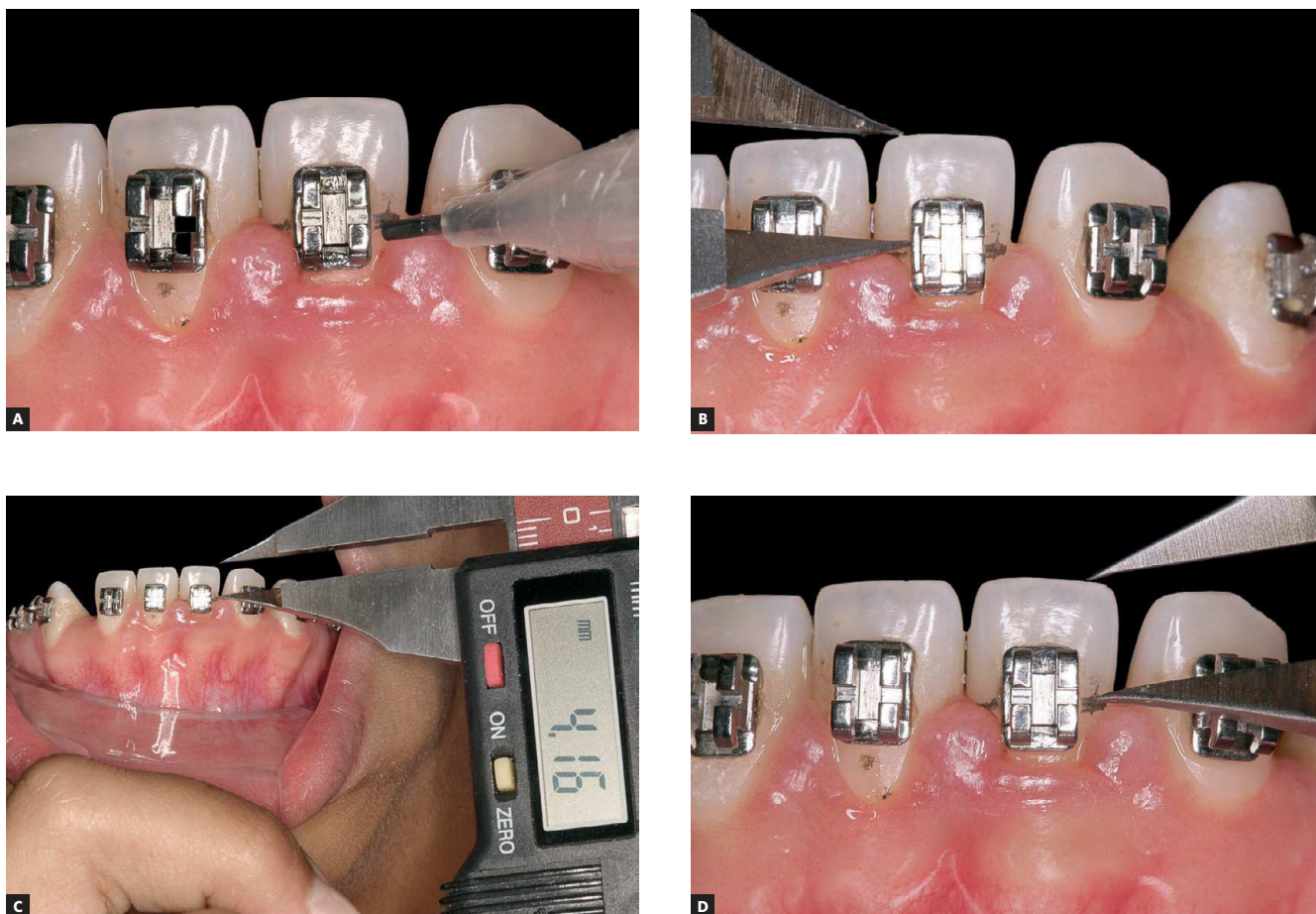
Gingival hyperplasia is a very frequent condition in patients undergoing fixed orthodontic treatment. Its development is usually attributed to chronic inflammation. Initially, gingival hyperplasia may be treated with improvement of the oral hygiene. However, when there is persistence of tissue hyperplasia, the classical treatment would include gingivectomy, which consists in surgically removing hyperplastic tissue, followed by mechanic dental plaque control and effective control of oral hygiene.

The modalities of gingivectomy include the conventional method performed with a scalpel, electrosurgery with electrocautery or through the use of lasers. Among surgical lasers, the most

commonly used in the oral cavity are the Nd:YAG, Argon and CO<sub>2</sub> lasers. In CO<sub>2</sub> laser, the long wavelength has the advantage of being highly absorbed by tissues that contain large amounts of water, presenting evaporation and providing easier removal of the lesions without causing a deep burn. This study aimed to assess the effectiveness of the use of the CO<sub>2</sub> laser on the removal of hyperplasia of the gingival papilla in orthodontic patients.

Ten patients were selected and a total of 75 teeth with hyperplasia were diagnosed. Following routine preparation for surgery, measurements of the distance of papilla to the incisal edge of teeth were performed with a digital caliper (Fig 1).

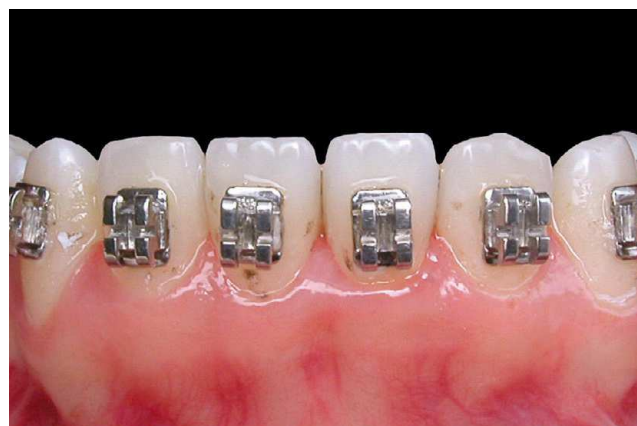The laser used was a CO<sub>2</sub> laser (Sharplan 20C, Tel Aviv, Israel;  $\lambda$  10.600 nm, 5 W, 0.2 mm focus, RSP/CW). The surgeries were performed by a single



**Figure 1 - A)** Marking the height of the papilla before surgery. **B, C and D)** Measuring the distance from the papilla to the incisal edge.

professional. The distance from the papilla to the incisal edge was measured four times: Before surgery - Time 0, immediately after surgery - Time 1, one month - Time 2 (Fig 2) and two months after the surgical procedure - Time 3.

The results showed that the laser treatment resulted in a statistically significant ( $p < 0.001$ ) increase in the distance of papilla to the incisal edge of the teeth and this was kept throughout the experimental period of two months. It can be concluded that the use of the  $\text{CO}_2$  laser was effective on the removal of gingival hyperplasia in orthodontic patients.



**Figure 2** - One month after the surgical procedure.

## Questions to the authors

### **1) What would be the two main advantages and disadvantages of using $\text{CO}_2$ laser to correct gingival hyperplasia?**

The two main advantages are: The absence of bleeding, allowing the bonding of brackets during the same clinical session, and an easier post-operative recovery, which is usually fast and with minimal discomfort. The disadvantages are the high cost of the equipment and the need for specialized training for the procedure.

### **2) It would be interesting to include two other groups with conventional gingivectomy and electrosurgery? What would be the next step in this research?**

The idea of including the group of conventional gingivectomy was thought at the beginning of the work, but since this was an early work between the Laser and Orthodontics Departments at our University, we decided to do it later. We did not think of electrosurgery because of the contraindications that this technique presents.

### **3) The high cost of a $\text{CO}_2$ laser device compensates its use in a private practice?**

The cost is really high, but depending on the size of the private practice, the number of partners and the public, would compensate because this laser device can be used for other purposes, such as caries removal, endodontic treatment, apical surgery, surgical treatment of soft tissues lesions, surgical treatment of premalignant and malignant lesions of oral cavity.