

# Cone-Beam computed tomography evaluation of maxillary expansion in twins with cleft lip and palate

Luciane Macedo de Menezes<sup>1</sup>, Fabiane Azeredo<sup>2</sup>, André Weissheimer<sup>3</sup>,  
Juliana Lindemann Rizzato<sup>4</sup>, Susana Maria Deon Rizzato<sup>5</sup>

**Introduction:** The establishment of normal occlusal relationships in patients with cleft lip and palate using rapid maxillary expansion may promote good conditions for future rehabilitation.

**Objective:** This study describes the clinical case of monozygotic twins with unilateral cleft lip and palate at the age of mixed dentition who were treated using the same rapid maxillary expansion protocol, but with two different screws (conventional and fan-type expansion screw). Results were evaluated using plaster models, intraoral and extraoral photographs, and Cone-Beam Computed Tomography (CBCT) scans obtained before the beginning of the treatment, ( $T_1$ ).

**Methods:** The patients were followed up for 6 months after maxillary expansion, when the same tests requested at  $T_1$  were obtained again for review ( $T_2$ ).  $T_1$  and  $T_2$  results were compared using lateral cephalometric tracings and measurements of the intercanine and intermolar distances in the plaster models using a digital caliper.

**Results:** The two types of expansion screws corrected the transverse discrepancy in patients with cleft lip and palate. The shape of the upper arches improved at 10 days after activation.

**Conclusion:** CBCT scans provide detailed information about craniofacial, maxillary and mandibular changes resulting from rapid maxillary expansion. The most adequate screw for each type of malocclusion should be chosen after detailed examination of the dental arches.

**Keywords:** Palatal expansion. Midpalatal fissure. Cone-Beam computed tomography. Orthodontics.

\*Access [www.dentalpress.com.br/revistas](http://www.dentalpress.com.br/revistas) to read entire article.

<sup>1</sup> Professor of Orthodontics, School of Dentistry of PUC-RS, Porto Alegre.

<sup>2</sup> Student of Specialization in Orthodontics, PUC-RS, Porto Alegre.

<sup>3</sup> PhD student in Orthodontics and Facial Orthopedics, PUC-RS, Porto Alegre.

<sup>4</sup> Specialization student in Orthodontics, PUC-RS, Porto Alegre.

<sup>5</sup> Professor of Orthodontics, School of Dentistry of PUC-RS, Porto Alegre.

**How to cite this article:** Menezes LM, Azeredo F, Weissheimer A, Rizzato JL, Rizzato SMD. Cone-Beam computed tomography evaluation of maxillary expansion in twins with cleft lip and palate. *Dental Press J Orthod.* 2012 Mar-Apr;17(2):42-5.

**Submitted:** January 01, 2010 - **Revised and accepted:** January 01, 2011

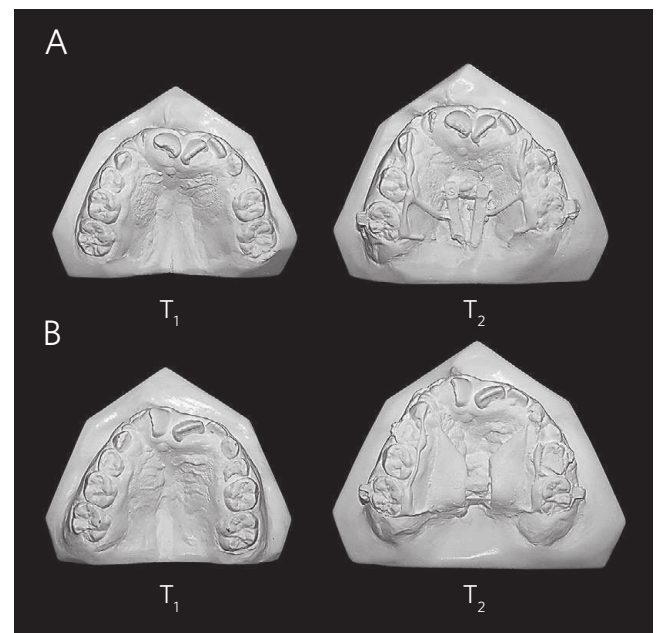
» The authors report no commercial, proprietary, or financial interest in the products or companies described in this article.

**Contact address:** Luciane Macedo de Menezes  
Av. Ipiranga, 6681 – Prédio 06 – Caixa Postal 1429 – Porto Alegre/RS – Brazil  
CEP: 90.619-900 – E-mail: [luciane.menezes@puers.br](mailto:luciane.menezes@puers.br)

## Editor's abstract

Cleft lip and palate, a congenital malformation with important clinical and psychosocial impacts, may occur alone (non-syndromic origin) or be associated with multiple congenital anomalies (syndromic origin). Some of the complications that may affect patients with cleft lip and palate are abnormal tooth number and shape, anterior and posterior cross bite, and facial esthetics compromised by maxillary retrusion or mandibular prognathism. Maxillary hypoplasia in individuals with a cleft palate is often not limited to the dentoalveolar segment, but may also involve the paranasal, infraorbital and zygomatic regions.

The establishment of normal intermaxillary relations in patients with cleft lip and palate at the right time using rapid transverse maxillary expansion may ensure good conditions for future rehabilitation. The authors of this study aimed to describe the clinical case of monozygotic twins with cleft lip and palate who underwent rapid maxillary expansion (RME) with two types of expander. Two maxillary expansion protocols were used, one using a tooth-anchored expander and a fan-type ("butterfly") expansion screw, and the other, a modified Haas appliance (palatal mucosa and tooth anchorage) and a conventional screw. Six months after the end of the active phase, new orthodontic investigations were requested, and results were compared with baseline records. Lateral cephalometry, measurement of plaster models, and visual examination of CT scans were used for analyses.



**Figure 1** - Comparison between initial models ( $T_1$ ) and the models obtained 6 months after maxillary expansion ( $T_2$ ) in patients A e B.

Results revealed that the two types of expansion screws were effective in correcting the transverse discrepancy, and the shape of the upper arches was improved 10 days after activation. CT scans showed the disjunction of the frontonasal, frontomaxillary and frontozygomatic sutures (Fig 1). Therefore, we may conclude that, according to the study results, expansion achieved with the conventional and the fan-type screw effectively corrected the transverse discrepancy in patients with cleft lip and palate and improved the shape of their maxillary arches.

## Questions to the authors

### **1) Do you think there would be any differences in the results found in your study if acrylic pads were added to the fan-type expander, so that it became an appliance with palatal mucosa as well as tooth anchorage?**

This case report compared the action of conventional and fan-type screws by measuring intermolar and intercanine distances. The presence of acrylic pads in the fan-type expander may not change the limited expansion of intermolar distance achieved by the fan-type screw. However, no measurements of dentoalveolar and skeletal dimensions were made transversely to assess and compare the effect of the acrylic pad on both immediate and long-term RME effects. An acrylic pad may be important, particularly after the active phase of RME, during which, according to Haas,<sup>1,2,3</sup> the acrylic pad works as a mechanical protection against possible relapse in the dentoalveolar region during the retention phase. A study with two groups of patients with cleft lip and palate who underwent RME using appliances anchored on teeth and palatal mucosa and who were divided according to type of expansion screw (conventional or fan-type) found that the maxilla moved downwards in both groups and remained so during the retention phase. The conventional screw promoted greater expansion in the posterior region, whereas the effect of the fan-type expander was more marked in the anterior region.<sup>4</sup> However, this issue should be further explored in prospective, randomized clinical trials to evaluate and compare the effects of RME using tooth-anchored appliances or appliances anchored to teeth and palatal mucosa, in which conventional and fan-type expansion screws should be used, and variables should be controlled, such as the number of teeth used for anchorage, standardized position of expansion screws, and the size of the orthodontic wire used to manufacture the appliances.

### **2) Why were examinations not repeated right after maxillary expansion? Do you believe that results would be different from the results found?**

Patients with cleft lip and palate are usually involved in long-term multidisciplinary treatments and often undergo radiographic or CT examinations.

The effective cone-beam CT (CBCT) radiation dose varies according to CT scanner manufacturer and the technical specifications set before scanning, such as field of view, exposure time, milliamperes and kilovolts.<sup>5</sup> The amount of radiation is similar to the dose emitted during periapical examination of the complete dentition,<sup>6</sup> or up to 10 times greater than that of a panoramic radiograph.<sup>7</sup> X-ray risks are cumulative, and the patients with cleft lip and palate remain under treatment for a long time, during which more complementary exams the use X-rays will have to be obtained. Therefore, the authors decided that it would be wise not to expose the patients to an extra dose of radiation. Whether there would be differences in the results found, we believe that no, because the appliances remained in the oral cavity. In a recent prospective randomized clinical trial with patients without cleft lip and palate, the immediate effects of RME using both tooth-anchored and mucosa-and-tooth-anchored appliances were similar.<sup>8</sup> Further well-designed clinical studies should be conducted to fully elucidate this issue in cases of patients with uni- or bilateral cleft lip and palate.

### **3) Based on the statement published in the Discussion Session, “CBCT generates images of the craniofacial complex at submillimeter resolutions...” I ask: It would not be more reliable to make all the measurements directly on the CT images using specific software instead of using lateral cephalometry and making measurements on the plaster models?**

In this case report, cephalometric studies were conducted using images that simulate lateral radiographs generated by CBCT. The advantages of such images are the fact that they are not magnified and are similar to conventional cephalometric radiographs. However, the ideal procedure for evaluation and comparison of orthopedic treatments in the maxillofacial region is the construction, superimposition and measurement of distances between surfaces in a 3D model, as described in details in the studies published by the researchers of the University of North Carolina.<sup>9,10,11</sup> However, such technologies remain limited to a few research centers, whereas traditional radiographs and plaster models are still routinely used by most clinical orthodontists.

#### 4) As it is a case study, would you expand the results to use in the general populations that have the same problem?

Before the effects of a treatment may be applied to the general population, they should be exhaustively studied in well-designed trials, in which the information generated has a high degree of scientific evidence, such as in

meta-analyses and prospective randomized clinical trials. Evidence-based Orthodontics is based on the best scientific evidence available associated with professional experience and patient expectations. As a case report has a low evidence level, the effects of RME presented in this study should be interpreted cautiously, as they may not reflect the effects expected for all the patients with cleft lip and palate.

#### REFERENCES

1. Haas AJ. Rapid expansion of the maxillary dental arch and nasal cavity by opening the midpalatal suture. *Angle Orthod.* 1961;31(2):73-90.
2. Haas AJ. The treatment of maxillary deficiency by opening the midpalatal suture. *Angle Orthod.* 1965;35(3):200-17.
3. Haas AJ. Palatal expansion: just the beginning of dentofacial orthopedics. *Am J Orthod.* 1970;57(3):219-55.
4. Lanes MA. Expansão rápida maxilar com parafuso convencional e limitador posterior em pacientes com fissura transforame incisivo: alterações verticais e ântero-posteriores [dissertação]. Porto Alegre (RS): Pontifícia Universidade Católica do Rio Grande do Sul; 2006. Disponível em: [http://tede.pucrs.br/tde\\_busca/arquivo.php?codArquivo=381](http://tede.pucrs.br/tde_busca/arquivo.php?codArquivo=381). Acesso: 8 jun. 2010.
5. Ludlow JB, Ivanovic M. Comparative dosimetry of dental CBCT devices and 64-slice CT for oral and maxillofacial radiology. *Oral Surg Oral Med Oral Pathol Oral Radiol Endod.* 2008;106(1):106-14.
6. Hatcher DC, Aboudara CL. Diagnosis goes digital. *Am J Orthod Dentofacial Orthop.* 2004;125(4):512-5.
7. Cohnen M, Kemper J, Möbes O, Pawelzik J, Mödder U. Radiation dose in dental radiology. *Eur Radiol.* 2002;12(3):634-7. Epub 2001 Jun 1.
8. Weissheimer A. Efeitos imediatos da expansão rápida da maxila no sentido transversal com os disjuntores tipo Haas e Hyrax em tomografia computadorizada cone beam [dissertação]. Porto Alegre (RS): Pontifícia Universidade Católica do Rio Grande do Sul; 2008. Disponível em: [http://tede.pucrs.br/tde\\_busca/arquivo.php?codArquivo=1960](http://tede.pucrs.br/tde_busca/arquivo.php?codArquivo=1960). Acesso: 20 July 2009.
9. Cevidanes LH, Bailey LJ, Tucker GR Jr, Styner MA, Mol A, Phillips CL, et al. Superimposition of 3D cone-beam CT models of orthognathic surgery patients. *Dentomaxillofac Radiol.* 2005;34(6):369-75.
10. Cevidanes LH, Motta A, Proffit WR, Ackerman JL, Styner M. Cranial base superimposition for 3-dimensional evaluation of soft-tissue changes. *Am J Orthod Dentofacial Orthop.* 2010;137(4 Suppl):S120-9.
11. Cevidanes LH, Heymann G, Cornelis MA, DeClerck HJ, Tulloch JF. Superimposition of 3-dimensional cone-beam computed tomography models of growing patients. *Am J Orthod Dentofacial Orthop.* 2009;136(1):94-9.