

Assessment of the mandibular symphysis of Caucasian Brazilian adults with well-balanced faces and normal occlusion: The influence of gender and facial type

Karine Evangelista Martins Arruda¹, José Valladares Neto², Guilherme de Araújo Almeida³

Objective: This study aimed to establish cephalometric reference values for mandibular symphysis in adults. Dentoalveolar, skeletal and soft tissue variables were measured considering the influence of gender and facial type.

Methods: The sample consisted of sixty cephalometric radiographs of white Brazilian adult patients, with a mean age of 27 years and 6 months, who had not undergone orthodontic treatment and who presented well-balanced faces and normal occlusion. The sample was standardized according to gender (30 males and 30 females) and facial type (20 were dolichofacial, 20 mesofacial and 20 brachyfacial).

Results: The results showed that male and female symphyses are similar, except for symphyseal height, which was greater in males. In terms of facial type, the dolichofacial group presented narrower symphysis in dentoalveolar and basal areas, with a more accentuated lingual dentoalveolar inclination.

Conclusion: The brachyfacial group showed broader symphysis in the dentoalveolar and basal areas and a greater buccal dentoalveolar inclination. The projection of the chin was 6.67 mm below the subnasal vertical line and there was no significant difference between the genders or facial types.

Keywords: Mandibular symphysis. Gender. Facial type. Facial balance.

¹ MSc in Dental Clinic, FO-UFG. Specialist in Orthodontics, ABO/MG.

² Assistant Professor of Preventive Orthodontics, FO-UFG. Professor of Specialization course in Orthodontics, ABO/MG.

³ Associate Professor of Orthodontics, FO-UFU. Coordinator of Specialization Course in Orthodontics, ABO/MG.

How to cite this article: Arruda KEM, Valladares Neto J, Almeida GA. Assessment of the mandibular symphysis of Caucasian Brazilian adults with well-balanced faces and normal occlusion: The influence of gender and facial type. *Dental Press J Orthod.* 2012 May-June;17(3):40-50.

Submitted: September 01, 2008 - **Revised and accepted:** December 30, 2009

» The authors report no commercial, proprietary or financial interest in the products or companies described in this article.

» Patients displayed in this article previously approved the use of their facial and intraoral photographs.

Contact address: José Valladares Neto
R. 132, 113, lote 13 – Setor Sul – Goiânia/GO – Brazil
Zip code: 74.093-210 – E-mail: jvalladares@uol.com.br

INTRODUCTION

Mandibular symphysis is an anatomical structure of the mandible in which the lower incisors are found including the anterior portion of the chin. Mandibular symphysis contributes to the composition and balance of facial harmony^{2,15,25} and must be considered when deciding on orthodontic treatment in borderline cases.^{12,20,30}

Mandibular symphysis is morphologically divided into two regions, the dentoalveolar and basal symphyses.²² The dentoalveolar symphysis includes the alveolar process and lower incisors. The long axis of the lower incisors cephalometrically matches the long axis of the alveolar process²² and its inclination is influenced by facial type.^{16,29} This classical concept dates from the Tweed era and defines the lingual inclination of the alveolar long axis (IMPA) in subjects with a high mandibular plane (FMA), while in subjects with low mandibular planes, the long axis is more buccally tipped.²⁹ According to this view, the positioning error of the lower incisors could compromise the stability of orthodontic results and facial esthetics.²⁹

Alveolar bone thickness varies according to location and facial type.¹² Generally, there is a greater bone thickness at the apex than in the cervical region, and towards the lingual surface when compared to the labial surface.¹² This explains the higher prevalence of bone dehiscence and fenestration on the buccal side, and gives rise to periodontal concern about the anterior orthodontic movement of the lower incisors.⁸

However, studies related to buccal projection^{3,4,9,10,19,28,30} of lower incisors present conflicting results, probably due to methodological differences and limitations, and the multifactorial etiology of periodontal recession.³¹ However, thin buccal bone coverage of the root^{10,12,28} associated to excessive buccal movement³¹ and insufficient thickness of the marginal gingiva have been shown^{19,31} to be significant variables in the development of non-inflammatory gingival recession.

In terms of cortical bone, the lingual side is thicker than the buccal, and due to the inclination of the lower incisors, there is a closer approximation of the root apex to the lingual cortical. This apex relationship is particularly evidenced in subjects

with vertical growth tendency¹² and Class III malocclusion.^{12,22} since the alveolar bone is very narrow in this region. Bone in the referred apical region is assumed as non-remodelable anatomical limit and restricts the orthodontic retraction movement, because it can perforate the lingual cortical.^{12,20,24}

The basal symphysis is part of the main body of the mandibular symphysis with more apical location, setting the hard menton outline. The menton is considered to be a recent phylogenetic acquisition (just over 10,000 years ago), exclusive to *Homo sapiens*. The morphological variation of the menton has a strong genetic basis and its occurrence may have emerged casually¹⁴ and, did not add any biomechanical advantages for mastication.

The long axis of the basal symphysis differs cephalometrically from that of the alveolar symphysis.²² Tooth movement of the lower incisors cannot influence the shape or position of the basal symphysis. The relationship between the height and width of the mandibular symphysis is one of Björk's five criteria for establishing the mandibular rotation pattern during growth.^{1,5,6,27} For long and narrow symphyses, the tendency of mandibular rotation during growth is predominantly vertical; when short and wide, it is predominantly horizontal.⁵ In the vertical pattern, a mandibular symphysis with a long axis and greater lingual inclination has also been observed.^{12,16}

The morphology of the mandibular symphysis is also influenced by the sagittal growth pattern.^{12,16,22} In Class III malocclusion, a higher,²² narrower¹² symphysis with greater anterior projection¹⁶ and evident lingual inclination of the long axis has been identified.^{16,22}

In addition, the height and projection of the basal symphysis influence the position of the adjacent soft tissue and are significant in terms of aesthetic and facial harmony.^{2,15,25} Menton deformities can be treated satisfactorily using basilar genioplasty. For this procedure, it is necessary to establish normative values for height and anterior projection, that are both influenced by ethnicity and sexual dimorphism. These values are usually higher in males.²

Despite its relevance, few studies have focused on mandibular symphysis^{17,26} and its standard cephalometric values. Some studies lack for uniformity in the sample regarding ethnicity, facial pattern and malocclusion. Hence, the objective of this study was

to describe the morphology of the mandibular symphysis in a sample of Brazilian adults with well-balanced faces and normal occlusion, individualized in terms of gender and facial type variables.

SUBJECTS AND METHODS

The research project was submitted to the Research Ethics Committee of *Universidade Federal de Uberlândia* and approved under the protocol number 247/07.

Sample selection

The total sample, composed of 60 subjects with well-balanced faces, equally divided between the genders, was prospectively selected from students of the Federal University of Goiás Dental School and complemented with subjects retrospectively selected from patients with minimum morphological occlusion deviations from the researchers' private clinics. The mean age of participants was 27 years and 6 months. The sample was also evenly distributed between the possible vertical variations in terms of facial type (dolichofacial, mesofacial and brachyfacial) (Table 1).

The following inclusion criteria had to be fulfilled by all participants: 1) be Brazilian; 2) Caucasian; 3) males over 18 and females over 16; 4) ANB between 0° and 4°; 5) well-balanced face; 6) apparent facial symmetry (clinically determined); 7) normal occlusion with Class I canine and molar relationship, overjet and overbite up to 3 mm and crowding up to 4 mm; 8) presence of all teeth, except third molars; 9) no serious medical condition; 10) no history of facial or dental trauma; 11) no previous orthodontic or prosthetic treatment, facial plastic surgery or orthognathic surgery.

In this study, all the subjects showed a well-balanced face according to Capelloza's Pattern I description.^{7,23} There were no skeletal discrepancies in sagittal

or vertical directions, and the profile was orthognathic, in other words, with gentle facial convexity, lips sealed when resting, the proportion of the facial thirds and the upper lip height were equal to half the height of the lower lip. In order to define the facial type, concordance between the subjective facial analysis and the angle of the mandibular plane (SN.GoGn) were used as criteria. Subjects were classified as mesofacial when SN.GoGn was between 30° and 34°, brachyfacial when less than 30° and dolichofacial when greater than 34°. For profile evaluation, the menton-neck line (length and angle) was used. Subjects were characterized as brachyfacial when the line was elongated and the angle more open. For mesofacial subjects, the line was proportional and the angle close to 90°. For dolichofacial subjects, the line was shortened and the angle reduced. For the frontal evaluation, the referential used was the width between gonion landmarks. This reference was comparatively larger for the brachyfacial type, balanced for the mesofacial type and narrow for the dolichofacial type. Cases in which the facial analysis was not compatible with the SN.GoGn angle were excluded from the sample (Fig 1).

Cephalometric method

After the radiographs were taken, the cephalogram was performed by a single calibrated examiner. Ultraphan paper, a 0.5 mm propelling pencil, soft white eraser, ruler, protractor, square (Desotec) and lightbox were used. The tracings were performed using predefined points, lines and planes in a dark room using black cardboard to protect the edges of the radiographic film. The values obtained were rounded off to 0.5 or the nearest whole number when decimal values were found. Radiographs were excluded when it was impossible to identify anatomical design.

The cephalometric landmarks used were (Fig 2):

- » Or (orbital): The lowest edge of the infraorbital margin.
- » Po (Porion): Highest edge of the external auditory canal.
- » Gn (gnathion): Lowest and most anterior edge of the symphysis.
- » Me (menton): The lowest edge of the menton symphysis outline.
- » Go (gonion): The lowest and most posterior point of the gonial angle.

Table 1 - Sample distribution according to gender and facial type.

	Brachyfacial	Mesofacial	Dolichofacial	Total
Male	10	10	10	30
Female	10	10	10	30
Total	20	20	20	60

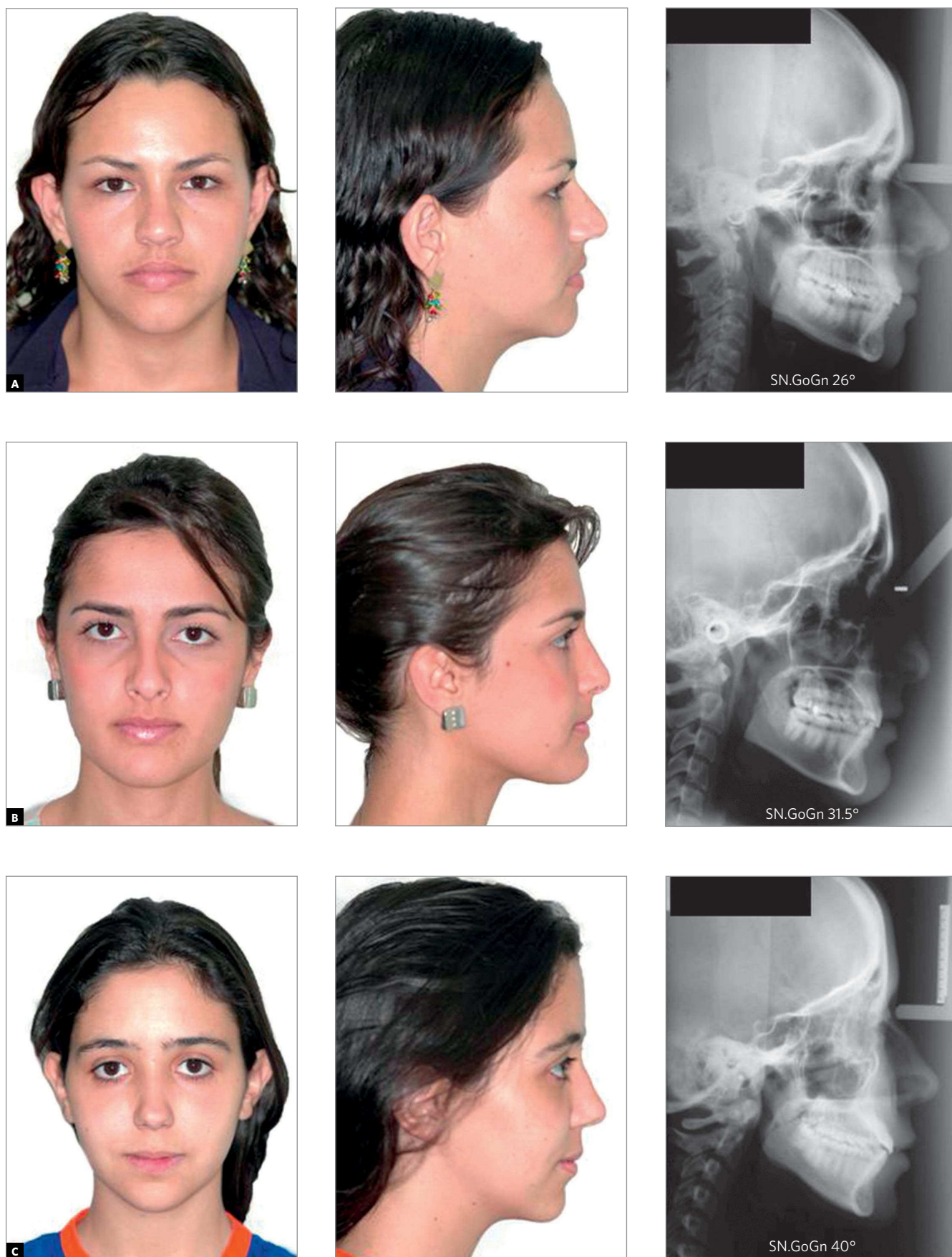

Figure 1 - Extraoral photographs (front and profile) and lateral radiographs with corresponding SN.GoGn values, representative of the female sample. Facial balance was classified into three facial types: **A)** Brachyfacial, **B)** mesofacial and **C)** dolichofacial.

- » Pog (pogonion): Most prominent edge in the symphysis.
- » Pog' (soft pogonion): Most prominent edge of menton soft tissue.
- » Pog'' (lingual pogonion): Suggested by Nojima et al²², represents the most posterior point located in the external lingual cortical of the mandibular symphysis.
- » Sn (subnasal): Point located at the junction between the upper lip and the base of the nose.
- » IiI: The uppermost point of the lower incisor incisal edge.
- » AIi: Lowest point located at the root apex of the lower incisor.
- » Sf: Midpoint between the outer lingual and outer buccal corticals in the IiAIperp line, suggested by the authors of this study.
- » Mi: Point on the mesiobuccal cusp tip of the lower first molar.

The lines and planes used were (Fig 3):

- » OrPo: Frankfurt horizontal plane.
- » GoMe: Mandibular plane.
- » IiAIi: Long axis of the lower incisors also representing the long axis of the alveolar symphysis.
- » IiAIperp line: Tangent to the apex of the lower incisors perpendicular to their long axis as defined by the authors of this study.
- » Sn perp Orpo: Line passing through the Sn, perpendicular to the Frankfurt plane.
- » SfMe: Long axis of the basal symphysis.
- » IiMi: Mandibular occlusal plane (MOP), suggested by Arnett et al.²

The angular measurements used were (Fig 3):

- » SN. GoGn: Mandibular plane inclination in relation to the base of the skull.
- » IMPA (GoMe.IiAIi): Lower incisor inclination in relation to the mandibular plane, also representing the alveolar symphysis inclination.
- » FMIA (OrPo.IiAIi): Lower incisor inclination in relation to Frankfurt plane.
- » IiAIi.MOP: Lower incisor inclination in relation to the mandibular occlusal plane.
- » SfMe. GoMe: Inclination of the basal symphysis in relation to the mandibular plane.
- » SfMe. Orpo: Inclination of the basal symphysis in relation to the Frankfurt plane.

The linear measurements evaluated were (Fig 3):

- » IiAIiMe: Distance from the projection of the long axis of the lower incisors on the mandibular plane to the Me point.
- » BBD: Buccal bone distance, comprising the thickness of the buccal alveolar bone at the apex of the lower incisors, measured from the AIi point to the external buccal cortical point, using the path of the IiAIperp line.
- » LBD: Lingual bone distance, comprising the thickness of the lingual alveolar bone at the apex of the lower incisors, measured from the AIi point to the external lingual cortical point, using the path of the IiAIperp line.
- » PogPog'': Distance between the pogonian and the lingual pogonian points representing the thickness of the basal symphysis, suggested by Nojima et al.²²
- » IiMe: Height of the long axis of the mandibular symphysis.
- » Pog'Sn (perpOrPo): Distance from the menton soft tissue to the subnasal line perpendicular to the Frankfurt plane.

Systematic error

In order to evaluate the systematic error, 20 randomly selected radiographs used in this study, were remeasured after 30 days. To determine intra-examiner error, the paired t test was applied. Random error was calculated using Dahlberg's test¹³ when error values greater than 1.5° or 1.0 mm were found. As noted in Table 2, systematic error was statistically significant for SN.GoGn and SfMe.OrPo, but with a slight average difference (0.67° and 0.62°, respectively), irrelevant from the clinical point of view. The results revealed a random error less than 1.5° and 1.0 mm, indicating the reliability of the data.

Statistical Analysis

Data normality of distribution was verified by the Kolmogorov-Smirnov test. A comparison of cephalometric measurements according to gender and facial type was performed using Student's t test for independent samples and analysis of variance (ANOVA), respectively. When the ANOVA indicated a statistically significant difference, the Tukey test for multiple comparisons was applied.

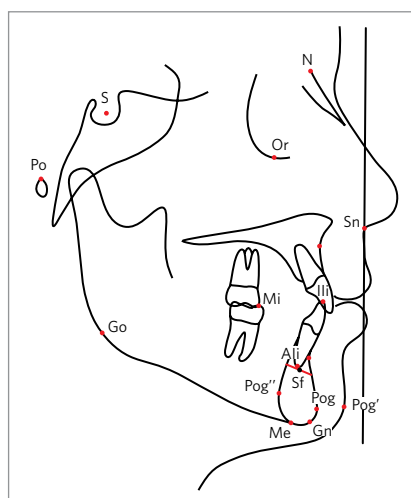


Figure 2 - Cephalometric landmarks used, emphasizing the Sf.

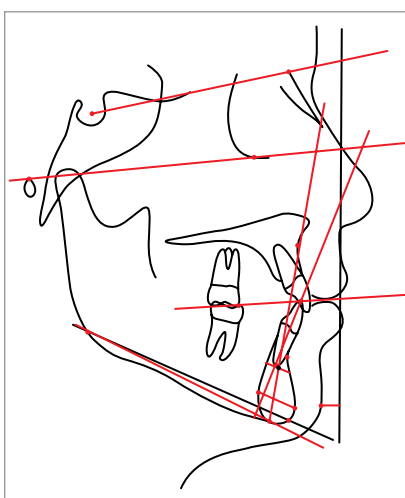


Figure 3 - Lines, planes and cephalometric measurements.

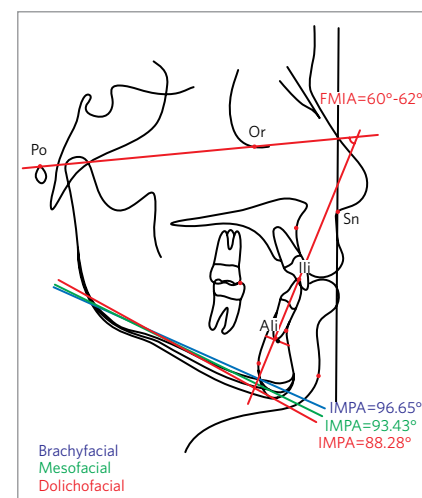


Figure 4 - Variations in dentoalveolar symphysis inclination means (long axis of the lower incisors, measured using IMPA and FMIA) as a variation of the mandibular plane (FMA).

For the statistical treatment of data, the SPSS for Windows (version 16.0) was used, considering a significance level of 5% ($\alpha = 0.05$).

RESULTS

Composition and characteristics of the sample

The sample consisted of subjects ranging from 18 to 38 years for males and 16 to 35 years for females. All subjects presented well-balanced faces, confirmed by subjective facial analysis and cephalometric measurements. The average ANB angle was $2.16 \pm 1.63^\circ$, indicating harmony in the sagittal position of both maxilla and mandible, and the average SN.GoGn was $32.11 \pm 5.46^\circ$, which confirmed facial balance in the vertical position. Classification in terms of facial type was clearly established by SN.GoGn cutoff values (Fig 4).

In this study, the buccolingual inclination of the lower incisors represented the long axis of alveolar symphysis. The cephalometric measurements which contributed to this evaluation were IMPA, FMIA, IiiAiI.POM and IiiAiI.Me. In general, the lower incisors were implanted perpendicular to the mandibular base (IMPA = 92.78°), buccally in relation to the Frankfurt horizontal plane (FMIA = 61.13°) and lower occlusal plane (IiiAiI.MOP = 63.10°) and the projection of the long axis of these teeth is about 9.51 mm after the Me point (Table 3).

The amount of buccal and lingual bone at the apex of the lower incisor was measured by BBD

and LBD widths, respectively. In this sample, the amount of buccal bone (BBD = 5.12 mm) was thicker than the amount found for lingual bone (LBD = 3.55 mm) (Table 3). The long axis of the basal and alveolar symphyses was not aligned. The basal symphysis was inclined 22° lingually in terms of the dentoalveolar symphysis in relation to both the mandibular and Frankfurt planes (SfMe.GoMe = $70.33 \pm 5.44^\circ$ and SfMe.OrPo = $83.13 \pm 6.50^\circ$). The width of the basal symphysis baseline was 15.61 mm (PogPog''), considered almost twice (BBD LBD = 8.67 mm) that of the dentoalveolar symphysis at the apex of the lower incisors. Symphysis height (IiiAiI.Me) was 44.78 ± 3.79 mm and in terms of soft tissue, the projection of the Pog' remained about 6.7 mm below the vertical subnasal line [Pog'-Sn(perp OrPo)] (Table 3).

Gender

Regarding gender, the results showed no statistically significant difference for most cephalometric measurements. Hence, as a general rule, both male and female mandibular symphyses have a similar morphology, except for a slight inclination of the basal symphysis (SfMe.PoOr) and height (IiiAiI.Me).

The basal symphysis inclination in relation to the Frankfurt plane (SfMe.PoOr), was 84.97° for males and 81.28° for females, and this difference was statistically significant at 5% level. However, caution

Table 2 - Systematic error values (paired t test) and random error (Dahlberg).

	First measurement		Second measurement		t	p	Random error
	Mean	s.d.	Mean	s.d.			
SN.GoGN (degrees)	32.65	5.61	33.32	5.42	-3.857	0.001*	0.72
IMPA (degrees)	90.58	5.47	90.5	5.42	0.164	0.871 (ns)	1.41
FMIA (degrees)	62.5	4.96	62.37	4.86	0.253	0.803 (ns)	1.42
IliAli.MOP (degrees)	64.67	5.17	64.95	5.83	-0.456	0.654 (ns)	1.47
IliAliMe (mm)	-7.63	5.11	-6.78	6.29	-0.430	0.672 (ns)	1.01
BBD (mm)	6.00	2.22	6.15	2.14	-0.653	0.522 (ns)	0.72
LBD (mm)	3.53	0.95	3.60	0.88	-0.314	0.757 (ns)	0.74
PogPog" (mm)	16.5	1.97	16.47	1.84	0.165	0.871 (ns)	0.47
SfMe.GoMe (degrees)	71.08	5.16	71.3	4.71	-0.920	0.369 (ns)	0.77
SfMe.OrPo (degrees)	82.25	6.72	81.63	6.43	2.490	0.022*	0.89
IliMe (mm)	45.3	4.19	45.28	4.41	0.165	0.871 (ns)	0.47
PogSn(perpOrPo) (mm)	-6.58	3.74	-6.15	3.71	-1.428	0.169 (ns)	0.87

Table 3 - Cephalometric characteristics of the total sample.

Variable	Mean	s.d.	Maximum value	Minimum value
SN.GoGn (degrees)	32.11	5.46	42	23
IMPA (degrees)	92.78	6.02	103	79.5
FMIA (degrees)	61.13	5.23	71	46
IliAli.MOP (degrees)	63.10	5.43	75	54
IliAliMe (mm)	-9.51	3.11	-3	-19
BBD (mm)	5.12	1.70	12.5	2
LBD (mm)	3.55	1.07	6	1.5
PogPog" (mm)	15.61	2.13	21.5	11
SfMe.GoMe (degrees)	70.33	5.44	84	51.5
SfMe.OrPo (degrees)	83.13	6.50	96	71
IliMe (mm)	44.78	3.79	55	39
Pog'Sn(perp OrPo) (mm)	-6.66	3.88	1	-14

Table 4 - Cephalometric values of the sample according to gender and facial type.

	Total	Gender			p	Facial type			p
		M	F	p		Brachyfacial	Mesofacial	Dolichofacial	
SN.GoGN (degrees)	32.10 (44.46)	32.91 (44.43)	31.30 (46.30)	0.255	26.50 (42.12) ^A	31.65 (41.10) ^B	38.17 (43.86) ^C	0.000	
IMPA (degrees)	92.78 (46.02)	93.63 (45.45)	91.93 (46.52)	0.278	96.65 (44.58) ^A	93.42 (45.00) ^A	88.27 (45.38) ^B	0.000	
FMIA (degrees)	61.12 (45.23)	60.07 (44.80)	62.18 (45.51)	0.118	61.37 (44.60)	61.00 (44.68)	61.00 (46.47)	0.967	
Ili.MOP (degrees)	63.10 (45.42)	63.31 (45.29)	62.88 (45.64)	0.760	60.67 (44.09) ^A	62.60 (45.29) ^{AB}	66.02 (45.60) ^B	0.005	
IliAliMe (mm)	-9.50 (43.10)	-8.83 (42.86)	-10.18 (43.24)	0.093	-10.37 (42.07) ^A	-10.07 (44.17) ^{AB}	-8.07 (42.22) ^B	0.037	
BBD (mm)	5.11 (41.70)	5.27 (42.04)	4.97 (41.28)	0.499	5.72 (42.00) ^A	5.35 (41.52) ^{AB}	4.27 (41.20) ^B	0.017	
LBD (mm)	3.55 (41.06)	3.57 (41.13)	3.53 (41.02)	0.905	4.22 (40.86) ^A	3.37 (41.15) ^B	3.05 (40.82) ^B	0.001	
PogPog" (mm)	15.60 (42.12)	15.30 (42.16)	15.91 (42.08)	0.265	16.07 (41.89) ^A	16.12 (42.25) ^A	14.62 (41.96) ^B	0.038	
SfMe.GoMe (degrees)	70.33 (45.44)	71.45 (45.98)	69.21 (44.68)	0.113	71.42 (44.37)	70.10 (46.63)	69.47 (45.17)	0.520	
SfMe.OrPo (degrees)	83.12 (46.50)	81.28 (46.90)	84.96 (45.60)	0.027	86.95 (44.51) ^A	82.72 (46.28) ^{AB}	79.70 (46.60) ^B	0.001	
IliMe (mm)	44.77 (43.79)	42.58 (42.13)	46.97 (43.85)	0.000	43.17 (43.06) ^A	44.45 (43.77) ^{AB}	46.70 (43.79) ^B	0.010	
PogSn(perpOrPo) (mm)	-6.65 (43.87)	-6.27 (43.89)	-7.05 (43.89)	0.439	-5.15 (43.28)	-6.90 (43.89)	-7.92 (44.07)	0.071	

should be exercised when evaluating this finding, because the systematic error was significant for this measurement (Table 4). Mean values for mandibular symphysis height (IiMe) were 46.97 mm and 42.58 mm, respectively, in both males and females. On average, male mandibular symphysis was 10% higher than female symphysis, and this finding was statistically significant ($p < 0.00$). Therefore, the height of the mandibular symphysis was considered a distinguishing criterion between the genders (Table 4).

Facial type

Facial type had no correlation with the FMIA, SfMe.GoMe or Pog'Sn (perpOrPo) measurements. IMPA and Pog'Pog'' measurements were similar for brachyfacial and mesofacial types and LBD measurements were similar for mesofacial and dolichofacial types SfMe.OrPo, BBD, IiAIiMe, IiMe and Ii.MOP were statistically different for the extreme facial types (dolichofacial and brachyfacial) but similar for the mesofacial type (Table 4).

DISCUSSION

This study described the cephalometric characteristics of the mandibular symphysis of a sample consisted of 60 Brazilian Caucasian adults residents of the central region of the country, with an average age of 27 years and 6 months. Subjects presented well-balanced faces and normal occlusion. The measurements analyzed included dentoalveolar, skeletal and soft tissue structures of the mandibular symphysis and the main objective was to evaluate the influence of gender and facial type on the morphology of the symphysis. In this study, the distinction between facial types was made using concordance between facial analysis and the SN.GoGn value. The cutoff value to characterize the mesofacial type was performed with a slight variation (2.0°) from the normative value (32°). Hence, when the facial features were compatible with a SN.GoGn less than 30° , the type was considered well-balanced brachyfacial and dolichofacial when over 34° . From this sample, it can be seen that reading the SN.GoGn angle is quite adequate for evaluation of facial type, just as Tweed suggested in relation to the FMA angle.²⁹ The data obtained

in this study confirmed certain characteristics of the mandibular symphysis already described in the literature, but it also unprecedentedly showed the influence of certain measurements when drawing up individualized therapeutic targets for Brazilians.

Gender

The similarities between male and female mandibular symphyses are evident, except in the case of height. The results in general showed significant morphological similarity between the dentoalveolar and basal symphyses, both in thickness and inclination. The absence of sexual dimorphism for the IMPA angle has also been confirmed by other studies^{17,26} involving normal occlusion.

The expectation of finding a male symphysis statistically more prominent than the female was not confirmed in this study, same findings were previously reported by Scavone et al²⁵ and Arnett et al.² The results confirmed that both the width of the basal symphysis and its anterior projection are similar between the genders. The perception of a more projected mandibular symphysis in males may be explained by a greater vertical tendency and especially by its greater height. On average, the height of the mandibular symphysis in males was 47 mm and 42.5 mm in females. This difference was statistically significant ($p = 0.0$) and can thus be considered a differentiating factor between the genders.

Facial type

In this study, the sample was based on subjects with skeletally well-balanced faces, but with variations in their mandibular plane angles. In addition to a subjective facial analysis, the subjects were categorized into three distinct facial types: dolichofacial, mesofacial and brachyfacial. One of the main objectives of this study was to identify possible variations in the morphology of mandibular symphysis from the premise of a variation in the facial morphology not involving the extremes.

Dolichofacial types presented features well described in the literature,^{5,6,12,27} which include narrower and higher alveolar and basal symphyses with greater lingual inclination of the lower incisors. For this reason, the projection of the long axis of the alveolar symphysis was closer to the Me

point (IIiAIiMe) in the dolichofacial types. These characteristics are typical morphological signs of subjects who are hyperdivergent or also called long faced. This study showed the tendency in the mandibular symphysis morphology in well-balanced dolichofacial type subjects and which probably becomes more accentuated as the vertical gap increases. The average thickness of the alveolar symphysis in the region of the apex of the lower incisors found by Handelman,¹² in 1996, in patients with a high mandibular plane was 5.5 mm. This result was lower than the findings of this study for dolichofacial type people with a well-balanced facial pattern (7.32 mm). However, there were methodological differences between the studies, such as the inclusion of patients with malocclusion, extreme vertical growth patterns and the different criteria for measuring the alveolar symphysis.

After adding the mean values of buccal and lingual thickness (BBD + LBD), the dolichofacial type group showed an average of 7.32 mm, while the average for the mesofacial and brachyfacial type groups was 8.72 mm and 9.94 mm, respectively. These values denote that the alveolar symphysis in the apical region of the lower incisors is on average 20% narrower in dolichofacial types.

For brachyfacial well-balanced faces, the most striking morphological feature was the greater thickness of the bone near the apex of the lower incisors, especially at the lingual region (LBD). In general, the findings of this study are in accordance with the literature in terms of a wider and shorter symphysis, with a greater buccal inclination of the dentoalveolar and basal symphyses for brachyfacial types.

The cephalometric IMPA measurement was influenced by facial type. The mean values were 88.27°, 93.42° and 96.65°, respectively, for the dolichofacial, mesofacial and brachyfacial types. Tweed's concept,^{7,29} is summarized as inclining the incisors and the alveolar portion in the buccal direction as the tendency to grow becomes more horizontal.

In contrast, the FMIA measurement, which evaluates lower incisor inclination in relation to the Frankfurt plane, was less variable with the oscillation of the mandibular plane. According to the results, this angle ranged between 60° and 62° for most patients (Fig 4).

Clinical implications

For the surgical orthognathic planning in cases of menton deformities, a comparison with normative values is needed. Thus, the extent of the surgical movement depends on the pre-surgical measurement of the height and anterior symphysis projection of the face. The height of the mandibular symphysis recommended for male and female Caucasian North Americans is 44 mm and 40 mm, respectively.² This study found higher mandibular symphyses, 47 mm and 42.5 mm, respectively. In other words, a 10% greater proportion for males was maintained, just the absolute value increased.

The expression of a higher mandibular symphysis and a lesser anterior projection in white Caucasian Brazilians contrasts when compared to North Americans. An average position of 6.67 mm below the subnasal line perpendicular to the Frankfurt plane was found, and it is worth noting that no significant difference was found between the genders. In North American Caucasians² the value found was 3.5±1.8 mm for males and 2.6±1.9 mm for females, with a differential methodology in the use of the natural head position. However, the lesser projection of the menton in white Caucasian Brazilians has also been confirmed by other studies^{15,25} (Fig 5).

Because of this difference, the use of normative value guideline of samples from North American Caucasians has been questioned for therapeutic application in white Brazilians.²⁵ This statement can be partly explained by the difference in ethnic origin, as white Brazilian are descendents of people from Mediterranean countries, such as Portugal, Italy and Spain, whereas North American Caucasians are mainly of English, Polish, Dutch, Scottish and French origin. Ethnic and individual diversity in human facial contours in Caucasians from different countries means that normative values²⁵ cannot be applied universally. Another reason to justify this difference is the criterion used for sample selection. Arnett et al² formed a sample with photographic models, unlike this study and others^{15,25} whose basis for selection was well-balanced faces, not always associated with beauty. Hence, it is essential to individualize orthodontic planning according to the population group being analyzed.

The thickness of the dentoalveolar symphysis is another feature of clinical relevance and its

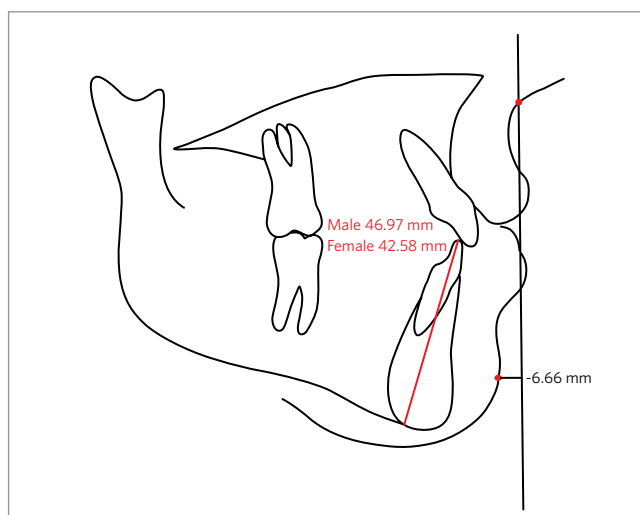


Figure 5 - Menton projection and mandibular symphysis height mean values proposed by this study.

evaluation can establish the extent of safe orthodontic movement of the lower incisors, such as projection and retraction.^{24,28} The possibility or lack of possibility of this orthodontic movement helps in making decisions for borderline cases undergoing orthodontic treatment with or without tooth extraction or in the treatment of skeletal sagittal discrepancies with compensation or with orthognathic surgery.¹² Buccal and lingual corticals at the level of the incisor apex may represent the lower anatomic limits for orthodontic movement, since there is no bone apposition^{12,20,28}. When tooth movement exceeds the limits imposed by the alveolar symphysis morphology, there could be a risk of instability or iatrogenesis.^{12,20,30} Hence, severe skeletal discrepancies in narrow alveolar symphyses limit orthodontic compensation and require orthognathic surgery. This concern about mandibular symphysis thickness is particularly acute in dolichofacial types. With the lesser alveolar thickness, subjects with vertical growth are naturally more limited in terms of sagittal orthodontic movement. An example of this clinical difficulty is the planning of this orthopedic treatment in cases of Class II malocclusion with mandibular deficiency and accentuated vertical growth. Mandibular growth with clockwise rotation complicates

orthopedic mandibular correction and requires a compensatory projection of the lower incisors in a narrow symphysis. The periodontal prognosis will depend on the quality of local hygiene and mainly on marginal gingival thickness.^{3,19,31}

Orthodontists have traditionally evaluated lower incisor positioning using angular and linear cephalometric measurements. It is important that a morphological analysis of the dentoalveolar symphysis be added to this simplistic geometric analysis. For this reason, computed tomography to evaluate buccal-lingual bone volume and density in the alveolar region of the symphysis prior to orthodontic treatment has become increasingly common.^{11,18,19,21,24}

Considering these facts and recognizing the undeniable importance of the mandibular symphysis for orthodontic treatment, this study has emphasized the need for individualization. It can be concluded that even for well-balanced facial patterns, some morphological variations are influenced by gender and facial type.

CONCLUSIONS

Based on these results and in accordance with the methodology used, it was concluded that:

- » Mandibular symphysis height was a differentiator between the genders and was, on average, 10% higher in males.
- » The degree of divergence of the mandibular plane tended to influence the inclination of the dentoalveolar symphysis but not that of the basal symphysis.
- » Well-balanced dolichofacial types have a narrower mandibular symphysis in the alveolar and basal portions and a greater dentoalveolar lingual inclination.
- » Well-balanced brachyfacial types have a thicker mandibular symphysis in the alveolar and basal portions and a greater dentoalveolar buccal inclination.
- » The soft tissue projection of the chin was on average 6.66 mm below the subnasal vertical line and there was no distinction between the genders and facial types.

REFERENCES

1. Aki T, Nanda RS, Currier GF, Nanda SK. Assessment of symphysis morphology as a predictor of the direction of mandibular growth. *Am J Orthod Dentofacial Orthop.* 1994;106:60-9.
2. Arnett GW, Jelic JS, Kim J, Cummings DR, Beress A, Worley CM Jr et al. Soft tissue cephalometric analysis: diagnosis and treatment planning of dentofacial deformity. *Am J Orthod Dentofacial Orthop.* 1999;116:239-53.
3. Artun J, Krogstad O. Periodontal status of mandibular incisors following excessive proclination. A study in adults with surgically treated mandibular prognathism. *Am J Orthod Dentofacial Orthop.* 1987;91:225-32.
4. Bimstein E, Crevoisier RA, King DL. Changes in the morphology of the buccal alveolar bone of protruded mandibular permanent incisors secondary of orthodontic alignment. *Am J Orthod Dentofacial Orthop.* 1990;97:427-30.
5. Björk A. Prediction of mandibular growth rotation. *Am J Orthod* 1969;55:585-99.
6. von Bremen J, Panchez H. Association between Björk's structural signs of mandibular growth rotation and skeletofacial morphology. *Angle Orthod.* 2005;75:506-9.
7. Capelloza Filho L. *Diagnóstico em Ortodontia.* Maringá: Dental Press; 2004.
8. Diedrich P. Problems and risks in the movement of the mandibular anterior teeth. *Fortschr Kieferorthop.* 1995;56:148-56.
9. Dorfman HS. Mucogingival changes resulting from mandibular incisor tooth movement. *Am J Orthod.* 1978;74:286-97.
10. Engelking G, Zachrisson BU. Effects of incisor repositioning on monkey periodontium after expansion through the cortical plate. *Am J Orthod.* 1982;82:23-32.
11. Fuhrmann R. Three-dimensional interpretation of labiolingual bone width of the lower incisors. Part II. *J Orofacial Orthop.* 1996;57:168-85.
12. Handelman CS. The anterior alveolus: its importance in limiting orthodontic treatment and its influence on the occurrence of iatrogenic sequelae. *Angle Orthod.* 1996;66:95-110.
13. Houston WJ. The analysis of errors in orthodontics measurements. *Am J Orthod.* 1983;83:382-90.
14. Ichim I, Swain M, Kieser JA. Mandibular biomechanics and the development of the human chin. *J Dent Res.* 2006;85:638-42.
15. Batista KBSL, Paiva JB, Rinoneto J, Queiroz GV, Bozzini MF, Farias B. Avaliações tegumentares, esqueléticas e dentárias do perfil facial. *Rev Clin Ortodon Dental Press.* 2007;5:95-105.
16. Martins AN. Inclinação da sínfise em relação aos padrões faciais em pacientes leucodermas, sul-brasileiros, portadores de má-oclusão de Classe I, de Classe II (divisão I) e de Classe III de Angle. *Ortodontia Paranaense.* 1991;12:1-19.
17. Martins DR, Janson GRP, Almeida RR, Pinzan A, Henriques JFC, Freitas MR. Atlas de crescimento craniofacial. São Paulo (SP): Ed. Santos; 1998.
18. Masumoto T, Hayashi I, Kawamura A, Tanaka K, Kasai K. Relationships among facial type, buccolingual molar inclination and cortical bone thickness of the mandible. *Eur J Orthod.* 2001;23:15-23.
19. Melsen B, Allais D. Factors of importance for the development of dehiscences during labial movement of mandibular incisors: a retrospective study of adult orthodontic patients. *Am J Orthod Dentofacial Orthop.* 2005;127:552-61.
20. Mulie RM, Hoeve AT. The limitations of tooth movement within the symphysis, studied with laminography and standardized occlusal films. *J Clin Orthod.* 1976;10:882-93.
21. Nauert K, Berg R. Evaluation of labio-lingual bony support of lower incisors in orthodontically untreated adults with the help of computed tomography. *J Orofac Orthop.* 1999;60:321-34.
22. Nojima K, Nakakawaji K, Sakamoto T, Isshiki Y. Relationships between mandibular symphysis morphology and lower incisor inclination in skeletal Class III malocclusion requiring orthognatic surgery. *Bull Tokyo Dent. Coll* 1998;39:175-81.
23. Reis SAB, Capelloza Filho L, Cardoso MA, Scanavini MA. Características cefalométricas dos indivíduos Padrão I. *R Dental Press Ortodon Ortop Facial.* 2005;10:67-78.
24. Sarikaya S, Haydar B, Ciger S, Ariyürek M. Changes in alveolar bone thickness due to retraction of anterior teeth. *Am J Orthod Dentofacial Orthop.* 2002;122:15-26.
25. Scavone H, Zahn-Silva W, do Valle-Corotti KM, Nahás AC. Soft tissue profile in white Brazilian adults with normal occlusions and well-balanced faces. *Angle Orthod.* 2008;78:58-63.
26. Silva OP, Oliveira AG, Oliveira JN, Souza LA, Silva ESO. Padrão cefalométrico de brasileiros, leucodermas, portadores de oclusão "normal". *R Dental Press Ortodon Ortop.* 2004;9:59-78.
27. Skieller V, Björk A, Linde-Hansen T. Prediction of mandibular growth rotation evaluated from a longitudinal implant sample. *Am J Orthod.* 1984;86:359-70.
28. Steiner GG, Pearson JK, Ainamo J. Changes of the marginal periodontium as a result of labial tooth movement in monkeys. *J. Periodontol.* 1981;52:314-20.
29. Tweed CH. The Frankfort-mandibular incisor angle (FMIA) in orthodontic diagnosis, treatment planning and prognosis. *Angle Orthod.* 1954;24:121-9.
30. Wehrbein H, Bauer W, Diedrich P. Mandibular incisors, alveolar bone and symphysis after orthodontic treatment. A retrospective study. *Am J Orthod Dentofacial Orthop.* 1996;110:239-46.
31. Yared KF, Zenobio EG, Pacheco W. Periodontal status of mandibular central incisors after orthodontic proclination in adults. *Am J Orthod Dentofacial Orthop.* 2006;130:6.e1-8.