

Class III malocclusion with severe anteroposterior discrepancy*

Susana Maria Deon Rizzato¹

This study aims at reporting the clinical case of a patient with Class III skeletal malocclusion with severe maxillary deficiency, producing a reduced midface associated with severe mandibular prognathism. The pre-surgical orthodontic preparation was composed mainly by dentoalveolar expansion and repositioning of the incisors in the lower arch. Then, a combined maxillary and mandibular orthognathic surgery was performed. The treatment objectives were achieved, with significant improvement in facial esthetics and occlusion, followed by post-treatment stability. This case was presented to the Brazilian Board of Orthodontics and Facial Orthopedics (BBO), as part of the requirements for obtaining the title of Diplomate by BBO.

Keywords: Class III malocclusion. Corrective orthodontics. Orthognathic surgery.

* Case Report, category 4, approved by the Brazilian Board of Orthodontics and Dentofacial Orthopedics (BBO).

¹ MSc and Specialist in Orthodontics, PUCRS/UFRGS. Professor of Orthodontics, PUCRS. Diplomate by the Brazilian Board of Orthodontics and Facial Orthopedics.

How to cite this article: Rizzato SMD. Class III malocclusion with severe anteroposterior discrepancy. *Dental Press J Orthod.* 2012 Sept-Oct;17(5):178-89.

Submitted: July 19, 2012 - **Revised and accepted:** August 08, 2012

» The author reports no commercial, proprietary or financial interest in the products or companies described in this article.

» Patients displayed in this article previously approved the use of their facial and intraoral photographs.

Contact address: Susana Rizzato
Rua Padre Chagas, 185/301 – Porto Alegre/RS – Zip code: 90.570-080 – Brazil
Email: smdr@uol.com.br

INTRODUCTION

Caucasian patient, male, 19 years and 7 months old, with accentuated Class III malocclusion and family history of Class III, being the mother the carrier. He had poor oral hygiene, caries, marginal gingivitis and good general health. His chief complaint was difficulty to chew.

DIAGNOSIS

During facial examination, a strongly concave profile was observed, with great midface deficiency and accentuated mandibular prognathism, followed by a flat malar region and deep nasolabial sulcus. The face presented symmetry, but with an increased lower third, prevailing the distance from the lower lip to

the menton base. The nasolabial angle was obtuse and the mentolabial angle was almost flat, characteristic of excessive compensation by lingual inclination of lower incisors in Class III. The absence of lip volume support was evident (Fig 1). The skeletal pattern was Class III, ANB = -11 ° (SNA = 73° and SNB = 84°); the mandible was elongated with a strongly obtuse gonial angle; high GoGnSN = 45° and FMA = 38° angles, characterizing a predominance of vertical face development (Fig 4 and Table 1). From the dental point of view, patients presented Angle Class III malocclusion, with anterior and posterior crossbite and relative maxillary constriction. The upper incisors were well positioned and the lower were retroclined with moderate crowding and severe Curve of Spee (Figs 1, 2, 4).

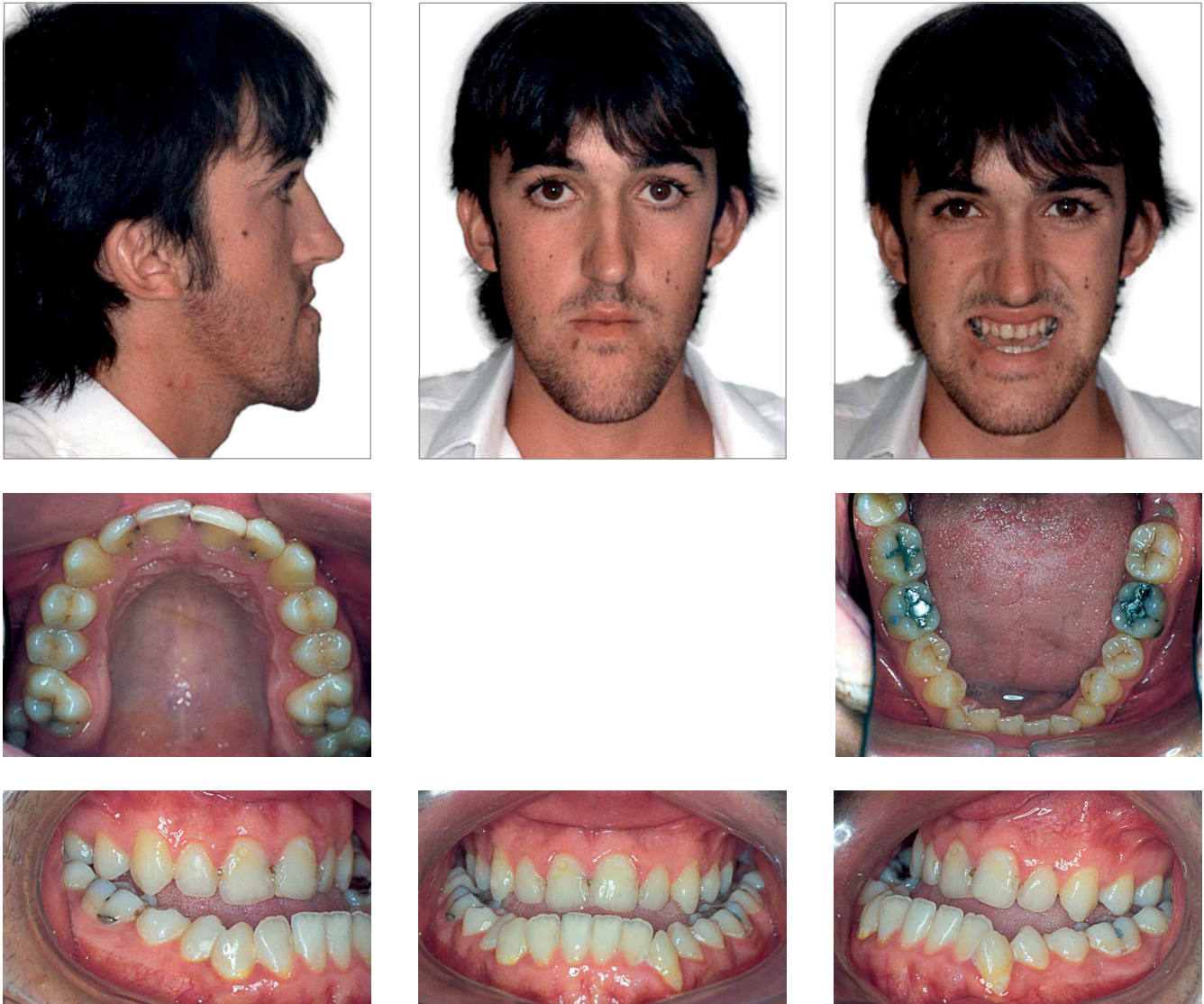


Figure 1 - Facial and intraoral initial photographs.

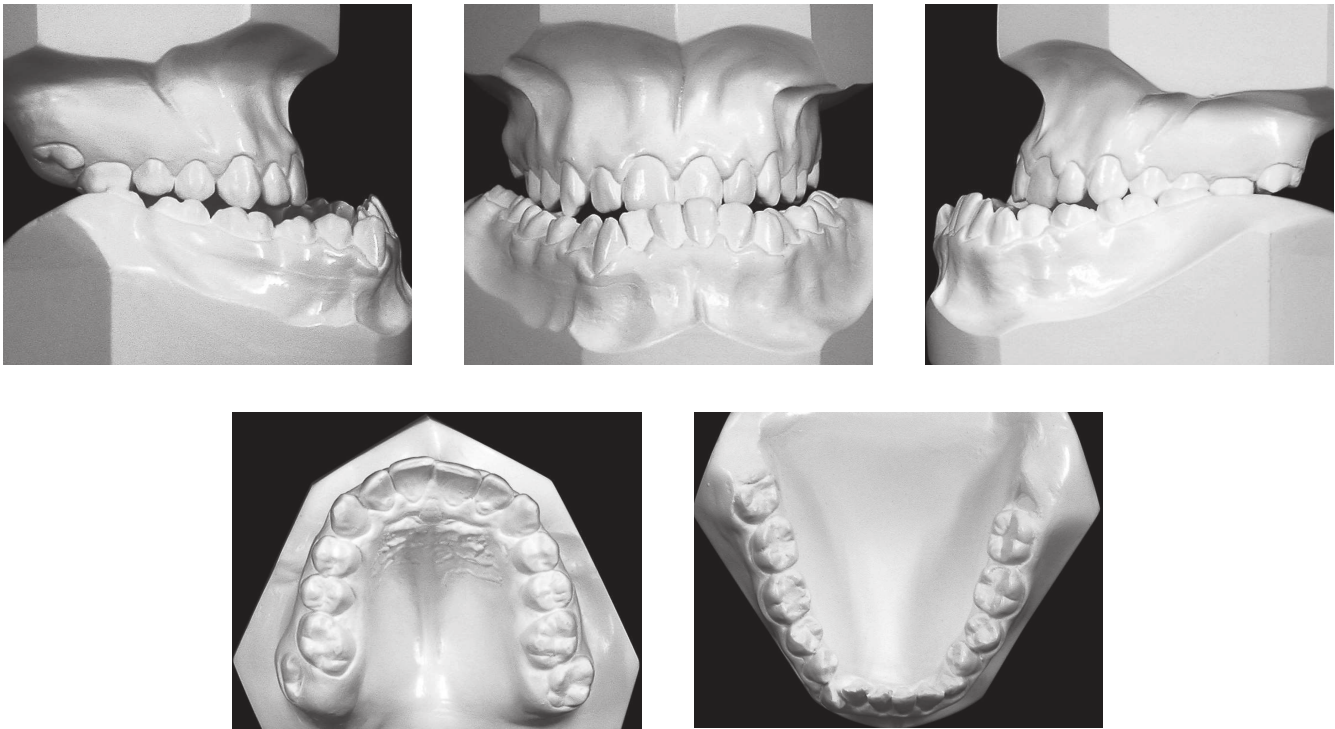


Figure 2 - Initial dental casts.

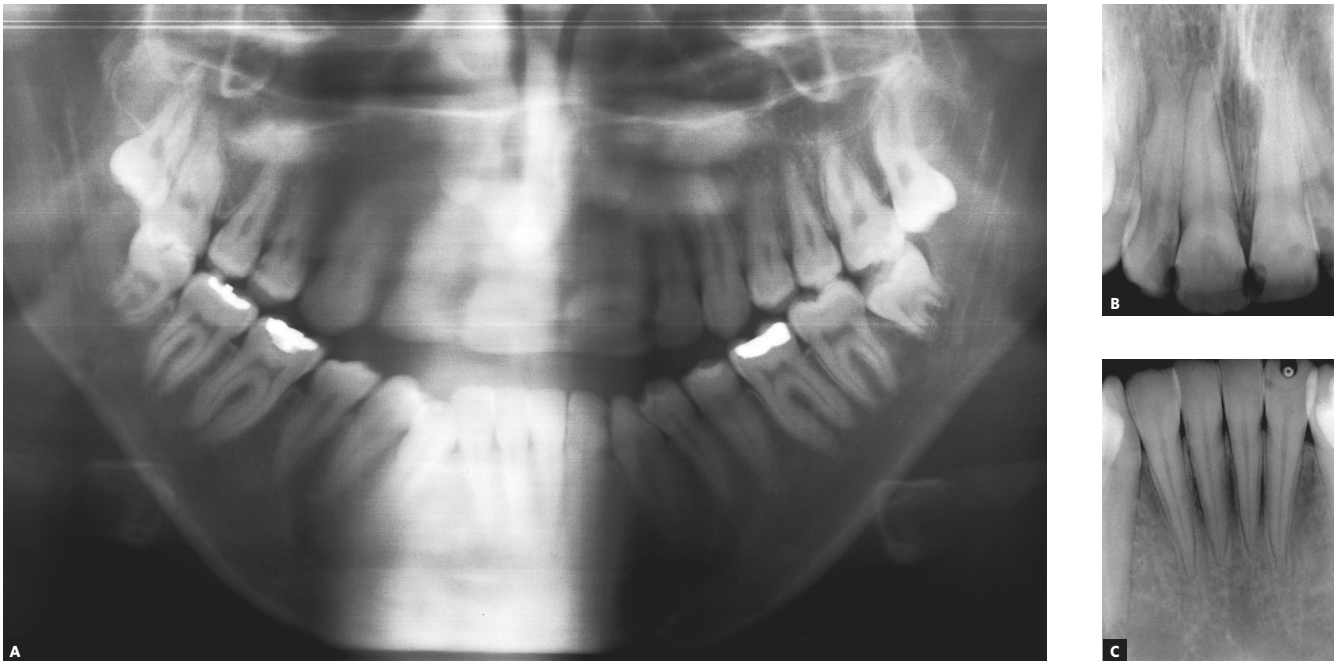


Figure 3 - Panoramic(A) and periapical (B, C) initial radiographs.

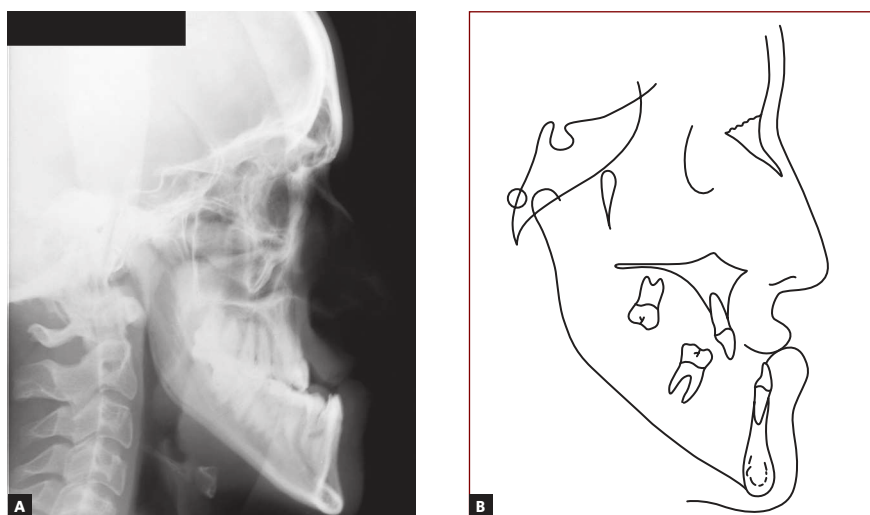


Figure 4 - Initial lateral cephalometric radiograph (A) and cephalometric tracing (B).

TREATMENT OBJECTIVES

The initial treatment objective was to correct the dental compensations in the maxilla and mandible through orthodontic treatment previous to the combined orthognathic surgery. In the maxilla, a dentoalveolar expansion should be performed by increasing the upper intermolar distance to adjust its transverse relation. In the mandible, the severe lingual inclination of the incisors should be corrected, leveling the curve of Spee and obtaining space for the canines and for positioning the incisors in their bone bases. The maxilomandibular sagittal and vertical will be corrected by orthognathic surgery with anterior and inferior repositioning of the maxilla and mandibular rotation and setback, aimed at obtaining the ideal occlusal relationship, function and facial harmony.

TREATMENT PLAN

The treatment plan consisted of three different steps:

First step: Refer the patient to carry out clinical review and preventive care. Following, bonding of upper and lower brackets and decompensation of the lower arch by leveling the curve of Spee and projection of the incisors. Also, placement of an upper removable plate with expanding screw to promote a mild maxillary dentoalveolar expansion and retention with the mechanics advocated by Mulligan.

Second step: At this phase to perform the combined orthognathic surgery (for maxillary advancement and mandibular setback).

Third step: A post-surgical immobilization of the jaws with rubber bands and intensive elastic physiotherapy was planned. After orthodontic treatment finishing, the appliances would be removed and the retainers would be installed.

TREATMENT PROGRESS

After clinical review and preventive care, the appliances were installed by banding first and second upper and lower molars, with double tubes in the first upper molars and installation of removable plate with the expanding screw (1/4 turn per week). The upper and lower brackets, Edgewise system (slot 0.022 x 0.028-in), were placed and alignment and leveling of the teeth were performed with initial twist-flex archwires (Dentaurum), followed by 0.016-in, 0.018-in, 0.020-in Stainless steel archwires (GAC). The decompensation of the lower arch occurred by leveling the curve of Spee and projecting the lower incisors. The retention of dentoalveolar expansion was performed with a Mulligan arch in the upper arch. Impressions of the upper and lower arches were taken for dental cast manipulation, four times before the rectangular arch. Then, a rectangular 0.019 x 0.025-in archwire (GAC) was installed and on it were soldered of 0.8 mm brass

wire hooks. After this first phase, an increase on the profile's disharmony was observed due to increased sagittal dental discrepancy, mainly due to the buccal inclination of the lower incisors. However, the mentolabial angle approached normality, as well as the volume of the lower lip (Figs 5 to 8).

The patient was referred to combined orthognathic surgery, consisting of maxillary protrusion with lower replacement and mandibular retrusion with upward rotation. For the following six months, the arches were

stabilized with rubber bands with Class III orientation and elastic physiotherapy was suggested. During this phase, intercuspation refining was performed, and then the appliance was removed. The lower retainer was installed, with a bonded intercanine fixed m retainer made with stainless steel 0.032-in archwire, and the upper retainer, wraparound type, was made with stainless steel 0.036-in archwire. This should be used full-time for 24 months followed by overnight use for another 12 months.

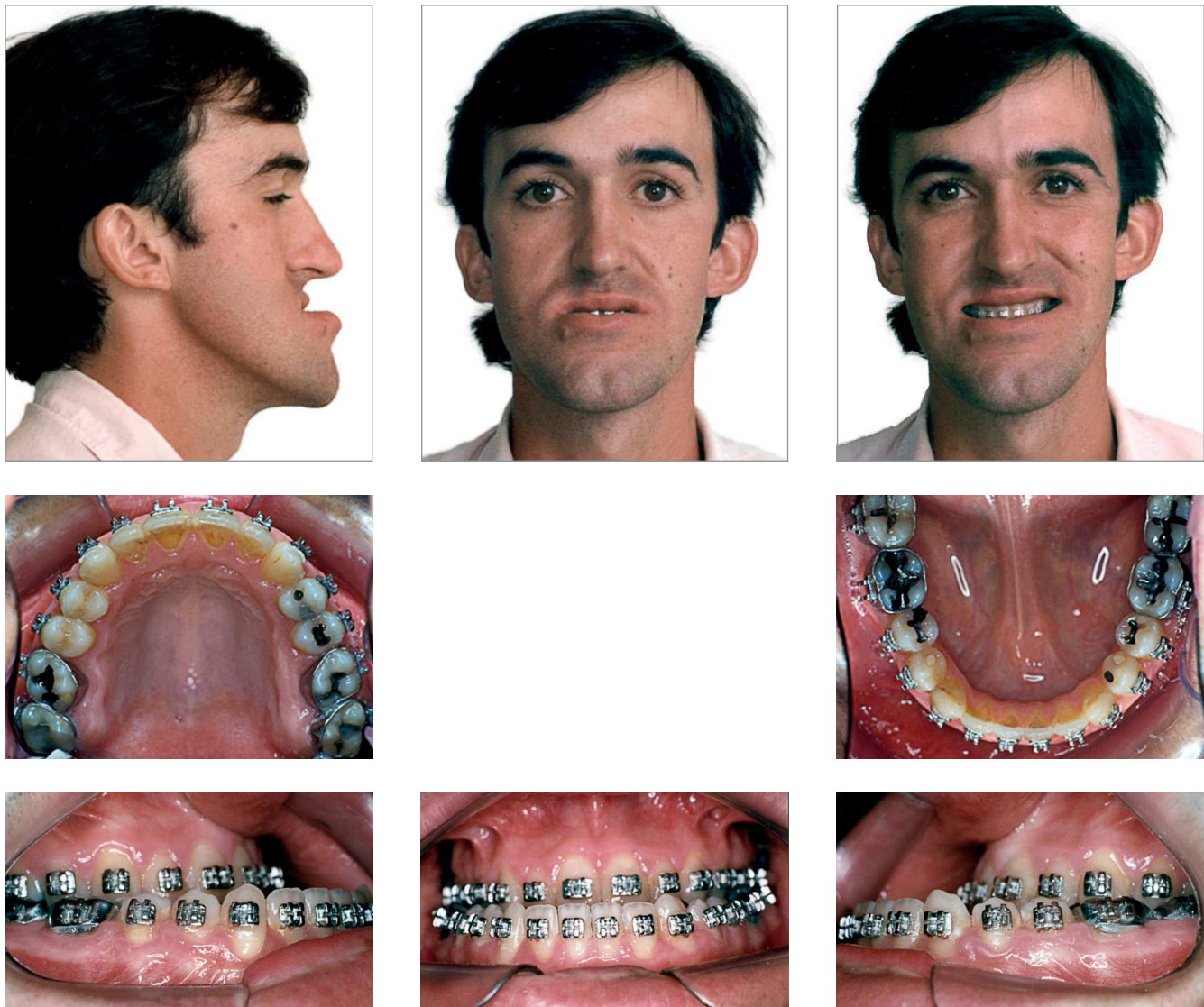


Figure 5 - Facial and intraoral pre-surgical photos.

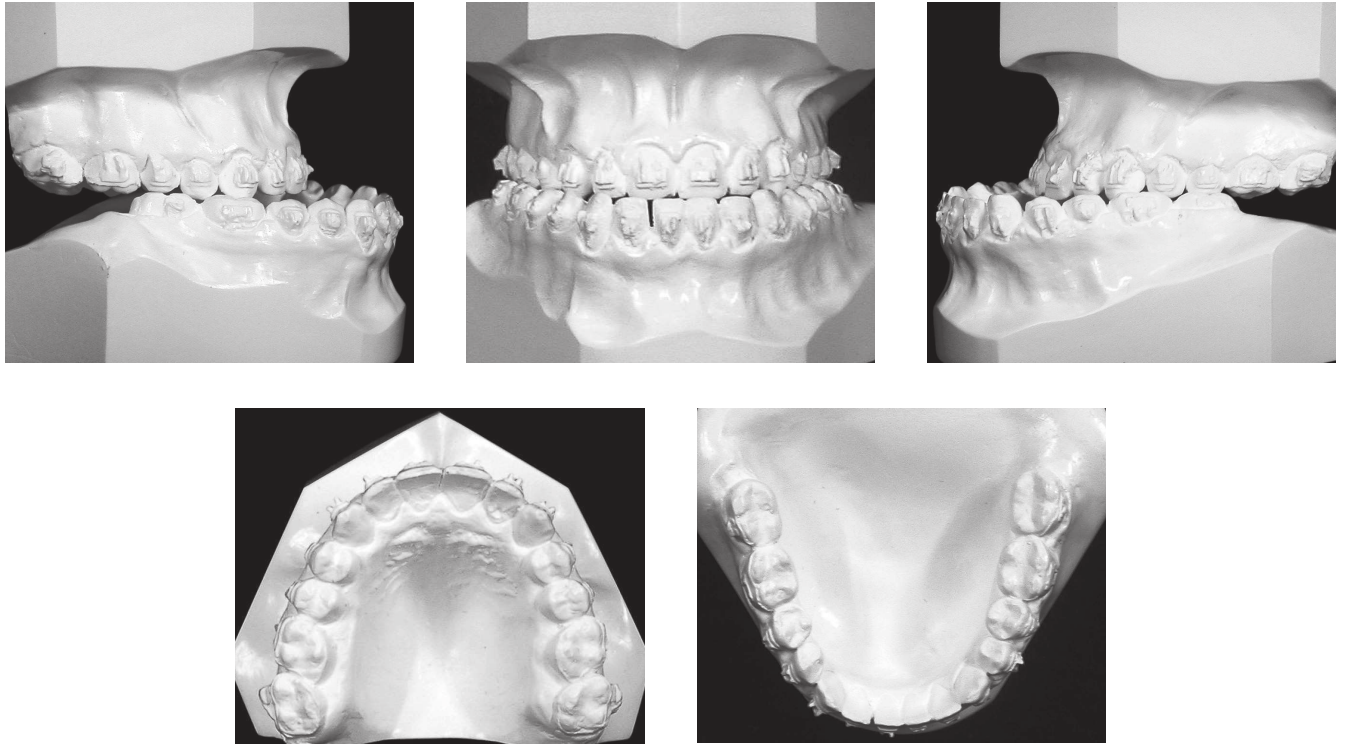


Figure 6 - Pre-surgical dental casts.

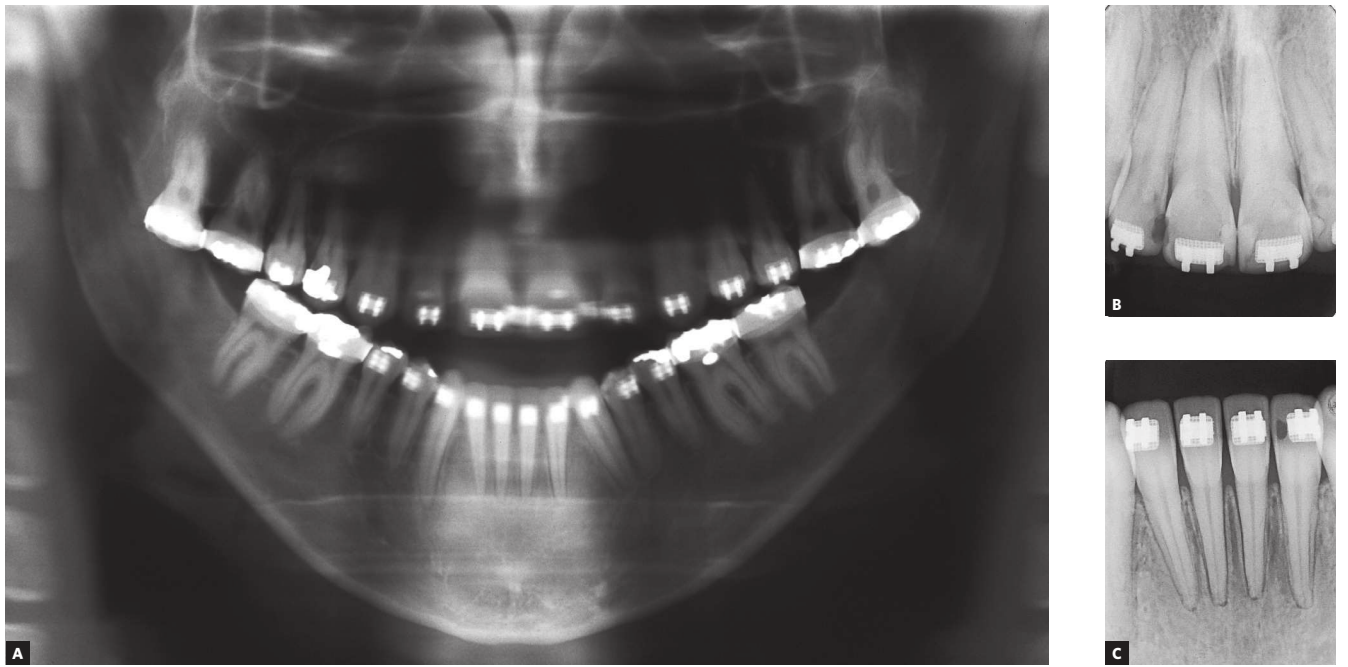


Figure 7 - Panoramic (A) and periapical (B, C) pre-surgical radiographs.

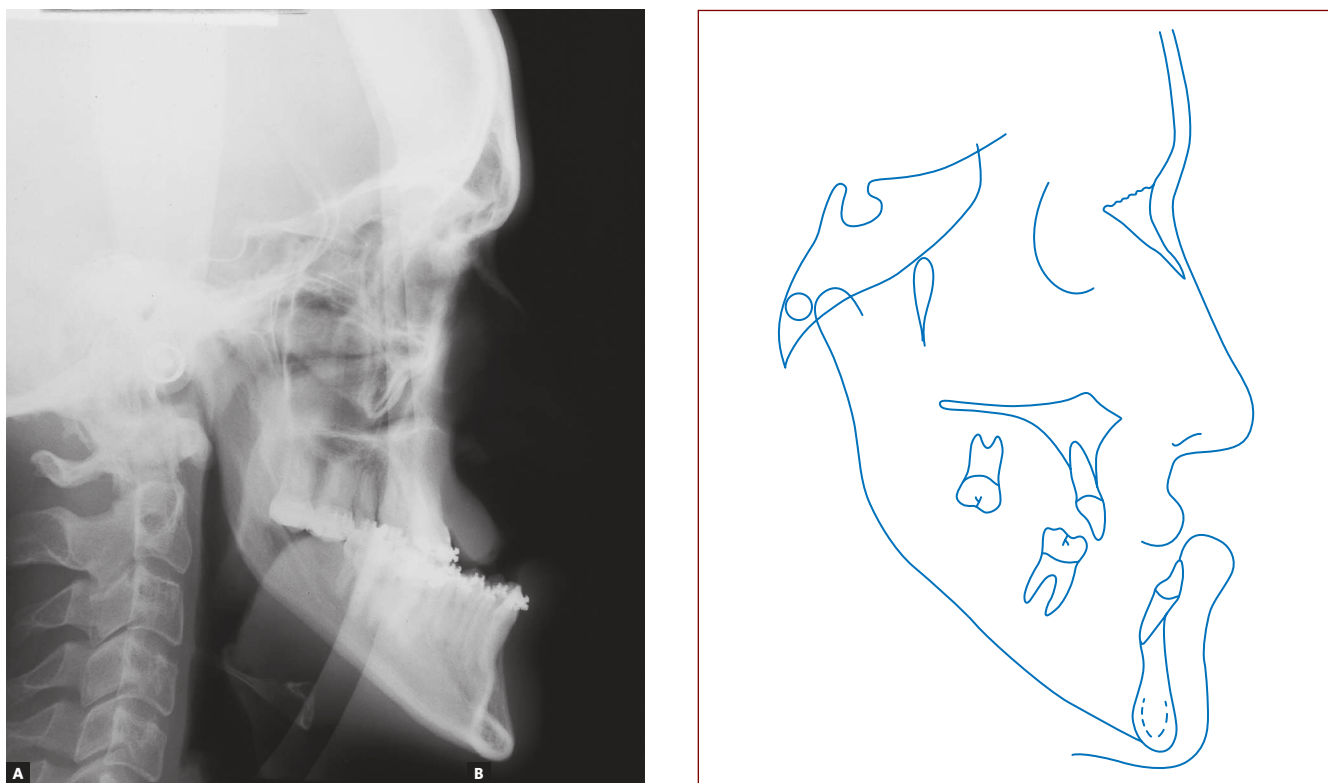


Figure 8 - Lateral cephalometric radiograph (A) and pre-surgical cephalometric tracing (B).

RESULTS

At the end of treatment, satisfactory occlusion was obtained with good dental intercuspation and presence of anterior and lateral disocclusion guides. The esthetic result was pleasing, harmonious, respecting the individual characteristics of the patient. Orthognathic surgery provided maxillary protrusion with an increase in SNA of 6° , plus lower replacement and

mild dentoalveolar expansion. In the mandible, the effect was of retrusion, with the reduction in SNB of 4° in the vertical direction. The dental effects on the mandible were retroclination of incisors and increase in the intermolar distance of 7 mm. In the mandible the incisors were severely protruded, the curve of Spee was leveled, the intermolar distance increased in 3 mm and intercanine distance in 1 mm (Figs 9 to 16).

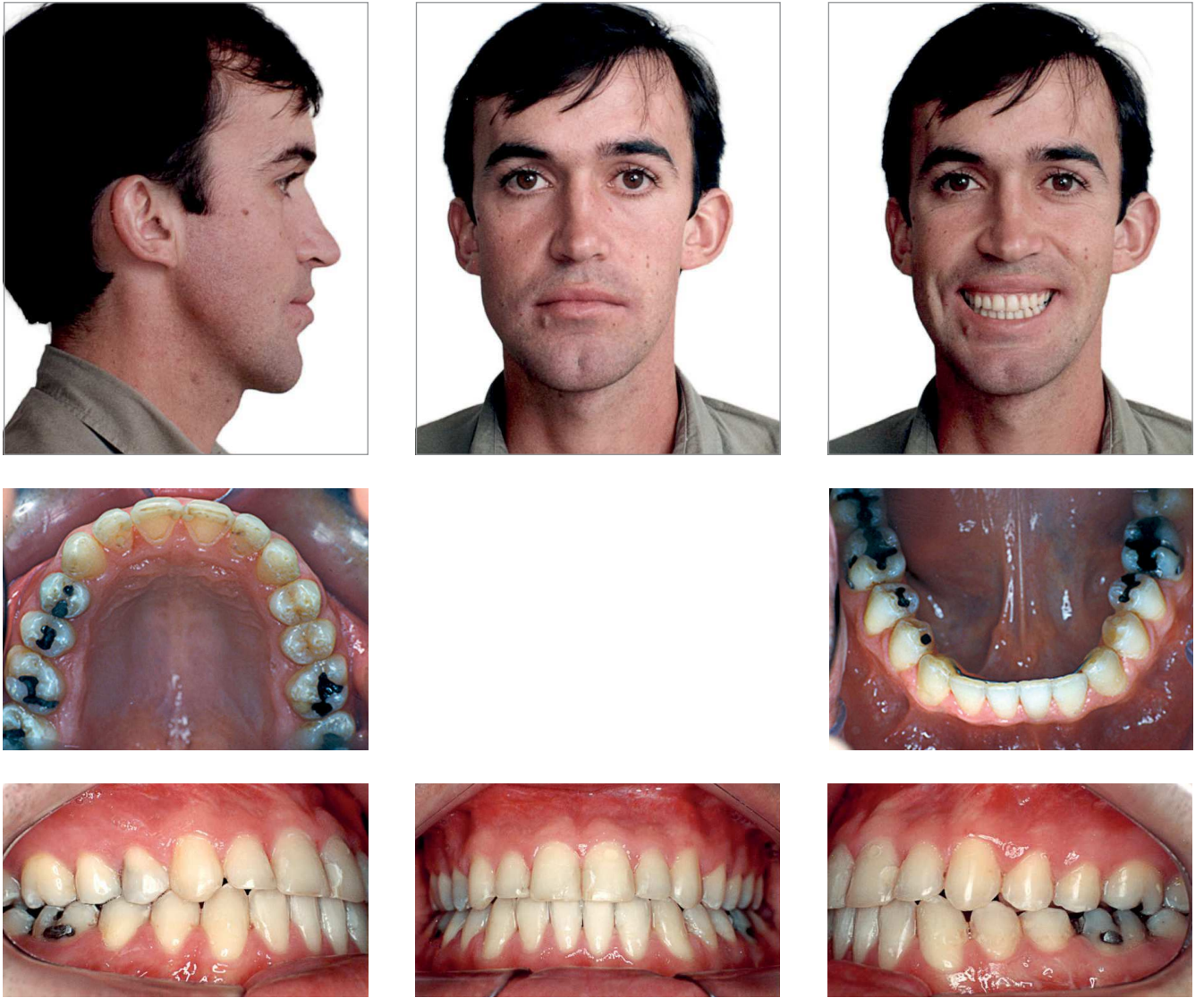


Figure 9 - Facial and intraoral final photos.

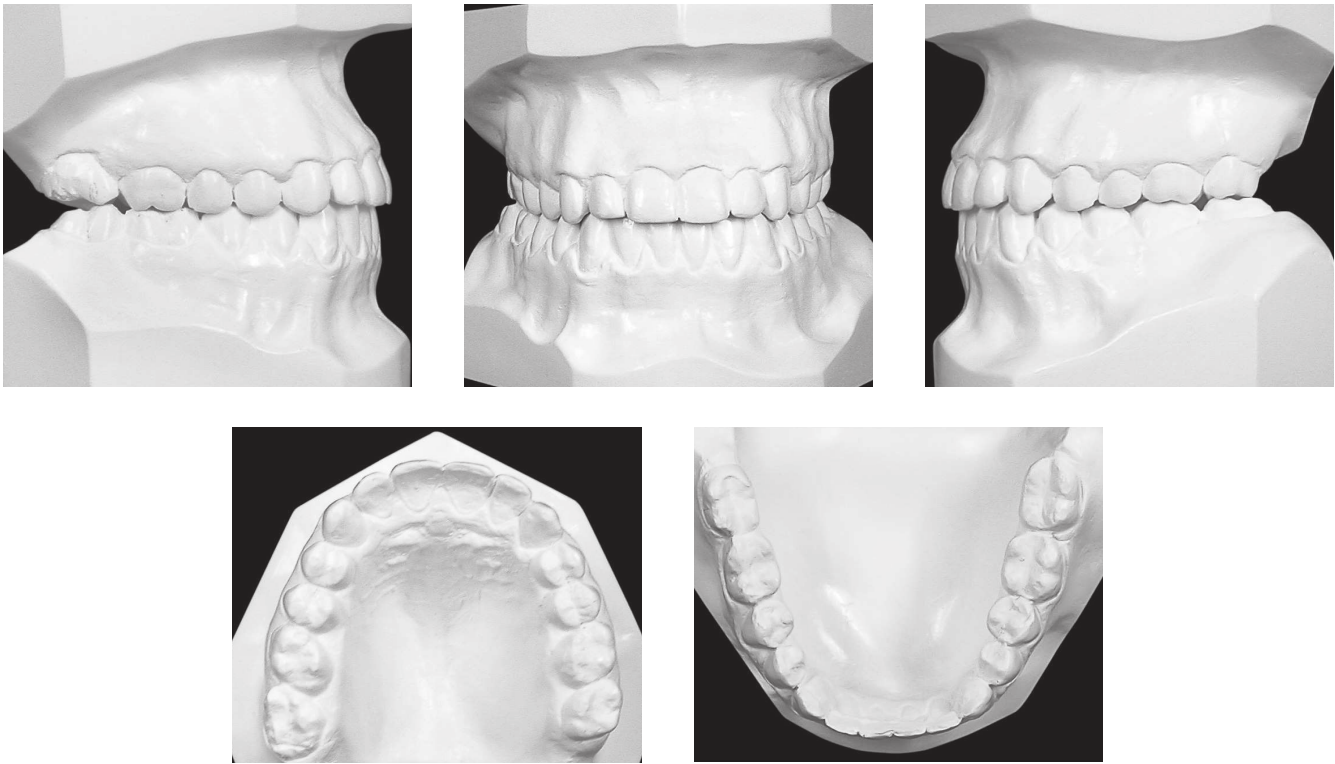

Figure 10 - Final dental casts.

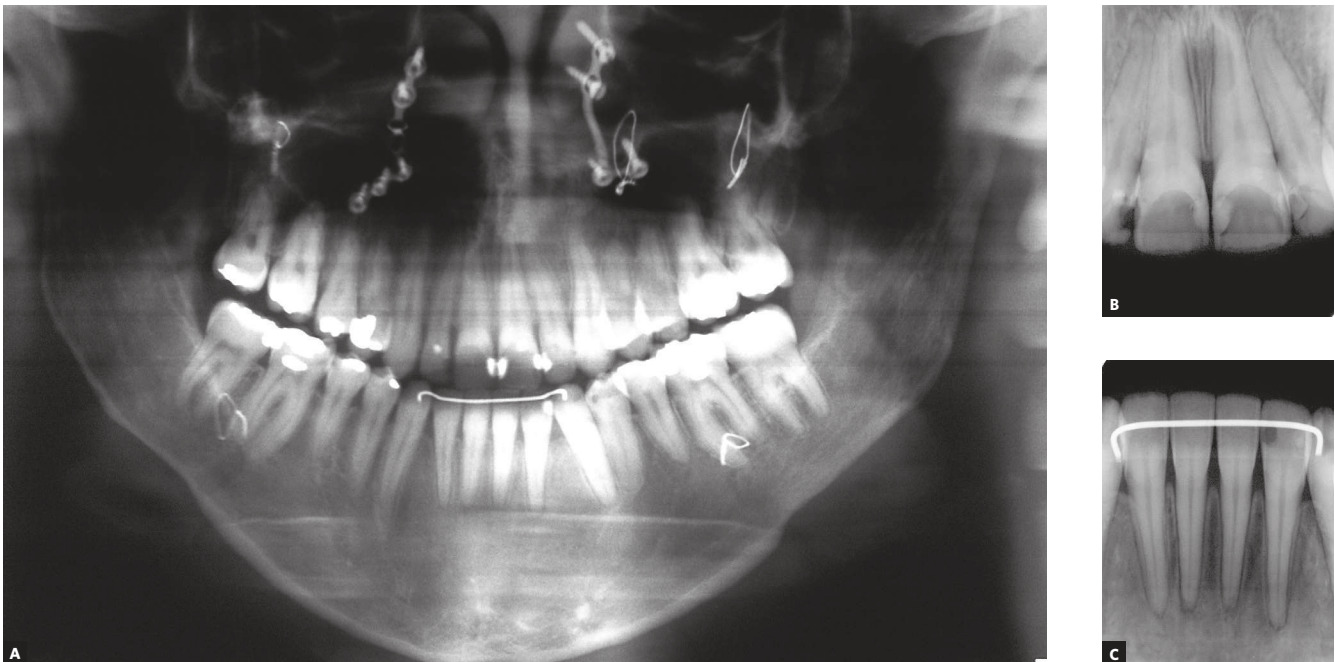


Figure 11 - Panoramic (A) and periapical (B, C) final radiographs.

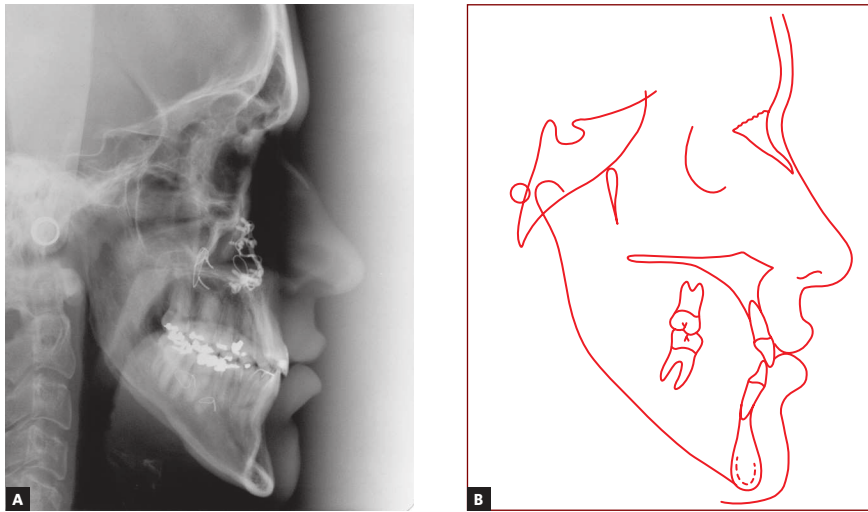


Figure 12 - Lateral cephalometric radiograph (A) and final cephalometric tracing (B).

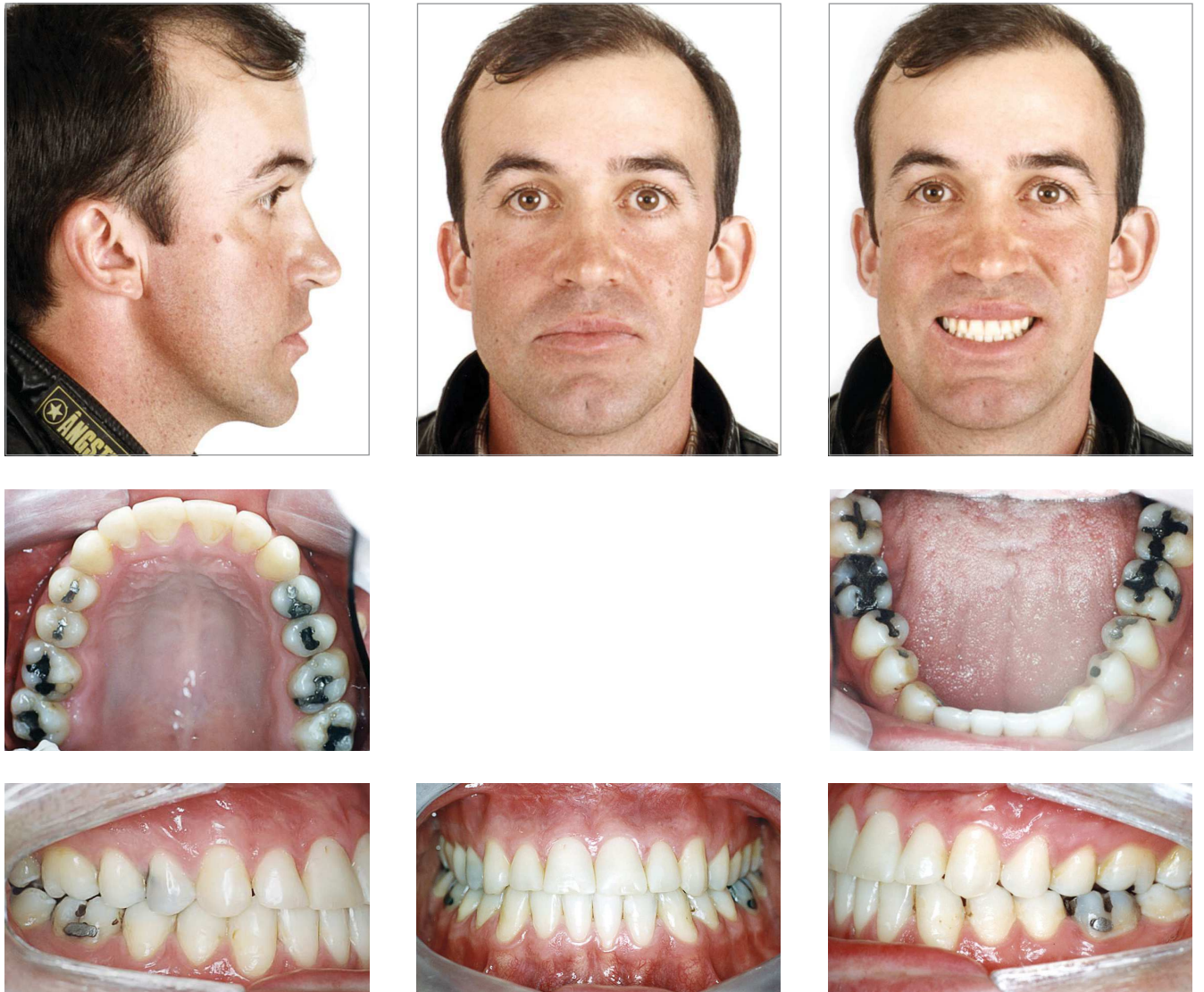

Figure 13 - Facial and intraoral control photos, four years after retention.

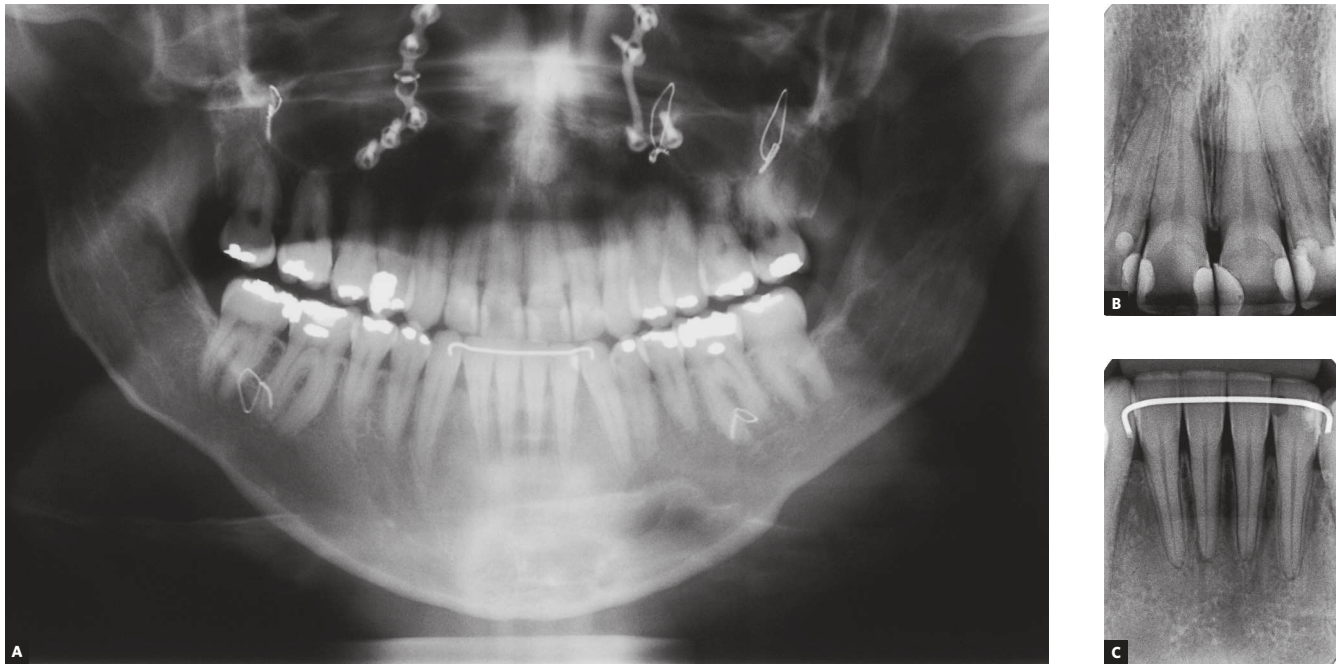


Figure 14 -Panoramic (A) and periapical (B, C) radiographs, four years after retention.

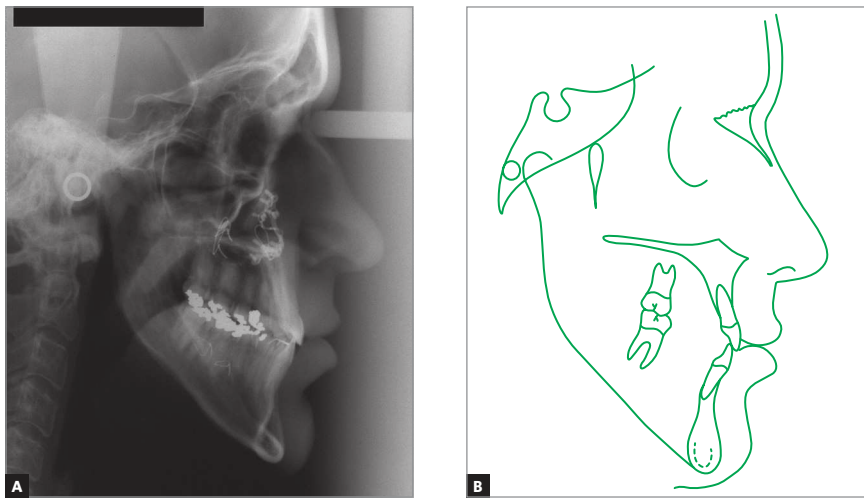


Figure 15 - Lateral cephalometric radiograph (A) and cephalometric tracing (B), four years after retention.

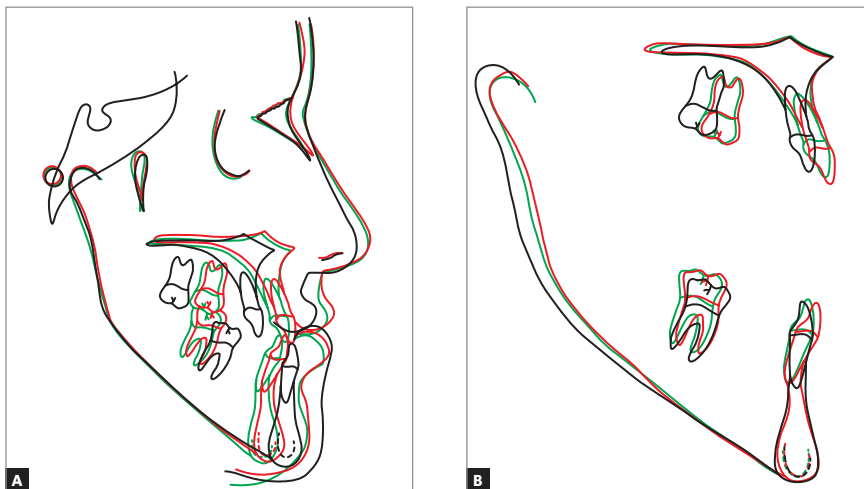


Figure 16 - Total (A) and partial (B) superimposition of the initial cephalometric tracing (black), final (red) and four years after retention (green).

Table 1 - Summary of cephalometric measurements.

	Measurements		Normal	A	P	B	C	Difference A/B
Skeletal pattern	SNA	(Steiner)	82	73	73	79	81	6
	SNB	(Steiner)	80	84	84	80	80	4
	ANB	(Steiner)	2	-11	11	-1	1	10
	Angle of convexity	(Downs)	0	-23	27	1	0	24
	Y axis	(Downs)	59	60	63	60	61	0
	Facial angle	(Downs)	87	91	90	90	90	1
	Sn-GoGn	(Steiner)	32	45	45	45	45	0
	FMA	(Tweed)	25	38	39	39	39	1
Dental pattern	IMPA	(Tweed)	90	57	77	69	70	12
	\perp -NA (mm)	(Steiner)	22	27	26	19	22	8
	\perp NA (degrees)	(Steiner)	4	5	5	5	5	0
	\bar{I} -NB (mm)	(Steiner)	25	25	47	20	20	5
	\bar{I} .NB (degrees)	(Steiner)	4	3	6	4	4	1
	$\frac{1}{1}$ - interincisal angle	(Downs)	130	160	140	145	144	15
	\bar{I} -APo (mm)	(Ricketts)	1	-6	-11	3	2	9
Profile	Upper lip - S line	(Steiner)	0	-3	-6	0	-1	3
	Lower lip -S line	(Steiner)	0	4	8	1	1	3

CONCLUSION

The Class III malocclusion is considered most challenging for the orthodontist, particularly when there is skeletal involvement.¹ In this case, the diagnosis conclusion was the recommendation of orthognathic surgery due to the dominant etiologic factor - severe maxillary and mandibular malocclusion - this being the primary focus on the treatment strategy. With the surgical approach, psychosocial aspects related to the deformity can also be privileged² and it is important that the diagnosis and treatment plan are performed in conjunction with the maxillofacial surgeon in order to maximize results and reduce the time and complications inherent to treatment.^{3,4} Combined maxillary and mandibular orthognathic surgery allowed the orthodontic treatment to be efficient, reaching its

goals, with appropriate overjet and overbite relationship between canines and molars in key of occlusion. Decompensation of the lower incisor inclination, considered severe, did not cause changes that compromised the periodontal support structures. Final and control radiographs showed moderate levels of root resorption, which reveals the low biological cost of the treatment. The change in the mentolabial angle, with the positioning of the lower lip near normality, helped to reduce the subjectivity degree in the analysis of the soft tissue profile in the pre-surgical phase, enhancing the final esthetic result. The improvement in facial esthetics contributed to raising the self-esteem of the patient. The follow-up of four years post-treatment denotes stability in occlusal characteristics, morphology of the arches and facial harmony.

REFERENCES

1. Stellzig-Eisenhauer A, Lux Cj, Schuster G. Treatment decision in adult patients with Class III malocclusion: orthodontic therapy or orthognathic surgery. *Am J Orthod Dentofacial Orthop.* 2002;122:27-38.
2. Bilodeau JE. Correction of a severe Class III malocclusion that required orthognathic surgery: a case report. *Semin Orthod.* 1996;2:279-88.
3. Vig KD, Ellis E. Diagnosis and treatment planning for the surgical-orthodontic patient. *Dent Clin North Am.* 1990;34(2):361-84.
4. Dann JJ, Fonseca R, Bell WH. Soft tissue changes associated with total maxillary advancement: a preliminary study. *J Oral Surg.* 1976;34:19-23.