

An interview with

Paulo José d'Albuquerque Medeiros

- Graduated from the School of Dentistry, Rio de Janeiro Federal University (UFRJ) – Praia Vermelha, Brazil, 1978.
- Specialist in Oral and Maxillofacial Surgery, UERJ, 1979.
- Residency in Oral and Maxillofacial Surgery, University of Texas-Dallas – USA, 1981-1984.
- MSc and PhD, School of Dentistry, UFRJ – 1991 and 2001.
- Professor at UFRJ and Rio de Janeiro State University (UERJ) since 1979 to date.
- Head Professor, Oral Surgery, School of Dentistry, UERJ, since 1995.
- Author of the following books: “Orthognathic Surgery for Orthodontists” (Ed. Santos), “Retained Tooth Surgery” (Ed. Santos), “Update on Oral and Maxillofacial Surgery and Traumatology” (Ed. Santos).
- In private practice in Rio de Janeiro, Brazil, since 1979.
- Renowned lecturer in Brazil and abroad.

Prof. Paulo José d'Albuquerque Medeiros was born to Paulo Pinho de Medeiros and Conceição Rosário d'Albuquerque Medeiros in the city of Rio de Janeiro, Brazil on March 7, 1957. He has been married for 31 years to Patricia Leo Medeiros and they have two children: Alessandra Leão Medeiros Parente, 30, a law judge, and Leo Bruno Medeiros, 28, economist. He is fond of music and the movies, and is a fine singer. He has developed a refined taste for good wines, his favorite being Chateau Palmer. He is currently reading a pocket book titled “1001 wines to drink before you die”. His most daunting challenge in life: “Keeping up the motivation to teach, which is my true calling”.

Marco Antonio Almeida

How to cite this interview: Medeiros PJD. Interview. Dental Press J Orthod. 2012 Sept-Oct;17(5):8-23.

Submitted: July 2, 2012 - **Revised and accepted:** August 7, 2012

» Patients displayed in this article previously approved the use of their facial and intraoral photographs.

AESTHETICS

What is the greatest demand of patients: Esthetics of function? (Antenor Araújo)

Most patients expect improved esthetics. Don't forget that - if the patient's facial esthetics is not compromised - it is quite a challenge for the orthodontist to persuade the patient to agree to ortho-surgical treatment, even if they have some sort of malocclusion.

Which parameters are most important in the analysis of facial esthetics?

(Carlos Estevanell Tavares)

I could cite several variables, but I prefer to highlight the smile, which is our "calling card." I've had several patients who, after correction of vertical maxillary excess, came to be questioned by friends who wanted to know if they were wearing contact lenses (Fig 1). It seems that an unsightly smile can "erase" other interesting facial features. The "buccal corridor", which is sometimes treated by ortho-surgical expansion (Fig 2), and in other situations by simply improving the shape of dental arches through tooth movement, also greatly affects the smile and facial esthetics (Fig 3).

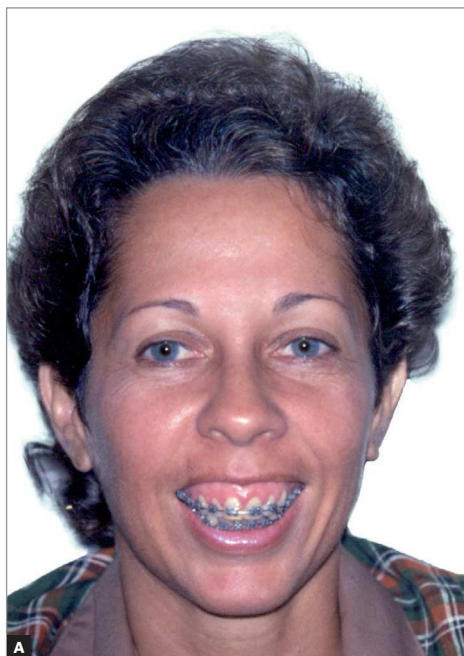



Figure 1 - Class II patient with vertical maxillary excess and anteroposterior mandibular deficiency (**A**). After maxillary repositioning and mandibular advancement. The surgical procedure highlighted the eyes (**B**).

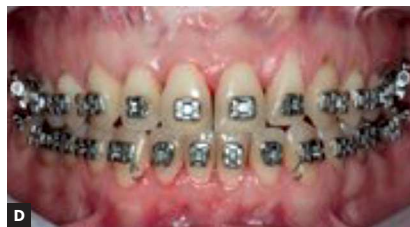
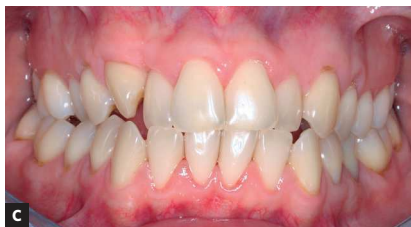
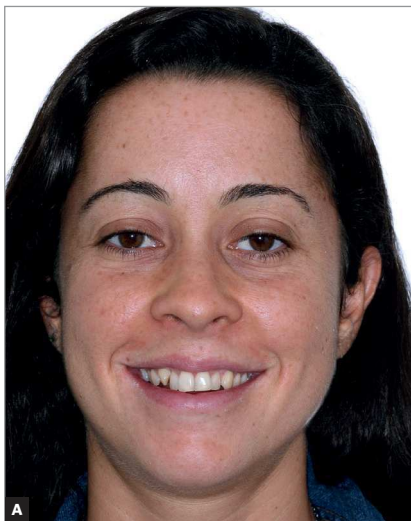
Figure 2 - Before (A) and after (B) surgically assisted rapid maxillary expansion. "Buccal corridor" shows improvement. Initial occlusion (C) and after intervention (D).

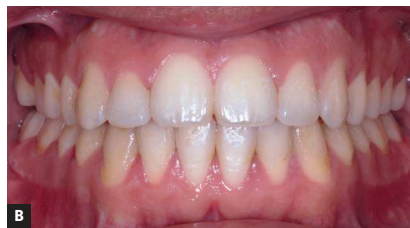
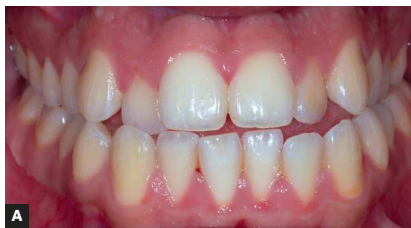
Figure 3 - Class III malocclusion and maxillary constriction before ortho-surgical treatment. Occlusion after osteotomies of maxilla and mandible without segmentation. The upper arch was expanded and its form improved through tooth movement.

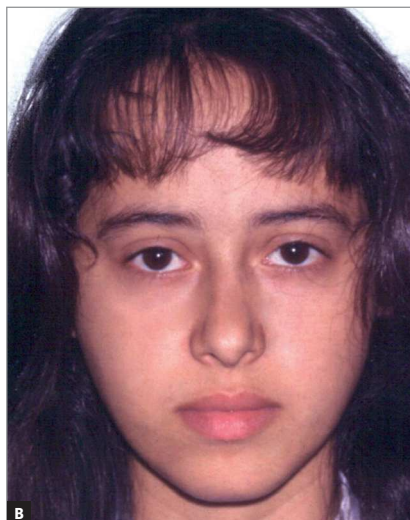


Figure 4 - Note nasal base tapering toward the tip. Increased nose harmony after slight base enlargement as a result of maxillary advancement.

What steps do you take in cases of advancement or repositioning orthognathic surgery in the maxilla to avert undesirable effects on facial esthetics? (Carlos Estevanell Tavares)

Nasal esthetics is a major concern of surgeons in planning and performing maxillary orthognathic surgery. Le Fort I osteotomy could cause nasal enlargement due to muscle detachment, but this

issue is particularly challenging in the aforesaid movements, i.e., maxillary advancement/repositioning. In rare, select cases enlargement may even be desirable (Fig 4). The vast majority of patients, however, have the base of their nose sutured after maxillary repositioning, which is intended to prevent enlargement. This procedure is called “Nasal plication” (Fig 5).

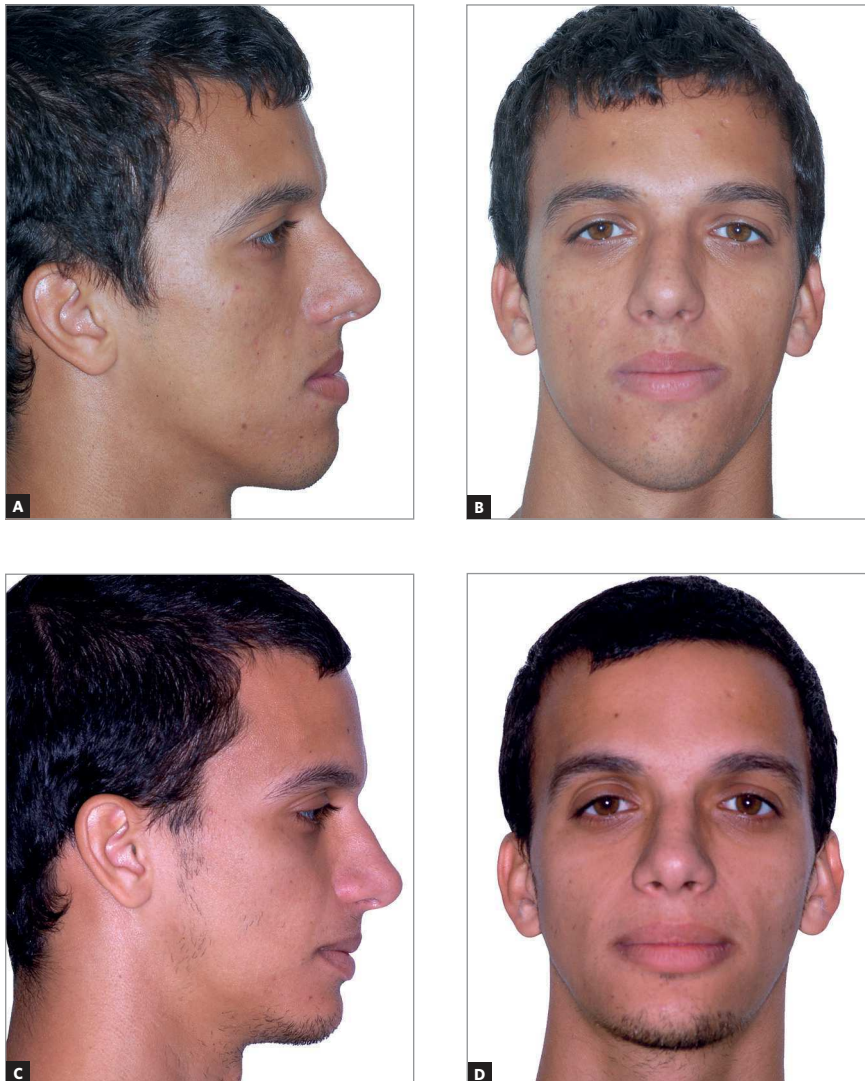


Figure 5 - A, B) This patient is a good candidate for maxillary advancement combined with maxillary repositioning. **C, D)** Good control of nasal base although the movement performed can be considered potentially detrimental to the esthetics of the nose.

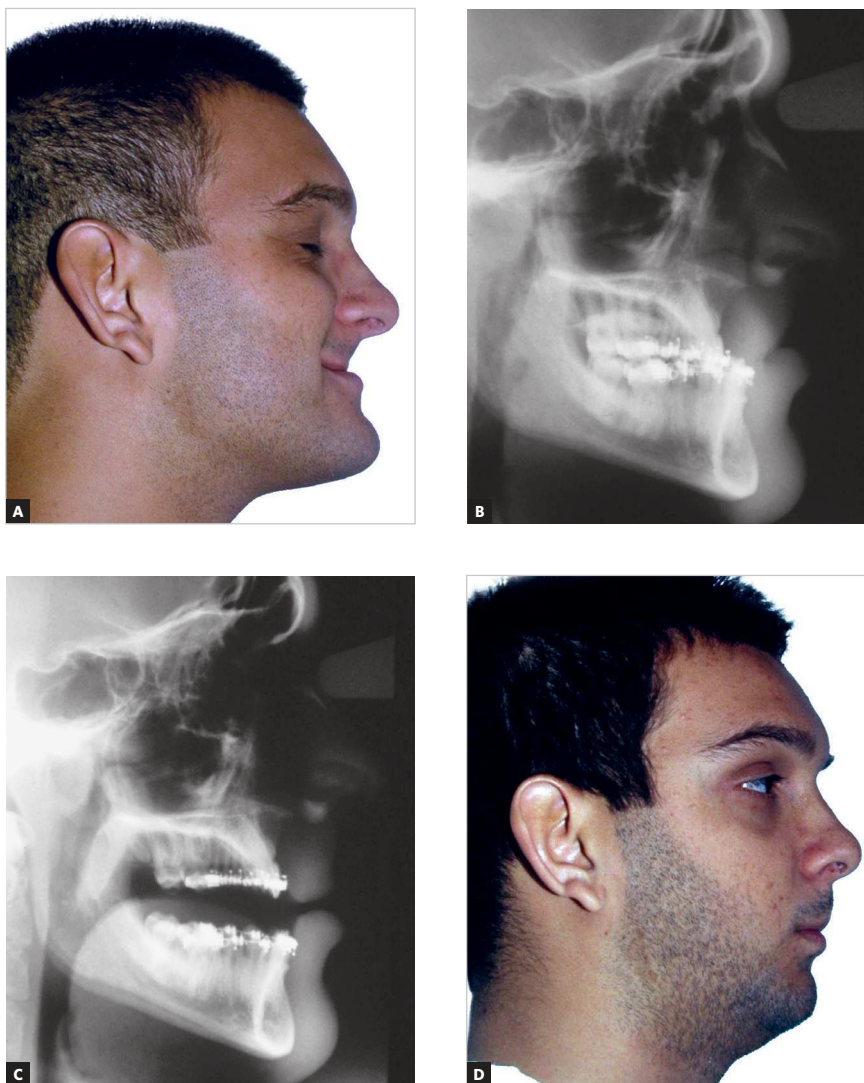


Figure 6 - Patient presented with anteroposterior and vertical maxillary hypoplasia in addition to anteroposterior mandibular excess. Lateral cephalometric radiograph highlighting the discrepancy between maxilla and mandible. Lateral cephalogram with mouth slightly open enabling visualization and quantification of vertical maxillary deficiency in relation to the upper lip. Patient after lowering and maxillary advancement combined with mandibular setback.

How do you address cases of closed mandibular plane and decreased lower face?

(Carlos Estevanell Tavares)

In the past, this condition was mistakenly called “Short Face Syndrome”. Although not a true syndrome, its expression tends to recur at different levels. The starting point for treatment is determining how many millimeters the maxilla should be lowered, and whether this lowering will have one single magnitude or different magnitudes, considering the incisal and

molar regions. A predictive tracing should indicate whether the mandible is likely to undergo a clockwise rotation only, and require surgery, or whether it will have to undergo advancement or setback osteotomy, depending on the initial malocclusion. The height of the mandibular symphysis in these individuals is usually short. Therefore, performing a genioplasty to increase the vertical dimension may be beneficial (Fig 6). These procedures elongate the face and improve the mandibular plane at the same time.

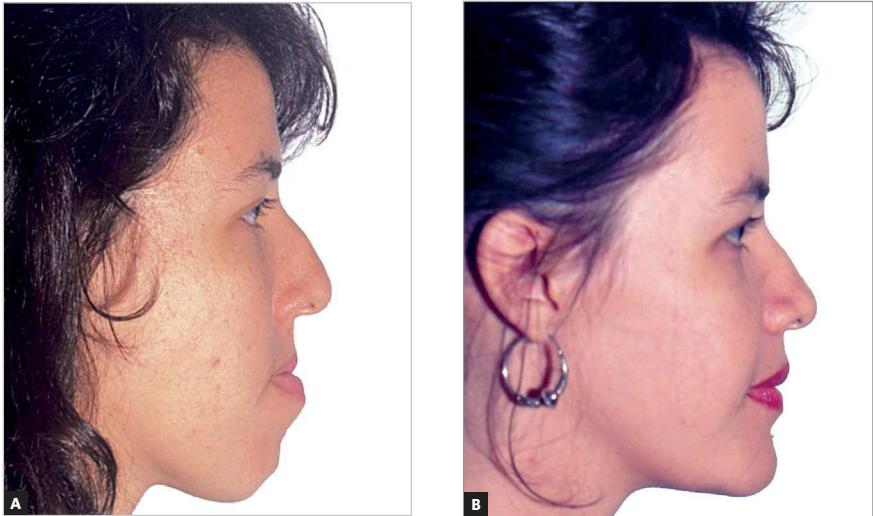

Figure 7 - Note the unsightly shape of the nasal dorsum (A). Improved nasal esthetics as a result of orthognathic surgery (B).

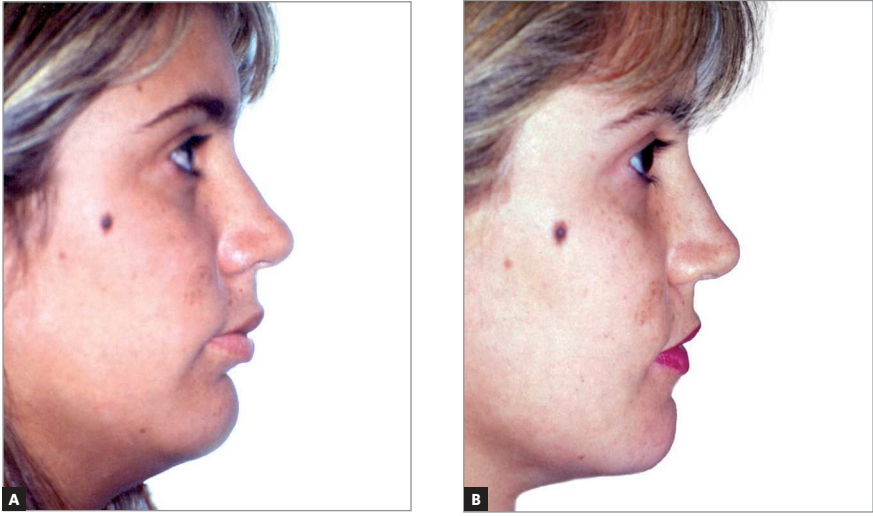

Figure 8 - Note unfavorable aspect of submental region (A). Note beneficial effect in the submental region after mandibular advancement (B).

When do you recommend plastic surgery as a complement to facial esthetics, concurrently with orthognathic surgery? (Carlos Estevanell Tavares)

The plastic surgery procedures more commonly performed as adjuncts to orthognathic surgery are rhinoplasty, submental liposuction and plication of the platysma muscle. As regards indication and timing, one should bear in mind that surgical movement of the maxilla and/or mandible can effect favorable changes in these anatomical regions. There are cases of individuals who wished to undergo rhinoplasty

and who gave it up after deciding that the effect of orthognathic surgery on the nose had delivered the desired esthetic outcome (Fig 7). Currently, most maxillofacial surgeons only indicate rhinoplasty when it is combined with isolated osteotomies of the mandible. When the patient is undergoing maxillary osteotomy, rhinoplasty is planned for 6 months after orthognathic surgery, but only if at that time the patient still wishes it. The same applies in the case of mandibular advancement, which in itself produces esthetic effects in the submental region (Fig 8).

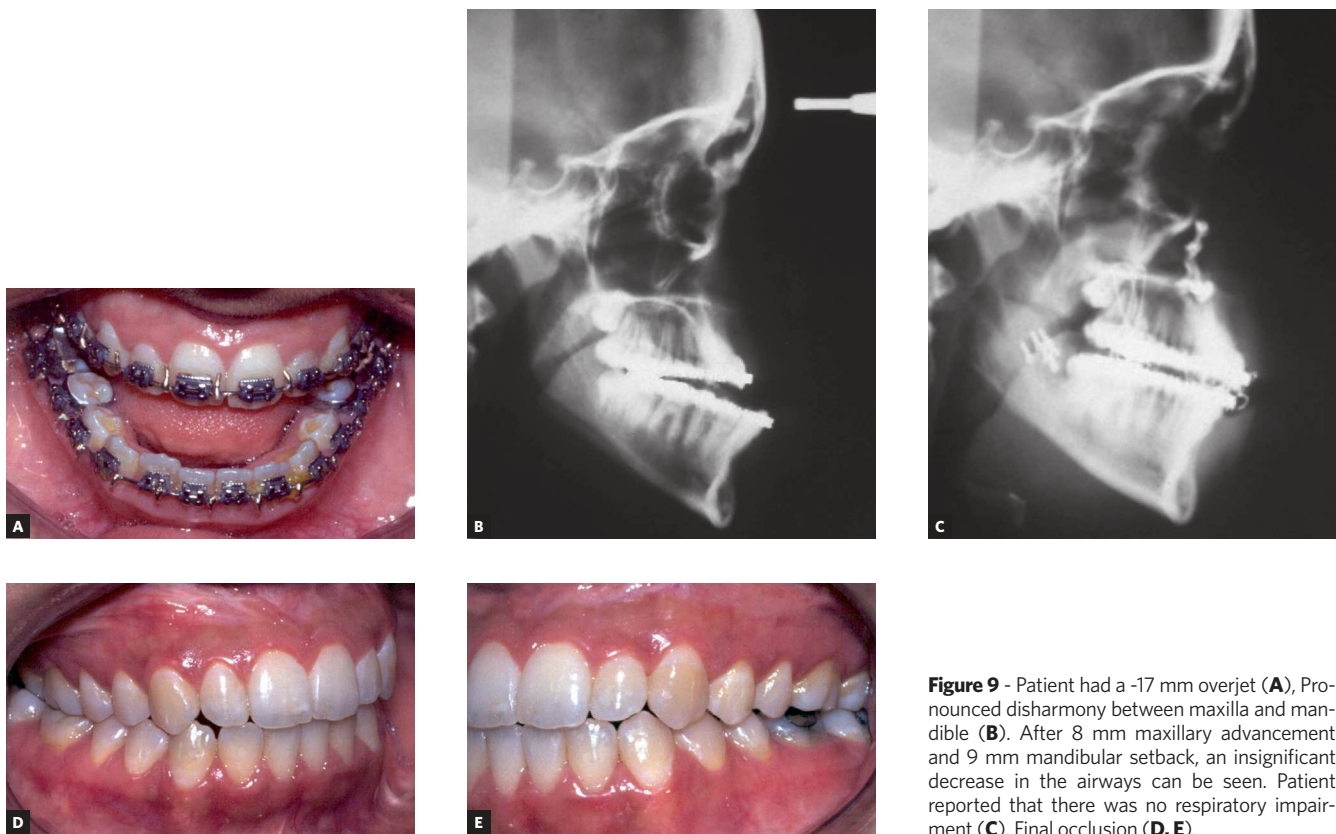


Figure 9 - Patient had a -17 mm overjet (A), Pronounced disharmony between maxilla and mandible (B). After 8 mm maxillary advancement and 9 mm mandibular setback, an insignificant decrease in the airways can be seen. Patient reported that there was no respiratory impairment (C). Final occlusion (D, E).

Conversely, in a patient undergoing mandibular setback who presents with excess submental tissue, liposuction and/or plication of the platysma at the time of orthognathic surgery seems to be the best approach.

FUNCTION

Surgical mandibular retrusions can impair the airspace and compromise breathing. Currently, how does surgical planning deal with this issue?
(Arno Locks)

Although decreases in airspace have been observed in mandibular setback samples, there are

no studies demonstrating functional impairment in these individuals. This may be because mandibular setbacks in excess of 7 mm or 8 mm are extremely rare. In treating severe Class III malocclusions, with overjets in excess of 10 mm, professionals tend to divide movements between the maxillary advancement and mandibular setback movements (Fig 9). Our group published an article in the September/October 2011 issue of this journal which analyzed 17 patients who had undergone isolated mandibular setbacks and other setbacks associated with maxillary advancement.

The average mandibular setback was of about 7 mm, and we noted an average reduction of about 1 mm in oropharynx, and about 3.5 mm in the hypopharynx. Despite these findings, none of the patients in the sample reported impaired breathing after surgery. In over 30 years of practice in orthognathic surgery I cannot recall having had any patients who returned with respiratory complaints after this procedure. I would only be reluctant to indicate mandibular setback for individuals with prior respiratory disorders or obese patients.

What scientific evidence is there regarding a cause-and-effect relationship between orthognathic surgery and snoring or sleep apnea? (Marco Antonio Almeida)

Orthognathic surgery has been used to treat sleep apnea in cases that prove refractory to more conservative, less invasive therapies. The literature reports that maxillary advancement performed simultaneously with mandibular advancement has yielded favorable results in a significant number of patients. There are researchers out there who have been conducting reliable, well-designed research that can attest to this fact, but I've had no experience with these patients.

A patient with no TMD symptoms before treatment starts presenting with TMD signs and symptoms after orthognathic surgery, such as clicking joints, pain in the TMJ region and restricted opening. What are the possible causes of this condition? Are the causes somehow related to orthodontic treatment, orthognathic surgery or attributable to chance? (Weber Ursi)

Joint dysfunction hardly ever occurs after orthognathic surgery. The most frequently occurring symptoms are muscle pain and discomfort, which the literature refers to as Myofascial Pain and Dysfunction Syndrome. This condition tends to be transient and is treated through measures to mitigate the symptoms and increase patient comfort. The rare cases of patients who experienced joint noises, which by the way were not painful, the incident occurred in the first weeks of the postoperative period and resolved spontaneously. This adaptability of patients might be due to the fact

that they are young and without prior dysfunction. I don't believe either orthognathic surgery or orthodontics is responsible for the onset of joint dysfunction in this particular population.

TECHNIQUE

What aspects of orthodontic preparation are you most often confronted with, which potentially compromise the outcome and stability of orthognathic surgery? How can these problems be avoided? (Weber Ursi)

Instability of movements during dental orthodontic preparation usually manifests itself in the medium or long term. After surgery the patient is still undergoing orthodontic treatment for about 1 year, after which a retainer tends to maintain the teeth in their correct position. In reassessing patients 10, 20 and even 25 years after ortho-surgical treatment I have noticed that the most significant losses occur in the transverse direction, as is usually the case with surgical relapses. When the patient needs significant transverse gains, either orthopedic or surgically assisted maxillary expansion seems to offer better results.

Do you believe that evaluation by a psychologist experienced with this type of patient in order to detect specific responses regarding acceptance of changes in appearance, actual motivation toward surgery, anxiety level, etc, would go a long way towards averting dissatisfaction with the outcome? Or is it your belief that this sort of detection can always and easily be carried out by the orthodontist and/or surgeon? (Carlos Elias Ferreira de Freitas)

I see no need for ortho-surgical patients to be routinely evaluated by a psychologist. In specific cases I do think such an evaluation would be highly advisable. On occasion, I have obviously had a few unsuccessful cases, and have also encountered difficulties in treating a handful of patients.

Those patients who lack family support, those living in conflict with relatives and making regular use of antidepressants should be more carefully evaluated by a professional psychologist. I strongly believe that patient selection is the key to a successful practice.

To what extent have the new distraction osteogenesis techniques contributed to resolve large mandibular advancements—including mandibular ramus lengthening—causing counterclockwise mandibular rotation? (Arno Locks)

Distraction osteogenesis, unlike what was initially believed, has not replaced conventional orthognathic surgery in conventional cases. Distraction osteogenesis is optimally indicated in the first decade of the patient's life to treat mandibular growth deficiencies. Cases of hemifacial microsomia or retrognathia resulting from TMJ ankylosis have been successfully treated by this method. The discomfort caused by prolonged use of a distractor in addition to difficulty in controlling the distraction vector are some of the disadvantages of distraction osteogenesis vs. orthognathic surgery starting in the second decade of the patient's life.

The conduct advocated by U.S. professor Larry Wolford, who often indicates surgical interventions in the temporomandibular joint concurrent with orthognathic surgery when the patient presents with intra-joint changes, has met with widespread acceptance in Brazil. What is your opinion on the subject?

(Carlos Elias Ferreira de Freitas)

I worked with Dr. Wolford for 2 years during my residency program and I know for a fact that he is a highly judicious professional. I believe this is not a routine approach, and the numerous joint interventions that he performs simultaneously with orthognathic surgery are due to, firstly, the large volume of patients he operates on, and secondly, because he is a reference in the treatment of patients with joint dysfunction. I have limited experience in performing orthognathic surgery in joint TMD patients. The vast majority of patients I treat are young and hardly ever present with joint TMD pain. I see no need to perform concurrent joint intervention. As in the cases of muscle TMD, these patients' dysfunction is treated conservatively before orthognathic surgery and, if necessary, further treatment is provided after surgery.

STABILITY

Some patients, after mandibular advancement surgery for correction of Class II, present with

condylar resorption, totally compromising the outcome. What have studies so far contributed on this topic? (Arno Locks)

It is important to differentiate condylar resorption from condylar remodeling. Condylar remodeling is a sort of "wear", albeit minor, which occurs in surgical and non-surgical patients, causing increased overjet over a few years. This can be considered a physiological phenomenon. It has been more often observed in patients who have undergone mandibular advancement, especially in those with the following three sets of features: 1) Small mandibular condyles inclined posteriorly, 2) open mandibular plane and short mandibular ramus, and 3) decreased posterior facial height and increased anterior facial height. Treatment results for these patients may be partially or totally compromised by this phenomenon. Condylar resorption has been widely studied and described, especially by the team of researchers led by Dr. Leonard Kaban, in Boston. In these cases condyles disappear altogether as meaningful retrognathia and open bite develop. There are many idiopathic cases, where patients never underwent orthodontic or ortho-surgical treatment. Among the possible causes of this condition are rheumatoid arthritis, use of corticosteroids, systemic lupus erythematosus, scleroderma, other collagen diseases, and even orthognathic surgery. Healthy patients who are good candidates for orthognathic surgery, but who present with the three sets of features I mentioned earlier should be alerted about the possibility that this phenomenon might occur.

The hierarchy of stability of ortho-surgical cases established by the North Carolina team of researchers is usually cited in scientific papers. Drawing on your extensive experience, how would you assess this hierarchy, and what factors can affect it? (Marco Antonio Almeida)

The two extremes of this "hierarchy" seem quite relevant: Maxillary repositioning is very stable, and maxillary expansion induces a certain medium and long term instability. Research shows that the routine use of rigid internal fixation has taken maxillary lowering off the list of unstable maxillary procedures. The presence of four mini-plates for

stabilization combined with bone grafting appear to give optimum vertical stability to the maxilla. As far as mandibular setback surgery is concerned, contrary to what is stated in the article, I have had excellent stability. I do however use, whenever possible, intraoral vertical osteotomy, which is a technique renowned for its high stability. The literature demonstrates that the optimal stability afforded by sagittal osteotomy in mandibular advancement is not replicated in mandibular setbacks, and the latter was the technique used in the study group. The major hurdle in terms of stability in orthognathic surgery today has to do with mandibular advancement, and this procedure appears in the article as the second most stable. However, when you read the article carefully you can't help but realize that mandibular advancement was performed or discussed only in individuals with normal or short facial height, which does not encompass those patients presenting with the three sets of features I referred to earlier on. I strongly believe that a study conducted in Class II patients with the three sets of characteristics described above will inevitably yield different outcomes.

FUTURE

How do you view the current position held by orthognathic surgery in Brazil? How would you compare it to other countries? (Antenor Araújo)

We owe the inception of orthognathic surgery in Brazil to pioneers, the likes of Mario Graziani, Paulo Pinho de Medeiros, Italo Gandelman, João Jorge de Barros and João Ephraim Wagner, and I can't think of a better start. With the development of "Modern Orthognathic Surgery" – by which is meant a combination of surgery and orthodontics – there was a refinement in surgical techniques that already existed, and are still widely employed to this day, combined with new concepts in diagnosis and treatment planning. When he arrived in Brazil in 1978 after 3 years spent in Dallas, Texas, USA, Dr. Antenor Araújo helped to develop Brazilian orthodontics and enabled a most fruitful exchange with centers of excellence abroad. Today Brazil has established itself in the international scene given the quality of our professionals, which is comparable to that of the best centers in the world. The

challenge we face today lies in training high-level professionals to serve 200 million people in a country of continental proportions. It is still not uncommon to see surgeons packing a "doctor's bag" with surgical instruments and traveling to operate on patients a long ways from home. This is obviously not the best care you can provide. I'd hate to have, say an abdomen surgery, today and not have the surgeon around the next day because he has flown off somewhere else to see another patient. Our challenge is to train more and more quality professionals and spread them throughout Brazil. I try to give my humble contribution.

What medium to long-term advances can we expect in the field of Orthognathic Surgery? What will this major surgery be like 20 years from now? (Weber Ursi)

Although there have been refinements in surgical techniques, the main developments have occurred and tend to develop further in surgical materials and in the area of digital technology. Rigid fixation techniques have improved through the development of finer plates and screws, without any noticeable loss in quality. Alloplastic materials are replacing autografts at such a rate that I believe in the near future we will no longer need to remove the patient's own bone for any purpose. Digital diagnostics and planning save time and impart reliability to ortho-surgical treatments. I really look forward to the development of less traumatic bone cutting instruments. Less invasive surgeries? Robotic Surgery? Time will tell.

YOUR SPACE

What were the three most gratifying ortho-surgical cases in your career? (Marco Antonio Almeida)

The first patient I would highlight is a girl now 25. She has a 7-year-old daughter with a severe retrognathia and no mouth opening as a result of temporomandibular joint ankylosis. The patient was operated on to resolve the ankylosis in two different steps, i.e., she received costochondral graft to improve mandibular growth in another intervention, and finally underwent orthognathic surgery. The interventions put in place during the first decade of life are aimed at enabling mobility and stimulating growth. The ortho-surgical

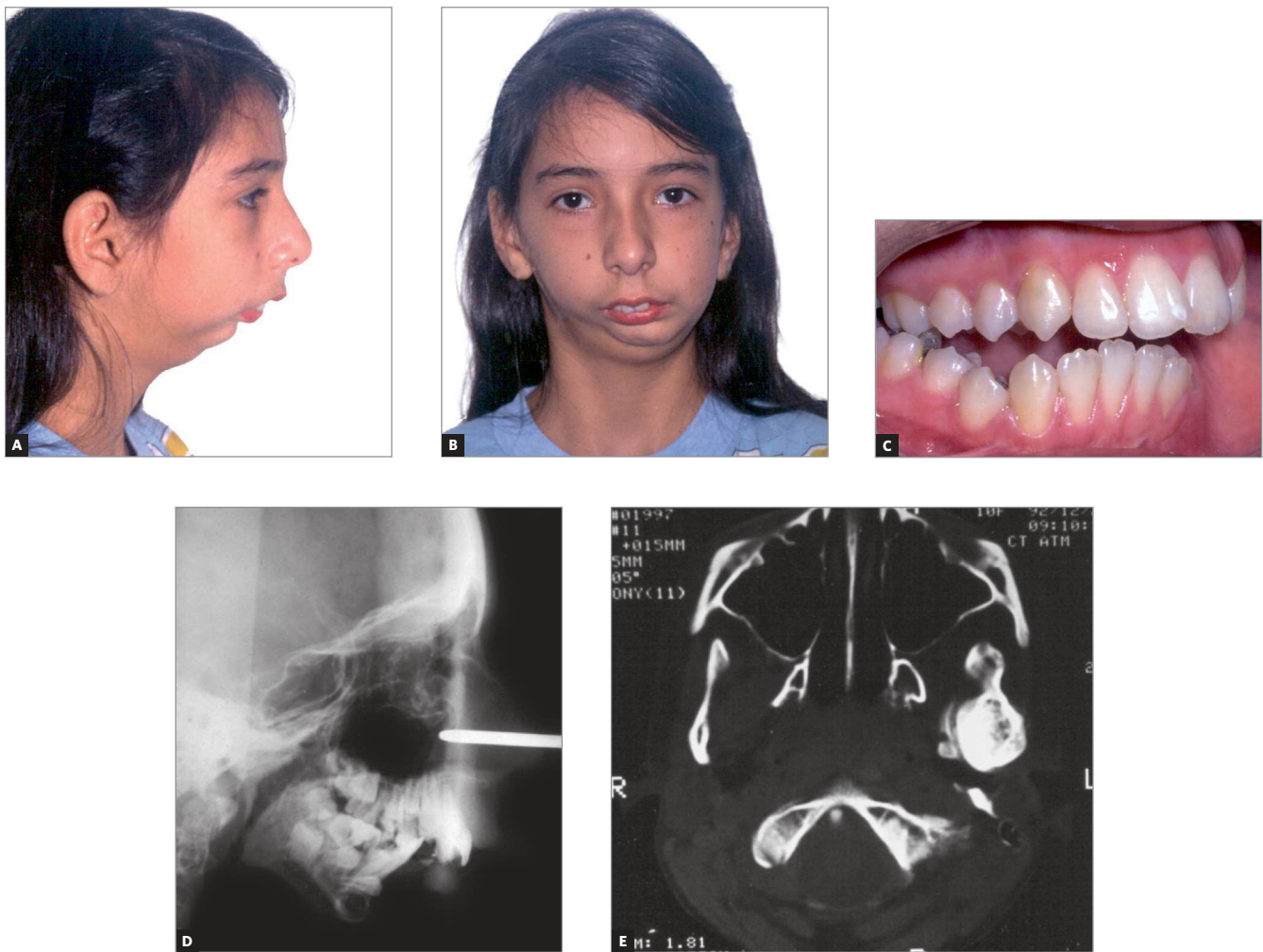


Figure 10 - Seven-year-old patient showing retrognathia with severe mandibular deviation to the left (**A, B**). Marked Class II malocclusion (**C**) and severely underdeveloped mandible (**D**). CT scan showed a major ankylotic block on the left side (**E**).

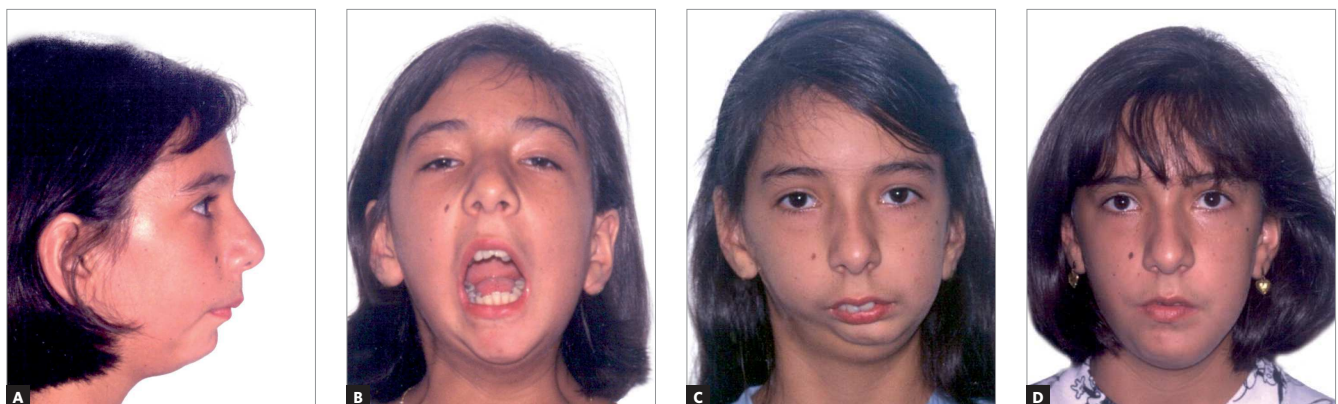

Figure 11 - After two interventions and 4 years into treatment, there was improvement in oral movements and esthetics (**A, B**). Patient at age 7 and 14 (**C, D**).

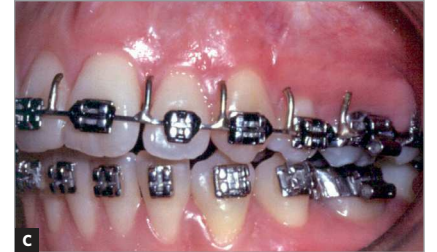
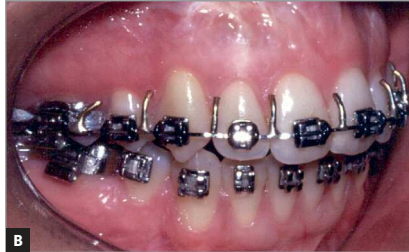
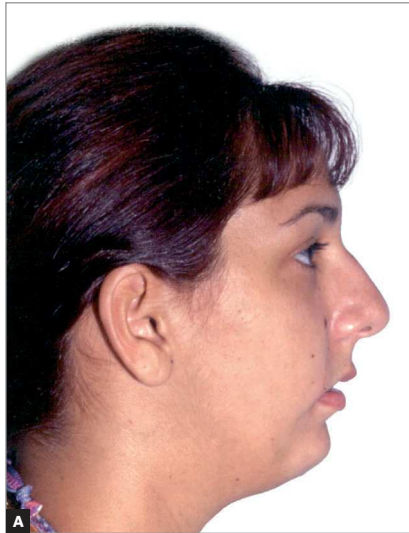Figure 12 - Patient at age 21 years.

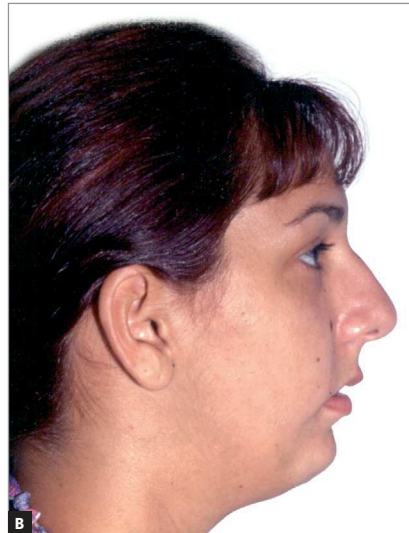
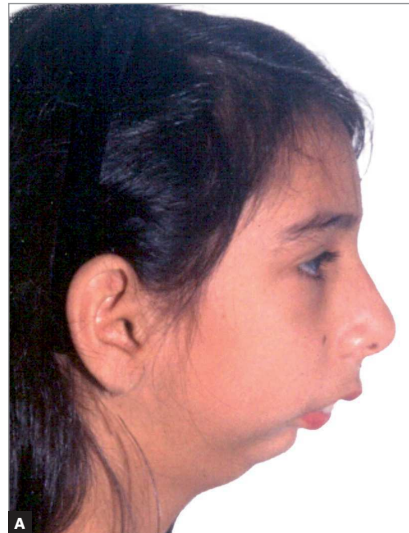
Figure 13 - Note degree of mandibular development about 14 years after interventions.

treatment achieved a better occlusion and satisfactory facial esthetics (Figs 10 to 13).

Shy and withdrawn, the second patient presented for treatment at 20 years of age. According to his mother, he had been bullied for many years because of his unsightly facial appearance. He underwent

orthodontic treatment and maxillomandibular osteotomies, and was given psychological support postoperatively. About a year after surgery and orthodontic treatment, he returned, now more talkative, lively and even responding to the jokes and remarks from members of our surgical team (Figs 14, 15, 16).

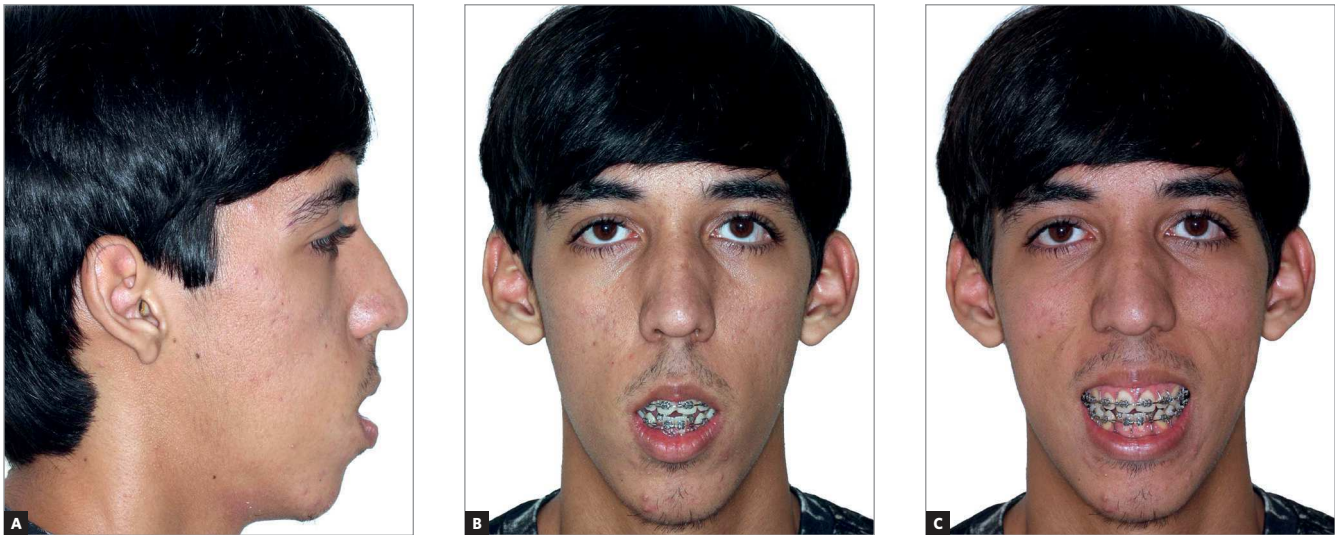

Figure 14 - Hypoplastic mandible and greatly increased mandibular plane. Note long face and severe lip incompetence (**A, B**); patient was extremely shy and hardly ever smiled (**C**).

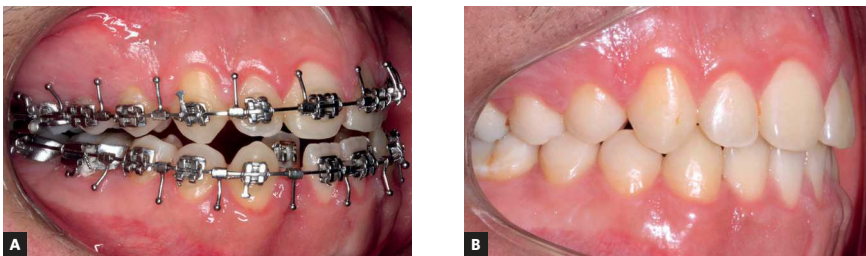


Figure 15 - Preoperative occlusion. Due to difficulties in social adjustment, "Anticipated Benefit" was employed (**A**). Occlusion about 14 months after surgery (**B**).

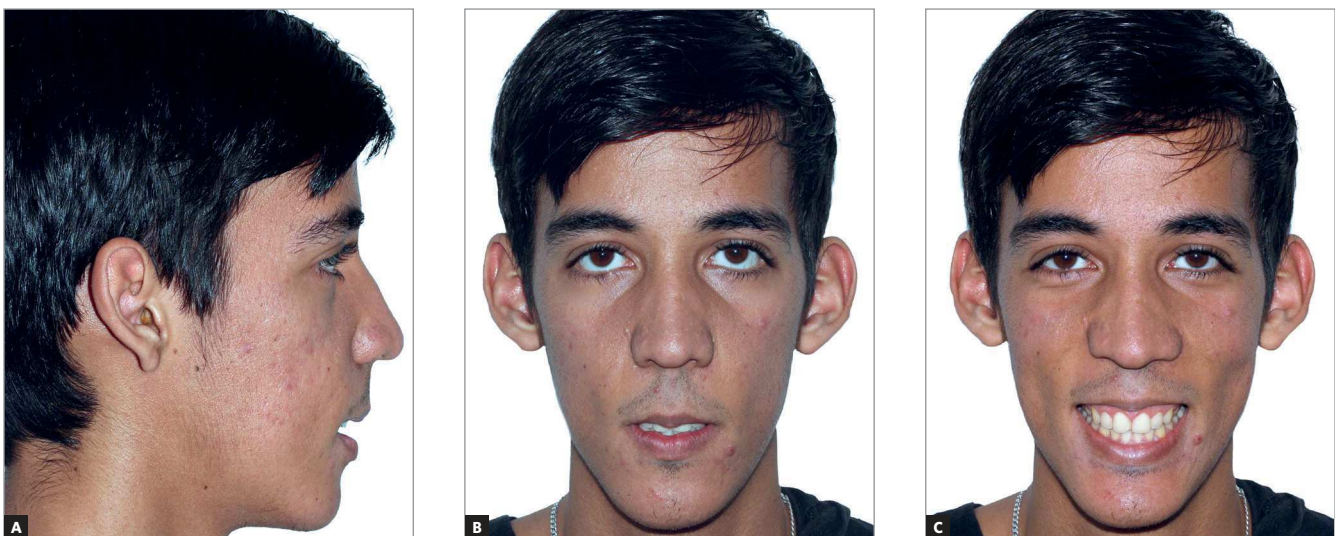


Figure 16 - 14 months postoperatively. Note improvement in interlabial relationship. Changes in behavior and attitude were remarkable.

The third patient was a young woman aged 23, who exhibited several positive characteristics such as beautiful skin, eyes and hair which, however, were undermined by a complex dentofacial deformity. She presented with maxillary retrusion,

maxillary vertical hypoplasia, mandibular prognathism and lateral deviation of the mandible. As a result of the successful functional and esthetic outcome achieved, positive changes occurred in many areas of her life (Figs 17 to 20).

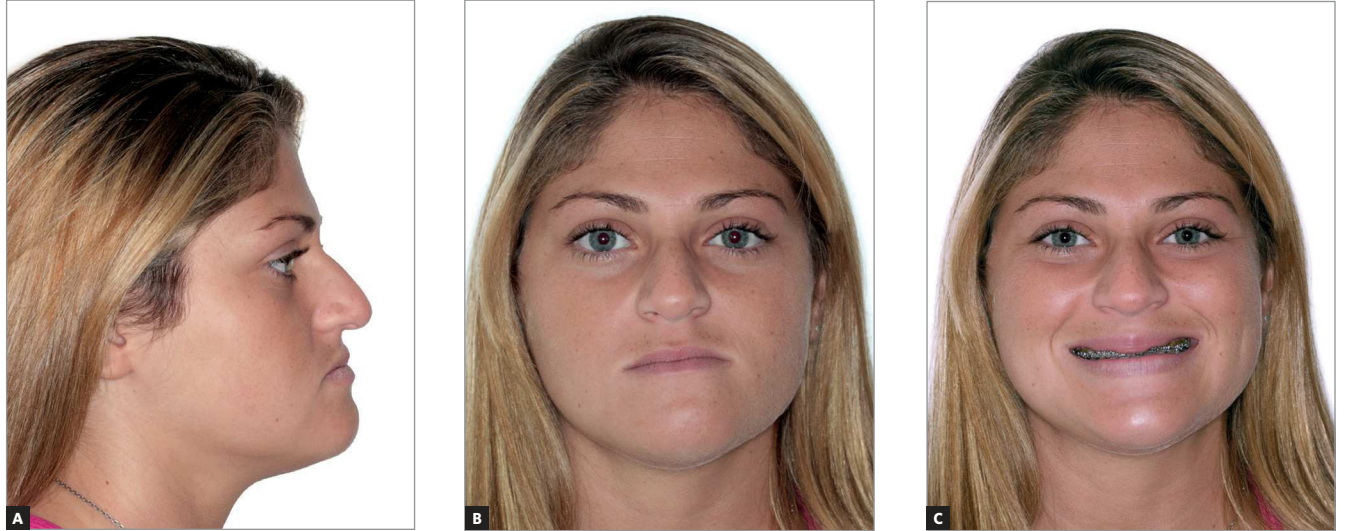

Figure 17 - **A)** The maxilla was retruded, the mandible overly protruded and the nasal dorsum showed an unfavorable contour, **B)** patient had facial asymmetry with marked mandibular deviation; **C)** the maxilla was uneven and also hypoplastic in the vertical direction, which compromised the smile.

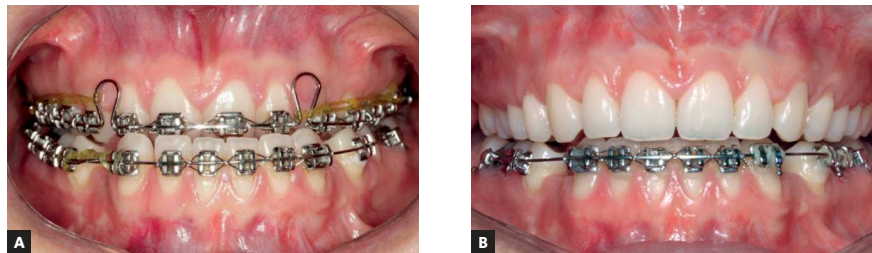


Figure 18 - Preoperative occlusion **(A)** and approximately 8 months after surgery **(B)**.

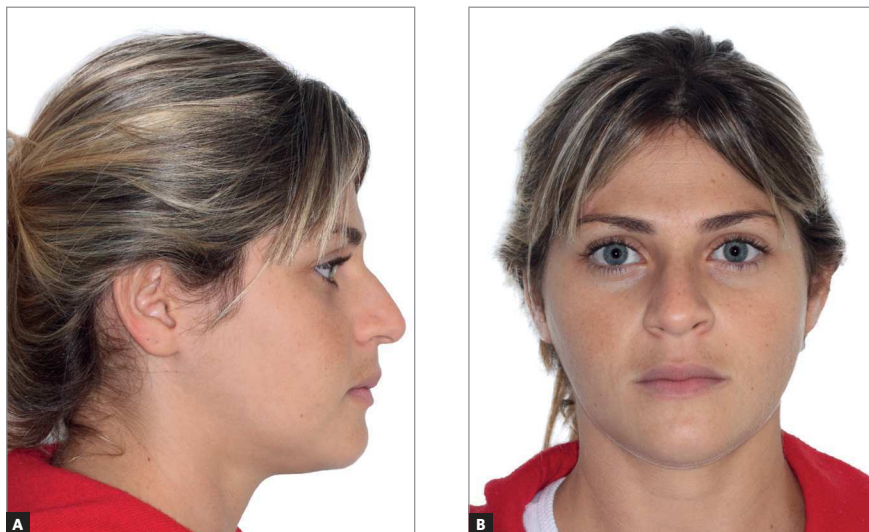

Figure 19 - Patient about 8 months after surgery.

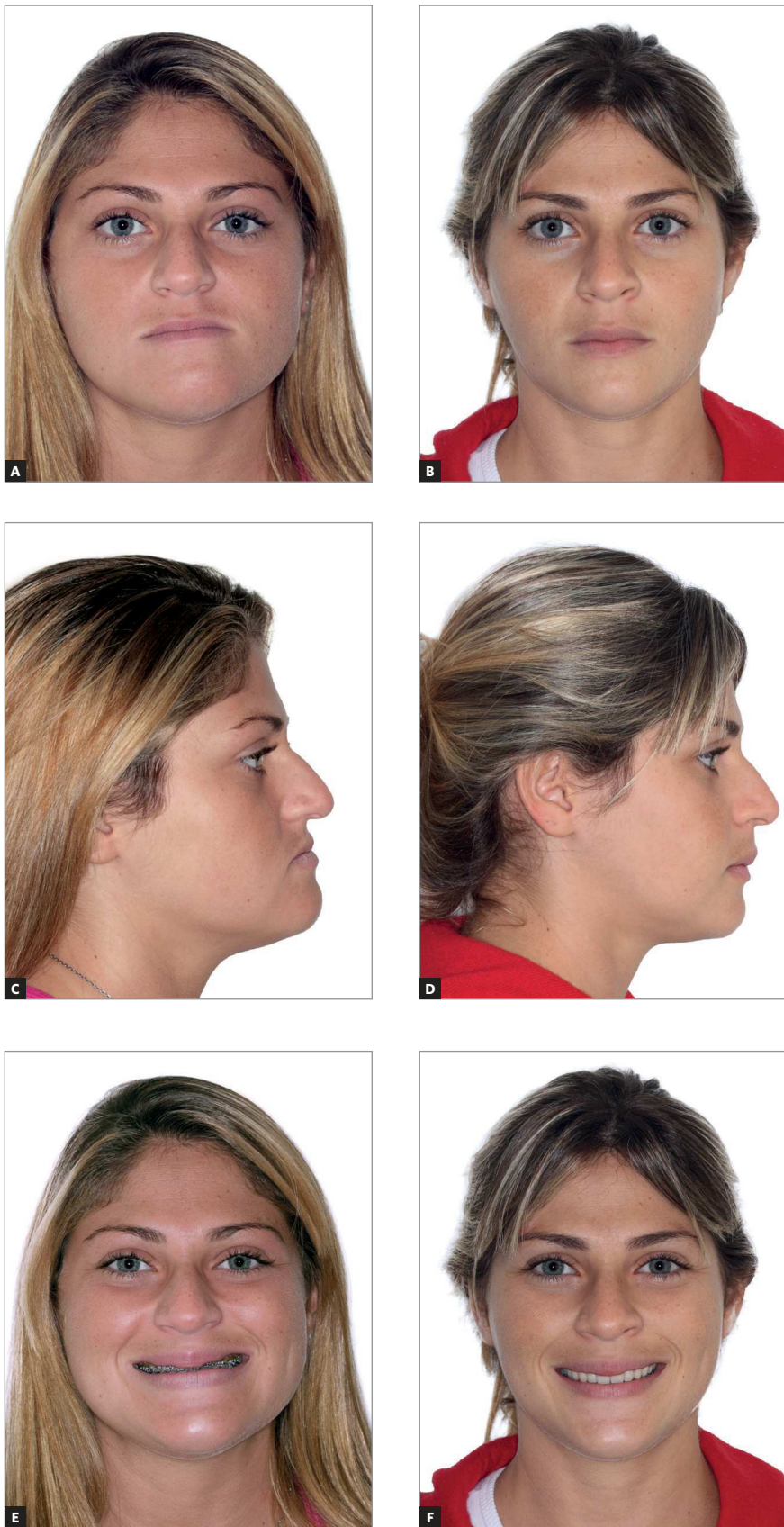

Figure 20 - Changes in frontal view resulting from esthetic treatment (**A, B**). Profile before and after surgery (**C, D**). An improved facial symmetry and smile highlighted other patient features (**E, F**).

REFERENCES

1. Gornic C, Nascimento PP, Melgaço CA, Ruellas ACO, Medeiros PJD, Sant'Anna EF. Análise cefalométrica das vias aéreas superiores de pacientes Classe III submetidos a tratamento ortocirúrgico. Dental Press J Orthod. 2011 Sept-Oct;16(5):82-8.

Antenor Araújo

- » Post-Doc in Bucomaxillofacial Surgery, University of Texas.

Arno Locks

- » PhD in Orthodontics, UNESP. Post-Doc, Royal School of Dentistry, University of Aarhus.

Carlos Elias Ferreira de Freitas

- » Professor of Surgery and Bucomaxillofacial Trauma, Hospital Geral Roberto Santos.
- » Professor of Orthognatic Surgery, Specialization Courses in Orthodontics, UFBA and ABO-BA.
- » Head of the Bucomaxillofacial Surgery and Trauma Division, SESAB.
- » Head of the Bucomaxillofacial Surgery and Trauma Division, Hospital da Bahia.

Carlos Estevanell Tavares

- » PhD in Dentistry, UFRJ.

Marco Antonio Almeida

- » Post-Doc in Orthodontics, University of North Carolina.

Weber Ursi

- » PhD in Orthodontics, USP.