

Cephalometric effects of the use of 10-hour Force Theory for Class II treatment

Marise de Castro Cabrera¹, Carlos Alberto Gregório Cabrera², Karina Maria Salvatore de Freitas³, Marcos Roberto de Freitas⁴, Guilherme Janson⁴, Laura de Castro Cabrera⁵

Objective: This study aimed to evaluate the cephalometric effects promoted by the orthodontic treatment of Class II malocclusion patients with the use of the 10-Hour Force Theory, that consists in the use of fixed appliances with 8 hours a day using a cervical headgear appliance and 16 hours a day using Class II elastics, 8 hours on the first mandibular molar and 8 hours in the second mandibular molar.

Methods: Sample comprised 31 patients with mean initial age of 14.90 years, final mean age of 17.25 years and mean treatment time of 2.35 years. The lateral cephalograms in pre-treatment and post-treatment stages were evaluated. Evaluation of cephalometric changes between initial and final treatment phases was performed by paired *t* test.

Results: The cases treated with the 10-Hour Force Theory presented a slight restriction of anterior displacement of the maxilla, increase in the effective length of the mandible, significant improvement of the maxillomandibular relationship, significant increase in anterior lower face height, distal tipping of the maxillary premolar crowns, extrusion and distal tipping of the roots of maxillary molars, significant proclination and protrusion of mandibular incisors, significant extrusion and mesialization of mandibular molars, besides a significant correction of the molar relationship, overjet and overbite.

Conclusion: The use of the 10-Hour Force Theory in treatment of Class II malocclusion provided satisfactory results.

Keywords: Angle Class II malocclusion. Corrective orthodontics. Extraoral traction appliances.

¹ Coordinator of the Specialization Course in Orthodontics, Herrero Faculty.

² Professor of the Specialization Course in Orthodontics, Herrero Faculty.

³ Coordinator of Master Course in Dentistry/Orthodontics, UNINGÁ.

⁴ Professor of the Department of Pediatric Dentistry, Orthodontics and Social Health, FOB-USP.

⁵ Student of the Specialization Course in Orthodontics, Herrero Faculty.

How to cite this article: Cabrera MC, Cabrera CAG, Freitas KMS, Freitas MR, Janson G, Cabrera LC. Cephalometric effects of the use of 10-hour Force Theory for Class II treatment. *Dental Press J Orthod.* 2012 Nov-Dec;17(6):31-40.

Submitted: August 14, 2008 - **Revised and accepted:** September 08, 2008

» The author reports no commercial, proprietary or financial interest in the products or companies described in this article.

Contact address: Karina Maria Salvatore de Freitas
Rua Jamil Gebara 1-25, Apto 111 - Bauru/SP - Brazil
CEP: 17017-150 - E-mail: kmsf@uol.com.br

INTRODUCTION

The goal of orthodontic treatment is to restore the normal occlusion characteristics. The Six Keys to the Perfect Occlusion advocated by the North American orthodontist Andrews¹ provide safe therapeutic goals, so we can identify deviations and seek perfect finishing of orthodontic treatment. The maxillary arch should match the mandibular arch containing it, so that there is a perfect intercuspation and thus promoting maximum function with minimum effort considering the longevity of the stomatognathic system.^{22,33,34}

The Class II malocclusion represents a challenge in modern orthodontics. It represents one of the most comprehensive malocclusion in amount of treatment protocols and diversity of appliances for its treatment. The diagnosis of the Class II malocclusion is crucial to determine the treatment planning. Silva Filho, Freitas and Cavassan³⁶ reported that 42% of the malocclusions are Class II, being 15% skeletal and 27% dental, which has no facial involvement and shows a good relationship between the apical bases. The treatment planning for Class II associated to dental protrusion can include dental extractions or distalization of the molars.

The treatment protocol most adequate for the success of orthodontic treatment of the Class II malocclusion, seeking better results, remains a problem for the orthodontist. The headgear with cervical anchorage is an effective therapeutic option used in orthodontics for maxillary molar distalization during the craniofacial growth and development stage,²⁶ but its efficiency is closely associated with patient cooperation since this appliance is removable, presents negative social impact and external elements, hindering the cooperation by teenagers. Given this, many intra-oral devices have been in evidence, providing satisfactory results and requiring minimal patient collaboration.^{10,19,21,23,28,29,35} It is known through researches that these devices have limitations and can cause unwanted tooth movement.

An important contribution to the treatment of molar distalization, comes from the concept of Andrews^{3,4} so called "Ten-Hour Force Theory." This concept is based on a biological theory which explains that a tooth only initiates its process of orthodontic movement after being submitted to force application for a continuous period of 10 hours, i.e., when applying

a force with the aim of promoting orthodontic movement, the osteoclasts responsible for bone resorption and osteoblasts responsible for bone apposition, only promote conditions for movement after 10 hours of continuous use of force. When the force ceases, the tooth movement stops immediately. After a period of approximately 30 minutes at rest, it will be necessary to apply more 10 hours of continuous force to restart the orthodontic movement.

It is a way to generate a non-reciprocal force. Based on this theory, the professional can alternate the use of intermaxillary elastic with the use of the extraoral headgear to obtain a distalization of the maxillary molars, so that forces are imposed on those teeth for a period of approximately 24 hours a day. "Teeth that do not require movement, can be used for up to ten hours, as non reciprocal anchorage for teeth that need movement, or as anchors for the application of orthopedic force".³ This treatment protocol can be used in two stages during orthodontic treatment: 1st. Phase – distalization of maxillary molars; and 2nd. Phase – Retraction or reduction of the overjet. Each phase has three stages.

As there were no publications on the Ten-Hour Force Theory or reports of experimental or microscopic studies, Cuoghi¹¹ analyzed and quantified (macro-and microscopically), the first moments of the induced tooth movement in the teeth of five young adult monkeys. For the conditions of continuous dissipating force, the tooth movement after 5, 10, 15 and 20 hours was analyzed and for continuous dissipating, but intermittent force, the periods of 10hF/5hR (hF=hours of force; hR=hours of rest), 10hF/10hR, 10hF/5hR/5hF and 10hF/5hR/10hF. Based on the methodology used and considering the inherent limitations, the results obtained allowed the author to verify that for a favorable tooth movement, the forces must be applied continuously throughout the day. The rest periods should be minimal and do not reach 5 hours. In the first moments, the interruption in hours of continuous dissipating force application does not favor the efficiency of the induced tooth movement. The author concluded from this study that the Andrews⁴ hypothesis on the amount of movement is valid, i.e., for a favorable tooth movement, the forces must be applied continuously, reaching maximum movement after 10 hours of application.

The absence of studies published adopting this methodology reinforces the relevance of this research.

PROPOSITION

This study aimed to evaluate the cephalometric effects promoted by orthodontic treatment of patients with Class II malocclusion using the 10-Hour Force Theory, which consist of the use of fixed orthodontic appliances with 8 hours daily use of cervical headgear and 16 hours use of Class II elastics, 8 hours applied to the first mandibular molar and 8 hours applied to the second mandibular molar.

MATERIAL AND METHODS

Material

The sample used for this study consisted of 62 lateral cephalometric radiographs, 31 pre-treatment and 31 post-treatment, of a group of patients with initial Class II malocclusion who were treated orthodontically with fixed appliances and the use of the Ten-Hour Force Theory. The criteria for sample selection were based on the following characteristics: 1- bilateral Class II molar relationship, 2 - Exclusion of cases with absence or loss of permanent teeth.

The objective at the end of treatment was to achieve the Six Keys to the Perfect Occlusion.^{1,2}

The sample consisted of 31 patients with mean initial age of 14.90 years and final age of 17.25 years (Table 1), 22 female and 9 male. Patients' records were obtained from the archives of Cabrera & Cabrera orthodontic clinic and were treated by them. The Class II malocclusion was corrected by using the Ten-Hour Force Theory associated to fixed orthodontic appliances with Straight Wire technique (A' Company). The mean treatment time was 2.35 years.

Methods

10-Hour Force Theory

The protocol for the Ten-Hour Force Theory used for molar distalization began with banding and soldering double tubes to the maxillary first molars (A' Company) and bonding of Straight Wire Andrews brackets (A' Company), 0.022 x 0.025-in slot, with the exception of the maxillary premolars.

The fixed orthodontic treatment was performed conventionally, with teeth leveling and alignment until reaching the 0.016-in stainless steel wire, when

the preparation was started for the first stage of the Ten-Hour Force Theory (T10), which aims to distalize maxillary molars. Initially, the extraoral headgear appliance was made and then the sliding jig for the use of intermaxillary Class II elastics. A hook made of 0.8 mm brass wire was soldered to the telescopic tube by holding the hook with a Mathieu plier at the end the telescopic tube of 0.07 mm in diameter and by applying soldering flux to the base of the hook. The brass wire was cut 7 mm above the solder and after finishing, the hook was made facing mesially and cervically.

With the maxillary arch previously prepared, without premolar bonding to receive the T10, the distance between the upper tube entrance and the distal surface of the canine bracket was measured with the telescope tube directly in the oral cavity, marking with a pen, and the excess of the telescopic tube was cut with a carborundum disc. The procedures were repeated on the opposite side. The telescopic tubes were attached to the leveling arch with the hooks facing mesially and tied to the bracket slots using metallic ligature (Fig 1). The procedures were repeated on the opposite side.

1st Phase: Distalization of the first molars

This phase is divided into 3 distinct stages:

» 1st stage – headgear appliance with cervical traction, with a force intensity of 400 to 500 cN/side, used at night, only for 8 hours a day (Fig 2).

» 2nd stage – Class II intermaxillary elastics that should be attached from the first molar tube hook to the telescopic tube hook, bilaterally (Fig 3). The patient is instructed to use it for 8 hours daily.

» 3rd stage – Class II intermaxillary elastics which should be attached from second mandibular molar tube hook to the telescopic tube hook, bilaterally (Fig 4). The patient is instructed to use it for 8 hours a day.

Table 1 - Descriptive statistics (mean, standard deviation, minimum and maximum) of the initial and final ages and treatment time (n = 31).

Variables	Mean	SD	Minimum	Maximum
Initial age	14.90	1.80	11.21	18.69
Final age	17.25	1.99	13.32	22.11
Treatment time	2.35	0.85	0.83	4.33

The magnitude of elastic force should be between 200 and 250 cN, measured with a dynamometer. Elastics should be changed daily for both sides and they should only be removed during meals for a period of approximately 30 minutes.

Thus, the maxillary first molars receive 24 hours of continuous force per day, favoring its distalization, and the mandibular teeth are not moved since the force is removed upon completion of eight hours of application, not reaching the 10-hour period necessary for the orthodontic movement to be initiated.

This phase ends when the anteroposterior correction of the maxillary first molar is complete (Class I molar relationship). In this situation, the brackets of the maxillary premolars can be bonded. Orthodontic treatment follows conventionally until the achievement of the six keys to normal occlusion recommended by Andrews,¹ when it should end with the removal of the fixed orthodontic appliance and placement of retainers, for the maxillary arch a modified Hawley plate and a fixed retainer bonded from canine to canine for the lower arch.

The telescopic tube used during the application of the Ten-Hour Force Theory, can be replaced by a sliding jig made of stainless steel wire

with 0.7 mm diameter and with this device the fixed appliance can be fully bonded, since the jig is placed above the brackets (Fig 5).

The use of the Ten-Hour Force Theory can be used for retraction or reduction of the overjet. This phase is divided into three distinct stages of 8 hours. The force application is performed by intramaxillary elastics attached from the maxillary first molar tube to the rectangular wire hook associated to the headgear for 8 hours. After this period, intermaxillary Class II elastics are tied to the rectangular wire hook alternating between two mandibular posterior teeth on each side for every 8 hours during the day. The use of the Ten-Hour Force Theory, can also be applied for the purpose of anchorage loss, always using the elastics in 3 different stages.

Cephalometric method

All radiographs were digitized in grayscale at 300 dpi (dots per inch) with a scanner (Microtek ScanMaker i800) and recorded on a DVD. Then, they were inserted in the Dolphin Imaging software Version 10.0 (Dolphin Imaging and Management Solutions, Chatsworth, CA, USA), where the cephalometric points were marked and the cephalogram and

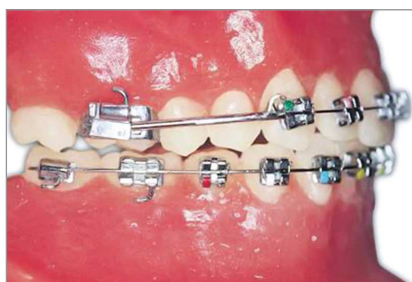

Figure 1 - Upper and lower arches prepared to receive the T10.

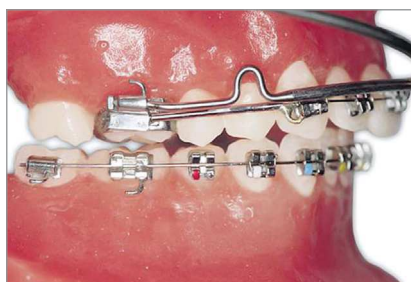

Figure 2 - T10 first stage: Use of the headgear.

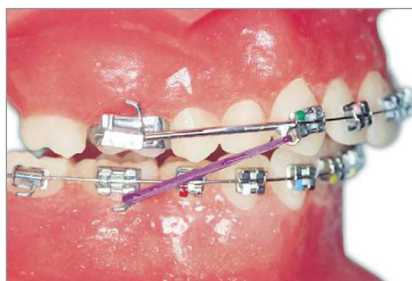

Figure 3 - T10 second stage: Use of Class II elastics, anchored on the lower first molar.

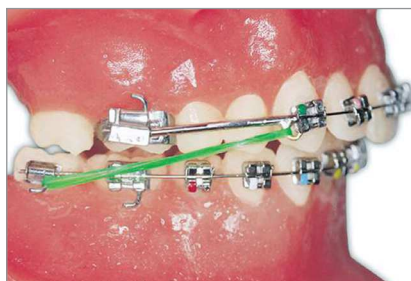

Figure 4 - T10 third stage: Use of the headgear.

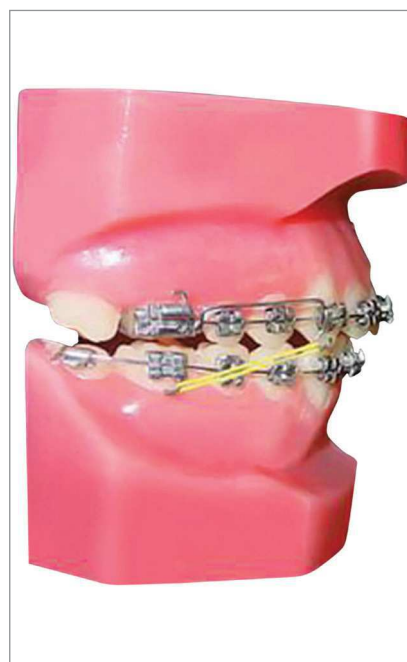

Figure 5 - Sliding jig substituting the telescopic tube for the use of Class II elastics in T10.

measurements were performed automatically by the software. All radiographs had the magnification factor (6%, 7.9% and 9.8%) corrected by the software. Cephalometric variables used are shown in Figures 6 to 9.

Error of the method

To assess intra-examiner error, 20 radiographs were randomly selected, and the measurements were repeated in the Dolphin software after an interval of one month. The formula proposed by Dahlberg¹² ($Se^2 = Sd^2/2n$) was applied to estimate the magnitude of casual errors, while systematic errors were evaluated by paired *t* test, according to Houston.²⁰

Statistical analysis

To evaluate the cephalometric changes that occurred between initial and final treatment stages, the dependent *t* test was used. All tests were performed

in the Statistica software (Statistica for Windows, version 6.0, StatSoft Inc.), adopting a significance level of 5% ($p < 0.05$).

RESULTS

Systematic errors were found for only two variables: ANB and 4-PTV. The greater random errors found were 1.79° for ANB and 1.25 mm for 4-PTV (Table 2). Table 3 shows the results of the intragroup comparison of cephalometric changes.

DISCUSSION

Method

To assess maxillary and mandibular dental components, points were marked at the first molars, first premolars and central incisors. The point located in the center of clinical crown (centroid), exactly at the midpoint of the mesiodistal distance, was chosen due to

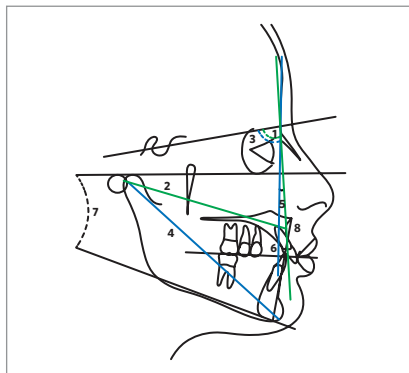


Figure 6 - Skeletal cephalometric measurements: 1) SNA; 2) Co-A; 3) SNB; 4) Co-Gn; 5) ANB; 6) Wits; 7) FMA; 8) LIFH.

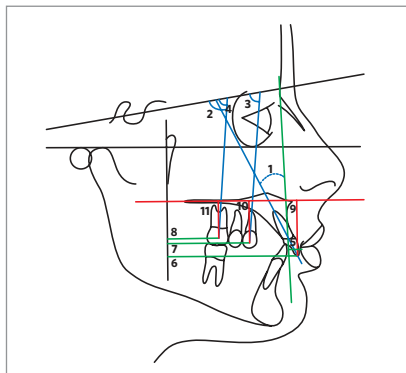


Figure 7 - Upper dental cephalometric measurements: 1) 1.NA; 2) 1.SN; 3) 6.SN; 4) 4.SN; 5) 1-NA; 6) 1-PTV; 7) 4-PTV; 8) 6-PTV; 9) 1-PP; 10) 4-PP; 11) 6-PP.

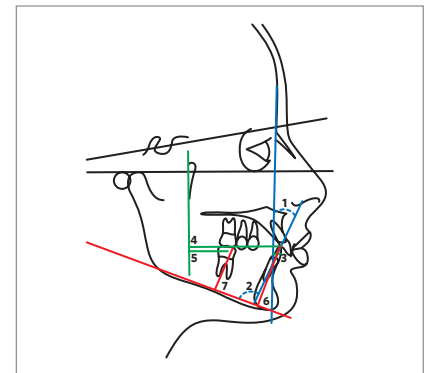


Figure 8 - Lower dental cephalometric measurements: 1) 1.NB; 2) IMPA; 3) 1-NB; 4) 1-PTV; 5) 6-PTV; 6) 1-GoMe; 7) 6-GoMe.

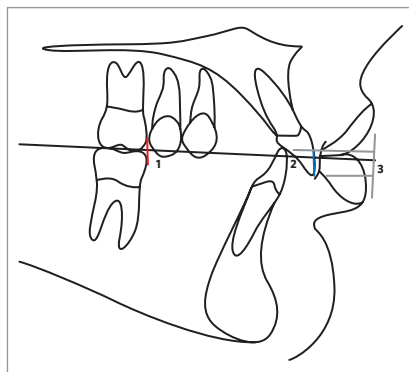


Figure 9 - Dental measurements: 1) Molar Relationship (MR); 2) Overjet (OJ); 3) Overbite (OB). The mesial surface of the upper first molar should be 3 mm distal to the mesial surface of the lower first molar to describe a Class I molar relationship (negative value = -3 mm). The example demonstrates a -0.5 mm for the molar relationship.

the claim of several authors that this point accurately represents dental changes, when compared with points located in the mesial and distal surfaces, which can show excessive changes when considering distal tooth angulation, not reflecting the actual movement of the maxillary molar and superestimating extrusion or intrusion of the assessed teeth.^{15,31}

For the evaluation of the linear dental changes, the pterigomaxillary vertical line was used. This measure is considered a very reliable reference, due to the fact that it does not change significantly in the anteroposterior direction during the craniofacial growth and for being consistently used in the literature.^{5,8,15}

Table 2 - Results of dependent *t* test and the Dahlberg's¹² formula, applied to the studied variables, to estimate systematic and casual errors, respectively.

Variables	1st. Measurement n = 20		2nd. Measurement n = 20		Dahlberg	p
	Mean	SD	Mean	SD		
Maxillary Component						
SNA (degrees)	81.26	3.12	81.98	3.74	1.26	0.512
Co-A (mm)	91.92	4.93	92.15	5.51	0.98	0.890
Mandibular Component						
SNB (degrees)	77.65	2.96	78.25	3.37	1.57	0.553
Co-Gn (mm)	116.68	6.45	117.94	6.00	0.86	0.526
Maxillomandibular Relationship						
ANB (degrees)	3.97	1.29	3.22	1.01	1.79	0.047*
Wits (mm)	-0.53	1.62	-0.14	1.95	0.52	0.495
Vertical Component						
FMA (degrees)	25.53	3.08	26.72	3.85	1.38	0.287
AFAI (mm)	68.77	4.03	67.61	4.38	0.73	0.388
Maxillary Dental Component						
1.NA (degrees)	25.43	4.87	24.31	4.60	1.06	0.459
1.SN (degrees)	104.69	4.01	106.18	3.58	1.29	0.222
1-NA (mm)	6.34	1.82	6.68	2.09	0.84	0.586
1-PP (mm)	29.01	1.85	29.91	1.24	0.77	0.078
1-PTV (mm)	59.97	2.75	60.31	2.70	1.10	0.695
4.SN (degrees)	75.65	2.51	76.08	3.13	1.68	0.634
4-PP (mm)	23.44	1.00	22.61	1.70	0.92	0.067
4-PTV (mm)	40.37	2.35	41.95	1.77	1.25	0.021*
6.SN (degrees)	69.65	3.34	70.63	3.65	1.20	0.381
6-PP (mm)	20.68	1.87	19.55	1.81	1.01	0.059
6-PTV (mm)	24.44	1.46	23.81	1.10	0.96	0.131
Mandibular Dental Component						
1.NB (degrees)	29.22	4.61	31.67	3.03	1.34	0.054
IMPA (degrees)	96.75	3.70	97.02	3.90	1.62	0.823
1-NB (mm)	7.10	1.35	6.75	1.14	0.86	0.381
1-GoMe (mm)	41.27	1.29	40.33	1.64	0.79	0.051
1-PTV (mm)	56.36	2.73	57.93	2.50	0.63	0.065
6-GoMe (mm)	30.24	1.53	29.36	1.60	0.89	0.083
6-PTV (mm)	24.78	2.11	25.39	1.58	0.99	0.307
Dental Relationships						
Molar Relationship (mm)	-0.39	0.85	0.10	0.97	0.27	0.097
Overjet (mm)	3.41	1.27	4.13	1.15	0.87	0.067
Overbite (mm)	2.56	1.44	3.05	1.69	0.45	0.329

* Statistically significant for $p < 0.05$.

Among the 29 variables evaluated, only two systematic errors were noted for the following variables: ANB, 4-PTV (Table 2). For the casual errors, values lower than 1 mm for linear variables and values lower than 1.5° for the angular variables are considered acceptable. The greater casual errors found were 1.79° for the ANB and 1.25 mm for the measure 4-PVT.

Thus, it can be concluded that the results of the method error demonstrated adequate reproducibility of cephalograms assessed by the examiner, since the accuracy of the measurements used in this study presented within acceptable parameters, not compromising the results and conclusions of this present study.

Table 3 - Results of the intragroup comparison of the cephalometric changes between the initial and final treatment stages (dependent t test) (n = 31).

Variables	Initial stage (T ₁)		Final stage (T ₂)		p
	Mean	SD	Mean	SD	
Maxillary component					
SNA (degrees)	82.66	3.43	81.50	3.29	0.089
Co-A (mm)	91.72	5.48	92.91	6.63	0.222
Mandibular component					
SNB (degrees)	77.89	3.22	77.53	2.84	0.321
Co-Gn (mm)	115.44	7.23	119.40	8.38	0.025*
Maxillomandibular relationship					
ANB (degrees)	4.76	2.33	3.06	2.21	0.002*
Wits (mm)	0.22	2.75	-0.89	2.99	0.066
Vertical component					
FMA (degrees)	26.54	5.15	26.34	5.29	0.440
AFAI (mm)	67.51	6.06	70.40	7.41	0.049*
Maxillary dental component					
1.NA (degrees)	21.77	7.03	23.17	6.05	0.202
1.SN (degrees)	104.43	6.87	104.67	5.28	0.439
1-NA (mm)	5.69	2.01	6.09	1.51	0.189
1-PP (mm)	29.34	2.82	30.31	3.60	0.121
1-PTV (mm)	60.01	3.85	61.13	4.04	0.134
4.SN (degrees)	76.97	4.75	74.54	6.22	0.044*
4-PP (mm)	22.65	2.51	23.65	2.66	0.066
4-PTV (mm)	41.44	3.00	41.81	3.48	0.327
6.SN (degrees)	66.37	5.35	69.30	4.88	0.014*
6-PP (mm)	19.65	2.34	20.67	2.35	0.046*
6-PTV (mm)	24.68	2.87	24.77	3.08	0.452
Mandibular dental component					
1.NB (degrees)	29.44	6.46	34.19	5.85	0.001*
IMPA (degrees)	95.22	6.61	99.93	5.69	0.001*
1-NB (mm)	6.75	2.70	8.22	2.73	0.018*
1-GoMe (mm)	41.10	3.35	42.04	4.19	0.166
1-PTV (mm)	56.27	4.29	58.32	5.00	0.044*
6-GoMe (mm)	29.36	2.73	31.78	3.33	0.001*
6-PTV (mm)	25.24	3.53	27.15	4.48	0.033*
Dental relationships					
Molar relationship (mm)	0.78	1.11	-2.86	1.12	0.000*
Overjet (mm)	5.21	2.07	2.53	0.68	0.000*
Overbite (mm)	3.68	1.53	1.97	0.72	0.000*

* Statistically significant for p < 0.05.

Changes with treatment

Intragroup comparison of cephalometric changes between the initial and final treatment stages are shown in Table 3.

There was a slight restriction, but not significant, of the anterior development of the maxilla (SNA, Table 3), probably due to the use of headgear only 8 hours a day. The redirection of maxillary growth, with anterior growth restriction in young patients who used extraoral headgear is widely reported in the literature.^{9,14,17,32}

There was a significant increase in the effective length of the mandible (Co-Gn, Table 3). This probably occurred because patients still were at the final growth phase.^{24,25}

There was an improvement in the anteroposterior discrepancy of the apical bases (ANB, Table 3). This improvement was already expected, since there was a slight restriction of the anterior development of the maxilla and a significant increase of the effective length of the mandible. In addition, this improvement is reported in cases treated with extraoral headgear and Class II elastics.^{16,25,27}

A significant increase can be observed in lower anterior facial height (LAFH) with treatment, probably due to the extrusion of the maxillary first molars that occurred with the use of the extraoral headgear (Table 3). The extrusion and increase of the LAFH has been previously reported in the literature using this mechanics for correction of the Class II malocclusion.^{6,7,9,18,37}

There was no significant change in the position of the maxillary incisors with treatment (Table 3). The maxillary first premolars showed a significant distal tipping of the crown, and the maxillary molars showed a significant distal tipping of the root and extrusion, with treatment (Table 3).

The maxillary first molar did not experience a significant distalization, as reported by some authors.^{6,37} This must have been due to the minor use of the headgear and also due to the lack of restriction of the maxillary displacement observed in this study.

The mandibular incisors were significantly buccally tipped and protruded with treatment (Table 3). This effect was caused by the use of Class II intermaxillary elastics, and probably due to the initial crowding exhibited by patients.

The mandibular molars presented significant extrusion and mesial movement during treatment (Table 3). This result agrees with some reports in the literature,^{5,13,30} showing mesial movement of mandibular molars and buccal inclination of mandibular incisors. Papaioannou-Maragou and Papaioannou³² also observed the same effect in the mandibular incisors using Class II elastics without headgear, agreeing with Ellen, Schneider and Sellke¹³ who observed a buccal inclination of the mandibular incisors, extrusion and mesial movement of the mandibular molars. Nelson, Hansen and Hägg³⁰ also observed mesial movement of the mandibular molars.

The Class II molar relationship was corrected satisfactorily and significantly during treatment (Table 3). As the molar remained stable, with no distalization, the correction of the molar relationship was probably due to the mesial movement of the mandibular molar. The overjet and overbite showed significant decrease with treatment, demonstrating that they were corrected with treatment. This improvement in the horizontal direction is mainly due to buccal inclination and protrusion of the mandibular incisors, correcting the overjet, and the overbite correction is probably due to the extrusion of the maxillary and mandibular molars.

Clinical considerations

The correction of the Class II molar relationship evidenced by the protocol of the 10-Hour Force Theory associated with the use of fixed appliances, showed that the treatment time was as planned because there was no need for further retraction of anterior teeth, since there was no anchorage loss.

There are no references in the literature of this type of protocol, so there is no possibility of comparison. There are other studies comparing the extraoral headgear to other intraoral device using intermaxillary elastics.^{5,32}

The results of this unpublished research showed that the protocol for molar distalization with the use of the 10-Hour Force Theory provided satisfactory results for the correction of the Class II molar relationship, and although it requires patient cooperation, it has the advantage of requiring only intraoral devices for most of the time. The fact of also avoiding premolar extractions, often impairing the

patient's profile, is a good reason for cooperating with the use of elastics for a few months.

The protocol using the T10 resource, did not provide orthopedic effects, but resulted in satisfactory dental effects such as the satisfactory molar relationship and adequate incisal guidance. Although it requires patient cooperation for the use of the headgear at night and exchange of intermaxillary elastics, since it is an easy resource to understand and esthetically pleasing to the patient, it is possible to obtain a successful treatment.

These results are evidence that the 10-Hour Force Theory would be an option for the treatment of the Class II molar correction. Since Orthodontics is based on scientific evidence, more researches are needed to truly prove the validity of this theory, as the comparison of theory with the use of conventional Class II elastics applied on the mandibular molars for 24 hours or the use of extraoral headgear with continuous use of Class II elastics; in addition,

it can be emphasized the importance of studies evaluating the stability of the results obtained through the use of the 10-Hour Force Theory for molar distalization.

CONCLUSIONS

According to the sample and the method used, it can be concluded that the Class II cases treated with the Ten-Hour Force Theory showed a slight restriction of anterior maxillary displacement, an increase of the effective length of the mandible, a significant improvement in the maxillomandibular relationship, a significant increase in lower anterior facial height, distal tipping of the crown of the maxillary premolars, extrusion and distal tipping of the roots of the maxillary molars, significant buccal inclination and protrusion of the mandibular incisors, significant extrusion and mesial movement of the mandibular molars, besides the significant correction of the molar relationship, overjet and overbite.

REFERENCES

1. Andrews LF. The six keys to normal occlusion. *Am J Orthod.* 1972;62(3):296-309.
2. Andrews LF. *Straight Wire: o conceito e o aparelho.* 2ª ed. Curitiba: Interativas; 1997.
3. Andrews LF. *The ten-hour force theory.* San Diego: [S.l.]; 1975.
4. Andrews LF. *The ten-hour force theory.* 5th ed. 1996.
5. Angeli F. Comparação dos efeitos cefalométricos promovidos pelos aparelhos extrabucal cervical e Pendulum [tese]. Bauri (SP): Universidade de São Paulo; 2005.
6. Baumrind S, Molthen R, West EE, Miller DM. Distal displacement of the maxilla and the upper first molar. *Am J Orthod.* 1979;75(6):630-40.
7. Blueher WA. Cephalometric analysis of treatment with cervical anchorage. *Angle Orthod.* 1959;29(1):45-53.
8. Brickman CD, Sinha PK, Nanda RS. Evaluation of the Jones Jig appliance for distal molar movement. *Am J Orthod Dentofacial Orthop.* 2000;118(5):526-34.
9. Cangialosi TJ, Meistrell ME Jr, Leung MA, Ko JY. A cephalometric appraisal of edgewise Class II nonextraction treatment with extraoral force. *Am J Orthod Dentofacial Orthop.* 1988;93(4):315-24.
10. Carano A, Testa M. The distal jet for upper molar distalization. *J Clin Orthod.* 1996;30(7):374-80.
11. Cuoghi OA. Avaliação dos primeiros momentos da movimentação dentária induzida: estudo microscópico em macacos da espécie *Cebus apella* [tese]. Bauri (SP): Universidade de São Paulo; 1996.
12. Dahlberg G. *Statistical methods for medical and biological students.* New York: Interscience; 1940.
13. Ellen EK, Schneider BJ, Sellke T. A comparative study of anchorage in bioprogressive versus standard edgewise treatment in Class II correction with intermaxillary elastic force. *Am J Orthod Dentofacial Orthop.* 1998;114(4):430-6.
14. Gandini MRS, Gandini LG Jr, Martins JCR, Del Santo M Jr. Effects of cervical headgear and edgewise appliances on growing patients. *Am J Orthod Dentofacial Orthop.* 2001;119(5):531-8; discussion 538-9.
15. Ghosh J, Nanda RS. Evaluation of an intraoral maxillary molar distalization technique. *Am J Orthod Dentofacial Orthop.* 1996;110(6):639-46.
16. Gianelly AA, Valentini V. The role of "orthopedics" and orthodontics in the treatment of Class II, division 1 malocclusions. *Am J Orthod.* 1976;69(6):668-78.
17. Henriques JFC. Estudo cefalométrico comparativo de três tipos de ancoragem extrabucal sobre as estruturas dentoqueléticas, em pacientes com Classe II, 1ª divisão [tese]. Bauri (SP): Universidade de São Paulo; 1993.
18. Henriques JFC, Martins DC, Pinzan, A. Estudo cefalométrico da ação da ancoragem extrabucal cervical, na dentadura mista, sobre a maxila, mandíbula e dentes, em pacientes com Classe II, divisão 1. *Ortodontia.* 1979;12(2):76-86.
19. Hilgers J. The Pendulum appliance for Class II non-compliance therapy. *J Clin Orthod.* 1992;26(11):706-14.
20. Houston WJB. The analysis of errors in orthodontic measurements. *Am J Orthod.* 1983;83(5):382-90.
21. Itoh T, Tokuda T, Kiyosue S, Hirose T, Matsumoto M, Chaconas SJ. Molar distalization with repelling magnets. *J Clin Orthod.* 1991;25(10):611-7.
22. Janson GRP, Martins DR, Henriques JFC, Freitas MR, Pinzan A, Almeida RR. Oclusão funcional e ajuste oclusal. In: Viazis SD. *Atlas de Ortodontia avançado.* São Paulo: Ed. Santos; 1999. p. 203-14.
23. Jones RD, White JM. Rapid Class II molar correction with an open-coil jig. *J Clin Orthod.* 1992;26(10):661-4.
24. Keeling SD, Wheeler TT, King GJ, Garvan CW, Cohen DA, Cabassa S, et al. Anteroposterior skeletal and dental changes after early Class II treatment with bionators and headgear. *Am J Orthod Dentofacial Orthop.* 1998;113(1):40-50.
25. Kim KR, Muhl ZF. Changes in mandibular growth direction during and after cervical headgear treatment. *Am J Orthod Dentofacial Orthop.* 2001;119(5):522-30.
26. Kloehn SJ. Guiding alveolar growth and eruption of teeth to reduce treatment time and produce a more balanced denture and face. *Angle Orthod.* 1947;17(1-2):10-33.
27. Lima Filho R, Lima AL, Ruellas ACO. Estudo longitudinal das alterações no ângulo ANB em pacientes Classe II esquelética, tratados com aparelho extra-oral de Kloehn. *Rev Dental Press Ortod Ortop Facial.* 2003;8(2):21-9.
28. Locatelli R, Bednar J, Dietz VS, Gianelly AA. Molar distalization with superelastic NiTi wire. *J Clin Orthod.* 1992;26(5):277-9.
29. Muse DS, Fillman MJ, Emmerson WJ, Mitchell RD. Molar and incisor changes with Wilson rapid molar distalization. *Am J Orthod Dentofacial Orthop.* 1993;104(6):556-65.
30. Nelson B, Hansen K, Hägg U. Class II correction in patients treated with Class II elastics and with fixed functional appliances: a comparative study. *Am J Orthod Dentofacial Orthop.* 2000;118(2):142-9.
31. Ngantung V, Nanda RS, Bowman SJ. Posttreatment evaluation of the distal jet appliance. *Am J Orthod Dentofacial Orthop.* 2001;120(2):178-85.
32. Papaioannou-Maragou O, Papaioannou A. Comparison of treatment results with the edgewise and the Begg approach. *J Clin Pediatr Dent.* 1994;19(1):27-30.
33. Roth RH. Functional occlusion for the orthodontist. Part I. *J Clin Orthod.* 1981;15(1):32-51.
34. Roth RH. Functional occlusion for the orthodontist. Part III. *J Clin Orthod.* 1981;15(3):174-98.
35. Silva E, Gasque CA, Vieira AM. Erty system: um novo conceito na distalização de molares. *Rev Clin Ortod Dental Press.* 2003;2(3):45-60.
36. Silva Filho OG, Freitas SF, Cavassan AO. Prevalência de oclusão normal e má oclusão em escolares da cidade de Bauri (São Paulo). Parte I: relação sagital. *Rev Odontol Univ São Paulo.* 1990;4(2):130-7.
37. Wieslander L. The effect of force on craniofacial development. *Am J Orthod.* 1974;65(5):531-8.