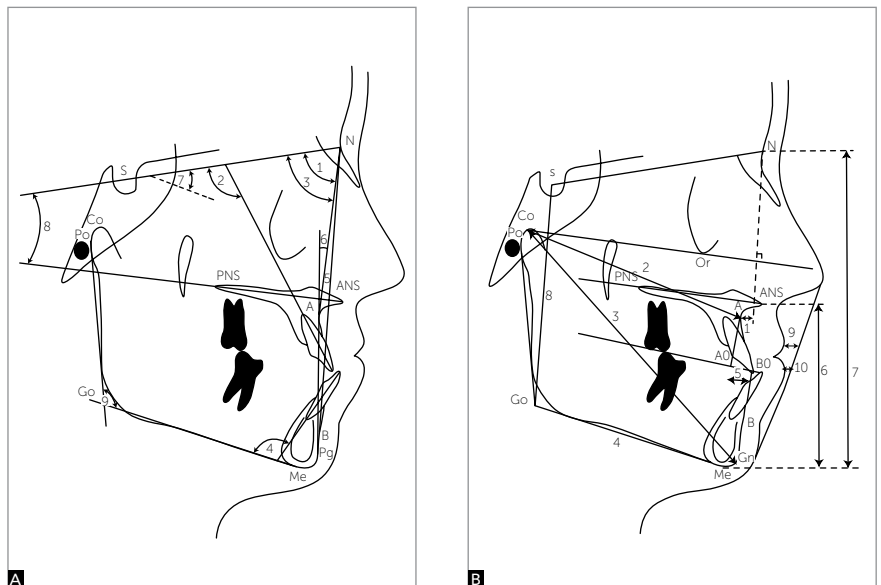


Matheus Melo Pithon\*

### PROTRACTION OF THE MAXILLA MAY BE ACHIEVED WITH FACE MASK WITHOUT PREVIOUS PALATAL EXPANSION

Class III malocclusion treatment is a daunting challenge for Orthodontics. In growing patients, the treatment procedure chosen for this malocclusion is maxillary expansion followed by reverse traction performed by means of a face mask. According to the literature, the ideal age range for patients undergoing this type of treatment is between 7 and 8 years old. At this age, it is possible to achieve better orthopedic results in comparison to dental effects. Nevertheless, patient's age may vary. Therefore, what is the ideal treatment approach for adult patients? Would it include maxillary expansion and protraction,

as in younger patients, or protraction with face mask, only? According to Halicioglu et al,<sup>1</sup> no study has been conducted to assess these treatment methods having adult patients as target. Thus, the authors conducted a study in which they assess the effects of protraction of the maxilla (alone and associated with palatal expansion) on treatment of young adults with maxillary retrognathism (Fig 1). Their results reveal that palatal expansion before maxillary protraction by means of a face mask does not enhance the effects of the former in young adult patients. Such outcomes are important, since they suggest that the use of face mask could start earlier without the need for previous maxillary expansion, thus taking advantage of the last months of maxillomandibular growth.



**Figure 1** - Measurements used: **A)** angular and **B)** linear. (Source: Halicioglu et al,<sup>1</sup> 2014)

**Submitted:** March 3, 2014 - **Revised and accepted:** April 10, 2014

\* Professor, Department of Orthodontics, State University of Southwest Bahia (UESB).

**How to cite this article:** Pithon MM. Orthodontics highlights. Dental Press J Orthod. 2014 May-June;19(3):17-9.

**Contact address:** Matheus Melo Pithon  
Av. Otávio Santos, 395 - Sala 705 - Vitória da Conquista/BA -  
CEP: 45020-750 - Brazil  
E-mail: matheuspithon@gmail.com

## CONVENTIONAL AND SELF-LIGATING BRACKETS HAVE SIMILAR TOOTH MOVEMENT, ANCHORAGE LOSS AND TOOTH TIPPING RATES

Undoubtedly, the issue of self-ligating brackets is what currently arouses the interest of most orthodontists. These devices have several benefits, namely: better orthodontic movement, decreased chair time and stronger possibility of greater intervals between appointments. Although these advantages are widely known, further scientific evidence is required to support theory. In the attempt to answer these questions, Brazilian researchers conducted a clinical trial<sup>2</sup> with Class I malocclusion patients in need for tooth extraction. Their aim was to assess the following rates: tooth movement, molar anchorage loss, and canine as well as molar tipping during canine retraction. Their results revealed that no differences are found regarding canine movement, molar anchorage loss and canine as well as molar tipping in comparing both types of brackets. It is worth noting that further studies are warranted to assess the other benefits offered by the aforementioned devices.

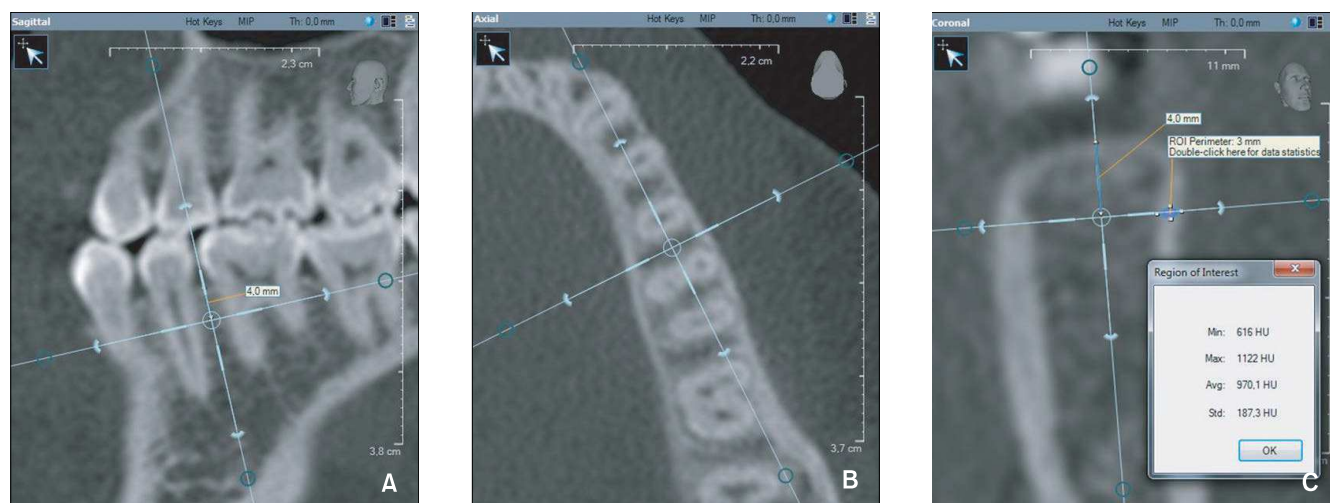
## PREMATURITY AND LOW BIRTH WEIGHT DO NOT AFFECT POTENTIAL MALOCCLUSIONS

It is widely known that several etiological factors contribute to develop and worsen malocclusion.

For this reason, Orthodontics is a unique specialty that deals with cases that seem similar, but in fact are caused by completely different etiological factors. Many studies have to be conducted to understand the occlusal characteristics associated with certain etiological factors. Prematurity and low birth weight are associated with several changes in physical development, including the orofacial structures. In this context, what are the functional and morphological characteristics of malocclusion in patients with deciduous dentition? In the attempt to answer this question, Slovene researchers<sup>3</sup> conducted a study to clinically assess premature, underweight children by means of questionnaires answered by the children's guardians. Their results revealed that the prevalence of malocclusion among premature children was not significantly different from the control group (children born from the 37<sup>th</sup> week of pregnancy on). The authors also found that premature birth is not considered an indication of risk of any functional or morphological characteristic of malocclusion.

## VERTICAL PATIENTS HAVE THINNER CORTICAL BONE

Since their beginning, in the mid-90s, mini-implants have been constantly renewed. Initially, they required previous perforation. However, as time went by, mini-implants became self-drilling and, nowadays, have different



**Figure 2** - Measuring cortical bone density. **A**) In sagittal view, the vertical reference line cuts the interdental area and is parallel to root long axis. **B**) In axial view the vertical reference cuts the interdental area. **C**) In coronal view, the cortical bone density is measured (in Hounsfield units or HU) between the points (one on the outer surface and the other on the border of the cortical-cancellous bone) on a line perpendicular to the bone surface and 4 mm apically to the alveolar crest. (Source: Ozdemir et al,<sup>4</sup> 2014).

types of threads. All the modifications mini-implants went through happened for one reason: To increase stability and provide greater practicality during placement. Nevertheless, it is known that implant stability is associated with different factors, among which alveolar bone density is one of the most important. In this context, how can we measure an individual's alveolar bone density without using tomography? Is it possible to estimate it based on the individual's facial type? With a view to establishing an association between facial type and bone density, Turkish authors<sup>4</sup> assessed the tomographic images (Fig 2) of patients with good growth vector, whether horizontal or vertical. Their results revealed that vertical patients tend to have lower bone density in comparison to other patients. They also found that women tend to have thicker palatal cortical bone in the alveolar process in comparison to men.

### TOOTH GEL WITH *MELALEUCA ALTERNIFOLIA* PROVES EFFECTIVE IN CONTROLLING CARIOUS BIOFILM IN ORTHODONTIC PATIENTS

Controlling carious biofilm in orthodontic patients is one of the most challenging tasks orthodontists have to face daily. Which orthodontist never bothered seeing white lesions when debonding brackets? Every day, new products are launched on the market with a view to

reducing the amount of carious microorganisms and, as a consequence, the amount of white lesions. Different substances have been added to dental pastes, mouthwashes and dental varnish with a view to reducing carious biofilm. Several medicinal plants with antimicrobial active ingredients have been added, among which *Melaleuca alternifolia* is the most frequent. In this context, the following question arises: Is the active ingredient of *Melaleuca alternifolia* effective in reducing carious biofilm in orthodontic patients? In the attempt to answer this question, Brazilian researchers conducted a clinical study<sup>5</sup> to compare tooth gel with *Melaleuca* with conventional tooth gel (Colgate Total®). In addition to assessing the microbiological activity of both gels, the participants were invited to conduct a sensorial analysis of the products (aspect, color, smell, brightness, viscosity and first taste sensation). They yielded satisfactory results, given that tooth gel with *Melaleuca* proved more efficient in controlling carious biofilm than conventional gel. Nevertheless, conventional tooth gel had better taste.

### REFERENCES

1. Halicioğlu K, Yavuz I, Ceylan I, Erdem A. Effects of face mask treatment with and without rapid maxillary expansion in young adult subjects. *Angle Orthod*. 2014 Mar 14. [Epub ahead of print].
2. da Costa Monini A, Júnior LG, Martins RP, Vianna AP. Canine retraction and anchorage loss Self-ligating versus conventional brackets in a randomized split-mouth study. *Angle Orthod*. 2014 Mar 4. [Epub ahead of print].
3. Primožič J, Farcnik F, Ovsenik M, Primožič J. A controlled study of the functional and morphological characteristics of malocclusion in prematurely born subjects with low birth weight. *Eur J Orthod*. 2014 Feb;36(1):114-20. doi: 10.1093/ejo/cjt016. Epub 2013 Apr 8.
4. Özdemir F, Tozlu M, Germec Cakan D. Quantitative evaluation of alveolar cortical bone density in adults with different vertical facial types using cone-beam computed tomography. *Korean J Orthod*. 2014 Jan;44(1):36-43. doi: 10.4041/kjod.2014.44.1.36. Epub 2014 Jan 17.
5. Santamaria M Jr, Petermann KD, Vedovello SA, Degan V, Lucato A, Franzini CM. Antimicrobial effect of *Melaleuca alternifolia* dental gel in orthodontic patients. *Am J Orthod Dentofacial Orthop*. 2014 Feb;145(2):198-202. doi: 10.1016/j.ajodo.2013.10.015.