

Periodontal and dental effects of surgically assisted rapid maxillary expansion, assessed by using digital study models

Danilo Furquim Siqueira¹, Mauricio de Almeida Cardoso², Leopoldino Capellozza Filho², Dov Charles Goldenberg³, Mariana dos Santos Fernandes⁴

DOI: <http://dx.doi.org/10.1590/2176-9451.20.3.058-063.oar>

Objective: The present study assessed the maxillary dental arch changes produced by surgically assisted rapid maxillary expansion (SARME).

Methods: Dental casts from 18 patients (mean age of 23.3 years) were obtained at treatment onset (T_1), three months after SARME (T_2) and 6 months after expansion (T_3). The casts were scanned in a 3D scanner (D-250, 3Shape, Copenhagen, Denmark). Maxillary dental arch width, dental crown tipping and height were measured and assessed by ANOVA and Tukey's test.

Results: Increased transversal widths from T_1 and T_2 and the maintenance of these values from T_2 and T_3 were observed. Buccal teeth tipping also showed statistically significant differences, with an increase in all teeth from T_1 to T_2 and a decrease from T_2 to T_3 . No statistically significant difference was found for dental crown height, except for left first and second molars, although clinically irrelevant.

Conclusion: SARME proved to be an effective and stable procedure, with minimum periodontal hazards.

Keywords: Orthodontics. Periodontics. Palatal expansion technique. Dental casts.

¹Coordinator of the Postgraduate course in Orthodontics, Sociedade Paulista de Ortodontia, Botucatu, São Paulo, Brazil.

²Professor of Orthodontics, Universidade Sagrado Coração (USC), Bauru, São Paulo, Brazil.

³Full professor, Universidade de São Paulo (USP), School of Medicine, Department of Surgery, São Paulo, São Paulo, Brazil.

⁴MSc in Orthodontics, Universidade Metodista de São Paulo (UMESP), São Bernardo do Campo, São Paulo, Brazil.

How to cite this article: Siqueira DF, Cardoso MA, Capellozza Filho L, Goldenberg DC, Fernandes MS. Periodontal and dental effects of surgically assisted rapid maxillary expansion, assessed by using digital study models. *Dental Press J Orthod.* 2015 May-June;20(3):58-63.

DOI: <http://dx.doi.org/10.1590/2176-9451.20.3.058-063.oar>

Submitted: March 20, 2014 - **Revised and accepted:** November 25, 2014

» The authors report no commercial, proprietary or financial interest in the products or companies described in this article.

Contact address: Danilo Furquim Siqueira
Rua Moyses Leme da Silva, 8-38, Jd América, Bauru, SP, Brazil
E-mail: danilofurquim@uol.com.br

INTRODUCTION

Proper maxillary transverse dimension is a key component of optimal, stable occlusion. Rapid maxillary expansion (RME) is a procedure commonly employed by orthodontists treating transverse issues.¹⁻⁵ Despite being successful in children and adolescents, this procedure fails when performed in patients in the final growth phase and in adults.^{1,2,6,7,8}

After growth ends, the amount of force required to split the midpalatal suture is relatively high due to increases both in the complexity of this suture and in the rigidity of adjacent facial structures. Thus, enlarging the maxillary complex by nonsurgical expansion in adults can cause side effects, such as higher relapse rates, tipping of support teeth, severe pain and gingival recession,^{1,2,6,9} since the forces delivered during expansion may produce buccal tipping of teeth, thereby generating areas of compression in the periodontal ligament of support teeth.^{10,11} In these cases, midpalatal suture splitting must be combined with a surgical procedure known as surgically assisted rapid maxillary expansion (SARME) which breaks down sutural resistance and enables maxillary expansion without the aforementioned side effects.^{1,3,4,6,9,12,13}

The benefits of treating transverse maxillary deficiency include improvements in dental and skeletal stability, decreased need for extractions to perform alignment and leveling, increased teeth visibility at smiling, and, occasionally, improvements in nasal breathing.^{5,12,14,15}

There are numerous ways to assess changes resulting from SARME, but in the last two decades, thanks to remarkable technological advances in Dentistry, cutting edge analysis tools have emerged. In Orthodontics, these advances have primarily occurred in diagnostic elements, such as the use of photography and digital radiography. The use of digital dental casts was introduced by the orthodontic industry as a component of the new, now fully digitized and highly accurate orthodontic records.^{7,16-23} Thus, this study aims at analyzing, with the aid of digital models, the major changes produced in the transverse dimension and tipping of maxillary teeth, as well as the potential impact of this procedure on adult patients undergoing SARME.

MATERIAL AND METHODS

This project was submitted to Universidade Metodista de São Paulo Institutional Review Board, and approved under protocol number 142.170/07.

This is a retrospective study of which sample comprised 54 maxillary dental casts obtained from 18 adult patients with maxillary atresia, 6 men and 12 women, with a mean age of 23.3 years (minimum of 18 and maximum of 35 years old) from the Postgraduate Clinic of Universidade Metodista de São Paulo. All subjects underwent SARME.

To perform the expansion procedure, a 13-mm Hyrax expansion screw was used.²⁴ Moreover, a conservative surgical technique consisting of LeFort I osteotomy was employed to approach the midpalatal suture without involving the pterygopalatine suture.²⁵ All surgeries were conducted by the same surgeon.

The expansion screw was first activated on the third day after surgery, and patients were instructed to make two daily activations, one in the morning (1/4 turn) and one at night (1/4 turn), until the screw was fully opened, or until it reached the desired overcorrection (palatal cusp of the maxillary first molar edge-to-edge with the buccal cusp of the mandibular first molar).

The appliance (Hyrax) remained in the oral cavity for three months, functioning as a retainer. After this period, the expander was removed and an acrylic plate (with retention clips between premolars) was inserted and remained in place for three months until a fixed orthodontic appliance was placed.

For variables assessment, dental casts were scanned with a 3D scanner (D-250, 3Shape, Copenhagen, Denmark). Only the maxillary models during phases T₁ (initial), T₂ (three months post-expansion) and T₃ (six months post-expansion) were used.

Linear measurements were taken by means of Geomagic Studio 5™ (Research Triangle Park, USA), a software that allows viewing and manipulating digital representations on a computer screen. Transverse changes resulting from SARME were assessed by means of intercanine, interpremolar and intermolar widths (Fig 1), using the points described by Currier²⁶ and Berger et al²⁷ as reference.

The height of the clinical crown of canines, premolars and molars was measured based on the distance between the buccal cusp and the most apical point of the gingival margin,^{5,9} as shown in Figure 2.

Angular measurements were taken with the aid of OrthoDesigner™ software (3Shape, Copenhagen, Denmark) which also features tools to assist in obtaining angular measurements and slicing dental casts.

Intercanine, interpremolar and intermolar tipping was calculated using the following references⁵: Line a= distance between the left and right midpoints of the deepest region of buccal and palatal surfaces in the gingival margin; Line b= distance between the geometric midpoint on the right side of the center of buccal and palatal cusps, and the midpoint of the deepest region in the gingival margin; Line c= distance from the left side of the geometric midpoint at the center of buccal and palatal cusps, and the midpoints of the deepest buccal and palatal portions of the gingival margin. With these reference lines, the internal angles formed by lines a-b and a-c were calculated with the aid of the software. After this definition, the bilateral angulation of posterior teeth was calculated (Fig 3).

To this end, it was necessary to create a clipping plane in the models (Fig 4) to allow teeth to be viewed mesially. The reference plane met the aforementioned criteria.

In selecting the clipping plane, the tool “enable clipping plane” was used. This allowed the mesial viewing of the models, as it excluded their anterior portion (Fig 5). The changes in each parameter occurring during treatment were calculated in the models at the times described before.

Statistical analysis

To determine the error of the method, 30% of the sample was randomly selected and measured after at least one week, using the same material and applying the same aforementioned criteria. Paired t-test was used to determine intraexaminer systematic error. Random error was calculated by Dahlberg’s formula.²⁸

In order to compare the three assessment periods, analysis of variance (ANOVA) was used with a criterion

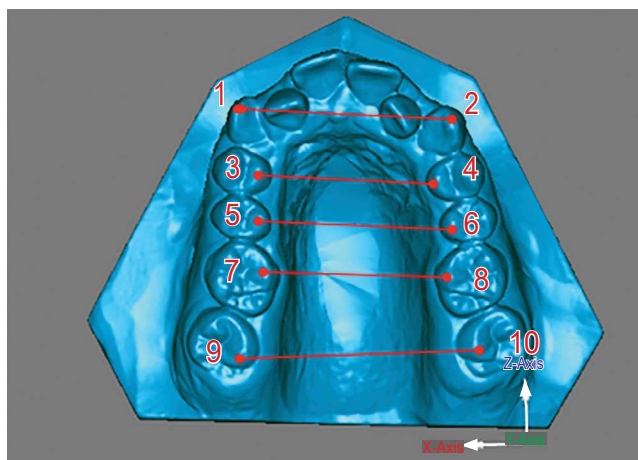


Figure 1 - Points and transverse widths in the digital models: **1**) Cusp tip of right canine; **2**) Cusp tip of left canine; **3**) Palatal cusp tip of right maxillary first premolar; **4**) Palatal cusp tip of left maxillary first premolar; **5**) Palatal cusp tip of right maxillary second premolar; **6**) Palatal cusp tip of left maxillary second premolar; **7**) Mesio-palatal cusp tip of right maxillary first molar; **8**) Mesio-palatal cusp tip of left maxillary first molar; **9**) Mesio-palatal cusp tip of right maxillary second molar; **10**) Mesio-palatal cusp tip of left maxillary second molar.

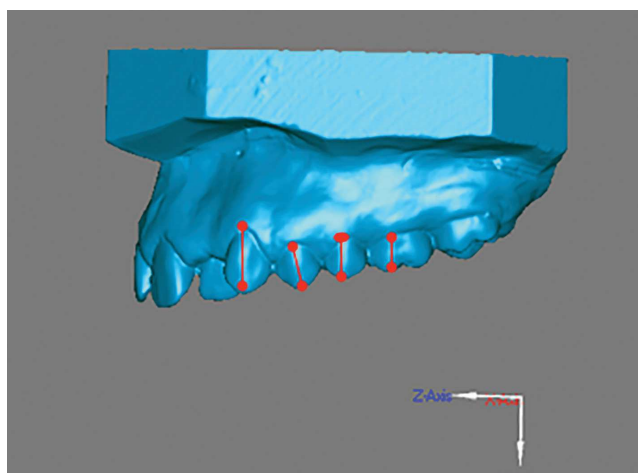


Figure 2 - Height of clinical crowns.

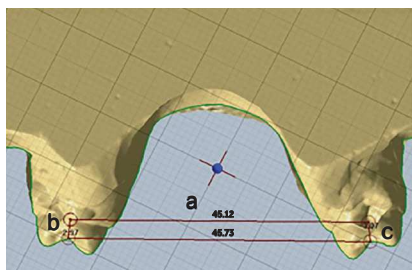


Figure 3 - Defining lines a, b and c

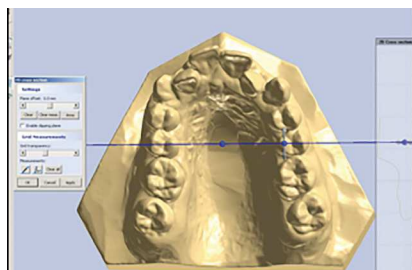


Figure 4 - Defining clipping plane.

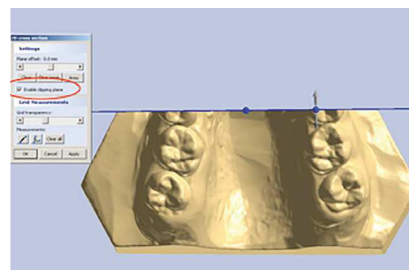


Figure 5 - Enabling clipping plane tool, shown in red.

for repeated measurements. When ANOVA revealed statistically significant difference, Tukey's test for multiple comparisons was applied. A level of significance of 5% ($p < 0.05$) was adopted for all tests.

RESULTS

From the foregoing, one can argue that the results found in this study are reliable, since, after further measurements were carried out in the dental casts of five randomly selected patients, no intraexaminer errors that might compromise this research were identified. Measurements of tooth tipping are more error-prone due to inconsistencies in (a) the location of points, (b) trimming of casts, and (c) construction of lines.

Table 1 depicts means and standard deviation values of transverse widths in the upper dental arch, expressed in millimeters, at the three evaluation periods, and results from ANOVA and Tukey's test. It shows an increase in transverse width with means of 9.26 mm for first molars, 5.4 mm for second molars, 9.8 mm for first premolars, 9.49 mm for second premolars, and 5.87 mm for canines from T_1 to T_2 . These values remained unchanged from T_2 to T_3 .

Table 2 presents the mean size of crowns in the maxillary arch, expressed in millimeters, at T_1 , T_2 and T_3 , and the results of ANOVA and Tukey's test showing differences only in left first and second molars.

Table 3 shows means and standard deviation values of maxillary teeth tipping, expressed in degrees, at T_1 , T_2 and T_3 , and the results of ANOVA and Tukey's test. All values increased, thereby pointing to buccal tipping, although significant only in some teeth.

DISCUSSION

The literature presents different methods to assess changes induced by SARME in dental casts, namely: assessment with a bow compass,²⁷ digital caliper⁴ and laser-scanned models. Laser scanning is common in industrial engineering and medicine as a noninvasive alternative to generate 3D images. The measurement method using a 3D scanner has been studied and proved reliable and convenient.^{7,18,21} It has also been proven that analyses in digital models can be performed in both clinical practice and research, with extremely accurate outcomes.^{16,17,19,20}

Digital models have the added advantage of allowing images to be sliced, providing superior viewing of points not visible in dental casts. Furthermore, they can

Table 1 - Means and standard deviation values of transverse widths in the upper dental arch, in mm, at the three assessment periods, and results of ANOVA and Tukey's test.

Tooth	T_1	T_2	T_3	P
1 st M	35.94 ± 4.43 ^a	45.20 ± 3.96 ^b	45.26 ± 4.41 ^b	< 0.001*
2 nd M	43.45 ± 4.58 ^a	48.85 ± 4.53 ^b	48.82 ± 4.72 ^b	< 0.001*
1 st PM	26.02 ± 2.56 ^a	35.82 ± 2.97 ^b	35.47 ± 2.69 ^b	< 0.001*
2 nd PM	31.28 ± 3.24 ^a	40.77 ± 3.05 ^b	40.73 ± 3.20 ^b	< 0.001*
C	30.56 ± 2.39 ^a	36.43 ± 2.41 ^b	36.14 ± 2.57 ^b	< 0.001*

*Statistically significant difference found by ANOVA ($p < 0.05$).
Periods of time with the same letter are not statistically different (Tukey's test).

Table 2 - Means and standard deviation values of crown heights in the upper dental arch, in mm, at the three assessment periods, and results of ANOVA and Tukey's test.

Tooth	T_1	T_2	T_3	P
1 st M right	7.25 ± 1.08	7.25 ± 0.84	7.23 ± 0.81	0.996 ns
2 nd M right	6.88 ± 1.00	7.19 ± 0.78	7.05 ± 0.79	0.182 ns
1 st PM right	7.66 ± 0.89	7.92 ± 0.94	8.04 ± 0.88	0.062 ns
2 nd PM right	6.88 ± 1.11	6.88 ± 1.15	6.98 ± 0.94	0.754 ns
C right	9.29 ± 1.15	9.47 ± 1.14	9.40 ± 0.98	0.492 ns
1 st M left	6.96 ± 0.74 ^a	7.17 ± 1.03 ^{ab}	7.39 ± 1.11 ^b	0.035*
2 nd M left	6.45 ± 0.78 ^a	6.89 ± 0.89 ^b	6.87 ± 0.91 ^b	0.006*
1 st PM left	7.92 ± 1.03	8.00 ± 0.79	8.03 ± 0.70	0.748 ns
2 nd PM left	6.81 ± 0.99	6.84 ± 0.93	6.84 ± 0.97	0.930 ns
C left	9.21 ± 1.00	9.35 ± 1.15	9.38 ± 0.99	0.597 ns

ns = No statistically significant difference.
*Statistically significant difference found by ANOVA ($p < 0.05$).
Periods of time with the same letter are not statistically different (Tukey's test).

Table 3 - Means and standard deviation values of tipping of teeth in the upper dental arch, in mm, at the three assessment periods, and results of ANOVA and Tukey's test.

Tooth	T_1	T_2	T_3	P
1 st M right	98.96 ± 9.47	102.76 ± 5.63	102.61 ± 4.90	0.120 ns
2 nd M right	106.98 ± 7.50 ^a	110.82 ± 8.73 ^b	109.41 ± 7.69 ^{ab}	0.041*
1 st PM right	88.18 ± 8.00 ^a	96.37 ± 8.19 ^b	95.48 ± 7.15 ^b	< 0.001*
2 nd PM right	92.20 ± 8.85 ^a	101.54 ± 8.77 ^b	100.34 ± 5.48 ^b	< 0.001*
C right	100.17 ± 8.77	99.33 ± 8.11	98.76 ± 8.95	0.644 ns
1 st M left	102.07 ± 7.10 ^a	106.40 ± 7.46 ^b	104.62 ± 5.72 ^{ab}	0.019*
2 nd M left	112.18 ± 6.28	113.70 ± 6.05	110.47 ± 6.34	0.154 ns
1 st PM left	94.24 ± 6.53	96.17 ± 7.13	96.68 ± 6.30	0.312 ns
2 nd PM left	93.33 ± 6.37 ^a	103.84 ± 5.78 ^b	101.45 ± 6.70 ^b	< 0.001*
C left	103.29 ± 7.17	104.06 ± 7.84	100.17 ± 5.13	0.084 ns

ns = No statistically significant difference.
*Statistically significant difference found by ANOVA ($p < 0.05$).
Periods of time with the same letter are not statistically different (Tukey's test).

be superimposed, which facilitates viewing of the mechanics used in a given treatment.²¹

The time spent while taking measurements in the digital models was relatively shorter, given the user-friendliness of the programs and the measuring resources available, which yield very accurate measurements.²³

Treatment including SARME proved successful for adult patients requiring maxillary expansion, a finding reported by several authors.^{2,4,6,12,13,25}

The present study disclosed an increase in transverse width in all teeth from T_1 to T_2 , with measurements remaining unchanged from T_2 to T_3 (Table 1). Thus, it is reasonable to assert that SARME demonstrated effectiveness and stability during the assessment period (6 months).

The slight increase found in intercanine width can be attributed to the fact that patients with indication for SARME often have canines in infralabioversion. As anterior space is gained, these teeth tend to align, consequently taking on a more lingual position and not showing so much increase in width.^{1,4,13,27}

In comparison to first molars, there was less increase in transverse width in second molars (5.4 mm and 9.4 mm, respectively). This difference can be probably linked to release of the pterygopalatine process due to the surgical technique employed, and also to the fact that this tooth was not included in the appliance.²⁵

In adults, both surgical and nonsurgical procedures can correct maxillary transverse deficiency and achieve stability,^{4,5,8,9} but comparison showed greater transverse increase in surgical cases.

SARME did not interfere in gingival attachment at the three assessment periods, except for first and second molars on the left side. Bassareli, Dalstra and Melsen⁵ as well as Handelman et al⁸ reported that nonsurgical maxillary expansion is effective in adults. However, these studies demonstrated greater dentoalveolar compensation due to increased tipping. Furthermore, they found no connection between the development of gingival recession and the amount of transverse expansion in adults, since there was no change in clinical crown height. In comparing the two types of treatment, i.e., SARME *versus* nonsurgical expansion, Carmen et al⁹ found that these treatment modalities result in increased transverse dimension and show no statistically significant differences in the development of gingival recession. Nevertheless, SARME proved more effective and

less harmful to the periodontium, thereby corroborating Northway and Meade,⁴ who argued that crown length displayed greater increase in nonsurgical patients.

The literature has shown that bone dehiscence can be produced in the alveolar bone when teeth are tipped buccally, but orthodontic movement would not necessarily be accompanied by loss of connective tissue.^{10,11}

It has been acknowledged that teeth positioned or moved buccally, bone dehiscence and the presence of thin and brittle keratinized mucosa are the main predisposing factors of gingival recession.^{15,29} Gingival recession, however, is only triggered by mechanical trauma caused by brushing, or inflammation induced by the presence of plaque.¹⁵ Therefore, the quality of the keratinized mucosa and tooth brushing in particular should be closely monitored in patients undergoing SARME.

The surgical procedure resulted in dentoalveolar tipping, with statistical significance (Table 3), in the second molar, first and second premolars on the right side, and first molar and second premolars on the left side from T_1 to T_2 . From T_2 to T_3 , tipping remained unchanged. In this study, crown tipping was calculated by means of the angle formed by the long axis of the tooth with a line that connects the buccal and lingual surfaces of the gingival most points. Thus, calculating tipping was less dependent on crown morphology,⁵ since other methods are influenced by changes in cusp height.^{1,4}

This difference in the amount of tipping may be related to the way in which expansive force is delivered. Second premolars experienced expansion forces through contact between the lingual connection wire and its homonymous surface. With simple force applied to the crown, away from the center of resistance, a moment of force was created in the buccal direction, ultimately yielding some tipping component. Furthermore, anchorage teeth received expansion forces by means of bands rigidly fixed to the appliance. As the screw was activated, the bands, which were wide in the cervico-occlusal direction, resisted the tendency to tip by moving the anchorage teeth predominantly through a bodily movement in buccal direction.¹⁵ This clearly shows that overcorrection was necessary due to relapse induced by the effects of tipping.^{3,4,8}

CONCLUSION

SARME proved to be an effective and stable procedure, with minimum periodontal hazards.

REFERENCES

1. Adkins MD, Nanda RS, Currier GF. Arch perimeter changes on rapid palatal expansion. *Am J Orthod Dentofacial Orthop.* 1990;97(3):194-9.
2. Atac ATA, Karasu HA, Aytac D. Surgically assisted rapid maxillary expansion compared with orthopedic rapid maxillary expansion. *Angle Orthod.* 2006;76(3):353-9.
3. Chung C, Goldman AM. Dental tipping and rotation immediately after surgically assisted rapid palatal expansion. *Eur J Orthod.* 2003;25(4):353-8.
4. Northway WM, Meade JB Jr. Surgically assisted rapid expansion: a comparison of technique, response, and stability. *Angle Orthod.* 1997;67(4):309-20.
5. Bassarelli T, Dalstra M, Melsen B. Changes in clinical crown height as a result of transverse expansion of the maxilla in adults. *Eur J Orthod.* 2005;27(2):121-8.
6. Bays R, Greco JM. Surgically assisted rapid palatal expansion: an outpatient technique with long-term stability. *J Oral Maxillofac Surg.* 1992;50(2):110-5.
7. Bell A, Ayoub F, Siebert P. Assessment of the accuracy of a three-dimensional imaging system for archiving dental study models. *J Orthod.* 2003;30(3):219-23.
8. Handelman CS, Wang L, BeGole EA, Haas AJ. Nonsurgical rapid maxillary expansion in adults: report on 47 cases using the Haas expander. *Angle Orthod.* 2000;70(2):129-44.
9. Carmem M, Marcella P, Giuseppe C, Roberto A. Periodontal evaluation in patients undergoing maxillary expansion. *J Craniofac Surg.* 2000;11(5):491-4.
10. Garib DG, Henriques JFC, Janson G, Freitas MR, Fernandes AY. Periodontal effects of rapid maxillary expansion with tooth-tissue-borne and tooth-borne expanders: a computed tomography evaluation. *Am J Orthod Dentofacial Orthop.* 2006;129(6):749-58.
11. Steiner GG, Pearson JK, Ainamo J. Changes of the marginal periodontium as a result of labial tooth movement in monkeys. *J Periodontol.* 1981;52(6):314-20.
12. Betts NJ, Vanarsdall RL, Barber HD, Higgins-Barber K, Fonseca RJ. Diagnosis and treatment of transverse maxillary deficiency. *Int J Adult Orthodon Orthognath Surg.* 1995;10(2):75-96.
13. Byloff FK, Mossaz CF. Skeletal and dental changes following surgically assisted rapid palatal expansion. *Eur J Orthod.* 2004;26(4):403-9.
14. Haas A. Long-term post treatment evaluation of rapid palatal expansion. *Angle Orthod.* 1980;50(3):189-217.
15. Garib DG, Henriques JFC, Janson G, Freitas MR, Coelho RA. Rapid maxillary expansion — tooth-tissue-borne versus tooth-borne expanders: a computed tomography evaluation of dentoskeletal effects. *Angle Orthod.* 2005;75(4):548-57.
16. DeLong R, Heinzen M, Hodges JS, Ko CC, Douglas WH. Accuracy of a system for creating 3D computer models of dental arches. *J Dent Res.* 2003;82(6):438-42.
17. Hayasaki H, Martins RP, Gandini LG Jr, Saitoh I, Nonaka K. A new way of analyzing occlusion 3 dimensionally. *Am J Orthod Dentofacial Orthop.* 2005;128(1):128-32.
18. Kusnoto B, Evans CA. Reliability of a 3D surface laser scanner for orthodontic applications. *Am J Orthod Dentofacial Orthop.* 2002;122(4):342-8.
19. Motohashi N, Kuroda T. A 3D computer-aided design system applied to diagnosis and treatment planning in orthodontics and orthognathic surgery. *Eur J Orthod.* 1999;21(3):263-74.
20. Okumura H, Chen L, Tsutsumi S, Oka M. Three-dimensional virtual imaging of facial skeleton and dental morphologic condition for treatment planning in orthognathic surgery. *Am J Orthod Dentofacial Orthop.* 1999;116(2):126-31.
21. Oliveira NL, Silveira ACd, Kusnoto B, Viana G. Three-dimensional assessment of morphologic changes of the maxilla: A comparison of 2 kinds of palatal expanders. *Am J Orthod Dentofacial Orthop.* 2004;126(3):354-62.
22. Stevens DR, Flores-Mir C, Nebbe B, Raboud DW, Heo G, Major PW. Validity, reliability, and reproducibility of plaster vs digital study models: comparison of peer assessment rating and Bolton analysis and their constituent measurements. *Am J Orthod Dentofacial Orthop.* 2006;129(6):794-803.
23. Sousa MVS, Vasconcelos EC, Janson G, Garib D, Pinzan A. Accuracy and reproducibility of 3-dimensional digital model measurements. *Am J Orthod Dentofacial Orthop* 2012;142(2):269-73.
24. Biederman W. A hygienic appliance for rapid expansion. *JPO, J Pract Orthod.* 1968;2(2):67-70.
25. Goldenberg DC, Alonso N, Goldenberg FC, Gebrin E, Amaral TS, Scanavini MA, et al. Using computed tomography to evaluate maxillary changes after surgically assisted rapid palatal expansion. *J Craniofac Surg* 2007;18(2):302-11.
26. Currier JHA. A computerized geometric analysis of human dental arch form. *Am J Orthod.* 1969;56(2):164-79.
27. Berger JL, Pangrazio-Kulbersh V, Borgula T, Kaczynski R. Stability of orthopedic and surgically assisted rapid palatal expansion over time. *Am J Orthod Dentofacial Orthop.* 1998;114(6):638-45.
28. Houston WJB. The analysis of errors in orthodontic measurements. *Am J Orthod.* 1983;83(5):382-90.
29. Joss-Vassalli, Grebenstein C, Topouzelis N, Sculean A, Katsaros C. Orthodontic therapy and gingival recession: a systematic review. *Orthod Craniofac Res.* 2010;13(3):127-41.