

Matheus Melo Pithon\*

### LOCAL INFILTRATION OF VITAMIN D3 DOES NOT ACCELERATE ORTHODONTIC TOOTH MOVEMENT IN HUMANS

Since the early days of Orthodontics as a specialty, researchers do not worry about the search for mechanisms that speed up the orthodontic treatment. There are several methods and products used for this purpose. Corticotomies, laser therapy and various drugs have been tested and some of them scientifically evidenced. As a gold standard has not been reached regarding the acceleration of orthodontic movement, the research continues. Following this trend, Indian researchers developed a study<sup>1</sup> evaluating whether vitamin D3 would accelerate orthodontic tooth movement or not. But the reader might wonder: why vitamin D3? According to the authors, the reason to test its application took place as a result of studies in animals that have shown good prospects of the substance for this purpose. Unfortunately, the results previously found in animals remained unproven when clinically used in patients. Therefore, it was concluded that vitamin D3 application does not increase the movement charge. The results of this study call attention to the need to conduct well-designed clinical studies prior to clinical use and that results found in animals do not always represent what occurs clinically in humans.

### NICOTINE INTAKE INCREASES ROOT RESORPTION WHEN ORTHODONTIC MOVEMENT OCCURS

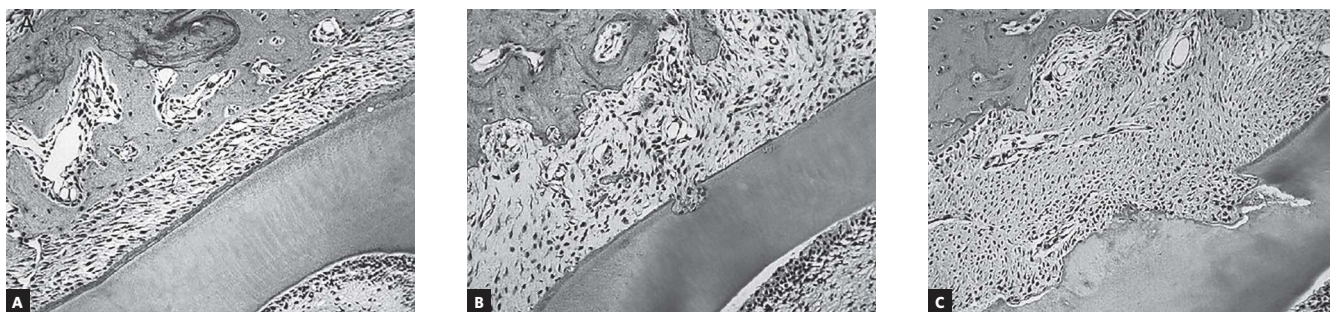Data from the World Health Organization show that there are about 1.1 billion smokers worldwide. The dangers of nicotine for the overall health of individuals are no surprise to anyone, it is estimated that about 5.4 million people worldwide will die prematurely as victims of complications of this addiction. In this perspective, a question arises: what is the effect of this harmful substance on periodontal tissues, specifically during orthodontic movement? Searching answers to this question, Chinese researchers developed this study<sup>2</sup> in which rats were used as animal models in order to assess whether nicotine associated with dental orthodontic movement would lead to a higher level of resorption. Results showed greater root resorption when teeth were moved in the presence of nicotine (Fig 1). The importance of this study's findings are worth mentioning because root resorption, if not the main, is undoubtedly an issue that most haunts orthodontists worldwide. Thus, at the beginning of treatment in a patient who smokes, it is always good to inform the increased risk, because, after all, forewarned is forearmed.

**Submitted:** July 21, 2015 - **Revised and accepted:** July 28, 2015

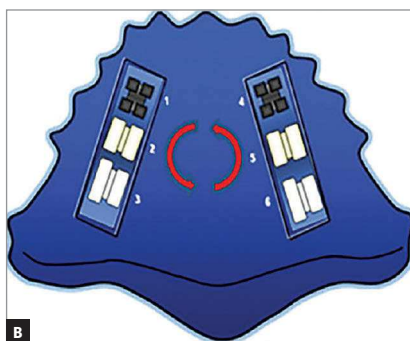
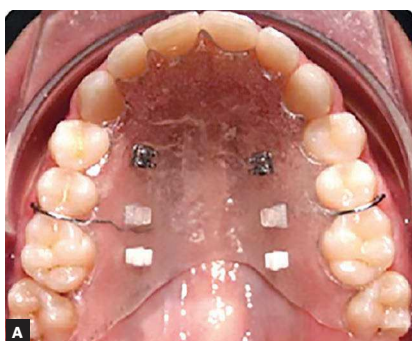
\*Professor, Universidade Estadual do Sudoeste da Bahia (UESB), Department of Orthodontics, Vitória da Conquista, Bahia, Brazil.

**Contact address:** Matheus Melo Pithon

Av. Otávio Santos, 395 – Sala 705 – Vitória da Conquista/BA – Brazil - CEP: 45020-750 - E-mail: matheuspithon@gmail.com



**Figure 1** - Histologic observation of molars on the compression side. Few resorption lacunae occurred in the (A) negative control group. More resorption lacunae and wider resorption area were observed in the (C) nicotine-treated group compared with the (B) positive control group (hematoxylin and eosin staining, magnification 200X) (Source: Li et al,<sup>2</sup> 2015).



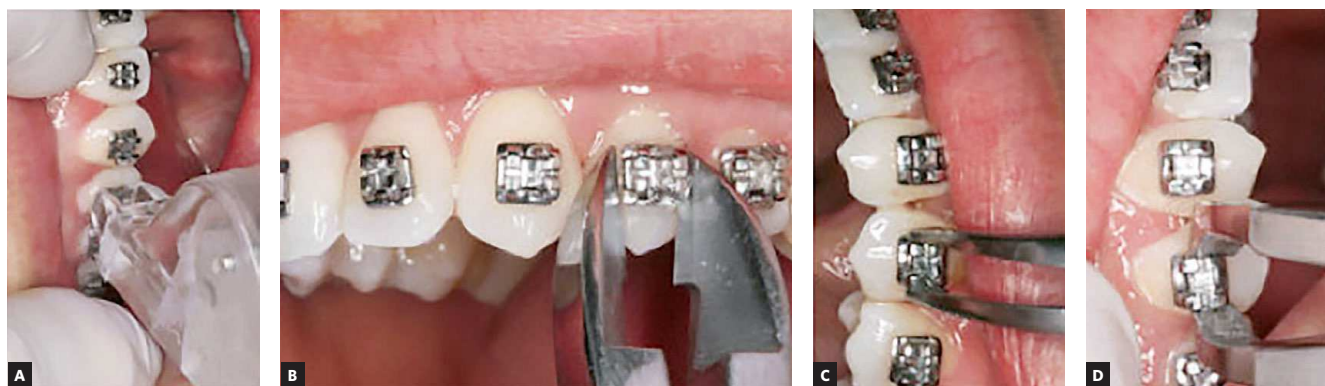
**Figure 2** - A) Schematic view of the palatal appliance containing three types of orthodontic brackets and B) anti-clockwise randomization (Source: Brandão et al,<sup>3</sup> 2015).

## PLASTIC BRACKETS ACCUMULATE MORE BIOFILM WHEN COMPARED TO METAL AND CERAMIC ONES

The difficulty encountered by patients in removing bacterial biofilm from their teeth and orthodontic appliances is no surprise to any orthodontist. This practitioner has the duty to instruct and motivate patients every day in the search for effective cleaning. But all this effort may be in vain when the patient does not contribute with his share. In this context, some questions arise: what could I, orthodontist, do to alleviate this problem? Does brackets' composition influence in greater or lesser bacterial aggregation? In order to verify this hypotheses, Brazilian researchers designed a study *in situ*<sup>3</sup> (Fig 2) in which they evaluated bacterial aggregation in metal, ceramic and polycarbonate (plastic) brackets. The results are of clinical importance since polycarbonate brackets showed a much larger amount of plaque than ceramic and metal brackets which showed similarity in the results. Given these results, plastic brackets should be avoided when cooperation regarding hygiene practice is not expected.

## LIFT-OFF DEBONDING INSTRUMENT PROVED THE LEAST PAINFUL METHOD IN PATIENTS' OPINION

The end of orthodontic treatment is a long-awaited and joyful moment to patients. This expectation is due to the desire to see the result achieved after a long period of treatment, the freedom to properly sanitize the teeth and also financial freedom. Conversely, this moment of ecstasy is often seen as a painful stage, given that, routinely, patients complain of discomfort when removing the orthodontic appliances at the end of treatment. There are several techniques and equipment used in this stage of treatment, each one with advantages and disadvantages regarding the removal technique. Nevertheless, little has been reported about the least painful method in patients' opinion. Thus, Brazilian researchers developed a clinical study<sup>4</sup> evaluating pain perception of patients regarding the removal of metal brackets by four different instruments (Fig 3). Therefore, the split-mouth method was used, in



**Figure 3** - Debonding methods used: **A)** Lift-off debonding instrument, **B)** Straight cutter, **C)** How plier, **D)** Bracket removal plier (Source: Pithon et al,<sup>4</sup> 2015).

which each quadrant had brackets removed. The obtained results showed that, in patients' opinion, the least painful method was the lift-off debonding instrument, whereas the most painful was the straight cutter plier. How pliers and bracket removal pliers showed intermediate results of discomfort.

### LE FORT I OSTEOTOMY INCREASES NASOPHARYNGEAL AIRWAY

Nowadays, many scholars in the field of Dentistry have been interested in assessing the impact of changes introduced by dental treatment in the general health of patients. It has been widely reported in the international scientific literature that the breathing of patients improved after they had undergone orthodontic treatment, especially surgical-orthodontic one. Patients with high mandibular deficiencies have benefited from mandibular advancement, not only for functional aesthetic improvement, but also for better respiratory conditions. In this context, a question arises: which orthognathic surgical procedures favor improved breathing of our patients? Interested in finding some answers, Scottish researchers developed a study<sup>5</sup> aiming to evaluate the impact of Le Fort I osteotomy on the nasopharyngeal airway. The results are revealing and encouraging, since an increased nasopharyngeal

airway can be seen after this procedure. This is good news for us orthodontists because this procedure is used when there is rapid expansion of surgically assisted maxillary and maxillary advancement.

### REFERENCES

- Shetty A, Patil AK, Ameet R, Sandhu PK. Local infiltration of Vitamin D does not accelerate orthodontic tooth movement in humans: a preliminary study. *Angle Orthod.* 2015 Jun 2. [Epub ahead of print].
- Li J, Wang X, Li N, Zhenga D, Su Y, Zhang J. Short-term effects of nicotine on orthodontically induced root resorption in rats. *Angle Orthod.* 2015 Jun 17. [Epub ahead of print].
- Brandão GA, Pereira AC, Brandão AM, Almeida HA, Motta RR. Does the bracket composition material influence initial biofilm formation? *Indian J Dental Res.* 2015;26(2):148-51.
- Pithon MM, Figueiredo DSF, Oliveira DD, Coqueiro RS. What is the best method for debonding metallic brackets from the patient's perspective? *Prog Orthod.* 2015;16:88.
- Almuzian M, Almukhtar A, Ju X, Al-Hiyali A, Benington P, Ayoub A. Effects of Le Fort I Osteotomy on the Nasopharyngeal Airway-6-Month Follow-Up. *J Oral Maxillofac Surg.* 2015 Jul 2. [Epub ahead of print].