



# Treatment of adult patient with hyperdivergent retrognathic phenotype and anterior open bite: report of a case with non-surgical orthodontic approach

Marinho Del Santo, Jr<sup>1</sup>

DOI: <https://doi.org/10.1590/2177-6709.25.4.075-084.bbo>

Adult patients with anterior open bite and hyperdivergent retrognathic phenotype demand complex treatments, as premolar extractions, molar intrusion or orthognathic surgery. In the present clinical case, a young adult patient without significant growth, with Class I and anterior open bite, was treated with four premolar extractions. The therapeutic result shows good intercuspitation, good facial esthetic, good function balance, and stability in a two-year post-fixed treatment follow-up.

**Keywords:** Hyperdivergent retrognathic phenotype. Anterior open bite. Premolar extractions. Non-surgical orthodontic therapy.

## INTRODUCTION

Patients presenting hyperdivergent retrognathic phenotype demand complex orthodontic treatments.<sup>1,2</sup> Etiologically, such phenotype mainly combines the vertical facial genotype with an inadequate mandibular posture.<sup>1,3</sup> Such patients present three mandatory morphologic-functional features: a) deficient ratio between posterior and anterior facial heights, provoking a long and convex facial profile;<sup>4,5</sup> b) deficient masticatory function, with weaker bite force when compared to normal and hypodivergent subjects<sup>6-8</sup>, and c) narrower dental arches, especially

the maxillary one, with tendency of posterior cross-bite occurrence.

Oral breathing is another environmental factor involved in the development of facial hyperdivergence, which evidence of cause-effect has been presented in primates.<sup>9</sup> Facial hyperdivergence has been related to clinical scenarios as enlarged adenoids,<sup>10-14</sup> allergic rhinitis,<sup>15,16</sup> enlarged tonsils,<sup>17</sup> and obstructive sleep apnea.<sup>18</sup> Eating habits and consequently muscle strength are environmental factors also related to facial hyperdivergence.<sup>19,20</sup> In such subjects, it has been postulated that vertical dimensions and mandibular

<sup>1</sup> Orthodontist, private practice (São Paulo/SP, Brazil). American Board of Orthodontics certified. *Board Brasileiro de Ortodontia* certified.

» The author reports no commercial, proprietary or financial interest in the products or companies described in this article.

» Patients displayed in this article previously approved the use of their facial and intraoral photographs.

**How to cite:** Del Santo Jr M. Treatment of adult patient with hyperdivergent retrognathic phenotype and anterior open bite: report of a case with non-surgical orthodontic approach. *Dental Press J Orthod.* 2020 July-Aug;25(4):75-84. DOI: <https://doi.org/10.1590/2177-6709.25.4.075-084.bbo>

**Submitted:** July 20, 2020 – **Revised and accepted:** July 30, 2020

**Contact address:** Marinho Del Santo Jr.  
Av. Vereador José Diniz, 3725, cj. 81, Campo Belo, São Paulo/SP  
CEP: 04.603-004 - E-mail: [officemarinhodelsanto@gmail.com](mailto:officemarinhodelsanto@gmail.com)

morphology are already established at 6 years of age.<sup>21</sup> The maxilla presents excessive dentoalveolar growth in the posterior region. Mandibular rami are shorter than in normal and hypodivergent subjects, gonial angles are greater, dentoalveolar growth is excessive in the posterior region as well, the mandibular symphysis is taller and thinner, anterior lower facial height is increased and the mandibular plane angle is steeper.<sup>1</sup> Such features are associated with clockwise true mandibular rotation, and lesser chin anterior projection.<sup>1</sup> Transversally, hyperdivergent subjects present narrower dental arches, especially the maxillary, when compared to normal and hypodivergent subjects.<sup>22-24</sup> True mandibular rotation is frequently camouflaged by mandibular remodeling, and only apparent rotation<sup>25,26</sup> is clinically detected by orthodontists.

Contrary to common sense, evidence that support the relationship between anterior open bite and this facial phenotype is weak, mainly because anterior open bite is clearly more dentoalveolar than skeletal.<sup>27-29</sup> However, anterior open bite is a common feature of these subjects, as can be noticed in the present case report.

Many therapeutic protocols have been presented for hyperdivergent retrognathic patients, for example: high-pull headgears,<sup>30</sup> dental extractions,<sup>31-35</sup> posterior bite-blocks and vertical-pull chin cup,<sup>36-38</sup> and orthodontic-surgical approaches.<sup>39</sup> In the same direction, Buschang et al<sup>40</sup> showed consistent results pursuing molars intrusion. They described intrusion of upper molars and secondary intrusion (actual or relative) of lower molars, with the use of coil springs and miniscrew implants.<sup>40</sup>

## CASE REPORT

The patient, a Caucasian woman aged 16 years and 7 months, presented in a private office for initial orthodontic consultation. Her chief complaint was related to the open bite. The patient reported absence of significant records in her medical history. She had never been orthodontically treated. Clinically, no caries or other dental/periodontal problem was detected, and she presented good oral hygiene. The patient presented convex soft tissue profile, Class I malocclusion, permanent dentition, significant anterior open bite, significant overjet, mamelons in the incisal edges of the maxillary and mandibular incisors, maxillary right central incisor presenting

yellowish hue, and moderate dental crowding in both dental arches (Figs 1 and 2).

The skeletal cephalometric assessment showed Class II tendency ( $ANB = 4^\circ$ ) and hyperdivergent facial type ( $SN.GoGn = 41^\circ$  and  $FMA = 33^\circ$ ), as shown in Table 1 and Figure 3. Cervical vertebrae maturation stage<sup>41</sup> was CS6, suggesting that her active growth was virtually completed. Her convex profile and hyperdivergent facial features called attention for possible overeruption of molars and detrimental backward (clockwise) mandibular rotation.

The patient showed Class I malocclusion; significant overjet (6 mm); anterior open bite (3 mm); permanent dentition with full formed roots and all teeth completely erupted (except third molars, not erupted); moderate dental crowding in the maxillary arch (5 mm) and mandibular arch (5 mm); maxillary and mandibular incisors significantly proclined (except mandibular right central incisor, retroinclined). Maxillary and mandibular arches presented narrow "U" shape. Tongue interposition between maxillary and mandibular dental arches in rest position and tongue thrust during deglutition were detected.

The patient presented leptoprosopic face and convex soft tissue profile; acceptable nasolabial angle and good chin projection; lip sealing, with lips slightly protruded.

## TREATMENT PLAN AND APPLIED ORTHODONTIC MECHANICS

The treatment objectives were: promote counterclockwise mandibular rotation, to reduce the anterior inferior facial height; increase the chin projection; improve the facial profile, decreasing facial convexity; maintain canines and molars in Class I; achieve adequate overjet and overbite, and correct dental crowding in both dental arches.

Maxillary and mandibular first premolars extractions, and vertical control for molar extrusion during space closure orthodontic mechanics were planned. Intermaxillary elastics would be used when necessary. Orthodontic retention (removable and lower fixed) for at least 12 months after removal of the fixed appliance.

Pre-adjusted brackets and tubes (0.022-in, MBT prescription, American Orthodontics, Sheboygan, WI, USA) were installed in all the teeth, including second molars. Alignment and leveling were achieved

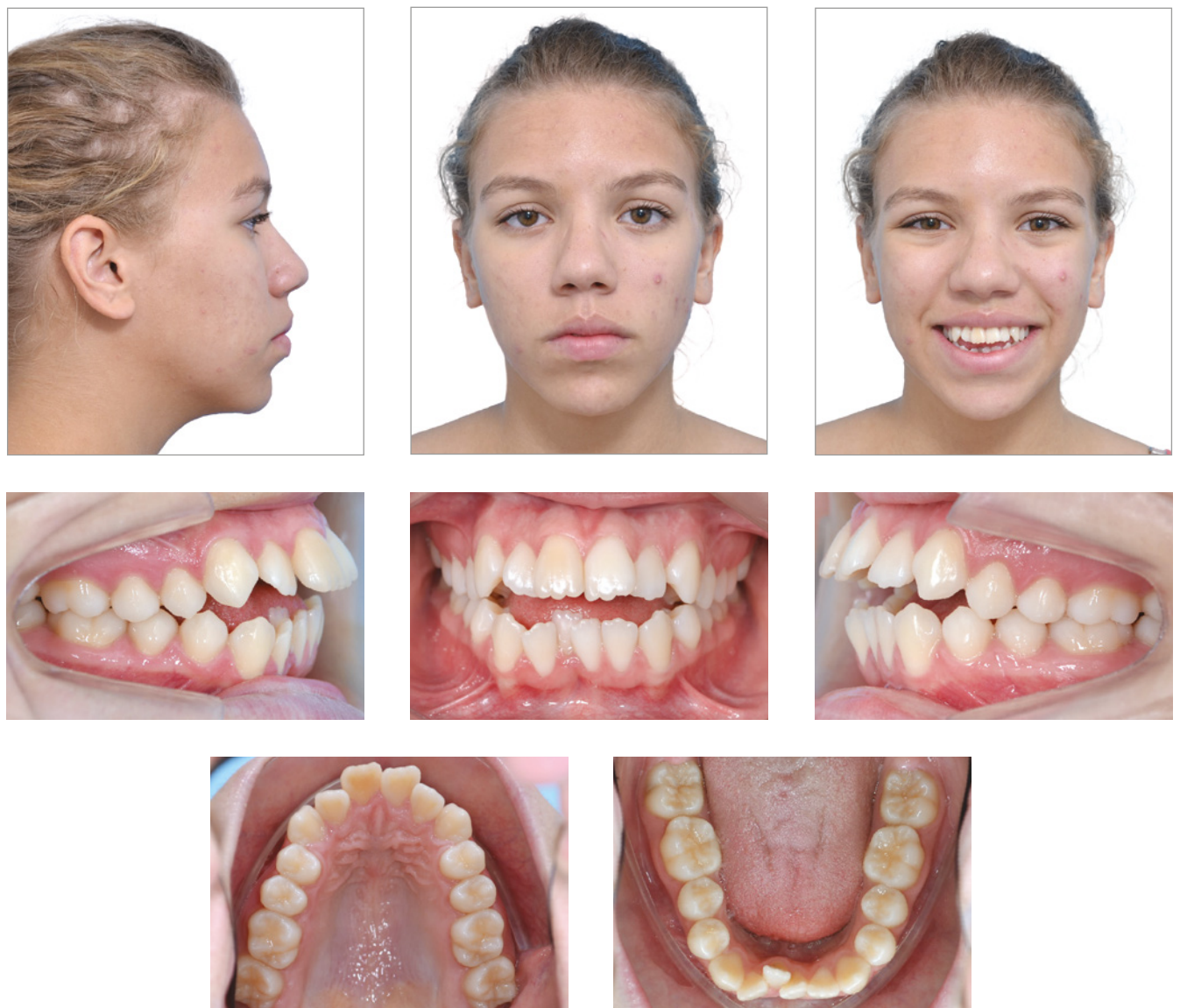

Figure 1 - Initial facial and intraoral photographs.

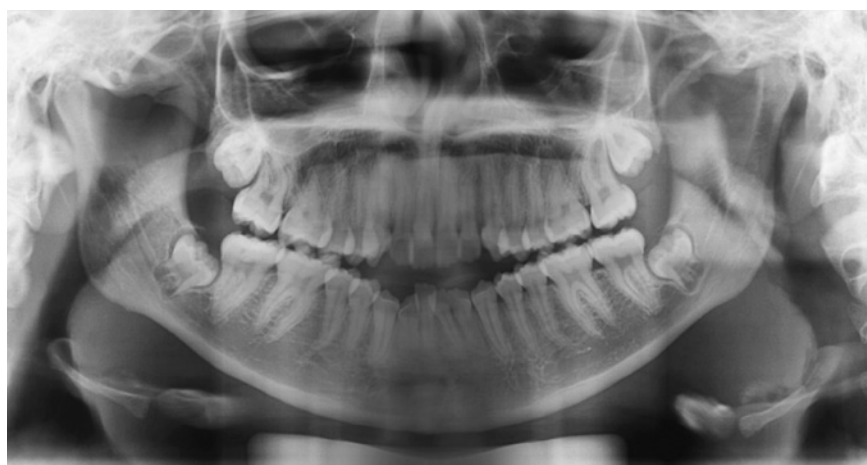

Figure 2 - Initial panoramic radiograph.

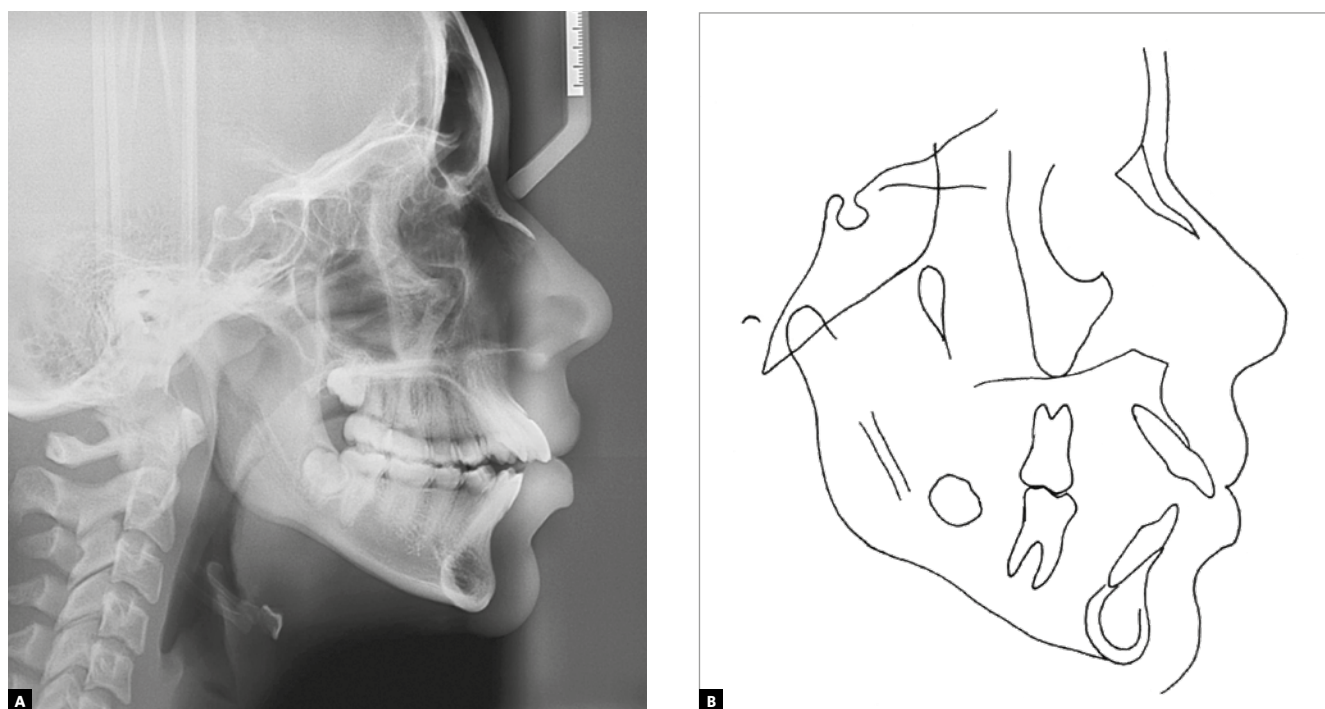


Figure 3 - Initial cephalometric radiograph (A) and cephalometric tracing (B).

with NiTi and stainless steel wires. Extraction spaces closure was performed with 0.017x0.025-in stainless steel archwires (upper and lower) with bull loops, and minimal gable bends. Class II elastics (3/16-in heavy) were applied 14h/day during three months, to differentiate forward movement of mandibular and maxillary molars (mandibular molars having more anchorage loss than maxillary molars). Artistic bends were made in the stainless steel archwires. Inter-maxillary elastics (3/16-in light) were used as needed in the posterior segments, for occlusal settling.

Retainers were installed no later than three weeks after fixed appliance removal. Check-up for occlusal relationships (and possible adjustment of occlusal interferences) was made no later than four weeks after retainers had been installed (Fig 4). For retention, a 0.75-mm Essix (Dentsply Raintree, New Orleans, LA) was installed in the maxillary arch, and a 1.0-mm Essix was installed in the mandibular arch. In the mandibular arch, a 0.018-in multistrand wire was also bonded to the canines only, as an adjunct fixed retainer. The patient was instructed to wear

the removable retainers for 22 hours/day (except for than meals) for at least 12 months.

### TREATMENT RESULTS

Class I was maintained, and anterior open bite and overjet were corrected, with significant uprighting of the maxillary and mandibular incisors ( $\bar{1}$ .SN difference =  $18^\circ$ ;  $\bar{1}$ -NA difference = 7 mm;  $\bar{1}$ .MP difference =  $11^\circ$  and  $\bar{1}$ -NB difference = 4 mm). Furthermore, correct relationship among maxillary and mandibular incisors was achieved. Dental crowding, dental rotations and unlevelled margin ridges were corrected (Figs 4 and 5).

Vertical change of the maxillary incisors was mainly due to the orthodontic mechanic. Two extra millimeters were left forecasting some grinding of incisor mamelons. Change in the position of the maxillary molars, without extrusion, was mainly due to the controlled space closure mechanics.

The maxillary intermolar distance was maintained, and slight decrease occurred in the mandibular one (1 mm). Maxillary and mandibular intercanines distances were minimally increased (1 mm).



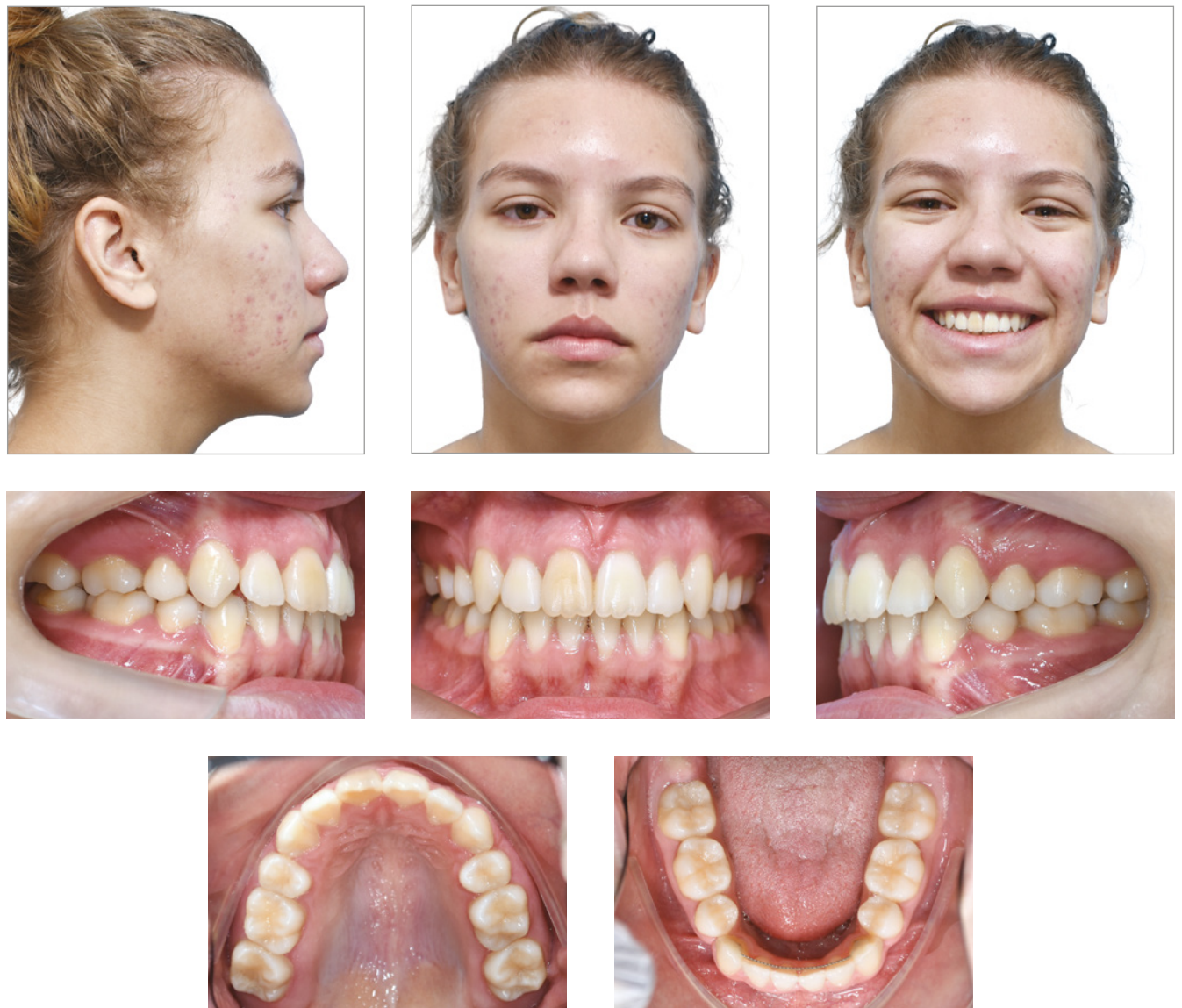

Figure 4 - Final facial and intraoral photographs.

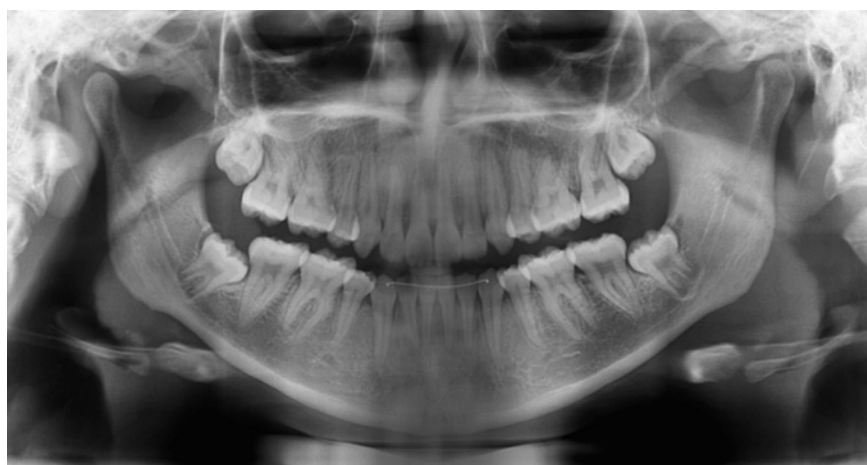

Figure 5 - Final panoramic radiograph.

The facial profile did not change significantly, but there was a slight decrease in the facial convexity and the lip sealing was maintained. Moreover, a slight decrease in the lower anterior facial height and some slight anterior chin projection were due to an-

terior mandibular rotation (Fig 6). The total and partial superimpositions show minimal reminiscent facial growth, including dentoalveolar changes (Fig 7). Small skeletal changes occurred, other than the significant reduction of the incisors anterior projection.

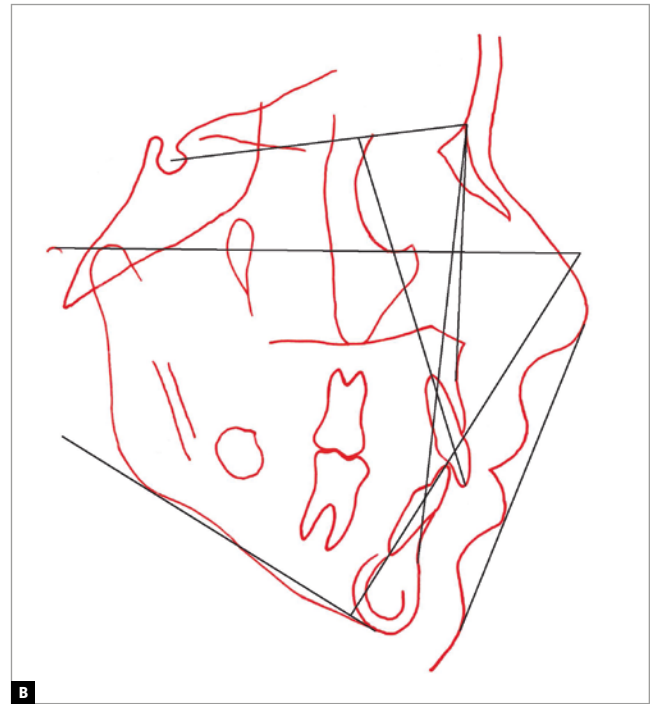
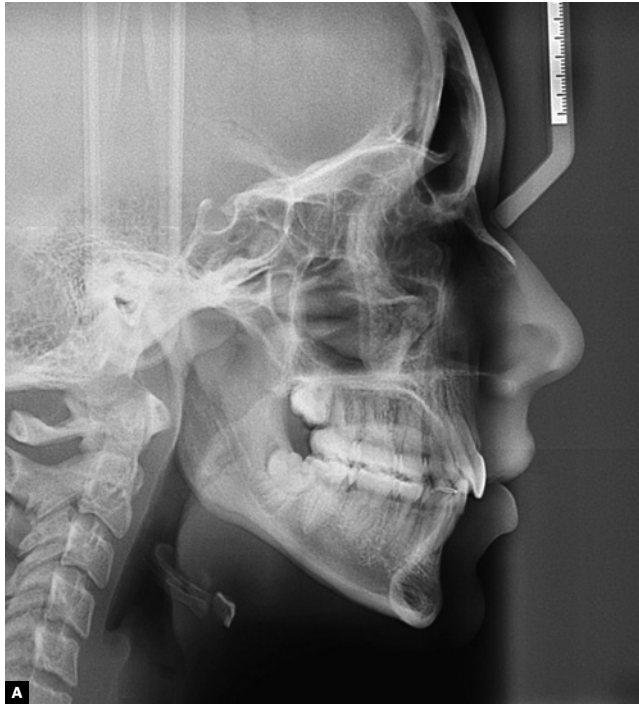


Figure 6 - Final cephalometric radiograph (A) and cephalometric tracing (B).

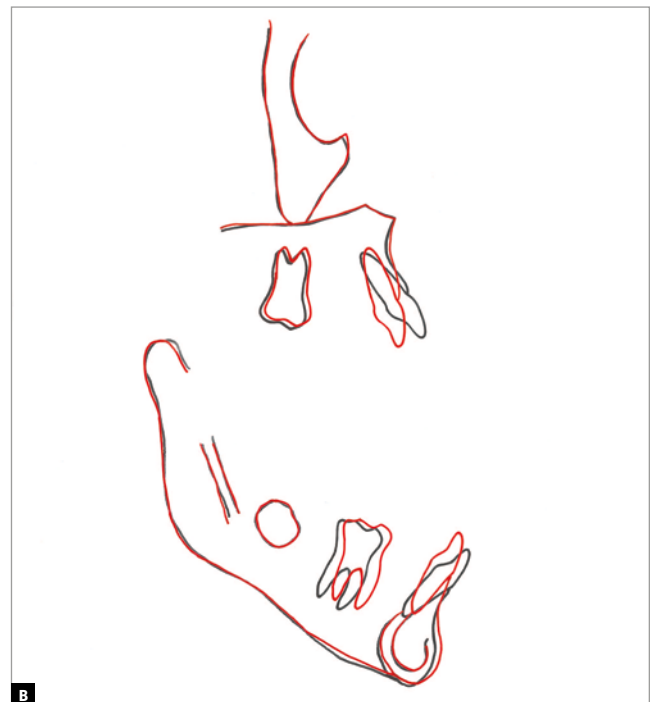
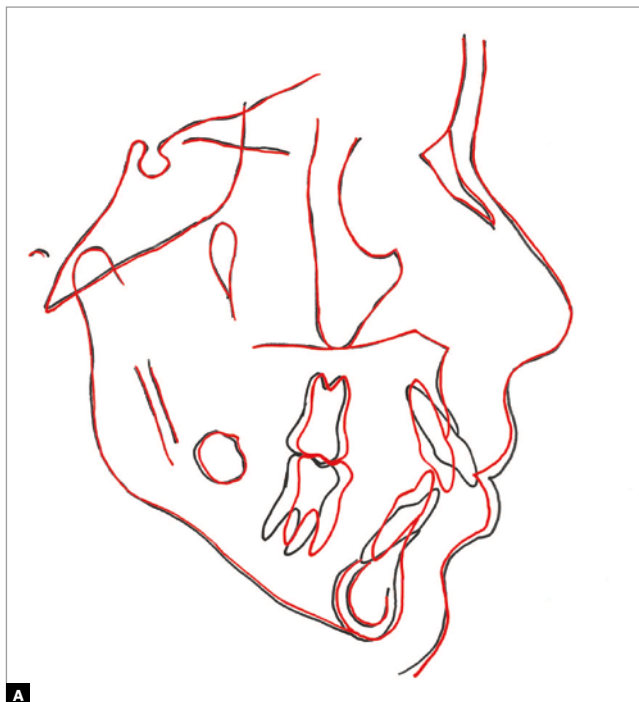
Figure 7 - Total (A) and partial (B) superimpositions of initial (black) and final (red) cephalometric tracings.

**Table 1** - Cephalometric measurements, comparing initial (A) and final (B) lateral radiographs.

	Measurement		Normal	A	B	A/B diff.
<b>Skeletal pattern</b>	SNA	(Steiner)	82°	81°	81°	0
	SNB	(Steiner)	80°	77°	77°	0
	ANB	(Steiner)	2°	4°	4°	0
	Wits	(Jacobson)	♀ 0 ± 2mm ♂ 1 ± 2mm	0mm	1mm	1
	Angle of Convexity	(Downs)	0°	7°	8°	1
	Y-Axis	(Downs)	59°	63°	63°	0
	Facial Angle	(Downs)	87°	84°	85°	1
	SN.GoGn	(Steiner)	32°	41°	39°	2
	FMA	(Tweed)	25°	33°	31°	2
<b>Dental pattern</b>	IMPA	(Tweed)	90°	102°	91°	11
	⊥-NA (graus)	(Steiner)	22°	36°	18°	18
	⊥-NA (mm)	(Steiner)	4mm	10mm	3mm	17
	⊥-NB (graus)	(Steiner)	25°	40°	27°	13
	⊥-NB (mm)	(Steiner)	4mm	7mm	3mm	4
	⊥ - Interincisal Angle	(Downs)	130°	100°	131°	31
	⊥ - APg	(Ricketts)	1mm	6mm	2mm	4
<b>Profile</b>	Upper lip-S line	(Steiner)	0	-2mm	-3mm	1
	Lower lip-S line	(Steiner)	0	4mm	-1mm	5

## DISCUSSION

For subjects presenting facial hyperdivergence, mandibular posture is an important etiologic factor involved.<sup>1,42</sup> During active craniofacial growth, postural deviations can be improved by neuromuscular re-education, and this is the core concept of the application of orthopedic appliances. Therefore, at least hypothetically, in patients with good facial growth potential, counterclockwise mandibular rotation can partially improve the initial hyperdivergent scenario. But in adult patients, strictly speaking, there are just two possible therapeutic alternatives: 1) dental extractions as a method of camouflage or, 2) an orthodontic-surgical approach.

Premolar extractions can improve lip and dental protrusion.<sup>43</sup> And this happened in the current case, since the patient's final facial profile has become very pleasant. Such effect is contradictory to the com-

mon sense that extractions damage facial profiles. When well indicated, extractions can definitely improve facial harmony.<sup>44</sup>

In this current case, all the treatment objectives were successfully achieved after four first premolar extractions: Class I was maintained in the molars, and fully accomplished in the canines; overjet, anterior open bite, and dental crowding were corrected; tongue thrust was eliminated, and facial profile convexity was slightly reduced. The final overbite was planned to allow long-term incisal mamelons wear (final overbite of 4 mm, considering that 2 mm – 1 mm of upper incisors and 1 mm of lower incisors – will be ground at a constant and steady pace, with the prospective incisors occlusal function).

Mechanically, when premolar extraction sites are orthodontically closed by *en masse* movements, two basic effects are expected: 1) loss of anchorage



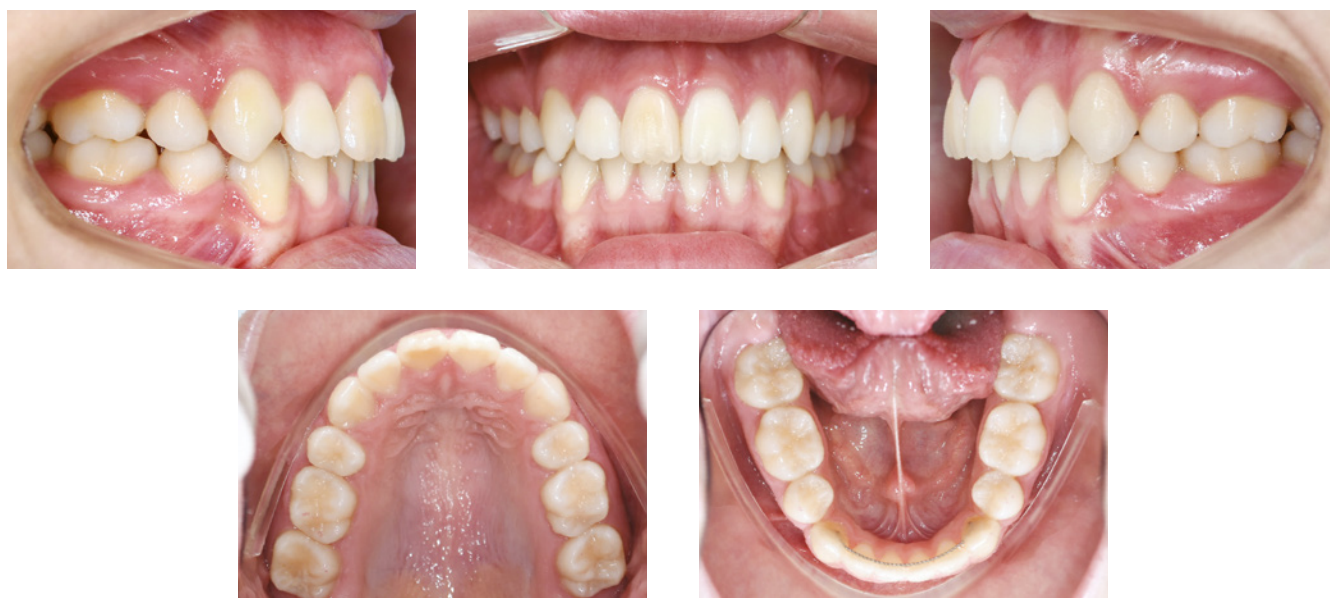

Figure 8 - Intraoral photographs, 2 years after completion of fixed orthodontic treatment.

of the molars, unless prevented by anchorage methods, and 2) loss of anterior vertical dimension, due to direct or indirect extrusion of the maxillary and mandibular anterior teeth. Such loss of vertical dimension was prevented by gable bends incorporated in the used archwires. However, in open bite cases, such loss of vertical dimension is welcome exactly because it closes the bite. With minimal or no gable effect in the archwires, the open bite was corrected. Passive tongue interposition between maxillary and mandibular incisors and tongue thrust, that in open bite cases are drawbacks, are eliminated when the relationship among maxillary and mandibular incisors is correct. However, achieved results must be monitored to avoid open bite relapse.

In practice, the risk of relapse in this case is minimal, if any: first of all, good occlusion was obtained (and there is a tendency to be maintained); secondly, the initial muscular pattern, in special of the tongue, was re-established; lastly, because the patient shows great compliance with the wear of removable retainers. A minimal occlusal adjustment was performed six months after debonding. Such fine-tuning is essential to maintain the balance of the occlusion. Two-year follow-up photographs show good stability (Fig 8).

In children and adolescents, anterior open bites with tongue thrust can be treated by fixed or removable appliances, with or without lingual spurs and cribs.<sup>45-47</sup> However, anterior open bites in adult patients are considered skeletal, since the positioning of the anterior teeth implies in permanently deformed dentoalveolar bases and, most of the time, malocclusion is treated with fixed orthodontic appliances and intermaxillary elastics.<sup>48</sup>

Indeed, an orthodontic-surgical approach, with mandibular advancement and counterclockwise rotation of the occlusal plane, can be an alternative therapeutic plan for these cases<sup>49</sup> But orthognathic surgeries involve extra costs and risks, and provide no full guarantee of long-term stability. Some professionals would claim that orthognathic surgery is the primary option for patients with hyperdivergent retrognathic phenotype, being the premolar extractions option an alternative treatment plan. However, the author of the present report believes the opposite: The premolar extractions choice is the first therapeutic option for young adult patients, mostly teenagers, been orthognathic surgery reserved for selected cases.

The American Board of Orthodontics Discrepancy Index (ABO-DI)<sup>50</sup> was 39, being this case considered



severe mainly because of the hyperdivergent facial phenotype, the presented open bite, and dental crowding. The American Board of Orthodontics Cast-Radiograph Evaluation,<sup>51</sup> when applied on the final records, scored 3. Therefore, it has been considered that the orthodontic treatment was well succeeded.

## CONCLUSION

The first premolar extractions therapeutic approach is valid and may be considered the main treatment option for young adult patients presenting hyperdivergent retrognathic phenotype.

## Acknowledgements

This case was presented to the Midwest Edward H. Angle Society, USA. The author thanks Dr. Steven Marshall (Chicago, IL), for his invitation and sponsorship.

## Authors contribution (ORCID<sup>®</sup>)

Marinho Del Santo Jr. (MDS): 0000-0003-0129-2626 <sup>id</sup>

Conception or design of the study: MDS. Data acquisition, analysis or interpretation: MDS. Writing the article: MDS. Critical revision of the article: MDS. Final approval of the article: MDS.

## REFERENCES

- Buschang PH, Jacob H, Carrillo R. The morphological characteristics, growth, and etiology of the hyperdivergent phenotype. *Semin Orthod*. 2013 Dec;19(4):212-26.
- Ghafari JG, Macari AT. Component analysis of predominantly vertical occlusal problems. *Semin Orthod*. 2013 Dec;19(4):227-38.
- Garcia-Morales P, Buschang PH, Throckmorton GS, English JD. Maximum bite force, muscle efficiency and mechanical advantage in children with vertical growth patterns. *Eur J Orthod*. 2003 Jun;25(3):265-72.
- Schudy FF. Vertical growth versus anteroposterior growth as related to function and treatment. *Angle Orthod*. 1964 Apr;34(2):75-93.
- Schudy FF. The rotation of the mandible resulting from growth: its implications in orthodontic treatment. *Angle Orthod*. 1965 Jan;35(1):36-50.
- Proffit WR, Fields HW, Nixon WL. Occlusal forces in normal- and long-face adults. *J Dent Res*. 1983 May;62(5):566-70.
- Proffit W, Fields H. Occlusal forces in normal and long-face children. *J Dent Res*. 1983 May; 62(5):571-4.
- Ingervall B, Minder C. Correlation between maximum bite force and facial morphology in children. *Angle Orthod*. 1997 Dec;67(6):415-22.
- Harvold EP, Tomer BS, Vargervik K, Chierici G. Primate experiments on oral respiration. *Am J Orthod*. 1981 Apr;79(4):359-72.
- Linder-Aronson S. Adenoids. Their effect on mode of breathing and nasal airflow and their relationship to characteristics of the facial skeleton and the dentition. A biometric, rhino-manometric and cephalometric-radiographic study on children with and without adenoids. *Acta Otolaryngol*. 1970;69(Suppl 265):1-32.
- Linder-Aronson S. Effects of adenoidectomy on dentition and nasopharynx. *Am J Orthod*. 1974 Jan;65(1):1-15.
- Linder-Aronson S, Woodside DG, Lundstrom A. Mandibular growth direction following adenoidectomy. *Am J Dentofacial Orthop*. 1986 Apr;89(4):273-84.
- Woodside DG, Linder-Aronson S, Lundström A, McWilliam J. Mandibular and maxillary growth after changed mode of breathing. *Am J Orthod Dentofacial Orthop*. 1991 Jul; 100(1):1-18.
- Lampasso JD, Lampasso JG. Allergy, nasal obstruction, and occlusion. *Semin Orthod*. 2004 Mar;10(1):39-44.
- Bresolin D, Shapiro PA, Shapiro GG, Chapko MK, Dassel S. Mouth breathing in allergic children: its relationships to dentofacial development. *Am J Orthod*. 1983 Apr; 83(4):334-40.
- Trask GM, Shapiro GG, Shapiro PA. The effects of perennial allergic rhinitis on dental and skeletal development: a comparison of sibling pairs. *Am J Orthod Dentofacial Orthop*. 1987 Oct;92(4):286-93.
- Behlfelt K, Linder-Aronson S, McWilliam J, Neander P, Laage-Hellman J. Cranio-facial morphology in children with and without enlarged tonsils. *Eur J Orthod*. 1990 Aug;12(3):233-43.
- Zettergren-Wijk L, Forsberg CM, Linder-Aronson S. Changes in dentofacial morphology after adeno-/tonsillectomy in young children with obstructive sleep apnoea – a 5-year follow-up study. *Eur J Orthod*. 2006 Aug;28(4):319-26.
- Varrela J. Dimensional variation of craniofacial structures in relation to changing masticatory-functional demands. *Eur J Orthod*. 1992 Feb;14(1):31-6.
- Ueda HM, Ishizuka Y, Miyamoto K, Morimoto N, Tanne K. Relationship between masticatory muscle activity and vertical craniofacial morphology. *Angle Orthod*. 1998 Jun;68(3):233-8.
- Wang MK, Buschang PH, Behrens R. Mandibular rotation and remodeling changes during early childhood. *Angle Orthod*. 2009 Mar;79(2):271-5.
- Wagner DM, Chung CH. Transverse growth of the maxilla and mandible in untreated girls with low, average, and high MP-SN angles: a longitudinal study. *Am J Orthod Dentofacial Orthop*. 2005 Dec;128(6):716-23.
- Forster CM, Sunga E, Chung CH. Relationship between dental arch width and vertical facial morphology in untreated adults. *Eur J Orthod*. 2008 Jun;30(3):288-94.
- Lineberger MW, McNamara JA, Baccetti T, Herberger T, Franchi L. Effects of rapid maxillary expansion in hyperdivergent patients. *Am J Orthod Dentofac Orthop*. 2012 Jul;142(1):60-9.
- Björk A. Prediction of mandibular growth rotation. *Am J Orthod*. 1969 Jun;55(6):585-99.
- Nanda SK. Growth patterns in subjects with long and short faces. *Am J Orthod Dentofacial Orthop*. 1990 Sep;98(3):247-58.

27. Richardson A. Skeletal factors in anterior open-bite and deep overbite. *Am J Orthod.* 1969 Aug;56(2):114-27.
28. Richardson A. Dentoalveolar factors in anterior open-bite and deep overbite. *Dent Pract Dent Rec.* 1970 Oct;21(2):53-7.
29. Cangialosi TJ. Skeletal morphologic features of anterior open-bite. *Am J Orthod.* 1984 Jan;85(1):28-36.
30. Brown P. A cephalometric evaluation of high-pull molar headgear and face-bow neck strap therapy. *Am J Orthod.* 1978 Dec;74(6):621-32.
31. Lamarque S. The importance of occlusal plane control during orthodontic mechanotherapy. *Am J Orthod Dentofacial Orthop.* 1995 May;107(5):548-58.
32. Hans MG, Groisser G, Damon C, Amberman D, Nelson S, Palomo JM. Cephalometric changes in overbite and vertical facial height after removal of four first molars or first premolars. *Am J Orthod Dentofacial Orthop.* 2006 Aug;130(2):183-8.
33. Cozza P, Marino A, Franchi L. A nonsurgical approach to treatment of high-angle Class II malocclusion. *Angle Orthod.* 2008 May;78(3):553-60.
34. Gkantidis N, Halazonetis DJ, Alexandropoulos E, Haralabakis NB. Treatment strategies for patients with hyperdivergent Class II division 1 malocclusion: is vertical dimension affected? *Am J Orthod Dentofac Orthop.* 2011 Sep;140(3):346-55.
35. Ye R, Li X, Li Y, Li J, Wang J, Zhao S, Zhao Z. Occlusal plane canting reduction accompanies mandibular counterclockwise rotation in camouflaging treatment of hyperdivergent skeletal Class II malocclusion. *Angle Orthod.* 2013 Sep;83(5):758-65.
36. Sankey WL, Buschang PH, English J, Owen AH. Early treatment of vertical skeletal dysplasia: the hyperdivergent phenotype. *Am J Orthod Dentofac Orthop.* 2000 Sep;118(3):317-27.
37. Iscan HN, Dincer M, Gultan A, Meral O, Taner-Sarisoy L. Effects of vertical chin cup therapy on the mandibular morphology in open-bite patients. *Am J Orthod Dentofacial Orthop.* 2002 Nov;122(5):506-11.
38. Schulz SO, McNamara Junior JA, Baccetti T, Franchi L. Treatment effects of bonded RME and vertical-pull chin cup followed by fixed appliance in patients with increased vertical dimension. *Am J Orthod Dentofac Orthop.* 2005 Sep;128(3):326-36.
39. Solano-Hernandez B, Antonarakis GS, Scolozzi P, Kiliaridis S. Combined orthodontic and orthognathic surgical treatment for the correction of skeletal anterior open-bite malocclusion: a systematic review on vertical stability. *J Oral Maxillofac Surg.* 2013 Jan;71(1):98-109.
40. Buschang PH, Carrillo R, Rossouw PE. Orthopedic correction of growing hyperdivergent, retrognathic patients with miniscrew implants. *J Oral Maxillofac Surg.* 2011 Mar;69(3):754-62.
41. Baccetti T, Franchi L, McNamara Junior JA. The cervical vertebral maturation (CVM) method for the assessment of optimal treatment timing in dentofacial orthopedics. *Semin Orthod.* 2005 Sep;11(3):119-29.
42. Van Spronsen PH. Long-face craniofacial morphology: cause or effect of weak masticatory musculature? *Semin Orthod.* 2010 Jun;16(2):99-117.
43. Hodges A, Rossouw PE, Campbell PM, Boley JC, Alexander RA, Buschang PH. Prediction of lip response to four first premolar extractions in white female adolescents and adults. *Angle Orthod.* 2009 May;79(3):413-21.
44. Allgayer S, Mezomo MB. Do premolar extractions necessarily result in a flat face? No, when properly indicated. *Dental Press J Orthod.* 2018 Sept-Oct, 23(5):82-92.
45. Leite JS, Matussi LB, Salem AC, Provenzano MGA, Ramos AL. Effects of palatal crib and bonded spurs in early treatment of anterior open bite: a prospective randomized clinical study. *Angle Orthod.* 2016 (Sep);86(5):734-9.
46. Mucedero M, Fusaroli D, Franchi L, Pavoni C, Cozza P, Lione R. Long-term evaluation of rapid maxillary expansion and bite-block therapy in open bite growing subjects: a controlled clinical study. *Angle Orthod.* 2018 Apr;88(5):523-9.
47. Rossato PH, Fernandes TMF, Urnau FDA, Castro ACC, Ferreira C, Almeida RR, Oltramari-Navarro PVP. Dentoalveolar effects produced by different appliances on early treatment of anterior open bite: a randomized clinical trial. *Angle Orthod.* 2018 Jun;88(6):684-91.
48. Choi KW, Ko HC, Todoki LS, Finkleman SA, Krosravi R, Wang HF, Funkhouser E, et al. The National Dental Practice-Based Research Network adult anterior open bite study: a description of the practitioners and patients. *Angle Orthod.* 2018 Sep;88(6):675-83.
49. Tavares CAE, Allgayer S. Open bite in adult patients. *Dental Press J Orthod.* 2019 Sept-Oct, 24(5):69-78.
50. American Board of Orthodontics [Internet]. ABO discrepancy index instructions. St. Louis: c2015. Available from: <https://www.americanboardortho.com/media/4349/discrepancy-index-instructions.pdf>
51. American Board of Orthodontics [Internet]. Grading System for Dental Casts and Panoramic Radiographs. St. Louis: c2015. Available from: <https://www.americanboardortho.com/media/1191/grading-system-casts-radiographs.pdf>