

Calcific metamorphosis and aseptic necrosis of the pulp:

Differential diagnosis of tooth discoloration

Alberto **CONSOLARO**¹
 Leda A. **FRANCISCHONE**²
 Renata Bianco **CONSOLARO**³
 João Batista Gagno **INTRA**⁴
 Armelindo **ROLDI**⁵

¹ Professor of Pathology - University of São Paulo, Brazil.

² PhD, Professor, Universidade Sagrado Coração, Bauru, Brazil.

³ PhD, Substitute Professor, School of Dentistry at Araçatuba (FOA), Universidade Estadual Paulista (UNESP), Araçatuba, Brazil, and Faculdades Adamantinenses Integradas, Adamantina, Brazil.

⁴ PhD, Professor, Endodontics, Brazilian Association of Dentistry, Espírito Santo section (ABO-ES), Vitória, Brazil.

⁵ Professor, Endodontics, Federal University of Espírito Santo (UFES), Vitória, Brazil.

Received: June 30, 2011. Accepted: July 13, 2011.

» The authors report no commercial, proprietary, or financial interest in the products or companies described in this article.

How to cite this article: Consolaro A, Francischone LA, Consolaro RB, Intra JBG, Roldi A. Calcific metamorphosis and aseptic necrosis of the pulp: Differential diagnosis of tooth discoloration. *Dental Press Endod.* 2011 July-Sept;1(2):11-20.

Considerations and assumptions

Scientifically, the following questions have not been accurately answered yet:

1. What determines tooth color, its shades and hues and its variations even in the same person?
2. Does tooth color result from the distribution of a pigment at variable concentrations in tooth structure?
3. Is color a consequence of the level of mineralization of tooth tissues, their thickness or mineral density?
4. Is tooth color genetically determined and what is the genetic transmission pattern?
5. Do teeth have the same color primarily, which then undergoes changes due to intrinsic or extrinsic environmental factors to which the individual is exposed since the first moments of life?

Natural tooth color is yellowish, and its hue varies from tooth to tooth in the same patient and much more intensely between different patients. In addition to the yellow shades classified as normal, different hues have been seen and classified as truly abnormal or pathological changes in tooth color:

Excessively yellowish, brownish, bluish, grayish and even blackish.¹⁰

“Tooth discoloration” is a diffuse change that results from increases of yellow and a change in its hue all over the tooth crown (Figs 1 and 2), or even in all the teeth of a single patient.¹⁰ In several cases, the cause of tooth discoloration may be defined, but when it is not, the case is classified as idiopathic. Several people complain about the darker color of their teeth and, unhappy with that, ask for bleaching procedures, usually because the media advertises “white teeth” as healthy and beautiful, although their normal color is yellowish.

Two important terminology questions:

1st) The term bleaching: For several years this clinical procedure has been called “whitening” by most people, and its equivalent in Portuguese (*clareamento*), for example, has even been included in the latest editions of popular dictionaries. Therefore, the current use of the term “*clareamento*” (bleaching) may be justified by this linguistic incorporation.

2nd) The term “pigment”, derived from Latin, means “color to paint” and names different types of

substances that impart a color to liquids, animal and vegetable tissues and even other substances. Pigments in the human body may have an endogenous or exogenous origin and may be deposited in excess inside cells or in intercellular spaces. The presence of pigments in cells and tissues may be normal, but their accumulation may be a morphological sign of aggression. The main pigments associated with human biology are:

» Endogenous pigments: Melanin, lipofuscin, bilirubin and hemosiderin;

» Exogenous pigments: Coal, silica, asbestos and silver.

Classification and causes of tooth pigmentation

The origin of pigments that discolor teeth may be:

(a) Intrinsic or endogenous: When they are produced by the organism itself, such as in the case of hemosiderin, iron and bilirubin.

(b) Extrinsic or exogenous: When originated in the environment, such as fluoride; in therapeutic agents, such as silver, bismuth or tetracycline; or, still, in other organisms, such as the pigments from chromogenic bacteria.

The incorporation of pigments in tooth discoloration may be:

(a) Internal: When incorporated into the structure of tooth tissues, such as when it results from endodontic treatment, systemic use of tetracycline during odontogenesis, and fluorosis.

(b) External: When the pigment undergoes apposition on the surface of mineralized dental tissues and is not part of their structure, such as in the case of tobacco tar, chromogenic bacterial pigments and food pigments in the bacterial plaque that adheres to tooth surfaces.

Some clinical conditions are directly associated with tooth discoloration:

1. Pulp haemorrhage associated with inappropriate crown opening in endodontic treatment favors tooth discoloration. Hemosiderin, a pigment derived from hemoglobin in red blood cells, has many iron ions. In pulp necrosis, pigments derived from hemosiderin are likely to play an important role in tooth discoloration.
2. The use of certain endodontic products, such

as obturating pastes containing silver, bismuth and other metal ions, may also promote the discoloration of tooth structures and lead to serious esthetic problems.

3. When tetracycline, fluoride and other products that act as pigments are found in blood, they may incorporate into forming enamel and tooth matrix and affect the color of several teeth. Bilirubin and hemosiderin, when present in excessive amounts in blood, may also be incorporated into teeth, though rarely.
4. Calcific metamorphosis (Figs 1 and 2) and aseptic necrosis of the pulp (Figs 2 and 3): Very frequent and clinically important, they affect one or two teeth separately in the dental arch, especially incisors, due to their greater exposure to dental trauma.^{18,21}

In an evaluation of 168 discolored and injured anterior teeth not treated endodontically, Oginni and Adekoya-Sofowora¹⁶ found, respectively, 47.6% and 31.6% with total and partial calcific metamorphosis (Figs 1 and 2). The other 20.8% had pulp necrosis. The cases of calcific metamorphosis had a history of dental trauma due to concussion or subluxation, particularly in the first and second decades of life. In the cases of pulp necrosis, trauma occurred predominantly in the third decade of life and included fracture of the affected teeth.

Tooth discoloration: Unknown mechanism

We do not know precisely how and where pigments are incorporated into tooth structures. With which proteins or tissue compounds would they unite to the tooth structure? Would they discolor the enamel or the dentin at a higher degree?

If we do not know how pigmentation takes place, we also do not know how tooth whitening happens! Several articles and textbooks show diagrams of pigment transformation by bleaching substances to the point that they generate, eventually, water molecules.⁴ As a hypothetical theoretical model, such diagrams are valuable, but in practice, we do not know how bleaching substances “destroy, inhibit, neutralize and modify” the pigments incorporated into teeth. Why does discoloration tend to recur, even if only partially, along time? Do pigments reconstitute or are new pigments incorporated?

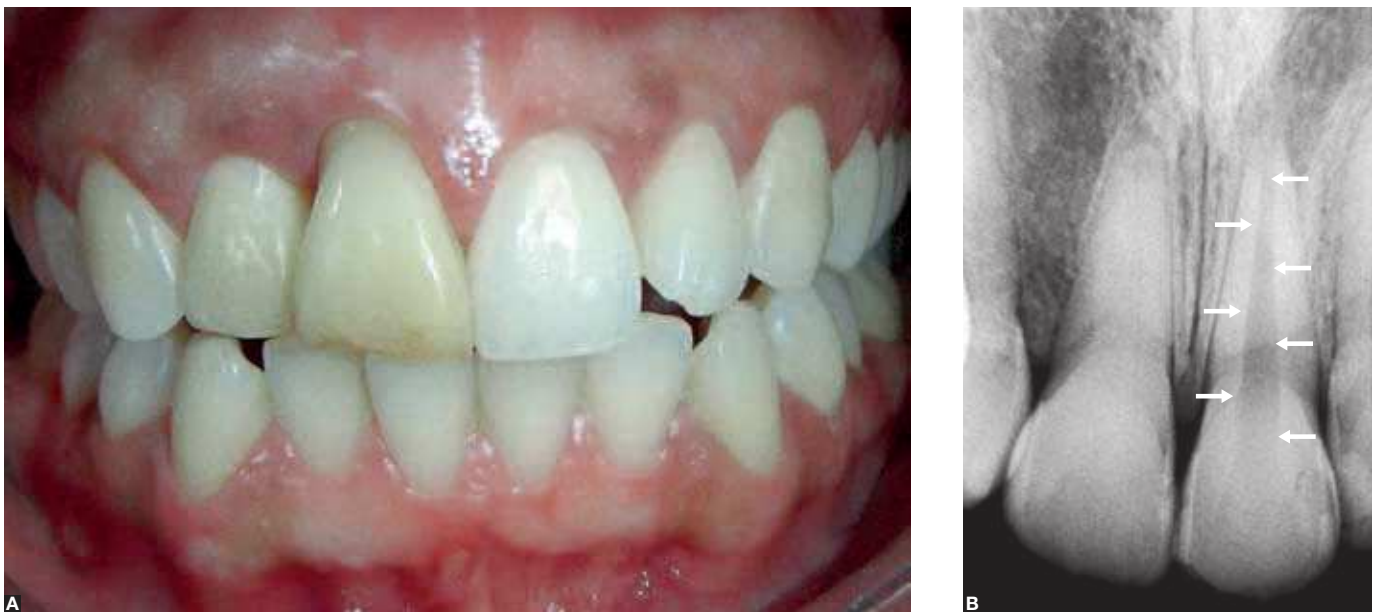

Figure 1. A) Discoloration of the left maxillary central incisor due to calcific metamorphosis in an intact tooth, associated with dental trauma, especially concussion. In this situation, the differential diagnosis with aseptic necrosis of the pulp was defined according to radiographs (B), which showed poorly defined pulp margins, typical of calcific metamorphosis of the pulp, when compared with the normal neighboring tooth (arrows).

We still do not have the answers to many of the questions about tooth discoloration, but several causes are known and, therefore, may be avoided by using advances in therapeutic approaches. Among the well-known, recognized causes of tooth discoloration are calcific metamorphosis and aseptic necrosis of the pulp.

Dental trauma in healthy teeth: what about the pulp?

Teeth that suffer trauma may either have a fracture or not. The neurovascular bundle in the apical foramen may be compromised at variable degrees, and their blood supply may be affected. Although the dental pulp may remain normal after trauma, there are many cases in which there is aseptic necrosis of the pulp (Figs 2 and 3).^{16,19,20}

Of the extreme possibilities of keeping the pulp normal after dental trauma and aseptic necrosis of the pulp is pulp metaplasia, also known as calcific metamorphosis of the pulp (Figs 1, 2, 3 and 4).^{2,16,19,20}

For the classic definition of aseptic necrosis and calcific metamorphosis of the pulp, we considered, in this description, injured teeth that did not have any type of fracture or periodontal changes that might

lead to secondary contamination of the pulp and periapical region. That is, the teeth were injured but remained structurally sound and their mineralized tissues were intact (Figs 1, 2, 5 and 6).

1st - Preserving the normal pulp

When the pulp retains its normal vitality, unpredictable changes may be detected along time, such as early pulp ageing and internal root resorption. Early pulp ageing is characterized by a reduction in pulp volume associated with nodules resulting from isolated dystrophic calcifications. Dystrophic calcification is the mineralization of tissue that underwent changes or morphological and biochemical dystrophy, such as in hyaline areas of excessive pulp fibrosis or small areas of pulp necrosis due to the rupture of small vessels. Therefore, according to microscopic and radiographic findings, they promote the formation of pulp nodules.

2nd - Aseptic necrosis of the pulp:

Pulpal necrosis due to rupture or injury to the neurovascular bundle in the apical foramen promotes tissue protein denaturation characterized by loss of water; pulp cells remain in their framework,

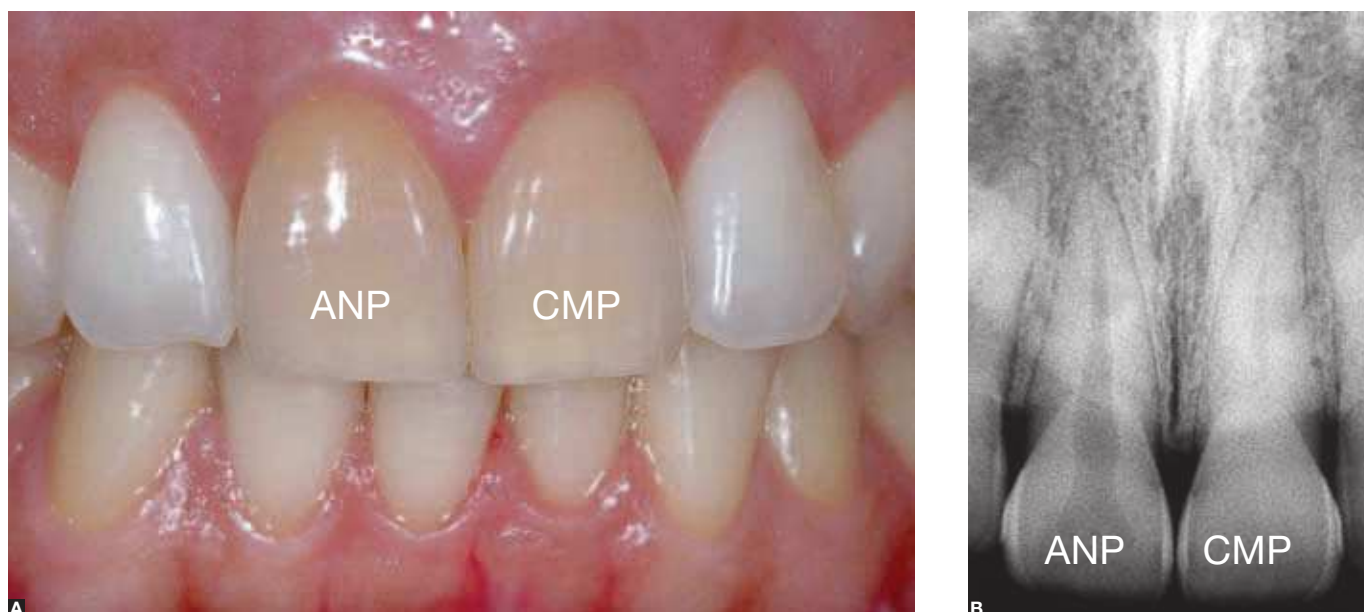


Figure 2. Discolorations of maxillary central incisors: Left incisor, due to calcific metamorphosis of the pulp (CMP) in intact tooth; and right incisor, due to aseptic necrosis of the pulp, both after dental trauma. Radiograph shows poorly-defined pulp canal margins, typical of calcific metamorphosis, when compared with aseptic necrosis of the pulp (ANP). Teeth had discoloration for years, but no symptoms; the two conditions were indistinguishable clinically.

though coagulated and lifeless. Pulp cells are poor in lysosomes, which are organelles full of proteolytic enzymes. Without proteolytic lysosomal enzymes, necrotized cells take too long to dissolve by hydrolysis. This type of necrosis is also called coagulation necrosis and may occur in several parts of the body, particularly in areas that are infarcted and poor in lysosomes.

In injured teeth in which the neurovascular bundle ruptures, but dental structure remains structurally intact without exposure of dentin or pulp to the oral environment and there is no periodontal damage, coagulation necrosis, also called aseptic necrosis of the pulp, is a sign of pulp infarction. Along time, the products derived from necrotized pulp tissue may incorporate into the dentin structure; protein decomposition usually generates dark components, and the tooth discolors into a dark yellowish hue of many shades (Fig 2). There are also pigments derived from hemosiderin, rich in iron and released into the pulp space due to the decomposition of red blood cells.

In aseptic necrosis of the pulp, radiographs show well-defined pulp margins in the chamber and in the root canal, and pulp spaces have normal dimensions and are homogeneously radiolucent. After all, cell

death is so sudden that the pulp has no time to deposit new layers of reactionary dentin.

In the periapical area of teeth with aseptic necrosis of the pulp, or coagulation necrosis, which is typical of dental trauma, chronic apical periodontitis or chronic periapical lesions suggestive of periapical granuloma may be found. They are long-lasting, discrete and practically asymptomatic lesions because the aggressive agents are products of tissue decomposition whose toxicity is low and there are no bacterial products. The main reason to seek dental care or the main complaint by the patient is the dark color of the crown.

3rd - Calcific metamorphosis of the pulp

In case of trauma, hard tissues may remain structurally sound and the pulp, healthy, or the damage may progress into aseptic necrosis of the pulp when the neurovascular bundle is severely and definitely affected.

However, the damage to the neurovascular bundle may be only partial or transient. Pulp cells may undergo transient hypoxia, temporary loss of nutrients, and reduce their metabolism to a minimum necessary for cell survival. This occurs mainly in

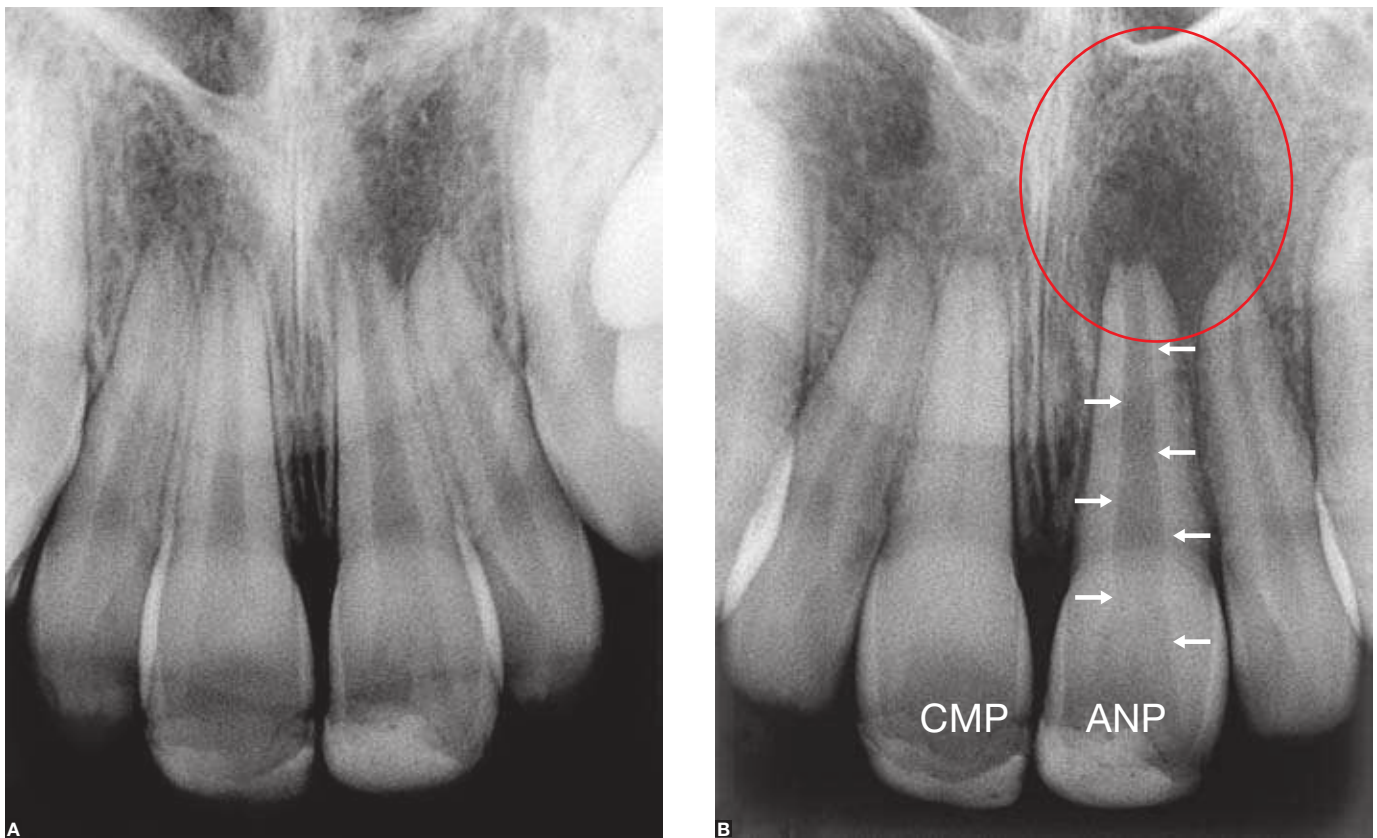


Figure 3. Central incisors had dental trauma according to patient's reports; no professional follow-up, as indicated by the crown lesion on radiograph obtained on an unknown date. The right central incisor progressed into calcific metamorphosis of the pulp (CMP) in some months, and radiograph shows practically no pulp margins and practically total obliteration of the chamber and root canal. Left central incisor had aseptic necrosis of the pulp (ANP), which progressed into chronic periapical lesion (circle), with preservation of well-defined pulp margins (arrows). The diagnosis was made using radiographs obtained for orthodontic planning as there were no symptoms (Source: Consolaro, Bernardini,⁸ 2007).

cases of subluxation (in 45.8% of the cases) and concussion (in 31.6% of the cases).¹⁶ Concussion may be defined as an aggression to supporting periodontal tissues with no abnormal mobility or tooth displacement, but with marked reaction to percussion. Subluxation is an aggression to supporting periodontal tissues with abnormal mobility, but without tooth displacement from the alveolus.^{5,11}

One of the forms of cell adaptation to adverse situations is cell metaplasia. The mature cell undergoes transformations and changes its phenotype into another cell type, equally mature and of the same embryonic lineage. Metaplasia is an efficient form of cell adaptation. When an individual starts smoking, for example, the cells that cover the trachea and bronchi change from ciliated cylindrical cells that produce a large amount of mucus into stratified squamous cells, which may at times even produce surface keratin. In other words, metaplasia is metamorphosis of cell morphology and function.

In the pulp of teeth that underwent trauma and that remain structurally intact, but which have a partial lesion of the neurovascular bundle, pulp cells may undergo metaplasia to adapt to transient hypoxia and their metabolism reduction. Metaplasia produces fibroblasts, pericytes, undifferentiated cells or stem cells, pre-odontoblasts and even vascular cells that differentiate, modify or change into odontoblasts. This initiates a random and disorganized production of reactionary dentin, incorporating cells and vessels into its structure, to the point of being identified as osteodentin or vasodentin, often also called tertiary dentin.^{2,15} Osteodentin and vasodentin are primitive forms of dentin found in teeth of lower animals in the biological scale.

The random deposition of dysplastic, that is, malformed dentin is often very disorganized and little mineralized, and may be directed from the periphery to the center of the pulp (Fig 2), though this is not always the case (Figs 1, 2 and 3). Such random deposition of

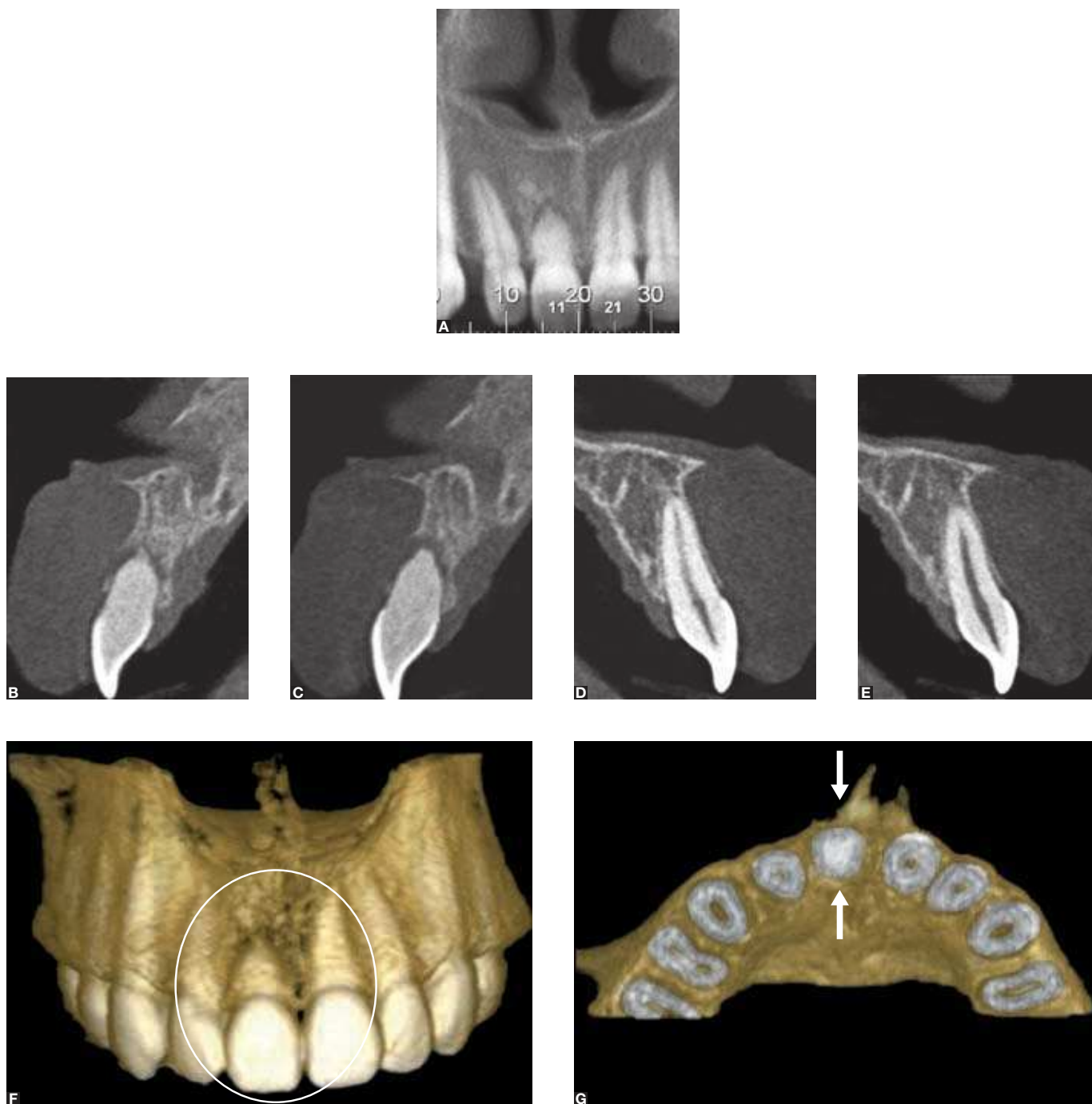


Figure 4. Dental trauma of incisor (11), which progressed into calcific metamorphosis of the pulp; CT scans show obliteration of pulp space and no definition of pulp margins (B and C) when compared with other central incisor (D and E). Three-dimensional reconstruction (F) shows that root is shorter (circle) and that there are separate apical fragments. Three-dimensional transverse views (G) show total obliteration of root canal by dysplastic dentin (arrows).

dysplastic dentin in injured teeth may be absolute and uncontrolled.¹⁵ After three months to one year, radiographs may show the disappearance of normal pulp margins and the obliteration of pulp spaces in the chamber, the root canal, or both (Figs 1, 2 and 3). Obliteration may be completed when the pulp spaces completely disappear, from six months to one year after trauma.

Obliteration of pulp spaces by dysplastic dentin is a very frequent phenomenon simply known as pulp or canal obliteration, but seems to be better classified as calcific metamorphosis of the pulp, the name most often used in the literature about this topic, although it is also common to call it calcific metaplasia of the pulp.

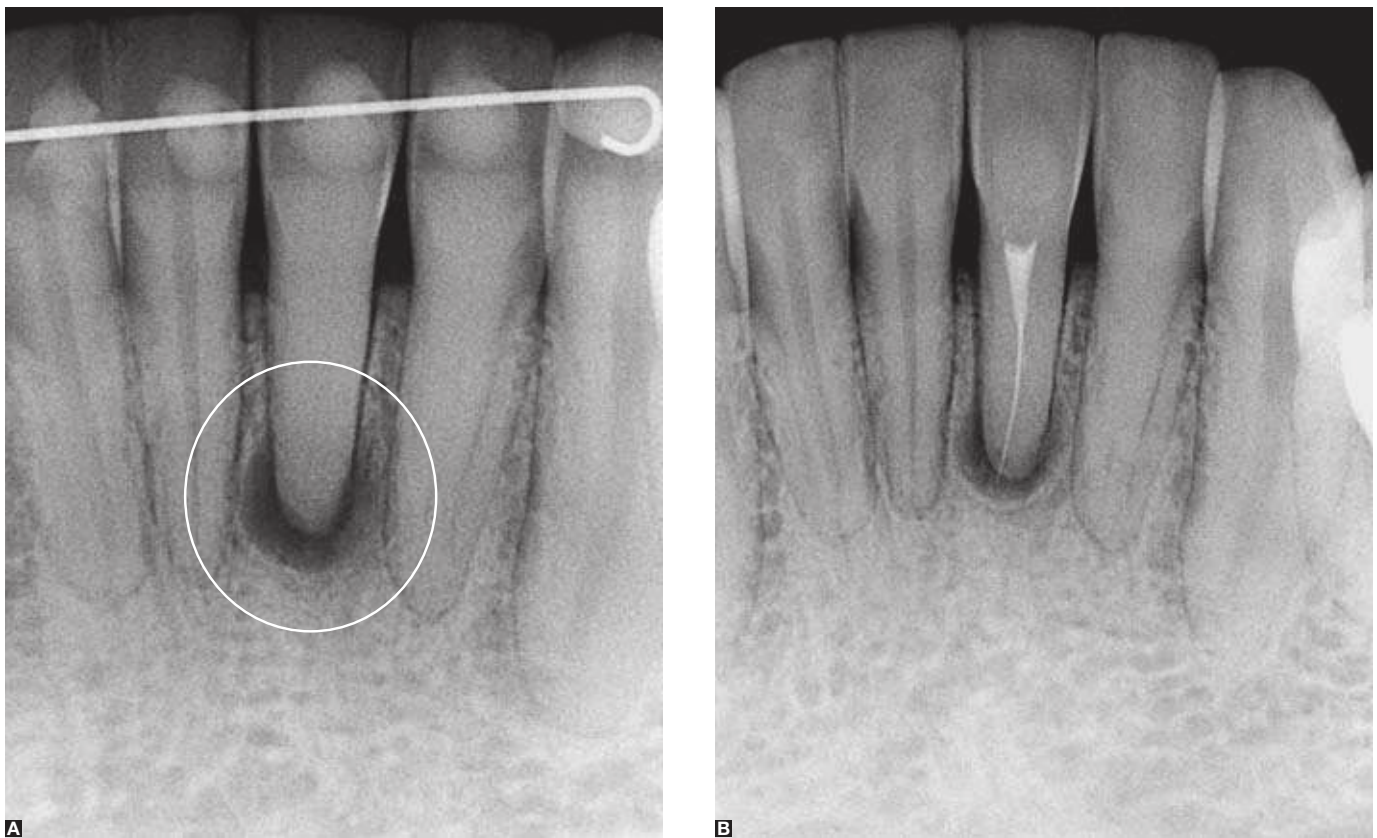


Figure 5. Calcific metamorphosis of the pulp obliterated the chamber and the root canal and prevented necessary endodontic treatment due to chronic periapical lesion (circle). Attempts to approach it through the canal to avoid endodontic surgery are risky because of the high probability of accidents, such as instrument fractures inside the root canal (B). However, even with a fractured instrument (B) and patient's refusal to undergo surgery, there was a reduction in lesion size.

In summary: calcific metamorphosis of the pulp is a response to trauma characterized by the deposition of hard tissues in the root canal space.¹ It occurs in about 3.8% to 24% of injured teeth.¹⁶ Radiographs show the partial or total obliteration of the pulp chamber and root canal spaces (Figs 1 to 6).

Calcific metamorphosis of the pulp is not dystrophic calcification of the pulp,⁶ but, rather, pulp metaplasia, or active deposition of dysplastic dentin. Dystrophic calcifications are the result of mineralization of previously injured tissues that necrotized or were somehow changed. Metaplasia is a form of tissue adaptation to a novel environmental condition.

Clinically, teeth with calcific metamorphosis of the pulp (Figs 1 and 2) gradually acquire a more yellowish color, subtle at first, but more perceptible and disturbing as time goes by, and eventually reaching severe crown discoloration (Fig 2). In most patients

with calcific metamorphosis of the pulp, tooth discoloration is noticed much later, 5 to 10 years after dental trauma.¹⁶ The greatest dentin thickness and the type of disorganized deposition of dysplastic dentin let a very dark and yellowish color appear through the enamel.

Teeth with calcific metamorphosis of the pulp may, along the years, progress into pulp necrosis in 1% to 16% of the cases; in 7.3% to 26.4% of those teeth, periapical rarefactions are induced in up to 4 years after trauma, especially when there is total obliteration of the pulp space.^{2,16}

The initial diagnosis of calcific metamorphosis of the pulp may be made clinically according to the isolated discoloration of one or two intact teeth. The patient might not be able to recall the history of dental trauma, but it practically always occurred. Periapical radiographs showing poor canal margin definitions confirm canal obliteration and establish

the final diagnosis. However, it should be no surprise the fact that, in place of calcific metamorphosis of the pulp, the discolored tooth may have preserved pulp margins associated with chronic periapical lesion, a sign of aseptic necrosis due to severe trauma or neurovascular bundle rupture in the apical foramen. Not rarely, the discolored tooth with such changes has small lateral areas of inactive root resorption, a sign of previous trauma (Fig 5).

Clinically and radiographically, calcific metamorphosis of the pulp points to a history of dental trauma²⁵ and injured teeth that, when moved orthodontically, have greater chances of developing more severe root resorption.^{5,8}

Often, root resorption may be severe if an orthodontist places an appliance and moves a tooth with undiagnosed calcific metamorphosis.⁸ At the same time or after the end of orthodontic treatment, crown discoloration makes the patient seek a dentist specialized in esthetics, and an inaccurate opinion may unfortunately be made: Orthodontic treatment induced pulp necrosis and, consequently, crown discoloration!

In fact, the diagnosis should be calcific metamorphosis or aseptic necrosis of the pulp due to previous dental trauma. Orthodontic movement does not induce aseptic necrosis or calcific metamorphosis of the pulp.^{7,9,12,14,26} In the same way, occlusal trauma does not induce aseptic necrosis or calcific metamorphosis of the pulp.

Basis for clinical and therapeutic decisions

In the clinical cases of aseptic necrosis and calcific metamorphosis of the pulp, the clinical decisions to be directly and immediately made involve the endodontist.^{2,3,13,17,23} The endodontic approach should be, along time, inevitable, either for canal treatment or for endodontic surgery.

Among the clinical decisions to be made, the following conditions should be taken into consideration:

1st - The patient reports recent dental trauma

If the patient reports dental trauma that affected a certain tooth, usually one of the incisors in the last days, weeks or months, the pulp should be evaluated using periapical radiographs and vitality tests. If there are no radiographic signs of calcific metamorphosis or chronic periapical lesions and the vitality test is

positive, the patient should be followed up with radiographs after 6, 9 and 12 months, time points at which calcific metamorphosis may appear. The same occurs with periapical lesions and crown discoloration in cases of aseptic necrosis of the pulp (Figs 2 and 3).

2nd - Patient reports discrete recent discoloration

When complaining about discrete crown discoloration in one or two isolate teeth, with no symptoms or relevant history, the patient may report previous dental trauma, even when apparently not significant. Tests may detect total loss of pulp vitality or positive responses only in the most severe and long tests with dry ice, for example.

Periapical radiographs of these teeth may lead to two diagnoses: Aseptic necrosis (Figs 2 and 3) or calcific metamorphosis of the pulp (Figs 1, 2 and 3).

If the diagnosis is aseptic necrosis of the pulp, conventional endodontic treatment should be prescribed, followed by specific external bleaching of the affected tooth or internal bleaching, if this is the option recommended by the endodontist. The advantage of external bleaching in these cases is the lack of risk of external cervical resorption and less weakening of tooth structures.

If the diagnosis is calcific metamorphosis of the pulp, with radiographic signs, even if subtle, of partially obliterated pulp chamber or canal, the most adequate option is, first, endodontic treatment to avoid the complete closing of the root canal. Canal obliteration complicates any future approach, because 16% of the cases may progress into necrosis in 3 to 21 years.²⁴ This approach would prevent severe and isolated discoloration of the tooth affected, which is esthetically recommended. After endodontic treatment, external bleaching should be performed specifically for the affected tooth.

3rd - Patient reports intense and long-lasting discoloration

The patient has an isolated tooth with discoloration, but no symptoms or any other sign. The patient has a very old history of dental trauma or does not associate discoloration with any previous event. Periapical radiographs may suggest two different diagnoses: Aseptic necrosis, probably with chronic periapical lesion, or calcific metamorphosis of the pulp.

If the diagnosis is aseptic necrosis of the pulp, probably with chronic periapical lesion, conventional

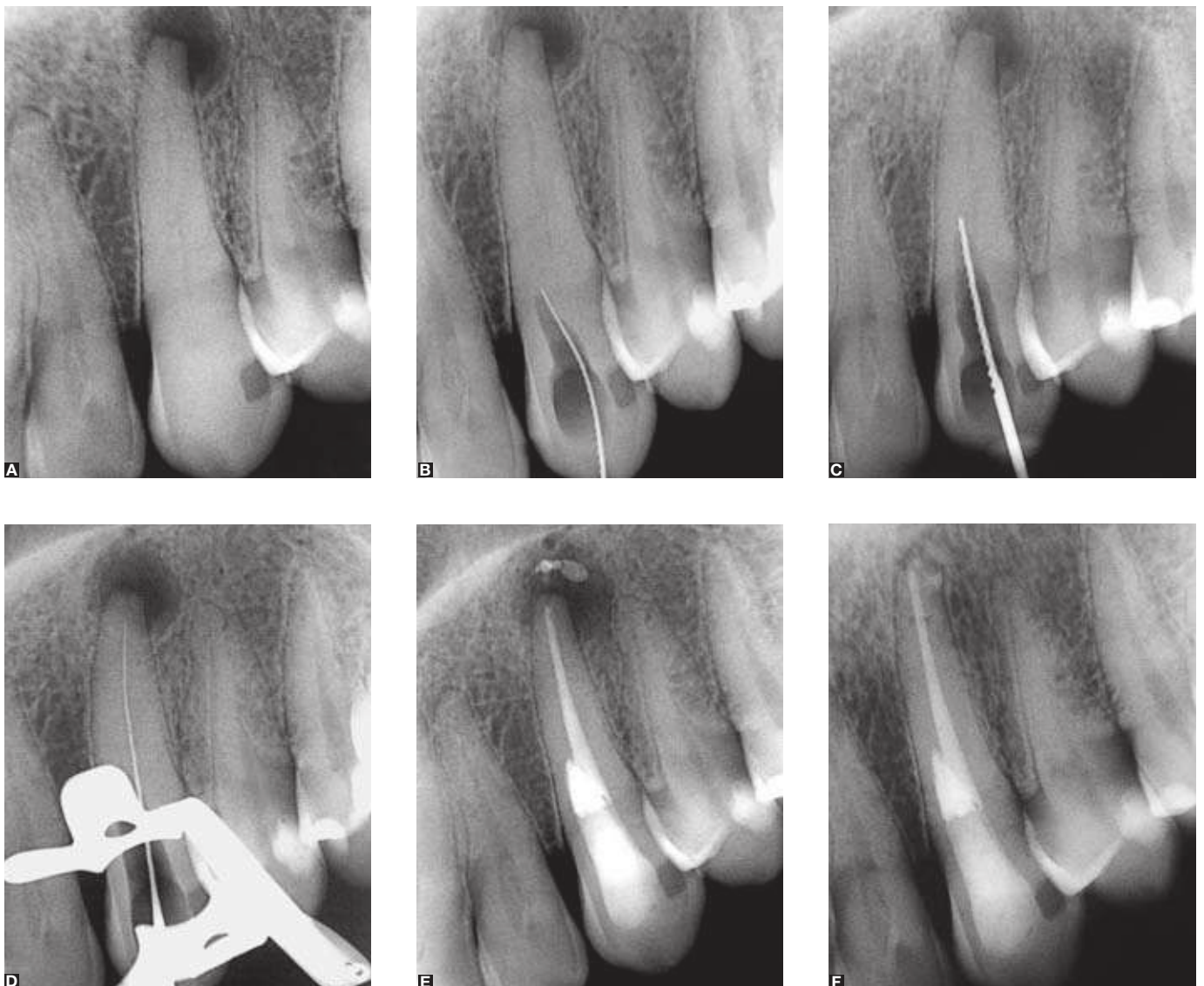


Figure 6. The appearing of the chronic periapical lesion occurred as it happens in approximately 25% of the cases of Calcific Metamorphosis of the Pulp (A). The endodontic treatment of teeth with Calcific Metamorphosis of the Pulp compose a risky maneuver due to the high probability of lateral trepanning of the root. In this clinical case almost occurred a trepanning of the maxillary canine (B and C), what was avoided with the aid of more experienced professionals, allowing to reach the apical foramen and fill the canal (D and E). After three years of control the regression of the associated chronic periapical lesion can be noticed (F).

endodontic treatment should be prescribed (Figs 2 and 3) followed by specific external bleaching of the affected tooth or internal bleaching if this is the most adequate option according to the endodontist's evaluation.

If the diagnosis is calcific metamorphosis of the pulp, there may be total obliteration of the pulp chamber and canal with or without periapical lesion. In this case, the best option is endodontic surgery and root-end obturation (Figs 5 and 6)^{2,22,23} or specific external bleaching for the affected tooth.

Several patients refuse to undergo endodontic surgery (Figs 5 and 6) at first, and request only bleaching of the affected tooth. Bleaching, in these cases, has temporary results, and discoloration returns in one to three years, when other bleaching procedures may be conducted. Another option may be the manufacture of veneers or crowns, a more stable and long-lasting solution. In such cases, the patient should be followed up yearly for radiographic control of chronic periapical lesions.

Final considerations

Isolated discoloration of teeth with structurally intact mineralized tissues strongly suggests the diagnosis of calcific metamorphosis or aseptic necrosis of the pulp. Any clinical procedure for these teeth, either a simple bleaching procedure or the placement of crowns or veneers, should be preceded by careful clinical and radiographic evaluations.

If not previously evaluated, any esthetic solution may be temporary and harmful for the patient, because the teeth may have aseptic necrosis or calcific metamorphosis of the pulp, which progress into chronic periapical lesions. Root resorptions, substantial loss of bone, and systemic repercussions due to these long-lasting chronic periapical lesions may be associated with this progressive condition.

References

1. American Association of Endodontics. Glossary: Contemporary Terminology for Endodontics. 6th ed. Chicago: AAE, 1998.
2. Amir FA, Gutmann JL, Witherspoon DE. Calcific metamorphosis: a challenge in endodontic diagnosis and treatment. *Quintessence Int.* 2001;32(6):447-55.
3. Cleen, M. Obliteration of pulp canal space after concussion and subluxation: endodontic considerations. *Quintessence Int.* 2002;33(9):661-9.
4. Consolaro A. Reabsorções dentárias nas especialidades clínicas. 2nd ed. Maringá: Dental Press; 2005.
5. Consolaro A. A Odontologia estética como causa e solução da reabsorção cervical externa: a importância do traumatismo dentário. *Rev Dental Press Estét.* 2008 jan-mar;5(1):130-4.
6. Consolaro A. Metamorfose cálcica da polpa versus "Calcificações distróficas da polpa". *Rev Dental Press Estét.* 2008;5(2):130-5.
7. Consolaro A. Orthodontic treatment does not cause pulpal necrosis. *Dental Press Endod.* 2011 Apr-June;1(1):14-20.
8. Consolaro A, Bernardini VR. Metamorfose cálcica da polpa e necrose pulpar asséptica no planejamento ortodôntico. *Rev Dental Press Ortod Ortop Facial.* 2007;12(6):21-3.
9. Consolaro A, Consolaro MFM-O. Controvérsias na Ortodontia e Atlas de biologia da movimentação dentária. Maringá: Dental Press; 2008.
10. Consolaro A, Francischone LA, Consolaro RB, Carraro EAS. Escurecimento dentário por metamorfose cálcica da polpa e necrose pulpar asséptica. *Rev Dental Press Estét.* 2007;4(4):124-33.
11. Consolaro A, Santamaria Jr M, Consolaro RB, Francischone LA. Movimento ortodôntico, disjunção palatina e metamorfose cálcica da polpa: um exemplo clínico de uma relação coincidental. *Rev Clín Ortod Dental Press.* 2010 out-nov;9(5):105-10.
12. Consolaro RB. Análise do complexo dentino-pulpar em dentes submetidos à movimentação dentária induzida em ratos [dissertação]. Bauri (SP): Universidade de São Paulo; 2005.
13. Holcomb JB, Gregory WB. Calcific metamorphosis of the pulp: its incidence and treatment. *Oral Surg Oral Med Oral Pathol.* 1967;24(6):825-30.
14. Massaro CS, Consolaro RB, Santamaria Jr M, Consolaro MF, Consolaro A. Analysis of the dentin-pulp complex in teeth submitted to orthodontic movement in rats. *J Appl Oral Sci.* 2009;17 Suppl:35-42.
15. Mjor I. Pulp-dentin biology in restorative dentistry. Chicago: Quintessence Books; 2002.
16. Oginni AO, Adekoya-Sofowora CA. Pulpal sequelae after trauma to anterior teeth among adult Nigerian dental patients. *BMC Oral Health.* 2007;7:11.
17. Oginni AO, Adekoya-Sofowora CA, Kolawole KA. Evaluation of radiographs, clinical signs and symptoms associated with pulp canal obliteration: an aid to treatment decision. *Dent Traumatol.* 2009 Dec;25(6):620-5.
18. Pissiotis A, Vanderas AP, Papagiannoulis L. Longitudinal study on types of injury, complications and treatment in permanent traumatized teeth with single and multiple dental trauma episodes. *Dent Traumatol.* 2007;23(4):222-5.
19. Robertson A. A retrospective evaluation of patients with uncomplicated crown fractures and luxation injuries. *Endod Dent Traumatol.* 1998;14(6):245-56.
20. Robertson A, Robertson S, Norén JG. A retrospective evaluation of traumatized permanent teeth. *Int J Paediatr Dent.* 1997;7(4):217-26.
21. Robertson A, Andreasen FM, Andreasen JO, Norén JG. Long-term prognosis of crown-fractured permanent incisors. The effect of stage of root development and associated luxation injury. *Int J Paediatr Dent.* 2000;10(3):191-9.
22. Schindler WG, Gullickson DC. Rationale for the management of calcific metamorphosis secondary to traumatic injuries. *J Endod.* 1988;14(8):408-12.
23. Smith JW. Calcific metamorphosis: a treatment dilemma. *Oral Surg Oral Med Oral Pathol.* 1982;54(4):441-4.
24. Stalhane I, Hedegard B. Traumatized permanent teeth in children aged 7-15 years. Part II. *Swed Dent J.* 1975;68(5):157-69.
25. Thoma KH, Robinson HBG. Oral and dental diagnosis, 5th ed. Philadelphia: Saunders; 1963.
26. Valladares Neto J. Análise microscópica do complexo dentino-pulpar e da superfície radicular externa após a expansão rápida da maxila em adolescentes [dissertação]. Goiânia (GO): Universidade Federal de Goiás; 2000.

Contact address:
Alberto Consolaro - E-mail: consolaro@uol.com.br