

Modern endodontic microsurgery treatment improves the outcome of challenging cases: A series report

Warley Luciano Fonseca **TAVARES**¹
Renata Carvalho Portes **LOPES**¹
Luiz Carlos Feitosa **HENRIQUES**²
Gustavo Batista de **MENEZES**³
Antônio Paulino **RIBEIRO SOBRINHO**⁴

ABSTRACT

Objective: The aim of this report was to describe challenging cases of modern endodontic microsurgery in teeth with persistent periodontitis following previous endodontic treatment. **Methods:** Four challenging cases of modern endodontic microsurgery were evaluated. **Results:** Healing has occurred at 6 and 12-month review appointments. **Conclusion:** The removal of the contami-

nation and satisfactory sealing of the root canal system were paramount for the success observed in these cases. Modern microsurgery protocol with the use of a magnified view, ultrasonic tips and biocompatible materials are an important component of endodontic surgery, improving the success when compared to traditional technique.

Keywords: Root canal therapy. Biocompatible materials. Dental infection control. Microsurgery.

How to cite this article: Tavares WLF, Lopes RCP, Henriques LCF, Menezes GB, Ribeiro Sobrinho AP. Modern endodontic microsurgery treatment improves the outcome of challenging cases: A series report. *Dental Press Endod.* 2011 July-Sept;1(2):81-8.

» The authors report no commercial, proprietary, or financial interest in the products or companies described in this article.

¹Professor of the Endodontics specialization course of the Institute of Health Studies (IES), Belo Horizonte, Brazil.

²Adjunct Professor of Dentistry, Federal University of Minas Gerais (UFMG).

³Adjunct Professor of Biological Sciences, Federal University of Minas Gerais (UFMG).

⁴Adjunct Professor, Federal University of Minas Gerais (UFMG).

Received: July 12, 2011. Accepted: July 21, 2011.

Contact address: Warley Luciano Fonseca Tavares
Universidade Federal de Minas Gerais – 31.270-901 – Belo Horizonte / MG - Brazil
E-mail: warleyt@hotmail.com

Introduction

Once conventional endodontic treatments have failed, surgical endodontic treatment is an option for teeth with apical periodontitis.¹ The aim of this procedure is to remove the root canal infection and create a seal using a biocompatible material to prevent possible bacterial leakage. Over the years, traditional surgical root canal treatment has been performed by root-end resection with a 45-degree bevel, retrograde preparation of the canal with burs and root-end filling.² The success rate of this procedure, however, has been demonstrated to be only moderate (60%).^{3,4} The use of unsuitable surgical instruments, inadequate vision, and frequent postoperative complications often result in tooth extraction.

In the late 1990s, the introduction of magnified vision, microinstruments, ultrasonic tips, and more biologically acceptable root-end filling materials marked the beginning of the modern endodontic microsurgery era. The use of microsurgery in surgical endodontic cases is an attempt to minimize trauma and improve results.⁵ With these developments, greater understanding of the apical anatomy has been gained, and a success rate of over 90% has been reported.^{6,7,8}

We report here a series of cases of modern endodontic microsurgery in teeth with persistent periodontitis and significant bone loss following previous endodontic treatments.

Case Reports

Case 1

A 52-year-old female patient was referred to a private dental office for an evaluation of swelling associated with a fistula on the apical portion of the second left maxillary premolar. According to the patient, symptoms had been present for 12 years (Fig 1A). Endodontic treatment had been performed unsuccessfully twice previously, leaving the patient with sporadic pain and facial discomfort. Clinically, the mobility and probing depth of the tooth were within normal limits. A percussion test showed no discomfort, and occlusal disharmony was not detected. Radiographic examinations revealed a uniform radiolucent lesion surrounding the root with a radius of approximately 10 mm (Fig 1B). Radiographic images showed that the original path of the

root canal had deviated and that apical perforation had occurred. Despite having been treated twice, the root canal filling was unsatisfactory, which led to the decision to perform endodontic retreatment with periapical microsurgery in order to establish satisfactory periapical healing.

An access cavity was created, and the tooth was isolated with a rubber dam. Briefly, the root canal filling was removed using rotary NiTi files (ProTaper Universal Retreatment®, Ballalgues, Switzerland) without any solvent. The canal was chemomechanically instrumented with NiTi rotary files (ProTaper Universal®, Ballalgues, Switzerland) and 2.5% sodium hypochlorite, and calcium hydroxide with 2% aqueous chlorhexidine paste was inserted as root canal dressing. After 21 days, the paste was removed, and the root canal was sealed using Tagger's hybrid technique. During thermoplastic condensation, sealer was scattered in the lesion (Fig 1C). Subsequently, the access cavity was restored with composite resin. After 10 days, the fistula was still present.

A Newman's surgical access flap was created (Fig 1D), and curettage of the periapical lesion was conducted (Fig 1E). The presence of perforation in the apical root surface was confirmed. A 3-mm apical resection was then performed without a bevel in an attempt to remove apical ramifications, lateral canals and necrotic, infected tissue (Fig 1F). A magnified view revealed anatomical details of the canal system, including an isthmus created by deviation between the anatomic and surgical canal during the initial root canal treatment. A cavity was prepared using an ultrasonic tip under copious irrigation with sterile saline to unify the perforation and the original canal path. The cavity was then filled with white mineral trioxide aggregate (MTA) (WMTA - Angelus, Londrina- Brazil), which was inserted using a small amalgam carrier and condensers (Fig 1G). After the excess material was removed and the surgical site was cleaned, the flap was repositioned and sutured. The extracted periapical lesion was histopathologically evaluated and diagnosed as a regular cystic inflammatory lesion. After one month, improvement was observed in the patient's clinical signs and symptoms, and one year later, radiographic evaluation showed an intact periodontal ligament (Fig 1I).

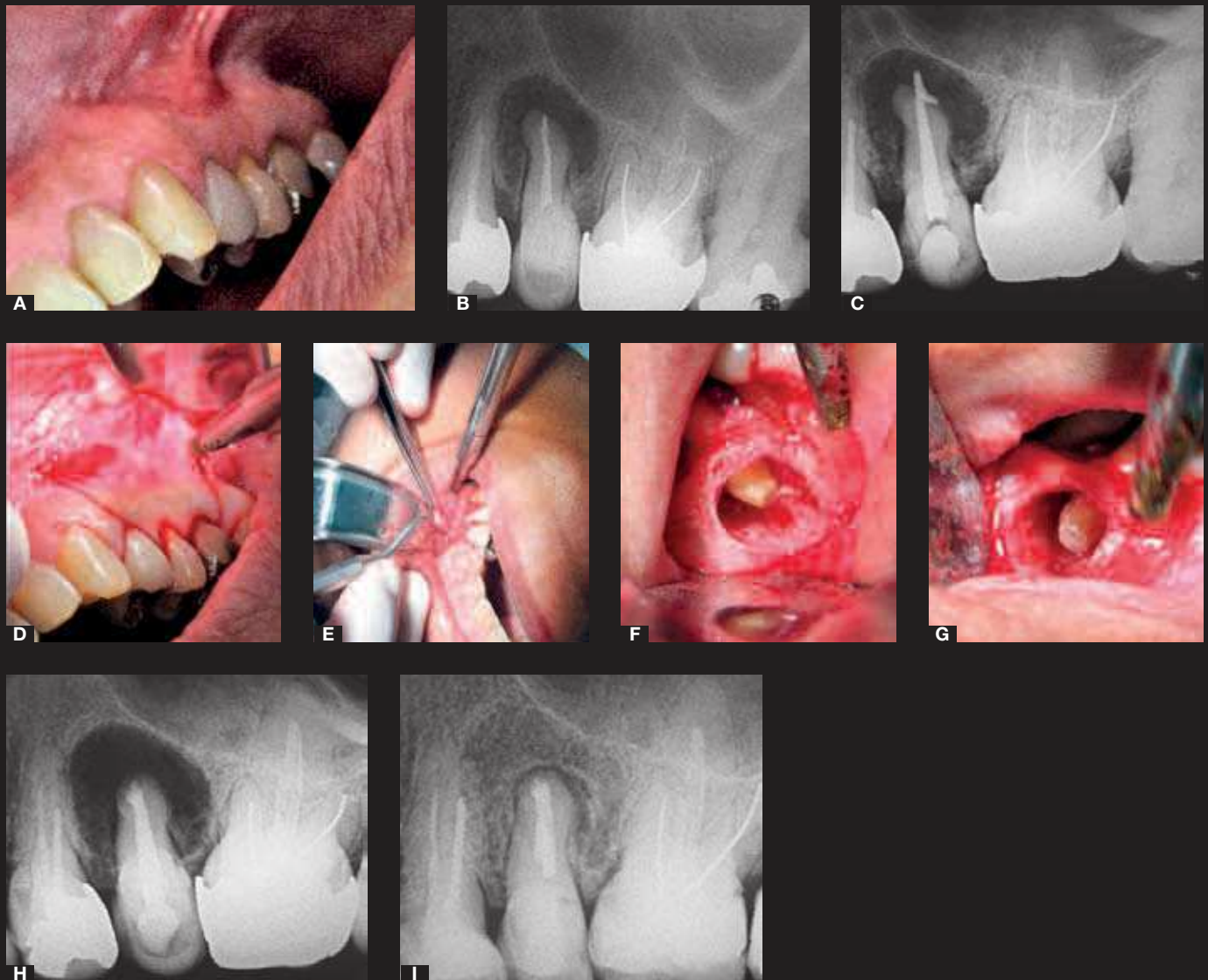


Figure 1. A) Initial clinical presentation including the presence of swelling associated with a fistula on the left maxillary second premolar. B) Periapical X-ray of tooth #25 showing a deviation in the root canal trajectory and unsatisfactory root canal filling prior to root canal retreatment. C) Periapical radiograph after thermoplastic condensation using Tagger's hybrid technique. D) Newman's incision (E) and excision of the periapical lesion. F, G) Apicoectomy without beveling and retrofilling with white MTA. H) Periapical X-ray showing the extension of bone loss after surgery. I) Radiograph showing significant signs of bone healing at one year postoperative.

Case 2

A 32-year-old woman patient was referred for endodontic assessment following severe pain one month after root canal treatment of the tooth #24. The periapical radiograph revealed a fractured endodontic instrument and periapical radiolucency (Fig 2A). The tooth was treated under the same protocol as described for Case 1. During apical root canal assessment with ultrasonic tips, it could be noticed two fractured instruments. They were removed

and the retro-preparation realized with the ultrasonic tips. The retro-filling was realized with MTA. After the excess material was removed and the surgical site was cleaned, the flap was repositioned and sutured. The definitive diagnosis from the pathology report was periapical granuloma. As shown in Figure 2B, a 6 month postoperative radiograph shows an apical plug of MTA with an interconnecting isthmus. At the 6 month review the tooth was completely asymptomatic and satisfactory healing could be appreciated.

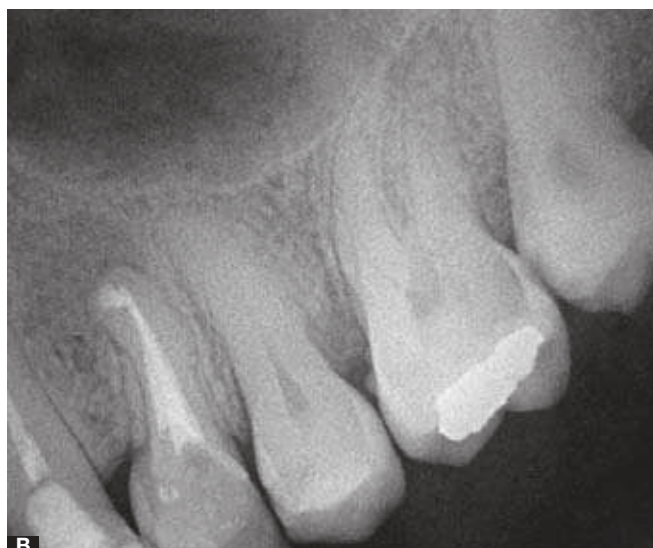
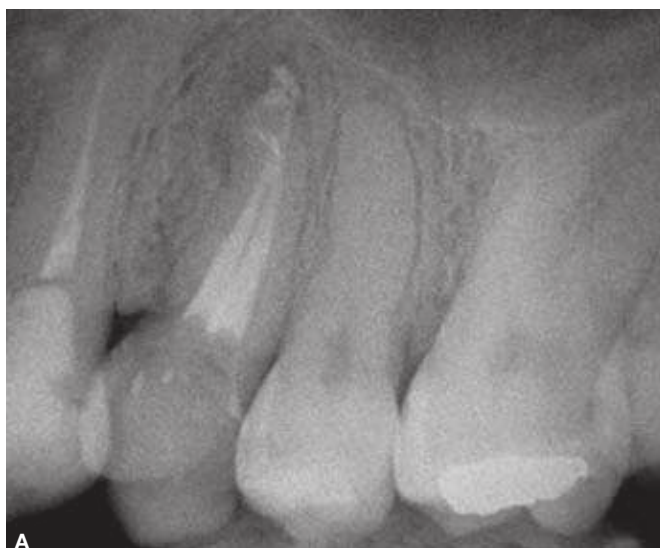
Figure 2. A) Pre-operative radiograph. A fractured endodontic instrument can be noticed. The patient was experiencing pain and discomfort after root canal sealing. B) Six month review radiograph. It can be noticed the MTA apical plug in surgical canal path. Satisfactory healing can be appreciated.

Case 3

A 35-year-old woman patient was referred for endodontic assessment. She was experiencing intense pain. According to patient's report, she had experienced an episode of facial trauma four years earlier. The patient had been previously submitted to an endodontic emergency procedure, and the lateral incisor had been accessed (Figs 3A and B). According to clinical exam, the adjacent teeth were in healthy conditions. During endodontic assessment, it could be noticed an intense exudation with a citric orange fluid, indicating a cystic inflammatory pathology. Three clinical appointments (30 days intervals) with change of root canal dressing (calcium hydroxide with 2% aqueous chlorhexidine paste) were performed. As exudation was still persistent after this period, the surgery was indicated. As the lesion involved both adjacent teeth, it was decided to perform the endodontic treatment of all the three involved elements before surgical procedure. The canals

were chemo-mechanically instrumented with NiTi rotary files (ProTaper Universal®, Ballalugues, Switzerland) and 2.5% sodium hypochlorite and sealed using Tagger's hybrid technique. A surgical access flap was created and curettage of the periapical lesion was conducted carefully, as the lesion presented a communication with nasal cavity. With magnified view, an area of root resorption could be noticed. Apical plastic resection was conducted in order to remove irregularities that would harbor microorganisms. As the microscopic view demonstrated an excellent apical sealing in the lateral incisor after root resection, with the absence of isthmus or micro-cracks, other root-end procedures were no longer necessary. The definitive diagnosis from the pathology report was periapical inflammatory cyst. At the 6 month review appointment, the signals had completely disappeared and the tooth was asymptomatic. At the radiographic examination, it could be observed a satisfactory healing (Figs 3D and E).

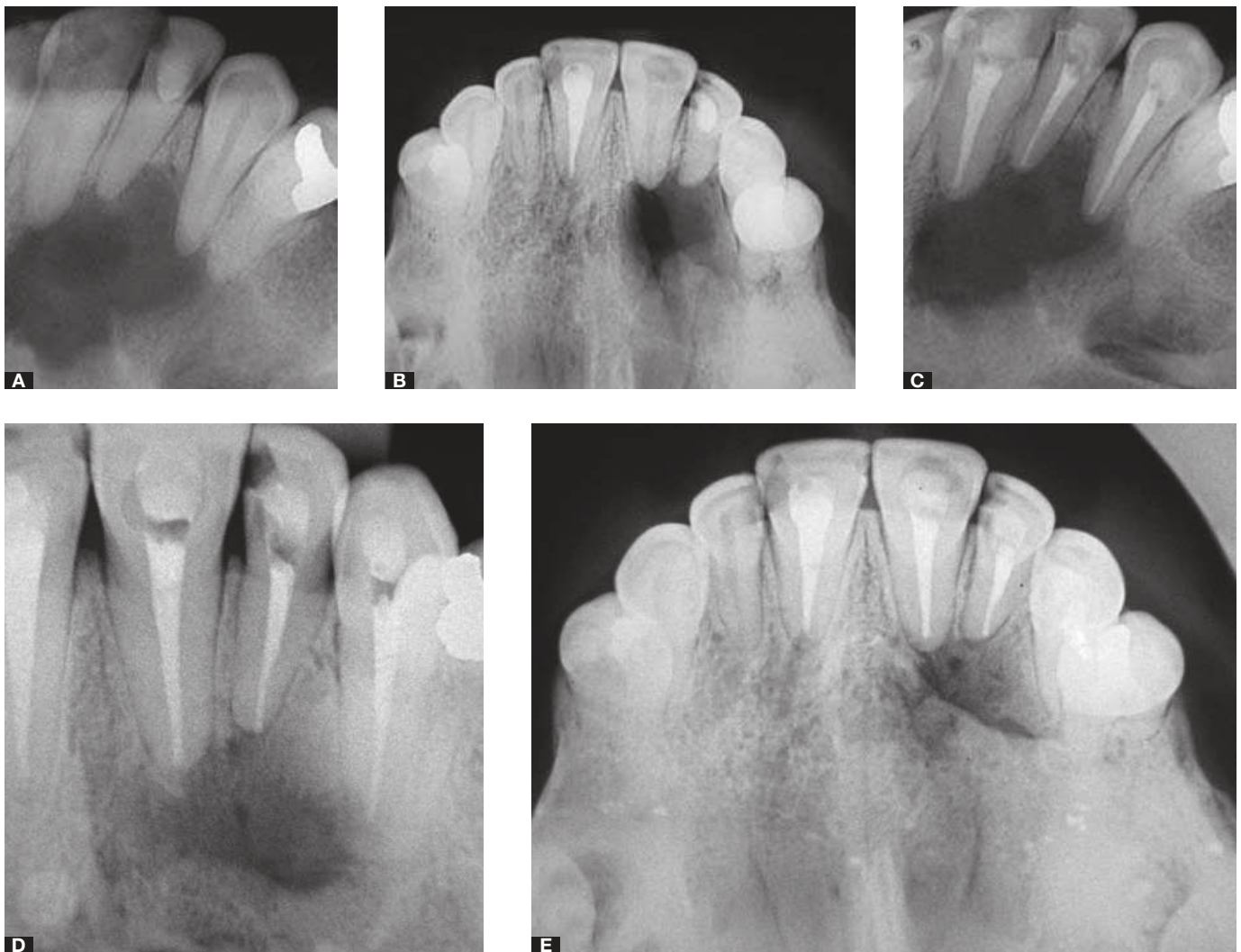


Figure 3. A) Pre-operative radiograph. Presence of severe maxillary bone resorption. Patient presented swelling and pain. B) Occlusal radiograph. C) Pre-operative radiograph after root canal treatment. Absence of healing can be noticed. D) Six month review radiograph. A satisfactory healing can be appreciated. E) Six month review occlusal radiograph.

Case 4

A 45-year-old man patient was referred for endodontic assessment. In radiographic examination, it was observed an extended periapical lesion involving the central inferior incisors. The patient was asymptomatic and no swelling was observed. Endodontic treatment was performed according to the protocol previously described in Case 3. After 6 month follow-up, the lesion was still present without any sign of healing and apical surgery was indicated. A Newman's surgical access flap was created, and curettage of the periapical lesion was conducted (Fig 4B). Within magnified view, it was observed a lack of apical sealing.

A 3-mm apical resection was then performed without a bevel angle in an attempt to remove apical ramifications, lateral canals and necrotic, infected tissue. Using magnified examination, it could be noticed a satisfactory sealing of guta-percha, without any gaps. The flap was repositioned and suture was performed. The definitive diagnosis from the pathology report was periapical granuloma. At the six month follow-up appointment, the teeth were completely asymptomatic. In the radiographic examination it could be observed a partial healing (Fig 4E). At the 12-month review the teeth were asymptomatic and the periapical radiograph revealed a favorable healing outcome (Fig 4F).

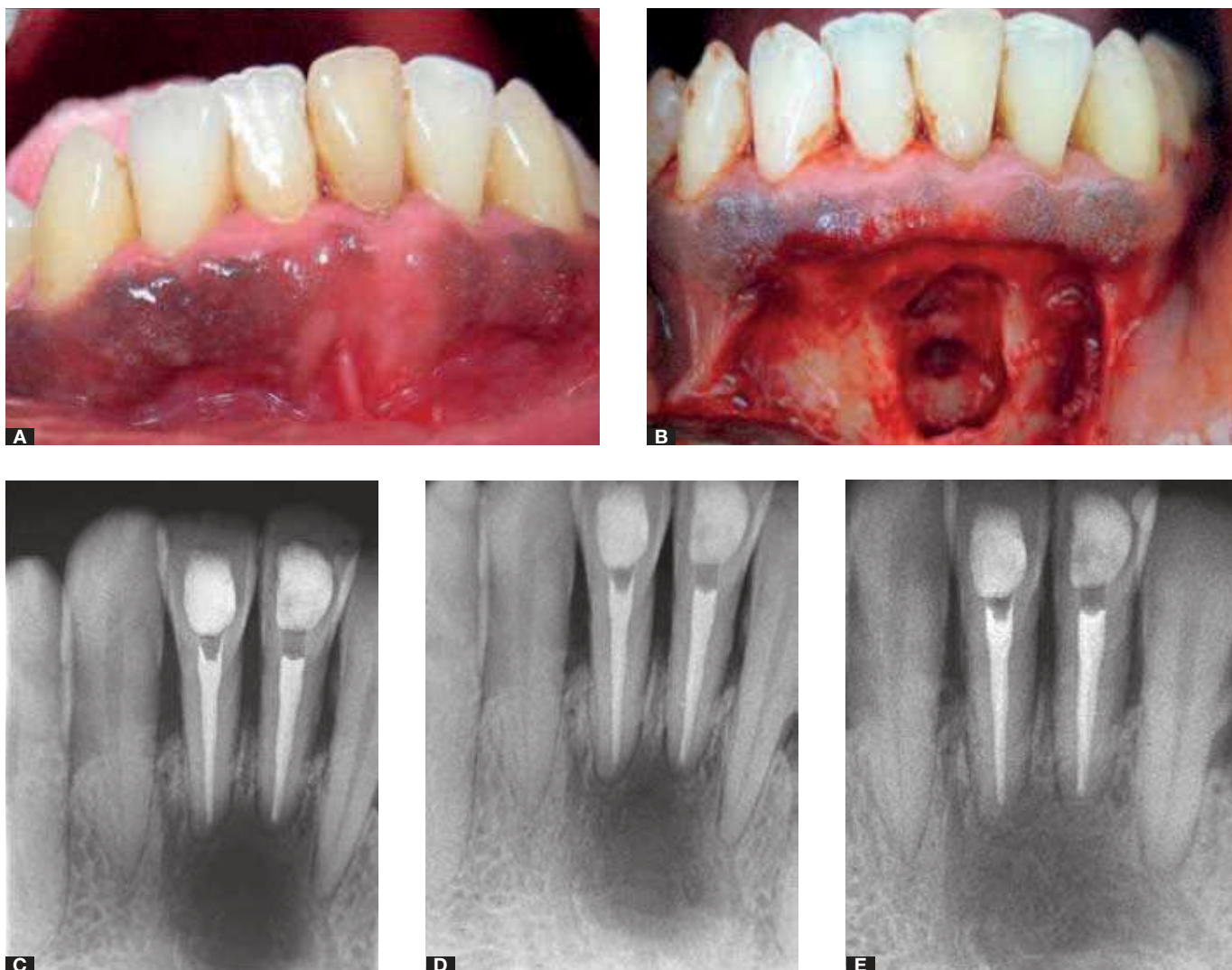


Figure 4. A) Pre-operative clinical aspect. B) Newman's surgical access flap. Clinical aspect after bone lesion curettage and 3 mm apicoectomy. C) Immediate post-operative radiograph. D) Six month review radiograph. E) Twelve month review radiograph.

Discussion

The complexity of the root canal system may not allow for predictable success rates of all endodontic treatments. The presence of ramifications and lateral canals can sustain microorganisms and impair the healing process, making root-end resection an important step in endodontic surgery. The success of endodontic surgery, however, is intimately related to the quality of conventional endodontic treatment. If this quality is unsatisfactory, then the prognosis of surgery is uncertain. A 2 mm apical resection accounts for a 78% and 86% reduction in the frequency of apical ramifications and lateral canals, respectively.⁹ In Case 1, the root canal was retreated, and during

microsurgery, in Cases 1, 2 and 4, root resection was performed in the last apical 3 mm as recommended by Kim et al.⁹ These authors observed a 98% and 93% reduction in the frequency of apical ramifications and lateral canals, respectively, using this approach.

In traditional endodontic surgery, a typical apical resection used to be performed with a 45- to 60-degree bevel to achieve a better vision and access during the procedure.^{2,10} Because the instruments used to retrogradely prepare the canal were large, a bevel angle was inevitable. In fact, larger root resections may weaken the root structure and cause unnecessary periapical tissue removal.¹¹ In addition, beveled angles expose a larger amount of dentinal tubules to

periapical tissues, which may increase contact between the remaining bacteria in the tubules and periapical tissues.

In modern endodontic microsurgery protocols, however, minimal or no bevel is typically used in root resection.¹² Given that the ultrasonic tips used in retrograde preparation do not require a large osteotomy or bevels due to the design of the instruments, the structure of the root is preserved. In the same way, the original root canal trajectory is maintained more efficiently during retrograde preparation with ultrasonic tips than with burs, achieving deeper, more effective debridement of the root canals.

With the advent of microscopes and loupes, as well as specifically designed micro-mirrors, a more detailed view of apical anatomy can be obtained. The presence of an isthmus, collateral canals, ramifications, cracks, and other varied anatomy can now be easily identified during surgical procedures. Furthermore, the apical magnification associated with the use of ultrasonic tips

can provide more predictable results for retrograde cleaning and preparation. (Figs 5A and B). In Case 3, the use of magnified view was determinant in choosing the clinical approach. As it could be noticed absence of sealing gaps, canal ramifications, isthmus, or micro-cracks after apical resection, a more conservative procedure could be performed, without the necessity of ultrasonic retrograde preparation.

Root-end prepared cavities must be filled with a biocompatible material. In this study, MTA was chosen based on its biological and physical properties.¹³⁻¹⁷ In addition, MTA promotes the overgrowth of cementum and bone formation, inducing regeneration of the periodontal ligament.¹⁸ Moreover, no significant differences have been observed in microsurgery results using MTA compared to IRM.¹⁹ Still, modern surgical endodontic treatment using an operative microscope and ultrasonic tips significantly improves the prognosis of the tooth compared to traditional techniques.¹²

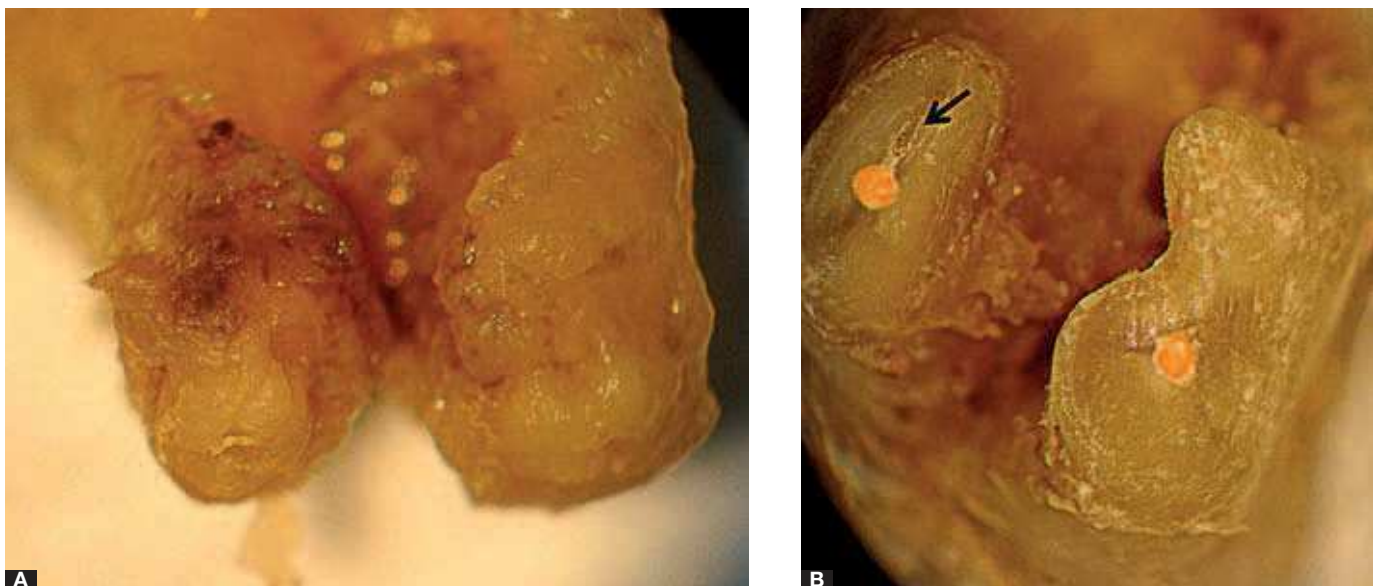


Figure 5. **A)** Apical view of a freshly extracted tooth presenting lesion refractory to endodontic microsurgery. The procedure was performed without the use of the modern surgery protocol. **B)** After apical extracted tooth curettage, magnified view demonstrates an isthmus in distal root canal (arrow). The absence of apical sealing was the cause of surgery insuccess.

Conclusion

We attribute the success observed in these cases to removal of the contamination and satisfactory sealing of root canal system. Additionally, the results reinforce the use of a modern microsurgery protocol with a magnified view, ultrasonic tips and biocompatible materials as an important component of endodontic surgery.

References

1. Cohn SA. When all else fails... *Aust Endod J.* 1998;24(3):128-9.
2. Gutmann JL, Harrison JW. Periradicular curettage, root-end resection, root-end filling. In: Guttmann JL, Harrison JW, editors. *Surgical endodontics.* Boston: Blackwell Scientific Publications; 1991. p. 208-13.
3. Allen RK, Newton CW, Brown CE Jr. A statistical analysis of surgical and nonsurgical endodontic retreatment cases. *J Endod.* 1989;15:261-6.
4. Friedman S. Treatment outcome and prognosis of endodontic therapy. In: Ørstavik D, editor. *Essential endodontology: prevention and treatment of apical periodontitis.* Oxford: Blackwell Science; 1998. p. 367-401.
5. Velvart P, Peters CI. Soft tissue management in endodontic surgery. *J Endod.* 2005;31:4-16.
6. Rubinstein RA, Kim S. Short-term observation of the results of endodontic surgery with the use of surgical operation microscope and Super-EBA as root end filling material. *J Endod.* 1999; 25(1):43-8.
7. Rubinstein RA, Kim S. Long-term follow-up of cases considered healed one year after apical microsurgery. *J Endod* 2002;28(5):378-83.
8. Zuolo ML, Ferreira MO, Gutmann JL. Prognosis in periradicular surgery: a clinical prospective study. *Int Endo J.* 2000; 33(2):91-8.
9. Kim S, Pecora G, Rubinstein R. Comparison of traditional and microsurgery in endodontics. In: Kim S, Pecora G, Rubinstein R, editors. *Color atlas of microsurgery in endodontics.* Philadelphia: W.B. Saunders; 2001. p. 5-11.
10. Rud J, Andreasen JO. A study of failures after endodontic surgery by radiographic, histologic and stereomicroscopic methods. *Int J Oral Surg.* 1972;1:311-28.
11. Kim S, Kratchman S. Modern endodontic surgery concepts and practice: a review. *J Endod.* 2006;32(7):601-23.
12. Tsesis I, Rosen E, Schwartz-Arad D, Fuss Z. Retrospective evaluation of surgical endodontic treatment: traditional versus modern technique. *J Endod.* 2006;32(5):412-6.
13. Torabinejad M, Rastegar AF, Kettering JD, Pitt Ford TR. Bacterial leakage of mineral trioxide aggregate as a root-end filling material. *J Endod.* 1995;21(3):109-12.
14. Torabinejad M, Chivian N. Clinical applications of mineral trioxide aggregate. *J Endod.* 1999;25:197-205.
15. Baek SH, Plenck H, Kim S. Periapical tissue responses and cementum regeneration with amalgam, superEBA, and MTA as root-end filling materials. *J Endod.* 2005;31(6):444-9.
16. Bernabé PFE, Gomes-Filho JE, Rocha WC, Nery MJ, Otoboni-Filho JA, Dezan-Júnior E. Histological evaluation of MTA as a root-end filling material. *Int Endo J.* 2007;40(10):758-65.
17. Yoshimine Y, Ono M, Akamine A. In vitro comparison of the biocompatibility of Mineral Trioxide Aggregate, 4META/MMA-TBB resin, and intermediate restorative material as root-end-filling materials. *J Endod.* 2007;33:1066-9.
18. Torabinejad M, Pitt Ford TR, McKendry DJ, Abedi HR, Miller DA, Kariyawasam SP. Histologic assessment of Mineral Trioxide Aggregate as a root-end filling in monkeys. *J Endod.* 1997;23(4):225-8.
19. Chong BS, Pitt Ford TR, Hudson MB. A prospective clinical study of Mineral Trioxide Aggregate and IRM when used as root-end filling materials in endodontic surgery. *Int Endod J.* 2003;36(8):520-6.