

A histological assessment of dentine, after the clinical removal of caries in extracted human teeth

Danielle Alves de **OLIVEIRA**¹
 João Carlos Gabrielli **BIFFI**²
 Camilla Christian Gomes **MOURA**³
 Eliseu Álvaro **PASCON**⁴

ABSTRACT

Introduction: Despite the evolution in the strategies used to prevent and treat dental caries, no consensus exists regarding the relationship among caries depth and bacterial contamination. **Objectives:** To analyze the depth of the carious lesion after clinical removal of carious dentin, and assess the presence, location and distribution of microorganisms in the dentinal tubules, in different degrees of the lesion depth. **Methods:** 20 carious human premolars were evaluated to determine the relationship among bacterial invasion and clinical carious degree using Brown and Brenn's bacterial stain. The data

were subjected to Pearson's correlation coefficient. **Results:** The correlation between the number of microorganisms found within the different caries degrees was considered slightly positive ($r = 0.038$). No correlation between the distribution and the location of microorganisms in different caries degrees was verified. **Conclusion:** The presence of microorganisms in critical areas, such as the enamel-dentin junction and in the deeper cavity floor suggests the influence of anatomical characteristics on caries pathology.

Keywords: Dental caries. Dentine. Microorganisms. Radiographic exam.

How to cite this article: Oliveira DA, Biffi JCG, Moura CCG, Pascon EA. A histological assessment of dentine, after the clinical removal of caries in extracted human teeth. *Dental Press Endod.* 2011 Oct-Dec;1(3):79-87.

» The authors report no commercial, proprietary, or financial interest in the products or companies described in this article.

¹Post Graduate Endodontic Student, Department of Endodontics, College of Dentistry, Federal University of Uberlândia, Minas Gerais, Brazil.

²Post Doctorate researcher of College of Dentistry, Federal University of Uberlândia, Minas Gerais, Brazil.

³Professor, CALABRODENTAL, Crotone, KR, Italy.

⁴Professor, Department of Endodontics, College of Dentistry, Federal University of Uberlândia, Minas Gerais, Brazil.

Received: November 16, 2011 / Accepted: November 21, 2011.

Contact address: João Carlos Gabrielli Biffi
 Universidade Federal de Uberlândia, Faculdade de Odontologia, Bloco 2B, sala 113
 Campus Umuarama - Uberlândia / MG - Brazil
 E-mail: jcgiffi@ufu.br

Introduction

When analyzing dental caries from a historical perspective, it can be seen the evolution in strategies used to prevent their development and the therapeutic strategies for treating them.^{1,2} However, no consensus exists regarding the caries depth and the accuracy in diagnosis methods^{3,4} or bacterial infection.⁵ Consequently, there are different approaches to treating dental caries.

The characteristic of carious dentin is a point of great controversy among researchers which influences the therapeutic strategy to be adopted.^{5,7,8} Appraisal of dentinal color and hardness — both of which are criteria for diagnostic procedures — is subjective, even when detector dye is used during caries removal.^{7,9} Despite these parameters do not allow an accurate assessment of the degree of bacterial infection and pulp injury, they are commonly used to support any particular intervention.^{9,10}

Although some studies point out that black or dark brown stained dentinal tissues generally indicate infected tissue, other studies report that natural stains do not always show significant amounts of bacteria.^{7,9,10} In spite of the difficulties in distinguishing the clinically affected dentin, the presence of microorganisms in dentinal tubules when caries are present is well established.^{11,12}

Several investigations were conducted to evaluate the microbial status of deep dentinal caries and the possible effects of these microorganisms in intact or decalcified dentin, as well as in the dental pulp.^{5,7,13} Though there is no consensus on the activity of remaining microorganisms inside the dentinal tubules, studies using bacteriological and histological methods have reported the persistence of bacteria in dentin even after the clinical removal of caries.^{5,8,14}

The existing controversy regarding microorganism viability in relation to the demineralization of dentin, its location, and pulp response^{5,11} leads to an increase in acceptance of the minimal-intervention dentistry observed in recent years.^{7,9} A greater understanding of the impact of specific carious sites on tooth pathology (as well as the relationship between bacterial penetration inside dentinal tubules and the clinical diagnosis) may help in making treatment decisions.

Hence, it was considered worthwhile to examine the remaining dentin of freshly extracted human

premolars after clinical removal of carious dentin for the presence, location, and distribution of microorganisms in the dentinal tubules in different degrees of lesion depth. It was hypothesized that the site and depth of the caries are strictly related to bacterial invasion inside dentinal tubules. The null hypothesis was that bacterial invasion of dentinal tubules is unrelated to clinical diagnosis of caries, using color and hardness criteria after excavation.

Materials and methods

In this study, 20 human upper premolars presenting proximal and/or occlusal caries recently extracted from 20 to 40 year-old patients for orthodontic or periodontal reasons were used (Table 1). The caries removal was done by a single calibrated operator. The bulk of carious dentin was removed using hand instruments followed by round low-speed burs (#2, #3, or #4). Throughout the entire clinical procedure, the cavity was irrigated with a saline physiologic solution. Carious tissue removal was considered complete when a probe running through the cavity floor demonstrated presence of hard dentin. The teeth were then split longitudinally in the mesiodistal direction using a sterile diamond disk under a jet spray of distilled water, taking care to reach both caries and pulp in the same cut. The hemi-split teeth were evaluated taking into account the enamel caries, and fixed in 10% buffered formalin solution for 24–48 hours.

The specimens were processed for routine histological examination, serial sections were cut with the microtome set at 5 µm thickness, and care was taken to obtain the whole carious lesion and the adjacent pulp tissue starting from the surface of each half of the tooth. Alternate slides were sequentially stained with Hematoxylin-Eosin, for general examination, and modified Brown and Brenn technique for bacteria stain.¹⁵

Analysis of Bacterial Stain and Carious Degree

In this study 60 surfaces (proximal and/or occlusal) of 20 specimens were evaluated. The caries degree was established after carious tissue removal by a single calibrated operator, according to the scores previously defined by Biffi et al:¹⁶ Absence of cavities (0), enamel caries (1), shallow cavity with up to 1/3 of dentin compromised (2), average decay up to 2/3 of dentin compromised (3), deep cavity with up to the

entire dentin compromised but no evidence of pulp exposure (4), and pulp exposure (5).

The presence or absence of microorganisms in dentinal tubules, the depth of penetration (superficial or deep), and the location of bacterial niches were evaluated.

For statistical analysis, the Pearson coefficient of correlation was used ($-1 \leq r \leq +1$) for the qualitative variables, presence of microorganisms, location in the enamel-dentinal junction and pulp floor, and caries degree, to discover a possible positive, negative, or faintly positive correlation.

Results

Of the 60 surfaces (proximal and/or occlusal) of the

20 evaluated specimens, 37 were clinically diagnosed as decayed: 10 were of Degree 1, 10 of Degree 2, 8 of Degree 3, 5 of Degree 4, and 4 of Degree 5. Table 1 summarizes the number of cases evaluated, caries depth, microorganisms found in dentinal tubules, and observations concerning the depth and location of the microorganisms in the cavity. In the 10 Degree 1 caries, the presence of microorganisms was detected in just 1. In cases 5, 8, and 10, even with loss of dentinal content, contaminated dentin was not detected. In the remaining specimens, in at least 1 of the carious surfaces per tooth, the presence of microorganisms inside the dentinal tubules was observed (Fig 1).

The correlation between the number of microorganisms found within the different caries grades was

Table 1. Number of teeth (cases), caries depth*, microorganisms found in dentinal tubules and observations concerning the depth and location in the cavity. (M = Mesial surface. O = Occlusal surface. D = Distal surface)

Case	Caries Depth*			Detected Microorganisms			Observations
	M	O	D	M	O	D	
01	0	1	0		x		Shallow penetration in the dentin-enamel junction (Fig. 1A-F).
02	2	0	1	x			(M) Deep penetrating the floor of the cavity and dentin-enamel junction. (D) Not detected (Fig. 2).
03	2	0	1	x			(M) Penetration on the floor surface and enamel-dentin junction. (D) Not detected.
04	1	0	4			x	(M) Not detected. (D) Penetration in the floor surface.
05	2	0	0				Microorganisms undetected.
06	4	0	3	x		x	(M and D) Penetration on the floor surface and enamel-dentin junction.
07	3	0	3	x			(M) Penetration on the floor surface and enamel-dentin junction. (D) Not detected.
08	3	0	0				Microorganisms undetected.
09	3	0	2	x			(M) Penetration on the floor surface. (D) Not detected.
10	2	0	0				Microorganisms undetected.
11	3	0	1	x			(M) Deep penetrating the floor and dentin-enamel junction. (D) Not detected.
12	2	3	1	x	x		(M) Deep penetrating the floor and dentin-enamel junction. (O) Penetration surface under restoration. (D) Not detected (Fig. 1G-K).
13	3	0	2	x			(M) Penetration on the floor surface and enamel-dentin junction. (D) Not detected.
14	1	0	1				Microorganisms undetected.
15	1	0	1	x			(M) Penetration at dentin-enamel junction. (D) Not detected.
16	5	0	2			x	(M) Not detected. (D) Penetration in the floor surface and enamel-dentin junction (Fig. 3A-F).
17	4	0	4	x		x	(M and D) Penetration in the limit of dentin-enamel junction.
18	5	0	4	x		x	(M) surface penetration on the floor and walls of the pulp chamber. (D) Penetration in the floor surface.
19	2		5	x		x	(M and D) Penetration on the floor surface and enamel-dentin junction (Fig. 3G-N).
20	2	0	5			x	(M) not detected. (D) Deep penetrating the floor and dentin-enamel junction.

* 0 = No caries, 1 = caries in enamel, 2 = shallow caries involving 1/3 the thickness of dentin, 3 = average decay involving 2/3 the thickness of dentin, 4 = deep cavity involving 3/3 the thickness of dentin without pulp exposure, and 5 = pulp exposure.

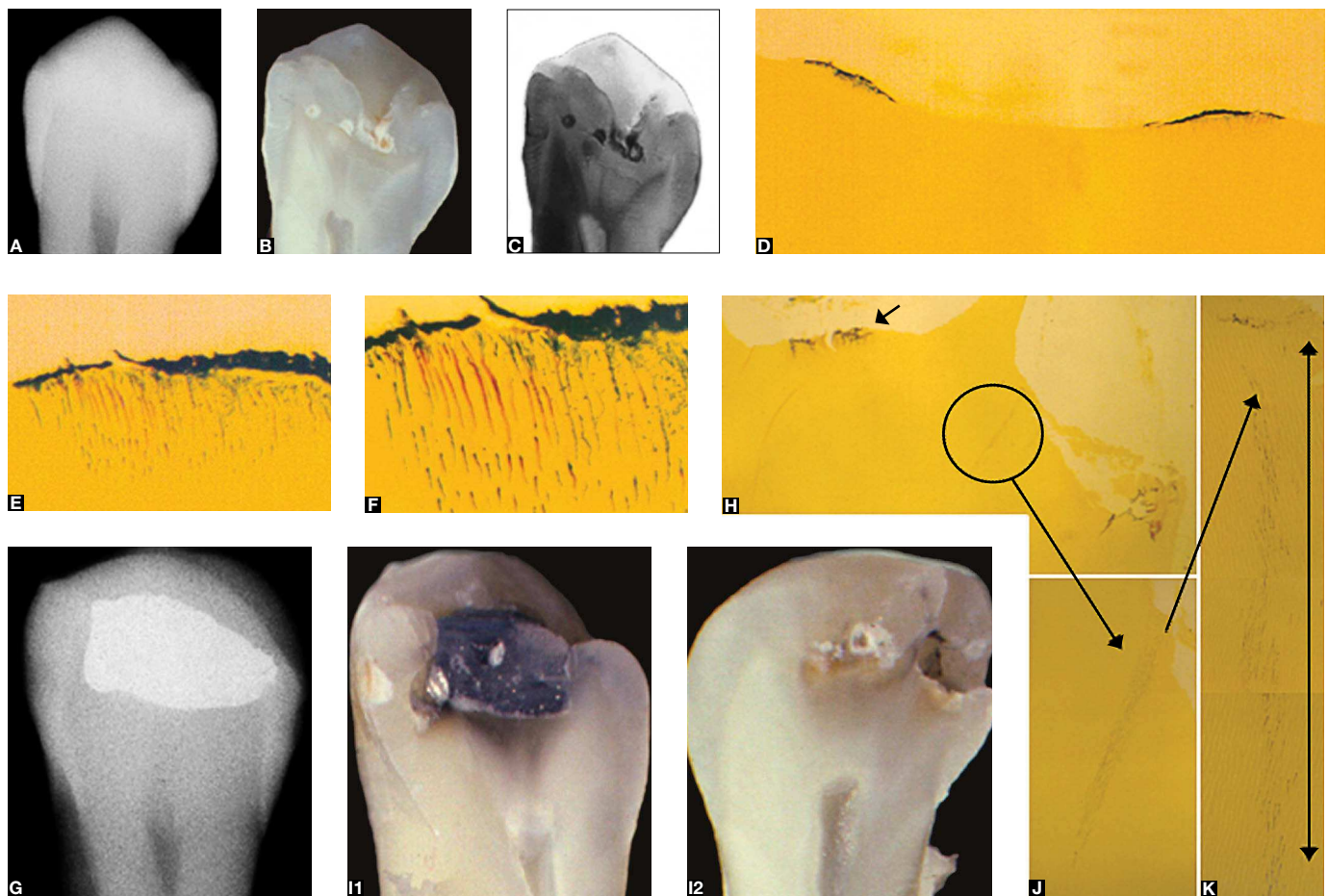


Figure 1. Illustrative images of cases evaluated in current research. Case 1 (A-F). A – Radiograph, diagnosis hypothesis – absence of occlusal caries. B – Longitudinal cut of teeth at center of pulp. Enamel caries evidence. C) Negative image of hemi-section, enamel caries confirmation. D) Microorganisms in dentin, subjacent to enamel caries (Brown e Brenn; original mag. 100X). E) Microorganisms in dentinal tubules after enamel caries removal (Brown e Brenn; original mag. 1000X). F) Microorganisms distribution, superficially (Brown e Brenn; original mag. 1000X). Case 12 (G-K). G - Radiograph, diagnosis hypothesis – proximal caries and occlusal amalgam. H) Microorganisms in mesial and occlusal surfaces subjacent to the amalgam restoration (Brown e Brenn; original mag. 100X). I) Longitudinal cut of teeth at center of pulp. Buccal hemi-section (I1) and lingual hemi-section (I2). J) Deep penetration (conical shape) of microorganisms in dentinal tubules after caries removal (Brown e Brenn; original mag. 400X). K) Higher magnification of H (circle) (Brown e Brenn; original mag. 400X).

considered faintly positive ($r=0.038$). This statistical finding confirms that the location and distribution of microorganisms in the dentinal tubules were varied and independent of the caries depth.

When the correlation between microorganisms found in different caries degrees and their distribution (superficial or deep) and location (enamel-dentin

junction and pulp floor) was established, the null correlation was verified, demonstrating that the location and distribution of microorganisms in areas considered critical in this study did not correlate to caries depth. Figures 2 and 3 illustrate the lack of correlation between the location of the microorganisms and classification of carious lesions.

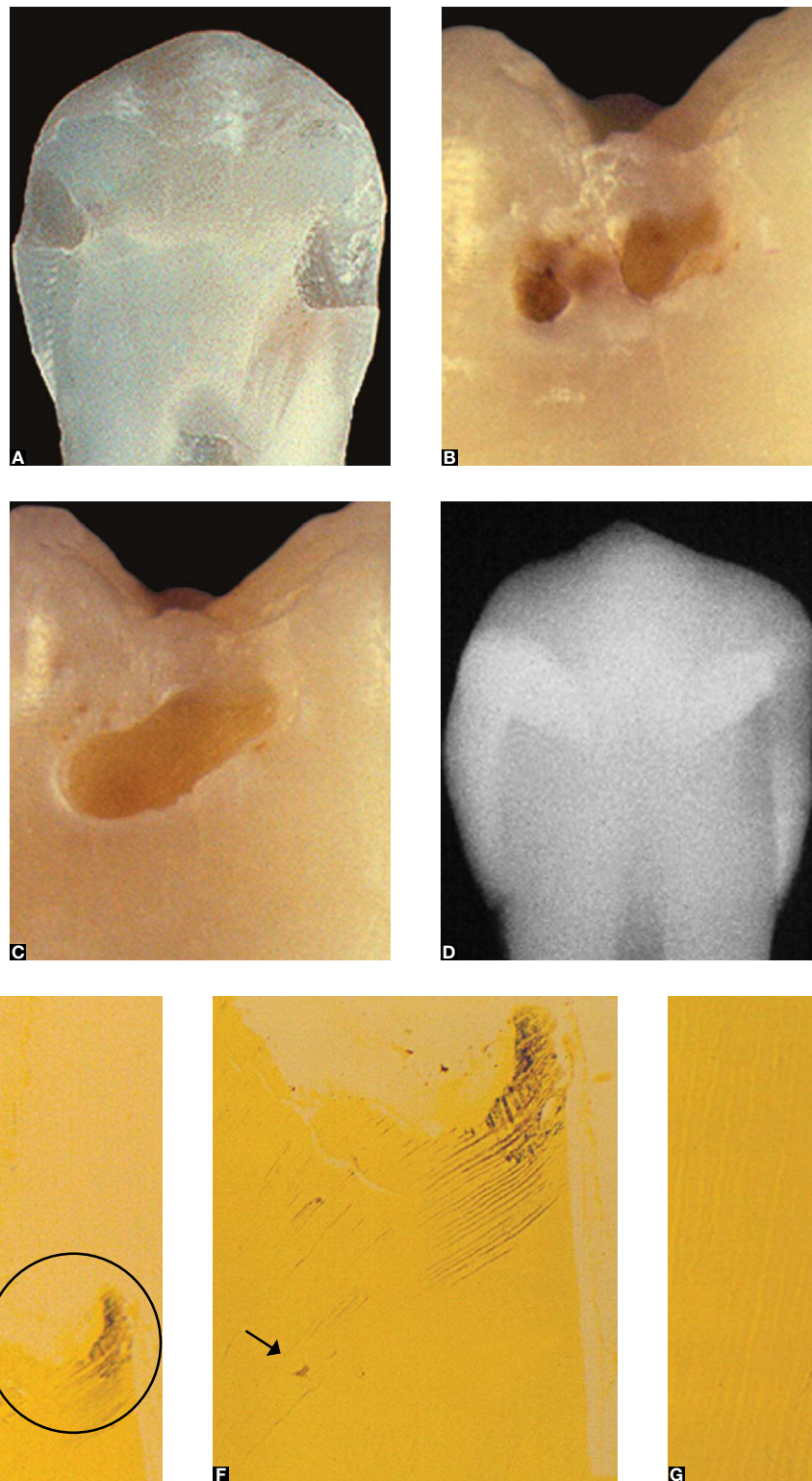


Figure 2. Illustrative images of cases evaluated in current research. Case 2 (A-G). **A**) Longitudinal cut of teeth at center of pulp. Hemi-section showing caries evidence at the bottom of cavity. **B**) Photograph of proximal caries. **C**) Photograph after caries removal. **D**) Radiograph, diagnosis hypothesis – deep proximal caries. **E**) Microorganisms in dentin (circle) (Brown e Brenn; original mag. 100X). **F**) After caries removal, deep penetration of microorganisms in dentinal tubules (Brown e Brenn; original mag. 100X). **G**) Higher magnification of F. Deep penetration in dentinal tubules (arrow) (Brown e Brenn; original mag. 400X).

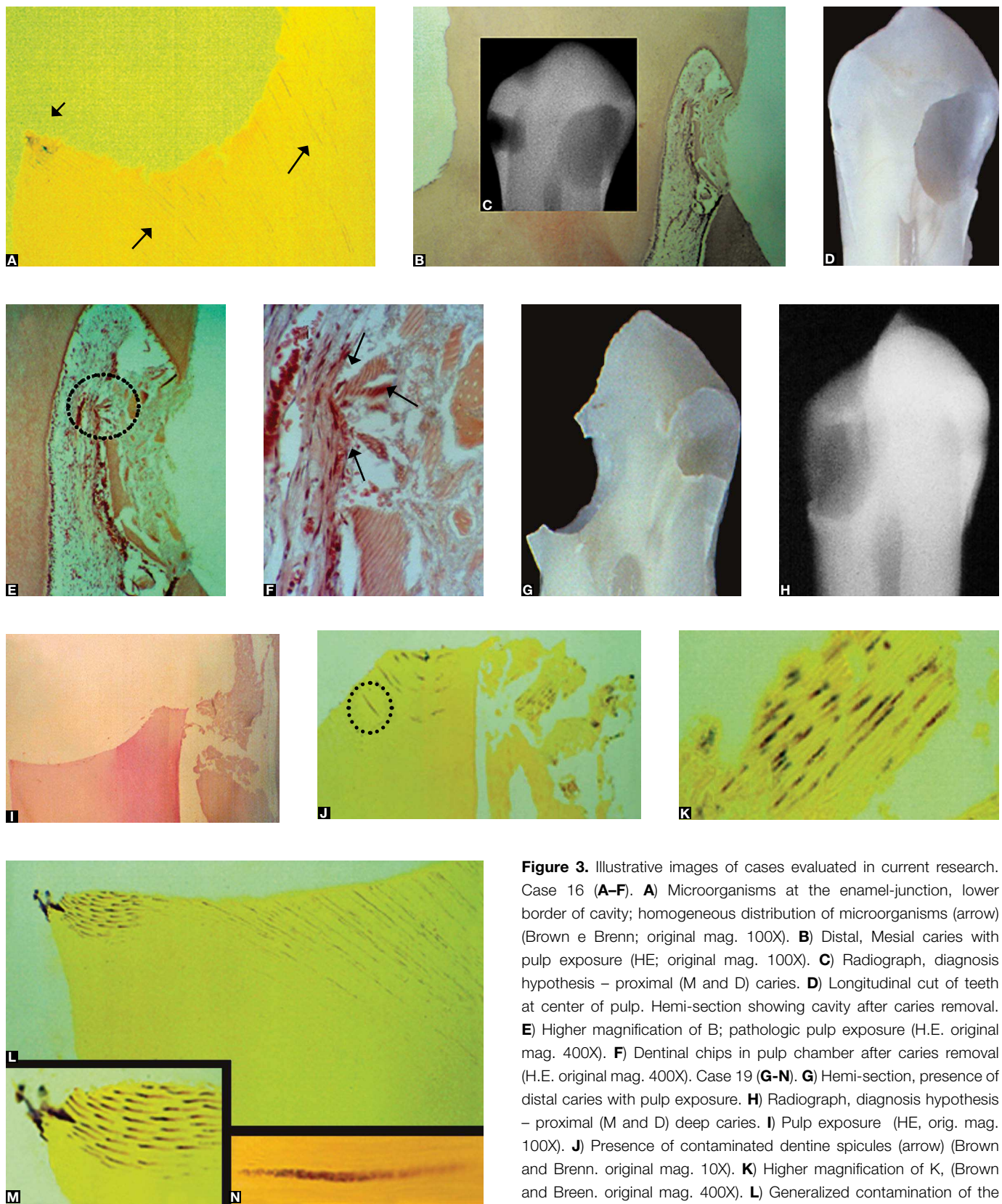


Figure 3. Illustrative images of cases evaluated in current research. Case 16 (**A-F**). **A**) Microorganisms at the enamel-junction, lower border of cavity; homogeneous distribution of microorganisms (arrow) (Brown e Brenn; original mag. 100X). **B**) Distal, Mesial caries with pulp exposure (HE; original mag. 100X). **C**) Radiograph, diagnosis hypothesis – proximal (M and D) caries. **D**) Longitudinal cut of teeth at center of pulp. Hemi-section showing cavity after caries removal. **E**) Higher magnification of B; pathologic pulp exposure (H.E. original mag. 400X). **F**) Dentinal chips in pulp chamber after caries removal (H.E. original mag. 400X). Case 19 (**G-N**). **G**) Hemi-section, presence of distal caries with pulp exposure. **H**) Radiograph, diagnosis hypothesis – proximal (M and D) deep caries. **I**) Pulp exposure (HE, orig. mag. 100X). **J**) Presence of contaminated dentine spicules (arrow) (Brown and Brenn. original mag. 10X). **K**) Higher magnification of K, (Brown and Breen. original mag. 400X). **L**) Generalized contamination of the dentinal tubules; (Brown and Breen. original magnifying 100X). **M**) Presence of microorganisms of the enamel-dentin junction; (orig. mag. 400X). **N**) Presence of microorganisms in the morphologically unchanged tubules, (Brown and Breen. original magnifying 1000X).

Discussion

In the present study the null hypothesis was accepted: That the presence, location, and distribution of microorganisms in dentinal tubules is unrelated to clinical diagnosis of caries after removal. This finding may have clinical implications and may help clinicians understand the differences on caries pathology and its relation to the site.

The destination of the remaining microorganisms in dentinal tubules is thought to be suspicious¹² and there are directed researches to speculate whether the persistence of microorganisms after caries removal could contribute to lesion progression and affect the prognosis of treatment.^{8,14} Although parameters related to caries inactivation with the initial excavation procedure has not been the focus of this study, we recognize the importance of such analysis to assess the effectiveness of indirect pulp treatment.⁵ For this purpose, several bacteriological studies have been conducted to evaluate what kind of bacteria predominates in lesions of different depths and if these remain viable after conservative restorative procedures.^{5,8,11,14,15}

Taking into account the fact that dentinal tubules run from the enamel-dentin junction to the pulp and have variable specific characteristics, depending on the analyzed area,^{17,18,19} we chose to assess the pulp floor and the enamel-dentinal junction, which are considered critical areas.²⁰ According to Garberoglio and Brännström,¹⁷ microorganisms located in the deeper layers of the pulp floor are not affected by isolation from the oral environment. They will stay alive and may have the potential to continue the carious process regardless of the type of restoration base or sealant used. The enamel-dentin junction is easily permeated by metabolic residue diffusion, enzymes, bacterial toxins, and poisonous components of restoring materials^{20,21} which can continue the carious process.

In present study, microorganisms were detected in the enamel-dentinal junction, showing both superficial and deep penetration. They were also detected under unsupported enamel, which functions as a bacterial niche, compromising the restoration by interfering with the marginal seal. Figure 3 (case 16) shows microorganisms in the enamel-dentinal junction. This study also demonstrated the presence of microorganisms under amalgam restoration in the occlusal

surface (Fig 1, case 12). However, it is not possible to determine if they came through the tooth-restoration interface or if they were already superficially established in the dentinal tubules when the loss of enamel occurred. Furthermore, it takes special importance the persistence of microorganisms into dentinal tubules, even after the removal of carious tissue and tooth restoration.

The bacterial stain also demonstrated that bacteria persisted in dentinal tubules, and there was not always a correlation between the location of the microorganisms and carious lesions clinically classified as shallow, verification extended to the other caries grades. Figure 2 (case 2) confirms this finding. Another important finding was that caries removal based on clinical criteria (such as hardness and color of the dentin) does not guarantee total elimination of microorganisms and a healthy pulp, because dentin remains contaminated, as it has been verified by several publications.^{14,22,23} In addition, the clinical evaluation of dentin can vary according to the tactile and visual criteria inherent to each investigator, usually guided by his or her own sensorial responses and clinical experience, which motivates speculation regarding the persistence and location of microorganisms in dentinal tubules. The findings in this research confirm these statements. Figure 1 (case 1) demonstrates that, although caries had been clinically diagnosed as enamel caries only, it was histologically observed that microorganisms were already invading the tubules on the dentin surface.

Pulp exposure may result from clinical deep carious excavation, and preservation of the pulp tissue becomes challenging because the actual pathologic condition cannot be clinically established. Furthermore, contaminated dentin debris may fall into the pulp chamber, compromising the tissue, as demonstrated in Figure 3 (case 19). The presence of microorganisms deeply embedded in dentinal tubules of morphologically unaffected dentin is also demonstrated in this figure. Clinical examination by the professional will give the impression of healthy dentin because of its hardness. Figure 3 (case 16) shows pulp exposure on the distal surface and no contaminated dentin chips in the pulp space in a tooth where the caries was clinically classified as grade 2, while the mesial surface shows microorganisms in the entire cavity floor. This is a condition that is impossible to diagnose clinically.

On the other hand, the absence of bacteria in 16 analyzed surfaces (43.25%, Table 1), which were clinically classified as having caries and having evidence of loss of dentinal content under microscopic examination, does not assure the sterility of dentin or the complete clinical removal of caries. It can be speculated that the process of demineralization may interfere with the visualization and characterization of the microorganism. There are reports²⁴ showing a severe reduction in number and in the staining capacity of Gram-positive bacteria when formic acid is used for decalcification. However, other methods commonly used in research, such as Polymerase Chain Reaction (PCR) or culture of the samples, also have limitations and would not be able to determine the presence or absence of microorganisms in the pulp wall – which is one of the objectives of the present study.

It was observed in this study that bacteria were located in the dentinal tubules morphologically unaffected, and penetrated following their curvature,

becoming a cone in occlusal caries extending in an S form in sections of interproximal caries. In areas of superficial penetration, the microorganisms followed the dentinal tubules toward the pulp cavity and dispersed alongside in the intertubular dentin. In deeper penetration areas, some microorganisms dispersed only near the dentinal tubules, which is a histological finding in agreement with the study by Ozaki et al.²⁵

The present study substantiates this problematic theme by demonstrating the presence of microorganism in areas considered critical, such as the enamel-dentinal junction and the deep cavity floor; and the microorganisms persisted regardless of the caries grade. Though these data are supported by current literature, studies of this nature contribute to a better understanding of the process and to improving the care to be taken during any clinical management. We suggest further studies combining different methodologies for a better understanding both of the contaminated dentin and of the pulp response.

References

1. Baelum V, Heidmann J, Nyvad B. Dental caries paradigms in diagnosis and diagnostic research. *Eur J Oral Sci.* 2006;114(4):263-77.
2. Bjørndal L. The caries process and its effect on the pulp: the science is changing and so is our understanding. *Pediatr Dent.* 2008;30(3):192-6.
3. Kielbassa AM, Paris S, Lussi A, Meyer-Lueckel H. Evaluation of cavitations in proximal caries lesions at various magnification levels in vitro. *J Dent.* 2006;34(10):817-22. Epub 2006 May 26.
4. Banerjee A, Watson TF, Kidd EA. Dentine caries excavation: a review of current clinical techniques. *Br Dent J.* 2000;188(9):476-82.
5. Orhan AI, Oz FT, Ozcelik B, Orhan K. A clinical and microbiological comparative study of deep carious lesion treatment in deciduous and young permanent molars. *Clin Oral Investig.* 2008;12(4):369-78.
6. Lizarelli RF, Bregagnolo JC, Lizarelli RZ, Palhares JM, Villa GE. A comparative in vitro study to diagnose decayed dental tissue using different methods. *Photomed Laser Surg.* 2004;22(3):205-10.
7. Iwami Y, Hayashi N, Takeshige F, Ebisu S. Relationship between the color of carious dentin with varying lesion activity, and bacterial detection. *J Dent.* 2008;36(2):143-51.
8. Ratledge DK, Kidd EA, Beighton D. A clinical and microbiological study of a proximal carious lesions. Part 1: the relationship between cavitation, radiographic lesion depth, the site-specific gingival index and the level of infection of the dentine. *Caries Res.* 2001;35(1):3-7.
9. Iwami Y, Yamamoto H, Hayashi M, Ebisu S. Relationship between laser fluorescence and bacterial invasion in arrested dentinal carious lesions. *Lasers Med Sci.* 2011;26(4):439-44. Epub 2010 Jun 10.
10. Kidd EA, Ricketts DN, Beighton D. Criteria for caries removal at the enamel-dentine junction: a clinical and microbiological study. *Br Dent J.* 1996;180(8):287-91.
11. Martin FE, Nadkarni MA, Jacques NA, Hunter N. Quantitative microbiological study of human carious dentine by culture and real-time PCR: association of anaerobes with histopathological changes in chronic pulpitis. *J Clin Microbiol.* 2002;40(5):1698-704.
12. Love RM, Jenkinson HF. Invasion of dentinal tubules by oral bacteria. *Crit Rev Oral Biol Med.* 2002;13(2):171-83.
13. Ayna B, Celenk S, Atakul F, Sezgin B, Ozekinci T. Evaluation of clinical and microbiological features of deep carious lesions in primary molars. *J Dent Child (Chic).* 2003;70(1):15-8.
14. Bjørndal L, Larsen T. Changes in the cultivable flora in deep carious lesions following a stepwise excavation procedure. *Caries Res.* 2000;34(6):502-8.
15. Duque C, Negrini T de C, Hebling J, Spolidorio DM. Inhibitory activity of glass-ionomer cements on cariogenic bacteria. *Oper Dent.* 2005;30(5):636-40.
16. Biffi JCG, Rodrigues HH, Gomes GS, Tamburus JR, Teixeira LC, Leonardo MR. Avaliação radiográfica e histobacteriológica da cárie dental. *Rev Assoc Paul Cir Dent.* 1983;37:347-53.
17. Garberoglio R, Brännström M. Scanning electron microscopic investigation of human dentinal tubules. *Arch Oral Biol.* 1976;21(6):355-62.
18. Carrigan PJ. A scanning electron microscopic evaluation of human dentinal tubules according to age and location. *J Endod.* 1984;10(8):359-63.
19. Mjör IA. Dentin permeability: the basis for understanding pulp reactions and adhesive technology. *Braz Dent J.* 2009;20(1):3-16.
20. Falster CA, Araujo FB, Straffon LH, Nör JE. Indirect pulp treatment: in vivo outcomes of an adhesive resin system vs calcium hydroxide for protection of the dentin-pulp complex. *Pediatr Dent.* 2002;24(3):241-8.
21. Bjørndal L, Thylstrup A. A structural analysis of a proximal enamel caries lesions and subjacent dentin reactions. *Eur J Oral Sci.* 1995;103(1):25-31.
22. Kidd EA, Joyston-Bechal S, Beighton D. Microbiological validation of assessments of caries activity during cavity preparation. *Caries Res.* 1993;27(5):402-8.
23. King JB Jr, Crawford JJ, Lindahl RL. Indirect pulp capping: a bacteriologic study of deep carious dentine in human teeth. *Oral Surg Oral Med Oral Pathol.* 1965 Nov;20(5):663-9.
24. Kreulen CM, de Soet JJ, Weerheijm KL, van Amerongen WE. In vivo cariostatic effect of resin modified glass ionomer cement and amalgam on dentine. *Caries Res.* 1997;31(5):384-9.
25. Ozaki K, Matsuo T, Nakae H, Noiri Y, Yoshiyama M, Ebisu S. A quantitative comparison of selected bacteria in human carious dentine by microscopic counts. *Caries Res.* 1994;28(3):137-45.