

# Assessment of success rate of endodontic treatment performed by Brazilian undergraduate students

Marcia Carneiro **VALERA**<sup>1</sup>

Maria Amélia Máximo **ARAÚJO**<sup>2</sup>

Aletéia Massula **FERNANDES**<sup>3</sup>

Carlos Henrique Ribeiro **CAMARGO**<sup>4</sup>

Claudio Antônio Talge **CARVALHO**<sup>4</sup>

## ABSTRACT

**Objective:** The aim of this paper was to evaluate the success rate of endodontic treatments performed by undergraduate students at São Paulo State University (Brazil). **Methods:** A random sample of 94 records from 85 patients who received endodontic treatment was analyzed. All evaluated cases undergone endodontic treatment using the same standardized irrigation solutions and intracanal medication. The criteria used to characterize the clinical successful were: no pain, swelling or fistula and complete or partial regression of apical injury, radiographically observed. Kappa's test was used

to verify the statistic correlation between treatment, clinical and radiographic success. **Results:** According to clinical and radiographic evaluation, the success rates were 89.36% and 88.29%, respectively. The statistical analysis indicated that the success of endodontic treatment occurred in 79 (84.04%) of 94 cases ( $p=0.14$ ). **Conclusion:** The treatment of teeth with pulp necrosis performed by Brazilian undergraduate students showed, clinically and radiographically, a high level of success.

**Keywords:** Endodontics. Treatment failure. Dentistry students.

**How to cite this article:** Valera MC, Araújo MAM, Fernandes AM, Camargo CHR, Carvalho CAT. Assessment of success rate of endodontic treatment performed by Brazilian undergraduate students. *Dental Press Endod.* 2012 Apr-June;2(2):25-9.

» The authors report no commercial, proprietary, or financial interest in the products or companies described in this article.

<sup>1</sup>Full professor of Endodontics, UNESP.

<sup>2</sup>Full professor of Operative Dentistry, UNESP.

<sup>3</sup>PhD student, Endodontics, UNESP.

<sup>4</sup>Associate professor of Endodontics, UNESP.

Submitted: July 23, 2012. Accepted: July 26, 2012.

Contact address: Marcia Carneiro Valera  
Av. Engenheiro Francisco José Longo, 777 – Jd. São Dimas  
Zip code: 12.245-000 – São José dos Campos/SP, Brazil  
E-mail: marcia@fosjc.unesp.br

## Introduction

In order to obtain success in the endodontic treatment, the elimination of the microorganisms in root canal system and the respect of the periapical tissue are considered an important step.<sup>1</sup>

Therefore, the outcome of treatment should be classified in terms of success, when upon follow-up examination there are no clinical signs and symptoms (absence of pain and swelling, normal function of the tooth) or periapical radiolucency (disappearance or reduction of the lesion or the periapical bone rarefaction).<sup>2</sup>

The most common failures observed after endodontic treatment can be related directly with errors in surgical technique, such as inadequate aseptic control, poor cavity access design, missed canals, inadequate instrumentation, use of inadequate root filling material, inadequate root filling, lack of debridement, fractured instruments in root canal, perforations and leaking temporary or permanent restorations.<sup>3</sup>

However, the appearance or persistence of pain or other signs and symptoms after endodontic treatment is an important clinical feature, suggesting endodontic failure<sup>4</sup>. Undoubtedly, the major factors associated with endodontic failure are the persistence of microbial infection in the root canal system and/or the apical area.<sup>5,6</sup>

The correct evaluation of all factors responsible for failure is very important and determines the appropriate treatment plan, beginning with an anamnesis and thorough clinical examination.

The completion of clinical studies that evaluate the success of endodontic treatment based on signs and symptoms is a fundamental point and should guide the basic research to propose new techniques, medicines and medical procedures. Therefore, the purpose of this study was to evaluate the rate of clinical and radiographic success of endodontic treatment performed by undergraduate students.

## Material and Methods

It were analyzed 94 teeth of 85 patients who received endodontic treatment performed by undergraduate students of the Faculty of Dentistry of São José dos Campos, São Paulo State University (UNESP). All selected teeth had pulp necrosis and periapical injury radiographically visible.

To each patient was assigned a dental clinical record with a card for each element to be evaluated. In each

card, clinical and radiographic signs and symptoms were documented to assess the actual condition of the teeth before, during and after treatment.

The selected teeth were treated using the same irrigant solution, intracanal medication and the same root canal preparation, material and root canal filling technique. During biomechanical preparation the canals were instrumented by serial instrumentation technique, associated with the anatomical step by step preparation and irrigated with 1% sodium hypochlorite (Biodinâmica Ltda. Ibioporã, Brazil). The intracanal medication used for 14 days was calcium hydroxide with CMCP (Calen-PMCC, SS White Ltda. Rio de Janeiro, Brazil) and the filling was performed by the active lateral condensation technique using gutta-percha and Grosmann Sealer - Fill Canal (Ligas Odontológicas Ltda. Catumbi, Brazil).

The cases were followed-up for a period ranging from 5 to 36 months with clinical and radiographic monitoring in order to establish the success rate of these treatments. The criteria adopted to characterize the case as a success were:

- » Absence of any painful symptoms: pain to vertical and horizontal percussion, chewing, apical or spontaneous palpation.
- » Absence of intra and extraoral edema.
- » Absence of fistula.
- » Absence of tooth mobility.
- » Complete or partial regression of the radiographic image lesion.

When any of the criteria was not filled out, the case was regarded as failure. The results were submitted to the Kappa's test to verify the correlation between clinical and radiographic success.

## Results

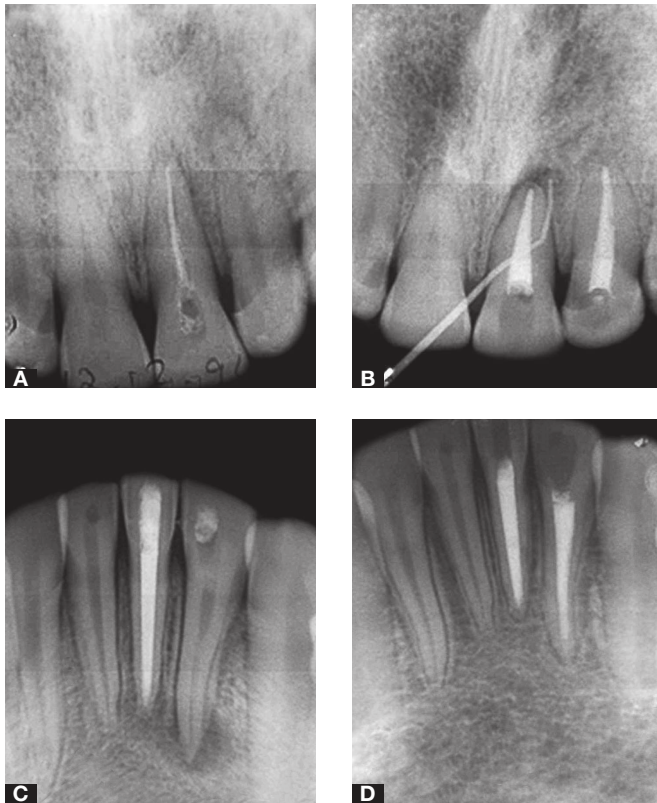
The results have shown, clinically, success rate of 89.36% (84 cases had clinical success) and of 88.29% radiographically (83 cases showed radiographic success). Statistical analysis indicates that there was correlation between success and treatment in 79 (84.04%) of a total of 94 cases ( $p= 0.52$ ).

## Discussion

With technological and scientific advances through the large number of studies in endodontics, there is a clear expectation for increasing success rate in endodontic treatments. Recent studies based on radiographic

**Table 1.** Percentiles of success and failure.

|         | CLINICAL    | RADIOGRAPHIC | CLINICAL + RADIOGRAPHIC |
|---------|-------------|--------------|-------------------------|
| Success | 84 (89.36%) | 83 (88.29%)  | 79 (84.04%)             |
| Failure | 10 (10.64%) | 11 (11.71%)  | 6 (6.38%)               |

**Figure 1.** Case 1: **A)** initial radiograph, **B)** failure. Case 2: **C)** initial radiograph, **D)** success.

evaluation of success/failure in endodontic treatment conducted by specialists, showed a mean failure rate of 21.09%.<sup>7</sup> In data collected for certain populations at the same period,<sup>8</sup> it was found in endodontic treatment performed by no specialists in teeth with pulp necrosis, failure around 39.9%. In this study, the treatments were performed by undergraduate students and the rate of failure based on radiographic examination was 11.70%, lower than the rate found by Kojima et al<sup>7</sup> when treatment was performed by specialists.

The results show that 6.38% of the cases presented as clinical and radiographic failures simultaneously and that 54.54% of cases of radiographic failures are related to problems in the filling of root canals (incomplete filling, and overfilling of 2 mm below the apical limit).

Especially the cases of extrusion are in agreement with the findings of Nair et al,<sup>9</sup> which reported that the presence of gutta-percha through the apical foramen during the root canal filling is associated with delay in the periapical healing process. The studies of Moussa-Badran et al<sup>10</sup> showed that from 304 endodontic treatments performed by undergraduate students at a dental teaching centre, 69.7% had inadequate root fillings. These results are consistent with those from the present study and indicate that the correct root canal filling is important for the endodontic success.

However, according to Lin et al<sup>11</sup> and Sjögren et al,<sup>5</sup> it is unlikely that most contemporary endodontic materials can maintain a periapical inflammation in the absence of endodontic infection. They claim that this statement is reinforced by the high rate of treatment success in teeth without apical lesions even in cases of overfilling.

Moreover, Siqueira<sup>6</sup> concluded that although it has been suggested that non-microbial factors may be implicated in endodontic treatment failure, the literature suggests that persistent infections inside the root canal system or secondary infections, and in some cases apical infections, are the major causes of failure. Also, in most cases, the apical seal is inadequate in overfilled root canal.

Anyway, Chugal et al<sup>12</sup> observed that the prognosis of teeth with periapical disease is increased if they are instrumented closer to the radiographic apex. In this study, 13 cases were closed in the apical limit and the rate of success in these cases was 76.92%. Probably fillings in the apical radiographic limit may in fact be overfilled. Fillings slightly below this limit could have better results.

As for the risk of reinfection, Saunders and Saunders<sup>13</sup> argue that it is dependent on the quality of filling and restoration and that in all cases where the bacteria remain in the canal system there is a constant risk of perpetuation of apical inflammation. For these authors, the coronary infiltration may be an important cause of failure in endodontic treatment, as well that in some situations the root canals can be contaminated through the oral cavity.

Kirkevang et al<sup>14</sup> also reported that teeth with inadequate crowns and restorations have a greater risk of developing apical changes, and this risk is 1.7 higher for teeth with inadequate than for those with adequate restorations.

In this study, 32.35% of teeth showed up without sealing or with provisional sealing in the control clinical visit. This result is disturbing because endodontically treated teeth should be restored in the shortest time as possible, to ensure the success of endodontic treatment. Despite this, the success rate was higher than the related in literature regarding this evaluation.

For the data of clinical failures, the most frequent symptom reported by patients was pain (93.75% of cases), and in 43.75% of these cases the pain was associated with the presence of fistula and/or edema. In this study the fillings were performed using gutta-percha and cement based on zinc oxide and eugenol. Sealers based on zinc oxide and eugenol do not offer satisfactory biocompatibility. Many studies have shown that the use of these sealers leads to a chronic and persistent inflammatory process in the periapical area.<sup>15,16</sup> Thus, nowadays, studies being conducted indicate the preferential use of cements based on less toxic materials.<sup>16,17</sup>

It should be noted that currently, chlorhexidine associated with calcium hydroxide is recommended as intracanal medication, due to CMCP toxicity, which is considered carcinogenic.<sup>18,19</sup> The association of chlorhexidine with calcium hydroxide as intracanal medication is the best option for treatment of pulp necrosis with periapical lesion, showing excellent results.<sup>20</sup>

It is believed that with developments in the protocol of endodontic treatment of teeth with pulp necrosis, futures researches may show even higher rates indicative of success. However, despite the high rate of success found in this study, the development of techniques, tools and materials led to the perception of the need for changes in the protocol of endodontic treatment of teeth with pulp necrosis.

## Conclusion

The treatment of teeth with pulp necrosis performed by graduate students of the Dental School of São José dos Campos/UNESP showed a high rate of clinical and radiographic success.

## References

- Orstavik D, Pitt Ford TR. Apical periodontitis. Microbial infection and host responses. In: Ørstavik D, Pitt Ford TR, editors. *Essential endodontology: prevention and treatment of apical periodontitis*. Oxford (UK): Blackwell Science; 1998. p. 1-9.
- Friedman S. Considerations and concepts of case selection in the management of post-treatment endodontic disease (treatment failure). *Endod Top*. 2002;1(1): 54-78.
- Nair PN. On the causes of persistent apical periodontitis: a review. *Int Endod J*. 2006;39(4): 249-81.
- Mead C, Javidan-Nejad S, Mego ME, Nash B, Torabinejad M. Levels of Evidence for the Outcome of Endodontic Surgery. *J Endod*. 2005 Jan;31(1):19-24.
- Sjögren U, Figdor D, Persson S, Sundqvist G. Influence of infection at the time of root filling on the outcome of endodontic treatment of teeth with apical periodontitis. *Int Endod J*. 1997 Sep;30(5):297-306.
- Siqueira JF Jr. Aetiology of root canal treatment failure: why well-treated teeth can fail. *Int Endod J*. 2001 Jan;34(1):1-10.
- Kojima K, Inamoto K, Nagamatsu K, Hara A, Nakata K, Morita I, et al. Success rate of endodontic treatment of teeth with vital and nonvital pulps. A meta-analysis. *Oral Surg Oral Med Oral Pathol Oral Radiol Endod*. 2004 Jan;97(1):95-9.
- Dugas NN, Lawrence HP, Teplitsky PE, Pharoah MJ, Friedman S. Periapical health and treatment quality assessment of root-filled teeth in two Canadian populations. *Int Endod J*. 2003 Mar;36(3):181-92.
- Nair PN, Sjögren U, Krey G, Kahnberg KE, Sundqvist G. Intraradicular bacteria and fungi in root-filled, asymptomatic human teeth with therapy-resistant periapical lesions: a long-term light and electron microscopic follow-up study. *J Endod*. 1990 Dec;16(12):580-8.
- Moussa-Badran S, Roy B, Bessart du Parc AS, Bruyant M, Lefevre B, Maurin JC. Technical quality of root fillings performed by dental students at the dental teaching centre in Reims, France. *Int Endod J*. 2008 Aug;41(8):679-84.
- Lin LM, Skribner JE, Gaengler P. Factors associated with endodontic treatment failures. *J Endod*. 1992 Dec;18(12):625-7.
- Chugal NM, Clive JM, Spångberg LS. Endodontic infection: some biologic and treatment factors associated with outcome. *Oral Surg Oral Med Oral Pathol Oral Radiol Endod*. 2003 Jul;96(1):81-90.
- Saunders WP, Saunders EM. Coronal leakage as a cause of failure in root-canal therapy: a review. *Endod Dent Traumatol*. 1994 Jun;10(3):105-8.
- Kirkevang LL, Vaeth M, Hörsted-Bindslev P, Bahrami G, Wenzel A. Risk factors for developing apical periodontitis in a general population. *Int Endod J*. 2007 Apr;40(4):290-9.
- Yesilsoy C, Koren LZ, Morse DR, Kobayashi C. A comparative tissue toxicity evaluation of established and newer root canal sealers. *Oral Surg Oral Med Oral Pathol*. 1988 Apr;65(4):459-67.
- Barbosa SV, Araki K, Spångberg LS. Citotoxicity of some modified root canal sealers and their leach able components. *Oral Surg Oral Med Oral Pathol*. 1993 Mar;75(3):357-61.
- Berbert FL, Leonardo MR, Silva LA, Tanomaru Filho M, Bramante CM. Influence of root canal dressings and sealers on repair of apical periodontitis after endodontic treatment. *Oral Surg Oral Med Oral Pathol Oral Radiol Endod*. 2002 Feb;93(2):184-9.
- Soekanto A, Kasugai S, Mataka S, Ohya K, Ogura H. Toxicity of camphorated phenol and camphorated parachlorophenol in dental pulp cell culture. *J Endod*. 1996 Jun;22(6):284-9.
- Chang YC, Tai KW, Chou LS, Chou MY. Effects of camphorated parachlorophenol on human periodontal ligament cells in vitro. *J Endod*. 1999 Dec;25(12):779-81.
- Gomes BP, Vianna ME, Sena NT, Zaia AA, Ferraz CC, de Souza Filho FJ. In vitro evaluation of the antimicrobial activity of calcium hydroxide combined with chlorhexidine gel used as intracanal medicament. *Oral Surg Oral Med Oral Pathol Oral Radiol Endod*. 2006 Oct;102(4):544-50.