

# Endodontic Treatment of a fused mandibular incisive

Álvaro Henrique **BORGES**<sup>1</sup>

Iussif **MAMEDE NETO**<sup>2</sup>

Maria Madalena Danda **MAIA**<sup>3</sup>

Ludmila de Aragão **OLIVEIRA**<sup>4</sup>

Luis Augusto **FAITARONI**<sup>5</sup>

Cláudio Maranhão **PEREIRA**<sup>6</sup>

## ABSTRACT

**Introduction:** Dental fusion is characterized by the union of two dental germs during the development stage, in consequence of the germ layer aberration in the ectoderm and mesoderm. **Objective:** The purpose of this study was to describe the endodontic treatment of lower incisor with supernumerary tooth. **Methods:** Patient sought for attention with spontaneous and severe pain in tooth #41. The dental element presented atypical crown, with aspect of fusion. By the radiographic image was observed the presence of single root and two root canals. It was determined the necessity for endodontic treatment, performed by nickel-titanium instruments.

Each instrument exchange was carried out irrigation with 2.5% sodium hypochlorite solution and 17% EDTA. The filling was performed by active lateral condensation technique of gutta-percha associated to cement and complemented by thermofilling. The cone beam tomography was realized for the filling quality verification and inner anatomy architecture. The patient returned to clinical and radiographic control of 1 year with the tooth showing signs of normality. **Conclusion:** The dentist should develop competence and ability for the adequate diagnosis of dental anomalies, providing good conditions for the promotion of patients' oral health.

**Keywords:** Ebstein Anomaly. Endodontics. Dental Pulp.

**How to cite this article:** Borges AH, Neto IM, Maia MMD, Oliveira LA, Faitaroni LA, Pereira CM. Endodontic treatment of a fused mandibular incisor. *Dental Press Endod.* 2012 July-Sept;2(3):42-7.

<sup>1</sup>PhD and MSc in Endodontics, UNAERP. Coordinator of the MSc Course in Integrated Dental Sciences, UNIC.

<sup>2</sup>MSc in Biological Sciences, UFG. Specialist in Endodontics, Brazilian Dental Association.

<sup>3</sup>MSc in Maxillofacial Radiology, UNICASTELO.

<sup>4</sup>Student of the Specialization Course in Endodontics, UniABO.

<sup>5</sup>Specialist in Periodontics.

<sup>6</sup>PhD in Stomatal Pathology, UNICAMP.

» The authors report no commercial, proprietary or financial interest in the products or companies described in this article.

Submitted: August 01, 2012. Accepted: August 03, 2012.

Contact address: Álvaro Henrique Borges  
Av. Beira Rio, 3100 – CEP: 78.065-900 – Cuiabá/MT  
Email: ahhborges@brturbo.com.br

## Introduction

Anomalies are defects caused by genetic disturbances and environmental factors during the dental formation.<sup>1-3</sup> The tooth development begins around the sixth week intrauterine and is divided in many stages. Any alteration in any of these phases can result in the abnormal development of size, shape and dental structure.<sup>3-5</sup> The anatomical changes, as a result of formation anomalies, can lead to changes in the dental crown, root and root canal.<sup>6,7</sup> In cases of fused teeth, the crowns are fused by the enamel and/or dentin, but show two roots or two root canals in single root.<sup>8</sup> It is characterized by the union of the two dental germs during the developmental stage, in consequence of the aberration in the germinative layer of the ectoderm and mesoderm.<sup>9,10</sup> The fusion etiology is unclear, but the influence of the pressure or physical forces producing close contact between two teeth in development, genetic predisposition and racial differences have been reported as possible causes.<sup>9,11</sup> Canines and incisors are the most affected, rarely occurs in molars and there is no prediction when the dental arches are compared.<sup>12,13</sup> In the permanent dentition, it has low incidence (0.1%), while in the primary one it appears around 0.5%, equally distributed in genders.<sup>14</sup> In thorough clinical and radiographic exams, it shows to be differentiated from germination cases.

Gemination is defined as the attempt of dental germ division by the invagination during the developmental stage.<sup>15,16</sup> The reduction of teeth number in the dental arch is not observed and, by imaging exam, one root and one pulp chamber is noted in a single crown, partial or totally separated.<sup>15,17</sup> In these cases, the two parts of the crown are symmetric.<sup>16</sup>

In the anterior region, the presence of anomalous tooth can cause an undesirable anatomical aspect due the irregular crown morphology. There is greater predisposition to dental caries and periodontal diseases and, in some cases, difficulties in endodontic treatment in consequence of the alteration in radicular shape.<sup>17</sup> The endodontic treatment has the goal of ideal cleaning, by instruments, irrigants, intracanal dressing and finalization with endodontic and coronal sealing.<sup>18</sup> The morphological endodontic characteristics, related to frequency of number, localization, direction and shape, can

determine the therapeutic success.<sup>19</sup> The inner anatomy knowledge is fundamental for the localization and proper treatment of the present root canals.<sup>8,19</sup> However, variation in normal conditions may occur. The aim of this study was to describe an endodontic treatment of a fused mandibular incisor.

## Case report

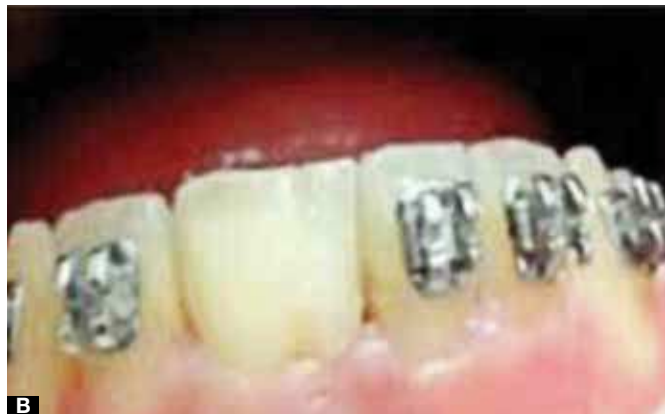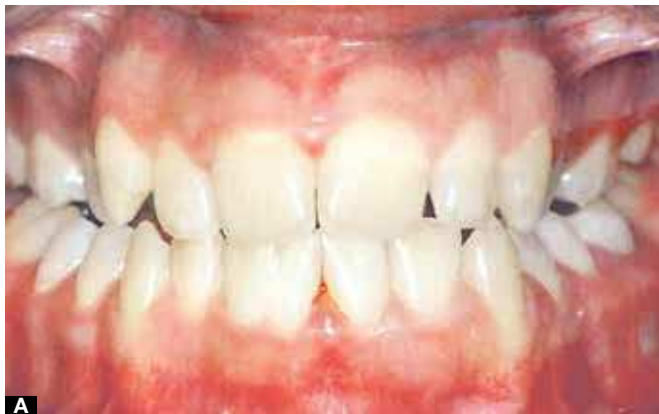A 24 year-old female patient sought dental care at the Brazilian Dental Association – Branch office of Imperatriz-MA with chief complaint of severe and spontaneous pain in the inferior anterior region. In the clinical exam, the presence of all inferior teeth in the dental arch and atypical crown in tooth #41 were observed (Fig 1A). The tooth presented large crown towards mesio-distal and fusion appearance of #41 and supernumerary tooth (Fig 1B). The radiographic exam showed normality aspect in the periapical region, however, differentiated anatomy, featuring the dental element fusion and the presence of single root with two radicular canals (Fig 3A). The vitality pulp test was realized with EndoFrost (Roeko- Wilcos do Brasil Ind. e Com. Ltda, Rio de Janeiro, Brazil), the response was positive, featuring the probable clinical diagnosis of symptomatic pulpitis. Then, the necessity of endodontic treatment was determined. Initially, the patient was anesthetized and in sequence, the absolute isolation of operative field with rubber dam and clip 212 (Fig 2A). The coronal opening was realized with 1014 long shaft spherical diamond tipped (Maillefer, Dentsply, Baillagueses, Switzerland) and Z-Endo (Maillefer, Dentsply, Baillagueses, Switzerland). The entrance orifices were located and the exploration done by 10, 15 and 20 K-file instruments (Maillefer, Dentsply, Baillagueses, Switzerland). The cervical and medium third of the radicular canal were prepared with Line-Angle Axxess 20.06 bur (SybronEndo, Sybron Dental Specialities, USA). The working length was determined in 22 mm for both root canals (Fig 3B). The cleaning and shaping of the root canal were done in sequence with ProTaper® (Maillefer, Dentsply, Baillagueses, Switzerland) Ni-Ti instruments, from the F1 to F5. In each instrument changing, a copious canal irrigation with 2.5% sodium hypochlorite and 17% EDTA (Biodinâmica, Quím. e Farm., Ibiporã-PR, Brazil), for 5 minutes, was performed and finalized by the final irrigation with 5mL

of 2.5% hypochlorite. The gutta percha cone proof was determined according to the last instrument diameter used in the preparation. The root canal filling was realized by the lateral condensation technique, using principal and accessories gutta-percha points (Dentsply, Petrópolis, RJ, Brazil), Sealapex<sup>®</sup> cement (SybronEndo, Sybron Dental Specialties, USA) and by n.55 MacSpadden gutta condenser (Maillefer, Dentsply, Baillagueses, Switzerland). After the root canal filling, a final toilet of the coronary chamber was done and the tooth sealed with universal restaurateur Filtek Z-350 XT (3M ESPE, Sumaré, SP, Brazil) (Fig 3C). The patient returned for one-year follow-up with the tooth in occlusal function, absence of pain,

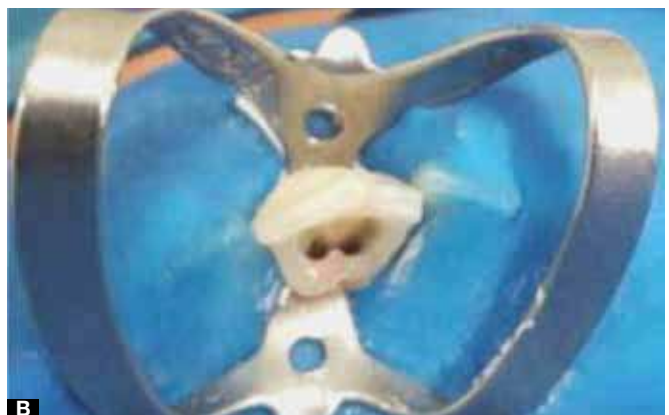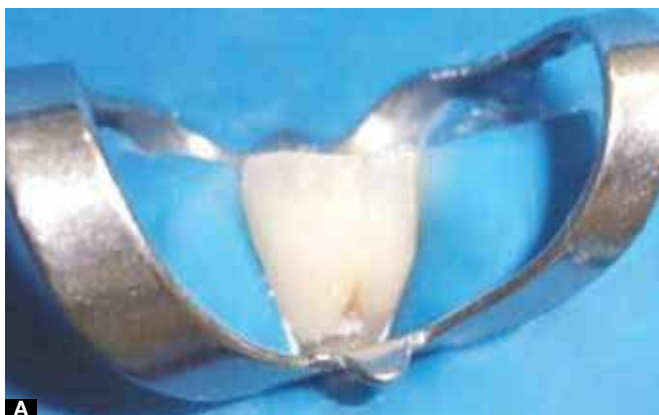fistula, edema, periodontal pocket, tooth and tissue with normal color, radiographic (Fig 3D) and tomographic (Fig 4A to 4D) aspects of normality.

### Discussion

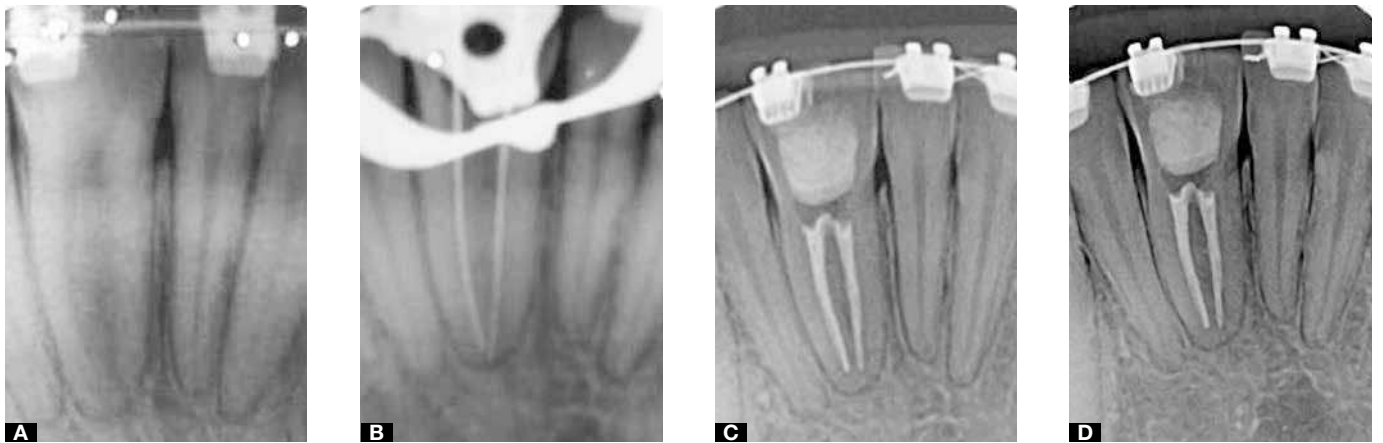Although there is wide literature about dental gemination and fusion, heated debate about the appropriate nomenclature happens. Usually, the definition occurs by the amount of tooth present in the arch or the aspect of radicular morphology.<sup>20</sup> Both dental fusion and gemination are formation anomalies characterized by teeth with large clinical crowns and by the imaging exams may present one or two pulpar chambers and two root canals.<sup>8,17</sup> Fusion,



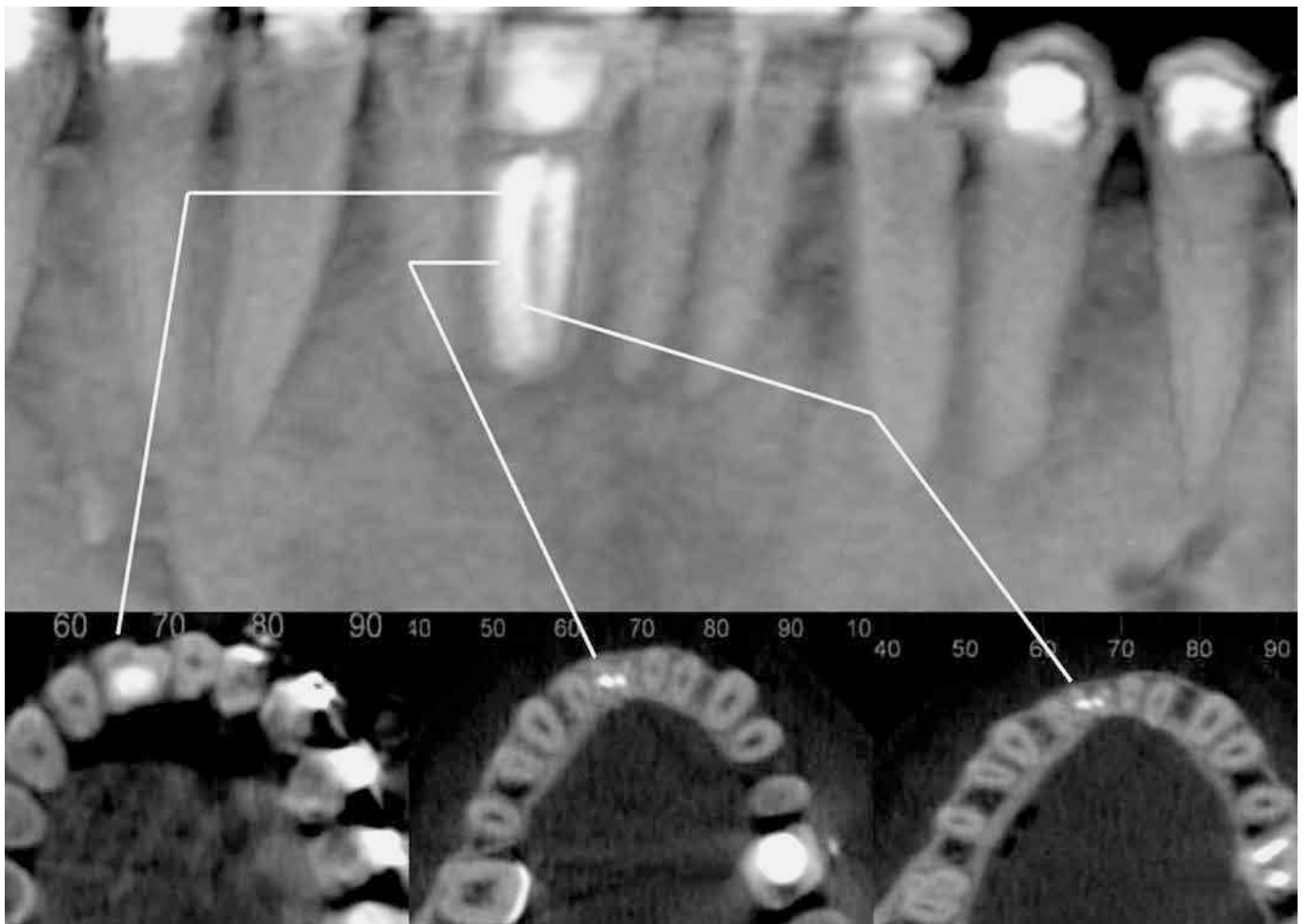
**Figure 1. A)** Image of the presence of all mandibular teeth in the arch, and atypical crown in the #41 **B)** Clinical aspect of the large crown e appearance of fusion between #41 and supernumerary.



**Figure 2. A)** Image of the absolute isolation of operative field with rubber dam and clip 212. **B)** Coronal opening and the entrance orifices were located.



**Figure 3.** **A)** Image of periapical radiograph showing normal aspect and differentiated anatomy, featuring the dental element fusion and the presence of single root with two radicular canals. **B)** Determination of working length. **C)** Root canal filling and tooth sealed with universal restorative. **D)** One year follow-up.



**Figure 4.** **A)** Image of panoramic exam, showing tooth #41 filled. **B)** Axial cut showing the cervical third of the tooth #41 root canal **C)** Axial cut showing the middle third of the tooth 41 root canal. **D)** Axial cut showing the apical third of the tooth #41 root canal.

conceptually, is defined as the union between dentin and/or enamel of two or more teeth in developmental stage, being partial or total, depending the phase in the moment of the union.<sup>9,10</sup> In these cases, in the dental arch are found less teeth.<sup>9,11-14</sup> By other side, the gemination is conceptualized as an attempt of dental germ division.<sup>3,15,16</sup> The teeth are presented with deformed appearance depending on the irregularities of the enamel.<sup>21</sup> The tooth amount present, in function of this situation, is not altered.<sup>3</sup> A rare case of fusion between a central inferior incisor and supernumerary tooth was presented in this study. Thus, the tooth amount in the dental arch did not alter and a possibility of diagnosis of gemination was considered. In this way, the medical history and clinical-radiographic exams are definitely important for the correct diagnostic.<sup>17</sup>

The fused teeth do not present clinical symptoms and therefore, do not need treatment, unless there is occlusal and esthetic interference for the patient.<sup>7</sup> Many conducts have been proposed in the way of this anomaly treatment, however, the dental morphology is so variable that a particular condition is recommended for each case, including surgical separation or even extraction and prosthetic treatment.<sup>22</sup> In the presented case, the patient showed

history of spontaneous pain and based in clinical and radiographic characteristics, the endodontic radical treatment was choosed.

Dental fusion shows a great variety in pulpar chamber size, varying obliteration degree and root canals configuration, being a challenge for the endodontists.<sup>8,17,20</sup> The anomaly can be confirmed by imaging exam and the success of the treatment depends on the cleaning of the root canal system.<sup>19</sup> The complications during the endodontic treatment are related to irregular dental morphology, increasing the difficulty of instrumentation and filling.<sup>17</sup> Thus, the clinical and radiographic exams are determinant for the success of endodontic therapeutic. In this context, the computed tomography is an effective resource for diagnostic and treatment of fused teeth in function of greater clarity that this exam offers to recognize inner and external anatomy.<sup>23</sup>

## Conclusion

Dental fusion is a developmental anomaly characterized by the union of two dental germs, diagnosed by clinical and radiographic exams. In the cases of endodontic treatment, the professional should develop competence in the diagnostic and adequate treatment, promoting conditions to patients' oral health.



## References

- Estrela C, Alencar AHG, Decurcio DA, Borges AH, Guedes OA, Estrela CRA. Influência de estratégias de sanificação no sucesso do tratamento da periodontite apical. *Rev Odontol Bras Central* 2012;21(56):367-75.
- Estrela, C. *Endodontic science*. São Paulo: Artes Médicas Dentistry; 2009. 1223p.
- Cimilli H, Kartal N. Endodontic treatment of unusual central incisors. *J Endod* 13. 2002;28(6):480-1.
- Marques-da-Silva B, Baratto-Filho F, Abuabara A, Moura P, Losso EM, Moro A. Multiple taurodontism: the challenge of endodontic treatment. *J Oral Sci*. 2010;52(4):653-8.
- Metgud S, Metgud R, Rani K. Management of a patient with a taurodont, single-rooted molars associated to multiple dental anomalies: a spiral computerized tomography evaluation. *Oral Surg Oral Med Oral Pathol Oral Radiol Endod*. 2009;108(2):e-81-6.
- Suprabhba BS, Sumanth KN, Boaz K, George T. An unusual case of non-syndromic occurrence of multiple dental anomalies. *Indian J Dent Res*. 2009;20(3):385-7.
- Neville B, Damm D, Allen C, et al. *Oral and maxillofacial pathology*. In: Forest E, ed. *Abnormalities of Teeth, Developmental Alterations of Teeth*. 2nd ed. Philadelphia, PA: WB Saunders Company; 2002:84.
- Gupta SK, Saxena P, Jain S, Jain D. Prevalence and distribution of selected developmental dental anomalies in an Indian population. *J Oral Sci*. 2011;53(2):231-8.
- Veeraiyan DN, Fenton A. Dental fusion: A case report of esthetic conservative management. *Quintessence Int* 2009;40(10):801-3.
- Tsisis I, Steinbock N, Rosenberg E, Kaufman AY. Endodontic treatment of developmental 2. anomalies in posterior teeth: treatment of geminated/fused teeth – report of two cases. *Int Endod J* 2003;36(5):372-9.
- Yucel AC, Guler E. Nonsurgical endodontic retreatment of geminate teeth: a case report. *J Endod* 2006;32(12):1214-6.
- Danesh G, Schrijnemakers T, Lippold C, Schäfer E. Fused maxillary central incisor with 4. dens evaginatus as a talon cusp. *Angle Orthod* 2006;77(1):176-80.
- Rajashekhara BS, Dave B, Manjunatha BS, Poonacha KS, Sujana SG. Bilateral fusion of primary mandibular lateral incisors and canines: a report of a rare case. *Rev Odontol Ciênc*. 2010;25(4):427-9.
- Nunes E, Moraes IG, Novaes PMO, Sousa SMG. Bilateral fusion of mandibular second 7. molars with supernumerary teeth: case report. *Braz Dent J* 2002;13(2):137-41.
- Liu S, Fan B, Peng B, Fan M, Bian Z. Endodontic treatment of an unusual connotation of 8. permanent mandibular molars: a case report. *Oral Surg Oral Med Oral Pathol Oral Radiol Endod* 2006;102(4):e72-7.
- Ghoddusi J, Zarei M, Jafarzadeh H. Endodontic treatment of a supernumerary tooth fused 9. to a mandibular second molar: a case report. *J Oral Sci* 2006;48(1):39-41.
- Mc Donald RE. *Dentistry for children and adolescent*. Saint Louis: CV Mosby Co, 1974, p.36.
- Kelly JR. Gemination, Fusion or Both? *Oral Surg* 1978;45(2):655-6.
- Faria MIA, Borges AH, Carneiro SM, Silva Filho JM, Semenoff Segundo A, Cruz Filho AM. *Rev Odontol Ciênc* 2011;26(1):88-91.
- Prabhakar AR, Kaur T, Nadig B. Bilateral fusion of permanent incisors with Talon's cusp: a rare case report. *J Oral Maxillofac Pathol*. 2009; 13(2):93-6.
- Chalakkal P, Thomas AM. Bilateral fusion of mandibular primary teeth. *J Indian Soc Pedod. Prevent Dent* 2009;27(2):108-10.
- Chipashvili N, Vadachkoria D, Beshkenadze E. Gemination or fusion? - challenge for dental practitioners (case study). *Georgian Med News*. 2011(194):28-33
- Gupta S, Singla S, Marwah N, Dutta S, Goel M. Synodontia between permanent maxillary lateral incisor and a supernumerary tooth: surgical treatment perspective. *J Oral Health Comm Dent* 2007;1:52-5.
- Decurcio DA, Silva JA, Decurcio RA, Silva RG, Pécora JD. Influence of cone beam computed tomography on dens invaginatus treatment planning. *Dental Press Endod*. 2011; 1(1): 87-93