

## Introduction

The radicular cyst currently represents the most common odontogenic cysts, this lesion predominates in adults between the third and sixth decade of life.<sup>1-5</sup> Also called peripheral cysts, are inflammatory cysts of the jaws, formed in the dental apices, with necrotic and infected pulps, thus they are considered as direct consequences of apical granulomas.<sup>3,6</sup> Its etiology generally come from the root canal infections caused by caries. It is known that the immune-inflammatory process is the basis of formation of dental granulomas and radicular cysts.<sup>7</sup>

The radicular cyst represents a pathological cavity, internally coated by epithelium and externally by a fibrous that contains, inside a semi-fluid or fluid material.<sup>8,9</sup> The formation of the radicular cyst has three distinct phases: initial phase, the phase of cyst formation and growth stage. In the first phase the epithelial rest of Malassez are continuously proliferate when stimulated by chemical mediators released during the inflammatory process, forming a epithelial net inside the apical granuloma. In the last phase, the existing micro cavity characterizes a cystic lesion that may be microscopically diagnosed. The cystic growth occurs slowly and continuously.<sup>5</sup>

Radiographically, the radicular cyst presents a picture which is radiolucent homogeneous density unilocular, circumscribed, round, oval, associated with an intact root apex, a devitalized tooth with rupture of the hard lamina at the apex,<sup>10</sup> very familiar to granuloma, as a circumscribed peripheral bone rarefaction may present a radiopaque line delimiting the lesion.<sup>11</sup>

According to World Health Organization the radicular cyst is classified as an inflammatory odontogenic cyst and represents a major cause of bone destruction of the jaws. Therefore and the frequent incidence of these lesions in the clinics that provide dental care, researches are developed in this area.<sup>12,13</sup> The recommended treatment for periapical lesions, with or without the involvement of periapex, has been the root canal treatment. A discussion regarding the efficacy of one and two-visit treatment of infected root canals has been going on among scientists for a long time.<sup>14</sup> Currently strong scientific evidence indicates regression of cystic lesions after conventional endodontic therapy with periodic changes of the medication based on calcium hydroxide with

or without paramonochlorophenol camphor or 2% chlorhexidine gel, with a very high success rate.<sup>15-20</sup>

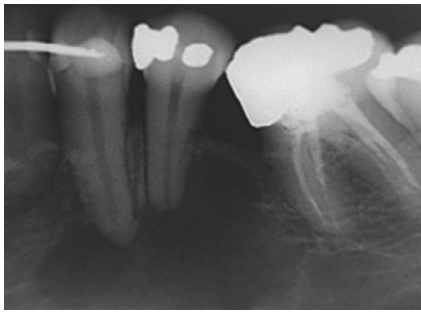
The endodontic surgery should only be given when the conventional endodontic treatment fails to restore the integrity of the peripheral tissue.<sup>11,21</sup>

## Case report

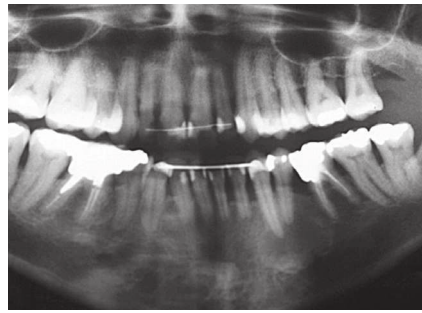
The patient, age 49, female, Caucasian, ought dental endodontic referred by a dentist oral maxillofacial, who found the presence of a radicular cyst between teeth #33 and #34, near the region of the mental foramen. The patient complained of pain and mobility in the region of tooth #34. Anamnesis was conducted, clinical examination, radiographic examination and testing of pulp vitality in teeth #33 and #34. Pulp necrosis and mobility was observed only on tooth 34. In peripheral radiograph (Fig 1), the panoramic (Fig 2) and tomography (Fig 3), observed the presence of radiolucent, unilocular, located in the anterior mandible between the elements #33 and #34. By the clinical and radiographic characteristic, the hypothetical diagnosis was inflammatory peripheral cyst associated with the first pre-molar, tooth #34. The necropulpectomy endodontic treatment was performed using the crown-apex technique. The channel was modeled irrigated with solution sodium hypochlorite 1%, the instrument memory was #45 K-file. After biomechanical preparation complete was used as canal dressing calcium hydroxide paste, made with calcium hydroxide pro-analysis and propylene glycol. The dressing with calcium hydroxide paste was renewed on a monthly basis for 10 months. The coronal sealing was carried out with light-curing glass ionomer cement type IV (Vitremar, 3M ESPE, U.S.A). After 10 months through periapical radiographs was observed significant regression of lesions with significant new bone formation and no symptoms in the patient and performed the root canal filling using thermoplastic technique using gutta-percha cones and Endofill cement with the help of a thermo compactor 60 (Mc Spadden), after a week was made final restoration of the tooth 34 with composite resin (Filtek- 3M ESPE- U.S.A).

## Results

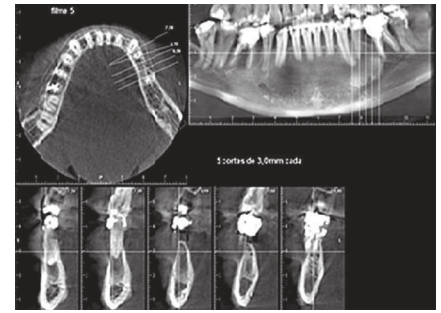
After one year of conventional endodontic treatment the patients without signs of recurrence, the endodontic treatment provided a favorable clinical and



**Figure 1.** Periapical radiograph showing extensive periapical lesion of endodontic origin, suggestive of periapical cyst between teeth #33 and #34.



**Figure 2.** Panoramic radiograph showing extensive periapical lesion of endodontic origin, suggestive of periapical cyst between teeth #33 and #34.



**Figure 3.** Cone beam volumetric tomography with shooting in small volumes the jaw teeth #33 to #36.

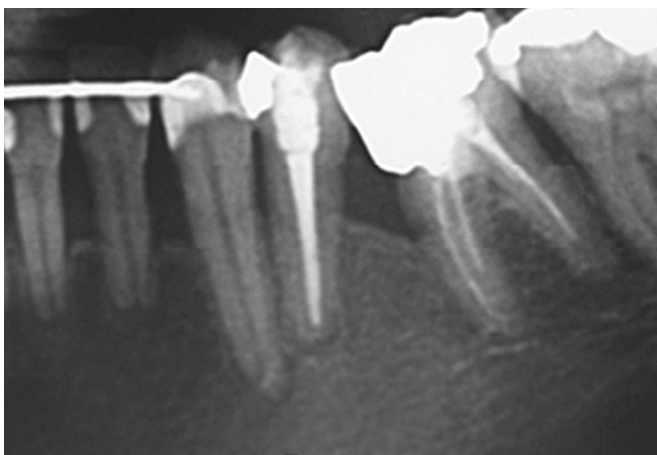periapical (Fig 4) and panoramic radiographic (Fig 5), without pain symptoms with the signs of regression of lesions, no need for additional surgery in the periapical region. The case remains being accompanied.

## Discussion

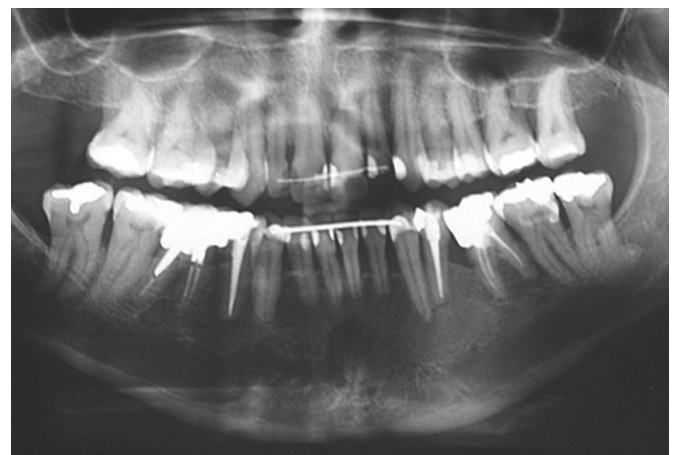
In this case was observed a significant regression of a cystic lesion associated with tooth #34 after conventional endodontic treatment associated with the medication a paste of calcium hydroxide monthly renewed for 10 months.

The results of this study is in agreement with other studies<sup>22-28</sup> which observed regression of non-surgical radicular cysts after conventional endodontic treatment, allowing tissue reactions and immunological and inflammatory nature, consistent with the repair.

Was inferred that the endodontic treatment non-surgical can be successfully implemented in a high percentage of cases of radicular cysts and that its success doesn't depend on the nature of the lesion, but appears to be influenced by individual variations of host's immune response.<sup>22</sup> Proper preparation of biomechanics followed by calcium hydroxide medication periodically renewed represents a nonsurgical approach to resolve extensive inflammatory peripheral lesions.<sup>28</sup> The regression of the cystic lesion with conservative treatment (based on successive changes of dressings  $\text{Ca}(\text{OH})_2$  basic, could occur due to collagen deposition generated by the healing process. Such a deposit would compress the capillaries involved in nutrition of the epithelial cystic line, which is degenerate being phagocytized by macrophages.<sup>29</sup>



**Figure 4.** Periapical radiograph after 1 year of endodontic obturation of the tooth #34. Note advanced repair in the periapical region between teeth #33 and #34.



**Figure 5.** Panoramic radiograph after 1 year root canal filling of the tooth #34. Note advanced repair in the periapical region between teeth #33 and #34.

It has been shown that treatment with calcium hydroxide as an intracanal dressing in the presence of large and chronic peripheral lesions can create an environment more conducive to healing and start bone repair. Calcium hydroxide is an effective intracanal antibacterial agent because of its high pH 12.5, with bactericidal and bacteriostatic.<sup>20</sup>

In the literature, some authors believe that direct contact with calcium hydroxide to the peripheral tissue benefits the osteoinduction, others have suggested that calcium hydroxide in the apical region has anti-inflammatory activity of neutralizing acidic products, stimulates alkaline phosphatase and also has antibacterial action.<sup>30</sup> The bacterial activity of various pastes of calcium hydroxide was confirmed with different vehicle.<sup>28</sup>

The success rate of endodontic treatment has increased significantly, explained fact by the development of techniques and instruments used for modeling and root canal filling and also related to pathology installed.<sup>31-34</sup>

In this clinical case, as in other studies, because it is an extensive peripheral lesion, in a region close to the mental foramen with clinical and radiographic characteristics, suggestive of periapical cyst, Panoramic, periapical and tomography radiographs were performed. Although the panoramic radiographs and periapical acceptable reproduce details in the mesiodistal, the observation in the bucco-lingual is inadequate, being important a tomography that provides three-dimensional visualization of pathologic lesions and their relationship to important anatomic structures.<sup>35</sup>

## Conclusions

After one year of conventional endodontic treatment the patient is without signs of recurrence, the endodontic treatment provided a favorable clinical and radiographic response, without pain symptoms, with evidence of regression of the lesion, with significant bone formation without the necessity for additional surgical in the periapical region. The case is being accompanied.

## References

1. Bystrom A, Happonen RP, Sjogren U, Sundqvist G. Healing of periapical lesions of pulpless teeth after endodontic treatment with controlled asepsis. *Endod Dent Traumatol.* 1987;3(2):58-63.
2. Shafer WG, Hine MK, Levy BM. *Tratado de Patologia bucal.* 4ª ed. Rio de Janeiro: Guanabara Koogan;1987.
3. Regezi JA, Sciubba JJ. Cistos da boca. In: *Patologia bucal: correlações clinicopatológicas.* 3a ed. Rio de Janeiro: Guanabara Koogan; 2000. p. 260-91.
4. Tommasi AF. *Diagnóstico em patologia bucal.* 3ª ed. São Paulo: Pancast; 2002.
5. Shear M. Cholesterol in dental cysts. *Oral Sug Oral Med Oral Pathol.* 1963;16:1465-73.
6. Neville BW. Doenças da polpa e do periápice. In: Neville BW, Damm DD, Allen CM, Bouquet JE. *Patologia oral e maxilofacial.* Rio de Janeiro: Guanabara Koogan; 1998. cap. 3, p. 9.
7. Santos LCS, Ramos EAG, Meira TC, Figueiredo CRLV, Santos JN. Etiopatogenia do cisto radicular. Parte I. *Rev Ci Méd Biol.* 2006;5(1):69-74.
8. Hisatomi M, Asaumi J, Konouchi H, Shigehara H, Yanagi Y, Kishi K. MR imaging of epithelial cysts of the oral and maxillofacial region. *Eur J Radiol.* 2003;48(2):178-82.
9. Gálvez-Gastélum FJ, Sandoval-Rodríguez AS; Armendáriz-Borunda, J. El factor de crecimiento transformante  $\beta$  como blanco terapéutico. *Salud Publica Méx.* 2004;46(4):341-50.
10. Freitas A, Rosa JE, Souza IF. *Radiologia odontológica.* 5ª ed. São Paulo: Artes Médicas; 2000.
11. Azambuja TWF, Bercini F, Alano F. Cirurgia paraendodôntica: revisão da literatura e apresentação de casos clínicos cirúrgicos. *Rev Fac Odontol Porto Alegre.* 2006;47(1):24-9.
12. Kramer IR, Pindborg JJ, Shear M. The WHO histological typing of odontogenic tumors; a commentary on the second edition. *Cancer.* 1992;70:12.
13. Taylor AM, Camacho MEI, Franco MAD, Tejero MAT. Quistes odontogênicos: análise de 856 casos. *Med Oral.* 2002;7(2):89-96.
14. Pietrzycka K, Pawlicka H. Efficacy of treatment of teeth with infected root canals as related to clinical procedure. *J Stoma.* 2011;64(3-4):174-86.
15. Lin LM, Ricucci D, Lin J, Rosenberg PA. Nonsurgical root canal therapy of large cyst-like inflammatory periapical lesions and inflammatory apical cysts. *J Endod.* 2009;35(5):607-15.
16. Oliveira, SHG, Lório LS, Maekawa LE, Camargo SEA, Camargo CHR, Palo RM. Tratamento não-cirúrgico de patologias com imagens radiográficas sugestivas de cisto radicular. *Rev. Assoc Paul Cir Dent.* 2009;63(1).164-8.
17. Caliskan MK. Prognosis of large cyst-like periapical lesions following nonsurgical root canal treatment: a clinical review. *Int Endod J.* 2004;37(6):408-16.
18. Cerda-Cristerna BI, Silva-Herzog FD, Pozos-Guillén A, Sayão SA. Reparo de reabsorção radicular externa associada com queratocisto odontogênico: relato de caso. *RSBO.* 2009;6(1)100-3.
19. Soares J, Brito-Junior M, Silveira FF, Nunes E, Santos SM. Favorable response of an extensive periapical lesion to root canal treatment. *J Oral Sci.* 2008;50(1):107-11.
20. Kusgoz AK, Yildirim S, Gokalp A. Nonsurgical endodontic treatments in molar teeth with large periapical lesions in children: 2-year follow-up. *Oral Surg Oral Med Oral Pathol Oral Radiol Endod.* 2007;10(104):60-5.
21. Guimarães KB. Cirurgia paraendodôntica com obturação simultânea dos canais: relato de caso. *Rev Ci Méd Biol.* 2006;5(2):188-94.
22. Shah N. Nonsurgical management of periapical lesions: a prospective study. *Oral Surg Oral Med Oral Pathol.* 1988;66(3):365-71.
23. Sjögren U, Häggglund B, Sundqvist G, Wing K. Factors affecting the long term results of endodontic treatment. *J Endod.* 1990;16(10):498-504.
24. Murphy WK, Kaugars GE, Collett WK, Dodds RN. Healing of periapical radiolucencies after nonsurgical endodontic therapy. *Oral Surg Oral Med Oral Pathol.* 1991;71(5):620-4.
25. Nair PNR, Pajarola G, Schroeder HE. Types and incidence of human periapical lesions obtained with extracted teeth. *Oral Surg Oral Med Oral Pathol Oral Radiol Endod.* 1996;81(1):93-102.
26. Laszkiewicz J. Evaluation of calcium hydroxide in conservative treatment of large periapical lesions. *Int Endod J.* 1998;31(3):203.
27. Oztan MD. Endodontic treatment of teeth associated with a large periapical lesion. *Int Endod J.* 2002;35(1):73-8.
28. Soares J, Santos S, Silveira F, Nunes E. Nonsurgical treatment of extensive cyst-like periapical lesion of endodontic origin. *Int Endod J.* 2006;39(7):566-75.
29. Bender IB, Seltzer S, Soltanoff W. Endodontic success. A reappraisal of criteria. 1. *Oral Surg Oral Med Oral Pathol.* 1966;22(6):780-9.
30. Souza FJ, Soares AJ, Vianna ME, Zaia AA, Ferraz CC, Gomes PB. Antimicrobial effect and pH of chlorhexidine gel and calcium hydroxide alone and associated with other materials. *Braz Dent J.* 2008;19(1):28-33.
31. Cunha PO. Avaliação radiográfica dos tratamentos endodônticos realizados por alunos de graduação da faculdade de odontologia da UFAM [monografia]. Manaus (AM): UFAM; 2010.
32. Gil AC, et al. Revisão contemporânea da obturação termoplastificada, valendo-se da técnica de compactação termomecânica. *Rev Saúde.* 2009;3(3):20-9.
33. Lopes HP, Siqueira JF Jr. *Endodontia: biologia e técnica.* 3ª ed. Rio de Janeiro: Guanabara Koogan; 2010.
34. Tsurumachi T, Honda K. A new cone beam computerized tomography system for use in endodontic surgery. *Int Endod J.* 2007;40(3):224-32.
35. Huuononen S, Kvist T, Gröndahl K, Molander A. Diagnostic value of computed tomography in retreatment of root fillings in maxillary molars. *Int Endod J.* 2006;39(10):827-33.

- Dental Press Endodontics publishes original research (e.g., clinical trials, basic science related to the biological aspects of endodontics, basic science related to endodontic techniques and case reports). Review articles only for invited authors. Authors of potential review articles are encouraged to first contact the editor during their preliminary development.
- Dental Press Endodontics uses the Publications Management System, an online system, for the submission and evaluation of manuscripts. To submit manuscripts please visit: [www.dentalpressjournals.com.br/rdpendo](http://www.dentalpressjournals.com.br/rdpendo)
- Please send all other correspondence to:  
Dental Press Endodontics  
Av. Euclides da Cunha 1718, Zona 5  
Zip Code: 87.015-180, Maringá/PR  
Phone. (44) 3031-9818  
E-mail: [artigos@dentalpress.com.br](mailto:artigos@dentalpress.com.br)
- The statements and opinions expressed by the author(s) do not necessarily reflect those of the editor(s) or publisher, who do not assume any responsibility for said statements and opinions. Neither the editor(s) nor the publisher guarantee or endorse any product or service advertised in this publication or any claims made by their respective manufacturers. Each reader must determine whether or not to act on the information contained in this publication. The Dental Press Endodontics and its sponsors are not liable for any damage arising from the publication of erroneous information.
- To be submitted, all manuscripts must be original and not published or submitted for publication elsewhere. Manuscripts are assessed by the editor and consultants and are subject to editorial review. Authors must follow the guidelines below.
- All articles must be written in English.

## GUIDELINES FOR SUBMISSION OF MANUSCRIPTS

- Manuscripts must be submitted via [www.dentalpressjournals.com.br/rdpendo](http://www.dentalpressjournals.com.br/rdpendo). Articles must be organized as described below.

### 1. Title Page

- Must comprise the title in English, an abstract and keywords.
- Information about the authors must be provided on a separate page, including authors' full names, academic degrees, institutional affiliations and administrative positions. Furthermore, the corresponding author's name, address, phone numbers and e-mail

must be provided. This information is not made available to the reviewers.

### 2. Abstract

- Preference is given to structured abstracts in English with 250 words or less.
- The structured abstracts must contain the following sections: INTRODUCTION: outlining the objectives of the study; METHODS, describing how the study was conducted; RESULTS, describing the primary results, and CONCLUSIONS, reporting the authors' conclusions based on the results, as well as the clinical implications.
- Abstracts in English must be accompanied by 3 to 5 keywords, or descriptors, which must comply with MeSH.

### 3. Text

- The text must be organized in the following sections: Introduction, Materials and Methods, Results, Discussion, Conclusions, References and Figure legends.
- Texts must contain no more than 4,000 words, including captions, abstract.
- Figures and tables must be submitted in separate files (see below).
- Insert the Figure legends also in the text document to help with the article layout.

### 4. Figures

- Digital images must be in JPG or TIF, CMYK or grayscale, at least 7 cm wide and 300 dpi resolution.
- Images must be submitted in separate files.
- In the event that a given illustration has been published previously, the legend must give full credit to the original source.
- The author(s) must ascertain that all figures are cited in the text.

### 5. Charts

- Files containing the original versions of charts must be submitted.
- It is not recommended that such charts be submitted only in bitmap image format (not editable).
- Drawings may be improved or redesigned by the journal's production department at the discretion of the Editorial Board.

### 6. Tables

- Tables must be self-explanatory and should supplement, not duplicate the text.
- Must be numbered with Arabic numerals in the order they are mentioned in the text.
- A brief title must be provided for each table.
- In the event that a table has been published previously, a footnote must be included giving credit to the original source.