

# Late treatment of dental trauma using apexification technique

João Eduardo **GOMES-FILHO**<sup>1</sup>  
 Camila Campos **MENDES**<sup>2</sup>  
 Simone **WATANABE**<sup>3</sup>  
 Carolina Simonetti **LODI**<sup>4</sup>  
 Marcelle **DANELON**<sup>5</sup>  
 Elói **DEZAN JÚNIOR**<sup>6</sup>  
 Mauro Juvenal **NERY**<sup>6</sup>  
 Luciano Tavares Angelo **CINTRA**<sup>7</sup>

## ABSTRACT

**Introduction:** A 37 years old male patient was admitted to the clinic of endodontics. After anamnesis it was found that the tooth #11 had coronary open access and the presence of calcium hydroxide with dental trauma history. Radiographically, the tooth had incomplete root formation, thin and fragile dentin walls and foraminal divergence associated with periapical radiolucent image.

**Objective:** To report a clinical case of apexification, performed with calcium hydroxide dressing. **Methods:** The treatment chosen was the apexification that began in the second session, after 15 days, through chemo-mechanical debridement of the entire root canal, with K files and irrigation with 2,5% sodium hypochlorite solution. Then, the calcium hydroxide paste (calcium hydroxide, iodoform and propylene glycol) was applied

and changed every 15 days over four months. The radiographic exam demonstrated the complete closure of the foraminal opening and regression of periapical radiolucency. The root canal was filled using a cone made from the union of three master cones #60 and lateral condensation technique with Sealapex®. **Results:** Six months after the filling, tests revealed normal periapical tissues and absence of symptoms. **Conclusion:** It was concluded that the treatment of dental trauma associated with dental pulp necrosis and periapical lesions with successive changes of calcium hydroxide paste was adequate to obtain the regression of periapical lesion, formation of a mineralized barrier and promotion of patient's health.

**Keywords:** Incomplete root formation. Calcium hydroxide. Apexification. Immature teeth.

**How to cite this article:** Gomes-Filho JE, Mendes CC, Watanabe S, Lodi CS, Danelon M, Dezan Júnior E, Nery MJ, Cintra LTA. Late treatment of dental trauma using apexification technique. *Dental Press Endod.* 2013 Jan-Apr;3(1):78-83.

» The authors report no commercial, proprietary or financial interest in the products or companies described in this article.

<sup>1</sup>Full Professor, UNESP. Post-Doc in Endodontics, University of Michigan.

<sup>2</sup>Graduated in Dentistry, UNESP.

<sup>3</sup>PhD in Pediatric Dentistry / Endodontics, UNESP.

<sup>4</sup>Post-Doc in Pediatric Dentistry, UNESP.

<sup>5</sup>PhD Student in Pediatric Dentistry, UNESP.

<sup>6</sup>Full Professor and PhD in Endodontics, UNESP.

<sup>7</sup>Post-Doc in Endodontics, UEM.

Received: March 03, 2013. Accepted: April 09, 2013.

Contact address: João Eduardo Gomes-Filho  
 Endodontia – Faculdade de Odontologia de Araçatuba, UNESP  
 R. José Bonifácio, 1193 – Araçatuba/ SP – CEP: 16015-050 – Brazil  
 Email: joao@foa.unesp.br

## Introduction

Trauma in young permanent teeth can produce effects such as pulp necrosis. When the pulp necrosis is linked to incomplete root formation there is a difficulty in performing a treatment, because the process of root formation by deposition of dentin ceases. The dental trauma with pulpal involvement, as well as dental caries, are generally in the main etiological factors of necrosis.<sup>1</sup> Permanent teeth with incomplete root development exhibit root canal and foramen diameter extremely large and exaggerated. The canal walls are not always parallel and present apical differences and the open foramen does not promote suitable bulkhead for filling material. Thus, it becomes difficult to keep the endodontic treatment within the limits of the root canal and especially to obturate it.

Various techniques have been described in literature to treat teeth with incomplete root formation associated with pulp necrosis. The techniques vary as a function of time and research on different authors. The apexification is the induction of the apical foramen closing through the deposition of hard mineralized tissue at the apex in teeth with pulpar necrosis.<sup>2</sup> It has been shown that mineralized tissue comprises osteocementum, osteodentine or bone, or a combination of all three in the apical region, with thickness variation.<sup>3</sup> Several studies show that the best option is filling the root canal temporarily with medicinal substances, thus inducing the apical closure.<sup>4,5,6</sup> Zinc oxide and eugenol paste have been advocated for this purpose,<sup>7</sup> as well as the polyantibiotic<sup>8</sup> and iodoformized paste.<sup>9</sup>

Currently, the cases of apexification are being treated by most professionals with the use of calcium hydroxide in resorbable pastes. The calcium hydroxide has been the material of choice for apexification since 1964, when Kaiser reported for the first time the ability to induce the biological closure of immature pulpless teeth.<sup>10</sup>

Calcium hydroxide has been nominated for apexification because of its alkaline pH and for presenting a high antibacterial effect, inhibiting osteoclastic activity and preventing the entry of exudate and granulation tissue. Several long term studies have shown a success rate of 74-100% for apexification cases using calcium hydroxide.<sup>11-19</sup>

The aim of this study was to report a case of apexification performed with dressing changes of calcium hydroxide.

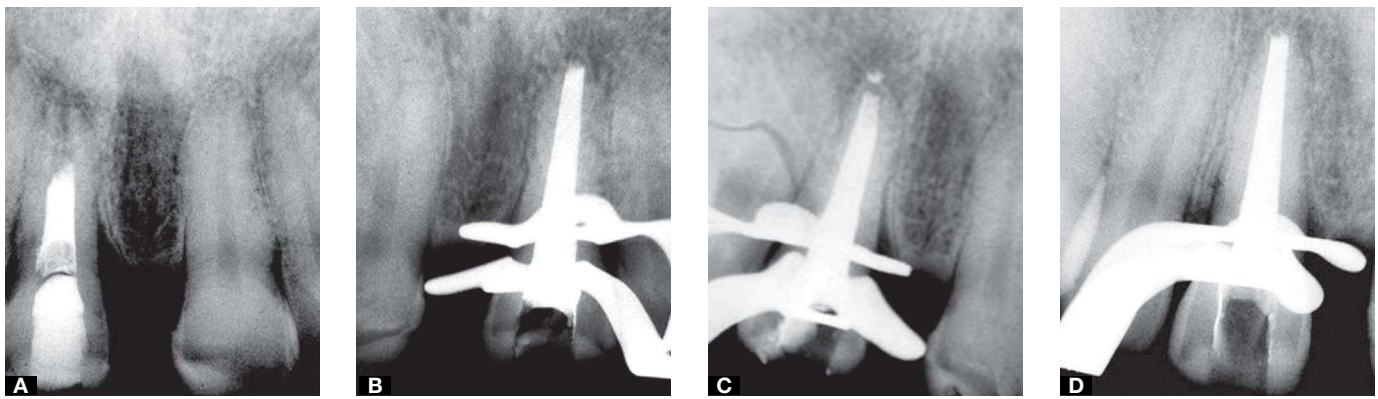
## Case report

The patient, 37 year-old, entered the clinic of endodontics, School of Dentistry of Araçatuba - UNESP, with a history of dental trauma in the permanent central incisor and lack of sensitivity. On clinical examination, it was observed the presence of coronary opening sealed with temporary material, lack of mobility and normal periodontal probing. Radiographs (Fig 1A) showed the presence of radiopaque material compatible with calcium hydroxide paste and iodoform filling the root canal with incomplete apex. The proposed treatment was apexification using calcium hydroxide paste.

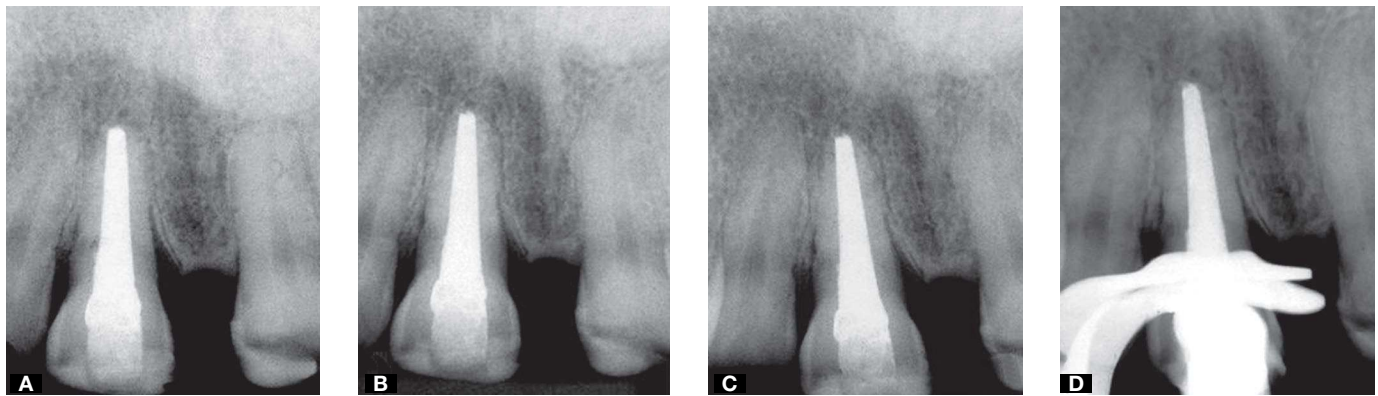
In the second appointment, odontometry was performed with the file dimensioned to the temporary work length that was obtained based on previous radiographs. The patient was anesthetized with Citanest (Dentsply, Rio de Janeiro, Brazil), the tooth was isolated with rubber dam and the temporary restoration was removed. The root canal was irrigated with a solution of 2.5% sodium hypochlorite and the calcium hydroxide that was in the canal root was removed. Following was done biomechanical preparation around the root canal with K files and irrigation with a solution of 2.5% sodium hypochlorite, caring not to reach the periapical tissues and not excessively wear out the root walls. The canal was instrumented to K file #80 and the working length was set at 20 mm, coinciding with the radiographic apex, always being careful not to wear out the walls, irrigating thoroughly with 2.5% sodium hypochlorite. The smear layer was removed with 17% EDTA and was performed the final irrigation with sodium hypochlorite. The canal was dried with absorbent paper points sterilized and then filled with calcium hydroxide paste (calcium hydroxide, iodoform and propylene glycol) using a lentulo spiral calibrated to 3 mm of work length, to avoid leakage of the paste (Fig 1B).

The exchange of calcium hydroxide paste was carried out each 15 days until complete formation of calcified tissue barrier, detected by clinical and radiographic examination (Figs 1C and 1D; Figs 2A-C). The time required for formation of the apical barrier was four months (Fig 2D).

The tooth was filled with the sealer Sealapex® (SybronEndo, Glendora, California, USA) and lateral condensation technique (Fig 3A). For this, the gutta-percha master cone was made from the union of three cones #60. The cone was taken to the work length and



**Figure 1.** Periapical radiographs of the upper right central incisor. **A)** Diagnostic radiographic exam. Note the radiopaque intracanal dressing partially filling the root canal and the provisional restoration with radiopaque material and incomplete root formation. **B)** Radiographic exam performed in the second appointment, in the end of the treatment, consisting of biomechanical preparation and intracanal dressing with calcium hydroxide paste and iodoform. **C)** Radiographic exam at the third appointment, in the end of the treatment, consisting of careful biomechanical preparation and change of intracanal dressing with calcium hydroxide paste and iodoform. **D)** Radiographic exam at the fourth appointment, in the end of the treatment, consisting of careful biomechanical preparation and change of intracanal dressing with calcium hydroxide paste and iodoform.



**Figure 2.** Periapical radiographs of the upper right central incisor. **A)** Radiographic exam at the fifth appointment, in the end of the treatment, consisting of careful biomechanical preparation and change of intracanal dressing with calcium hydroxide paste and iodoform. **B)** Radiographic exam at the sixth appointment, in the end of the treatment, consisting of careful biomechanical preparation and change of intracanal dressing with calcium hydroxide paste and iodoform. **C)** Radiographic exam at the seventh appointment, in the end of the treatment, consisting of careful biomechanical preparation and change of intracanal dressing with calcium hydroxide paste and iodoform, note the apical closure. **D)** Radiograph proving obturation by lateral condensation technique and Sealapex, in the eighth appointment.

a periapical radiograph was performed to proof length (cone test). A signal was made on the cone with clinical tweezers marking the reference point. After cone test, the sealer was prepared from a portion of homogenized base paste with a portion of the catalyst paste on a glass plate sterilized. The cone was smeared with sealer and settled in the root canal. The length was observed by the coincidence of the mark on the cone with the reference point. Spacing was initially carried out with spacers A30 (Maillefer Instruments, Switzerland)

and removed with semicircular clockwise and counter-clockwise movement with slight pressure towards incisal. Immediately after the spacing, a B7 cone (Dentsply, Rio de Janeiro, Brazil) was settled in the space obtained. The process was repeated in order to set four cones B7. Then, new spacings were made with spacer A40 (Maillefer Instruments, Switzerland) and settlement of B8 cones (Dentsply, Rio de Janeiro, Brazil) until complete filling of the canal. In this moment a radiograph was performed to confirm the filling.

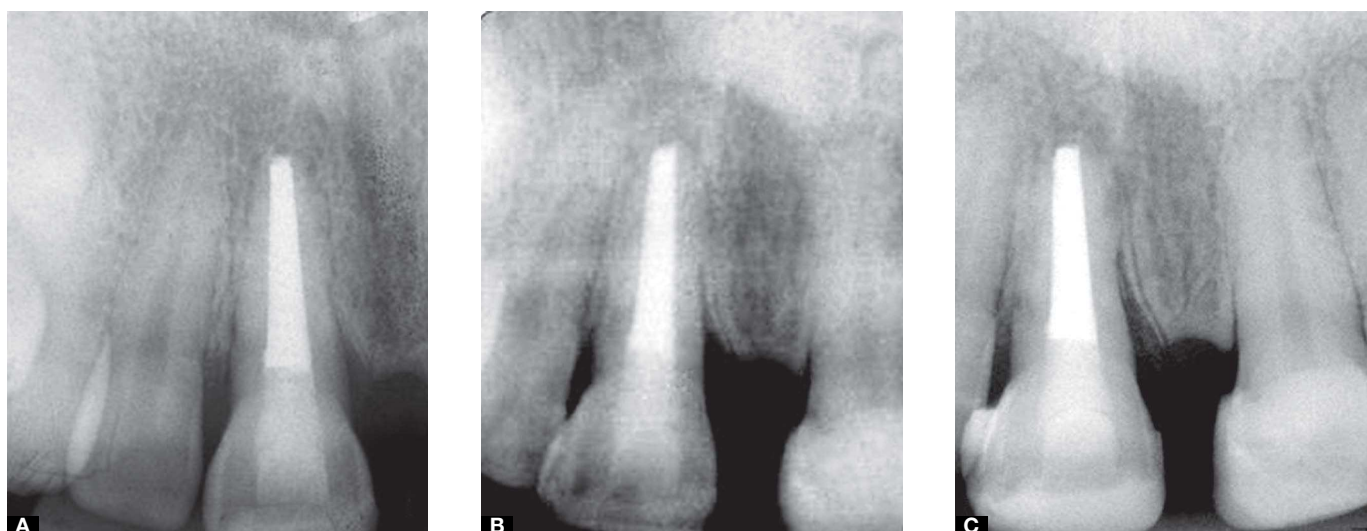
Then, the cones were cut at the height of the orifice of the canal using heated Paiva condenser #4. A cotton ball soaked in alcohol was used to clean the remnants of filling material in the pulp chamber and coronal sealing was accomplished with glass ionomer cement (Vidrion R, SS White). The final periapical radiograph revealed dense and homogeneous obturation, associated with the filling of apical branching in the root segment newly formed (Fig 3A).

Six months after the final treatment, a new periapical radiograph was performed and revealed complete disappearance of the lesion and absence of signs and symptoms (Fig 3B). At 18 months of postoperative control, there was again complete disappearance of the lesion and apical closure, confirming the successful treatment (Fig 3C).

## Discussion

Immature permanent incisors with open apices can lose their vitality, as a result of trauma, which leads to root development stoppage. The root canal treatment in such cases becomes difficult due to the open apex. However, with the apexification technique, which consists in inducing the closing of the apical foramen through the deposition of hard mineralized tissue, root canal treatment may be well conducted.<sup>20</sup>

Immature permanent teeth and pulp necrosis require the use of a dressing for the occurrence of hard tissue deposition in the apical region for a period of time.<sup>14,21</sup> Traditionally, the most commonly used material for apexification is calcium hydroxide, which stimulates formation of mineralized and fibrous tissue by cells of the granulation tissue in the apical portion of the root.<sup>18,22</sup>



**Figure 3.** Periapical radiographs of the upper right central incisor. **A)** Radiographic exam at the eighth appointment, at the end of the obturation by the lateral condensation and Sealapex. **B)** Radiographic exam for 6-month postoperative control; note the total remission of the lesion and apical closure. **C)** Radiographic exam for 18-month postoperative control; note the total remission of the lesion and apical closure.

In the present clinical case it was chosen the use of calcium hydroxide, following the example of various studies which demonstrated a high degree of clinical success.<sup>14,23,24,25</sup>

As to the period of time to the exchange of calcium hydroxide, to induce apical closure and normal periapical tissues,<sup>18</sup> there is no consensus among the authors. Some suggest that the change is initially made in a month and subsequently each interval of three months.<sup>20</sup> Other authors believe that a single application of calcium hydroxide paste is sufficient to form the barrier.<sup>11</sup> Another indication is to change only if there is reabsorption of calcium hydroxide in the apical third of the root canal.<sup>19,26</sup> In this clinical case was chosen to make the exchange of calcium hydroxide each 15 days, until there was a complete barrier formation of calcified tissue.

A study on the index of apical barrier formation showed that it was directly proportional to the frequency of renewal of the paste.<sup>27</sup> However, another study, in dogs, reported that replacement of the calcium hydroxide paste was not required to occur the apexification in teeth with incomplete root formation, however, it significantly reduced the intensity of the inflammatory process<sup>14</sup> and a simple application of calcium hydroxide paste with

monthly applications or renewals every three months showed that the amount of calcified tissue formed was similar in the three groups.<sup>28</sup>

Calcium hydroxide is capable of inducing the formation of a hard tissue barrier, and in addition, is also capable of stimulating tissue repair. When placed in direct contact with the pulp tissue, there is an immediate and short-term reaction of the tissue, supposedly caused by high alkalinity. This effect is alkaline due to the release of hydroxyl ions, which, in contact with vital tissues, produce morphological alterations that are characterized histologically by the presence of self limiting superficial necrosis in its initial phase. It has also been reported that the alkaline environment prevents the growth of bacteria, which is very important, as tissue repair and deposition of mineralized tissue only occur in the absence of an infectious process.<sup>26</sup>

## Conclusion

It was concluded that treatment of dental trauma associated with necrosis of the pulp tissue and periapical lesions with successive changes of calcium hydroxide paste was adequate to obtain the regression of periapical lesion, formation of a mineralized barrier and health promotion for the patient.



## References

- Lopes HP, Siqueira Junior JF. *Endodontia: Biologia e técnica*. 2a ed. Rio de Janeiro: Ed. Guanabara Koogan; 2004.
- Soares IJ, Goldberg F. *Endodontia: técnica e fundamentos*. 2a ed. Porto Alegre: Ed. Artes Médicas; 2001.
- Nicholls E. *Endodontics*. 2a ed. Bristol: J Wright; 1977.
- Ghose LJ, Baghdady VS, Hikmat BYM. Apexification of immature apices of pulpless permanent anterior teeth with calcium hydroxide. *J Endod*. 1987;13(6):285-92.
- Leite RMGV, Abbud R. Tratamento de canal radicular de dentes com rizogênese incompleta empregando pasta de hidróxido de cálcio, estudo radiográfico. *Rev Odontol Unesp*. 1986-1987;15-16:1-12.
- Leonardo MR, Bezerra da Silva LA, Utrilla LS, Leonardo Rde T, Consolaro A. Effect of intracanal dressings on repair and apical bridging of teeth with incomplete root formation. *Endod Dent Traumatol*. 1993;9(1):25-30.
- Cooke C, Rowbothan TC. Root canal therapy in non vital teeth with open apices. *Br Dent J*. 1960;108(4):147-50.
- Ball JS. Apical root formation in a non vital immature permanent incisor: report of a case. *Br Dent J*. 1964;18(116):166-7.
- Rule DC, Winter GB. Root growth and apical repair subsequent to pulpal necrosis in children. *Br Dent J*. 1966;120(12):586-90.
- Rafter M. Apexification: a review. *Dent Traumatol*. 2005;21(1):1-8.
- Chawla HS. Apical closure in a nonvital permanent tooth using one Ca(OH)<sub>2</sub> dressing. *ASDC J Dent Child*. 1986;53(1):44-7.
- Cvek M. Treatment of non-vital permanent incisors with calcium hydroxide. I. Follow-up of periapical repair and apical closure of immature roots. *Odontol Revy*. 1972;23(1):27-44.
- Cvek M. Prognosis of luxated non-vital maxillary incisors treated with calcium hydroxide and filled with gutta-percha. A retrospective clinical study. *Endod Dent Traumatol*. 1992;8(2):45-55.
- Felippe MC, Felipe WT, Marques MM, Antoniazzi JH. The effect of the renewal of calcium hydroxide paste on the apexification and periapical healing of teeth with incomplete root formation. *Int Endod J*. 2005;38(7):436-42.
- Kleier DJ, Barr ES. A study of endodontically apexified teeth. *Endod Dent Traumatol*. 1991;7(3):112-7.
- Mackie IC, Hill FJ. A clinical guide to the endodontic treatment of non-vital immature permanent teeth. *Br Dent J*. 1999;186(2):54-8.
- Reyes DA, Munoz Munoz L, Martin TA. Study of calcium hydroxide apexification in 26 young permanent incisors. *Dent Traumatol*. 2005;21(3):141-5.
- Sheehy EC, Roberts GJ. Use of calcium hydroxide for apical barrier formation and healing in non-vital immature permanent teeth: a review. *Br Dent J*. 1997;183(7):241-6.
- Yates JA. Barrier formation time in non-vital teeth with open apices. *Int Endod J*. 1988;21(5):313-9.
- Mackie IC. UK National Clinical Guidelines in Paediatric Dentistry. Management and root canal treatment of non-vital immature permanent incisor teeth. Faculty of Dental Surgery, Royal College of Surgeons. *Int J Paediatr Dent*. 1998;8(4):289-93.
- Soares J, Santos S, César C, Silva P, Sá M, Silveira F, et al. Calcium hydroxide induced apexification with apical root development: a clinical case report. *Int Endod J*. 2008;41(8):710-9.
- Vojinovic O. Induction of apical formation in immature teeth by different endodontic methods of treatment. *J Oral Rehabil*. 1974;1(1):91-7.
- Dylewski JJ. Apical closure of non-vital teeth. *Oral Surg Oral Med Oral Pathol*. 1971;32(1):82-9.
- Frank AL. Therapy for the divergent pulpless tooth by continued apical formation. *J Am Dent Assoc*. 1966;72(1):87-93.
- Mackie IC, Bentley EM, Worthington HV. The closure of open apices in non-vital immature incisor teeth. *Br Dent J*. 1988;165(5):169-73.
- Foreman PC, Barnes IE. A review of calcium hydroxide. *Int Endod J*. 1990;23(6):283-97.
- Kinirons MJ, Srinivasan V, Welbury RR, Finucane D. A study in two centres of variations in the time of apical barrier detection and barrier position in nonvital immature permanent incisors. *Int J Paediatr Dent*. 2001;11(6):447-51.
- Chosack A, Sela J, Cleaton-Jones P. A histological and quantitative histomorphometric study of apexification of nonvital permanent incisors of vervet monkeys after repeated root filling with a calcium hydroxide paste. *Endod Dent Traumatol*. 1997;13(5):211-7.