

Importance of diagnosing invasive cervical resorption

Marilúcia Zugno **KULCZYNSKI**¹

Fernando Zugno **KULCZYNSKI**²

Fernando Antonio da Silva **RABALDO**³

Michele Machado **VIDOR**⁴

Mariana Boessio **VIZZOTTO**⁵

doi: <http://dx.doi.org/10.1590/2178-3713.4.2.062-068.oar>

ABSTRACT

Root resorption is the loss of dental hard tissues as a result of physiological or pathological clastic activity. Invasive cervical resorption is the clinical term used to describe a pathological form of relatively uncommon, insidious and aggressive resorption of the tooth, which may be asymptomatic and often undiagnosed, and occur in any tooth of the permanent dentition. It is usually a casual finding of radiographic routine or initial orthodontic records. This paper reports a case of invasive cervical resorption, and aims

to raise awareness of potential occurrence of this type of lesion and highlight the importance of early diagnosis by dentists, radiologists and orthodontists who are often the first specialists to come across these kinds of images. Treatment will rely on the development of the lesion. In its initial stage, conservative therapy can be applied; while in advanced cases, radical treatment, such as tooth extraction, is the therapy of choice. The severity of the lesion will guide the choice for the best procedure.

Keywords: Diagnosis. Radiography. Endodontics.

How to cite this article: Kulczynski MZ, Kulczynski FZ, Rabaldo FAS, Vidor MM, Vizzotto MB. Importance of diagnosing invasive cervical resorption. *Dental Press Endod.* 2014 May-Aug;4(2):62-8. DOI: <http://dx.doi.org/10.1590/2178-3713.4.2.062-068.oar>

¹Specialist in Endodontics, Lutheran University of Brazil (ULBRA).

²MSc in Oral and Maxillofacial Surgery and Traumatology, Catholic University of Rio Grande do Sul (PUC/RS).

³Postgraduate in Orthodontics, Foundation for Studies and Treatment of Craniofacial Abnormalities (FUNCRAF).

⁴MSc student in Dentistry, Federal University of Rio Grande do Sul (UFRGS).

⁵Adjunct professor, UFRGS.

» The authors report no commercial, proprietary or financial interest in the products or companies described in this article.

» Patients displayed in this article previously approved the use of their facial and intraoral photographs.

Submitted: January 21, 2014. Revised and accepted: February 10, 2014

Contact address: Marilúcia Zugno Kulczynski
E-mail: mari_zk@hotmail.com

Introduction

Root resorption is the loss of dental hard tissues as a result of physiological or pathological clastic activity. An example of physiological root resorption is the exfoliation of deciduous teeth. The factors involved in the onset of physiological resorption of primary teeth have not been fully clarified, although the process seems to be governed by cytokines and transcription factors similar to those involved in bone remodeling. Unlike bones, which undergo continuous physiological remodeling in a lifetime, root resorption of permanent teeth is not a natural process. On the contrary, it is a pathological condition that, if untreated, may cause premature loss of affected teeth.¹³

Establishing the causes of crown and/or root resorption requires careful examination of patient's medical record, which should include previous dental history, accidents, treatments, associated pathologies, and all details that may be relevant in the etiology of the pathology, although they may not be recalled by the patient.⁶

Criteria used to classify pathological resorption are:

- » Affected tooth surface: internal, external, internal-external.
- » Stage of development: active, paralyzed or repaired.
- » Affected tooth region: crown, cervical, lateral or apical root surface.
- » Extent of damage: simple or multiple.
- » Extent of the cause: local, systemic, idiopathic.
- » Mechanism of action: inflammatory or replacement (substitutive).¹

Invasive cervical resorption (ICR) is a clinical condition that remains not fully understood in Dentistry. In many cases, the pathology is not correctly identified and diagnosed. Even when it is, there is no consensus on the best course of treatment. Mistaken interpretations of diagnosis and characteristics of ICR are partially due to the fact that the condition is labeled under different names in the literature, namely: odontoclastoma, idiopathic external resorption, peripheral cervical resorption, cervical external resorption, extra-canal invasive resorption, supraosseous extra-canal invasive resorption, peripheral inflammatory root resorption, asymmetric internal resorption, intradental progressive resorption, or simply cervical resorption.¹⁶ When location of the lesion is considered, the condition is called cervical external resorption.^{4,12}

ICR begins in the cervical region of the tooth. Furthermore, it is highly variable in size, from a small orifice to a large area of dentin reabsorbed between the cement and the pulp. The initial stage generally evolves fast, which explains why it is called invasive cervical resorption. It is characterized by invasion of the root cervical region by fibrovascular tissue containing clastic cells that gradually reabsorb cement, dentin and enamel. In this process, the pulp remains protected by an intact layer of dentin and pre-dentin for a considerably long period. Ectopic calcifications may be observed in advanced lesions, both in the fibrovascular tissue and as deposits on the reabsorbed dentin.

This study presents a literature review and a case report of ICR diagnosed by panoramic radiographs. The aim is to raise awareness of this pathology and highlight the importance of early diagnosis by dentists, especially radiologists, pediatricians and orthodontists who are often the professionals who first come across images suggestive of ICR in their practice.

Case report

A 10-year-old female patient was diagnosed with ICR during orthodontic treatment in the upper and lower first molars #16, 36 and 46.

The patient attended her first appointment in February 2007, at the age of 7 years 9 months, when she was referred to orthodontic evaluation. Clinical examination did not reveal any changes and the patient did not complain of pain or any other symptom. A panoramic radiograph was requested to assess the development of dentition and the presence of all permanent teeth. No resorption was noticed in this first radiograph (Fig 1).

In March 2009, when the patient was 9 years old, a new panoramic radiograph was requested as a follow-up approach to rhizolysis of deciduous teeth and to the eruption of permanent teeth. Again, no change was diagnosed (Fig 2). In December 2009, a third panoramic follow-up radiograph was requested. In March 2010, the patient was 10 years old and presented the radiograph requested in December 2009 (Fig 3). This image revealed the presence of radiolucent lesions in first molars #16, 36 and 46. Lesions in teeth #16 and 46 were larger (similar to large caries in aspect), while the lesion in tooth #36 was smaller and there was no evidence of lesion in tooth #26. At that moment, ICR was suspected due to the clinical and radiographic

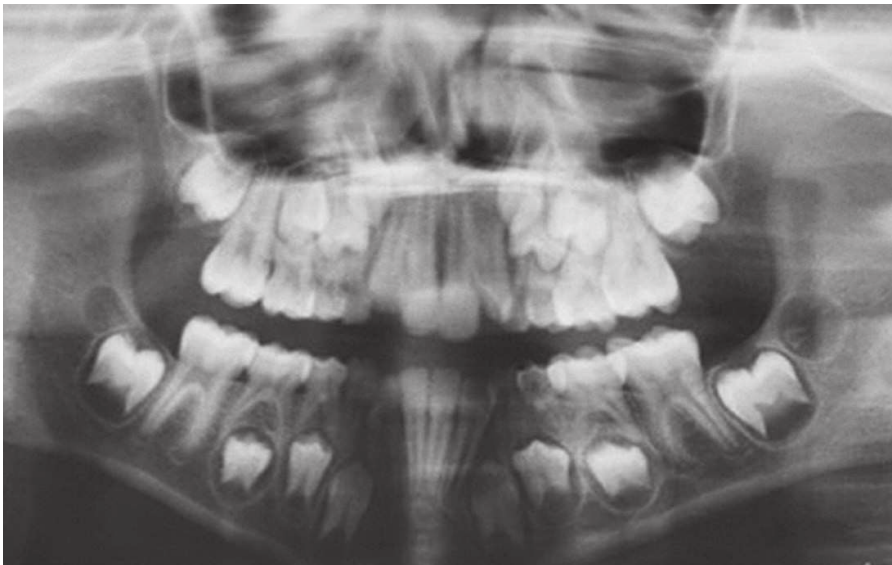


Figure 1. First panoramic radiograph.

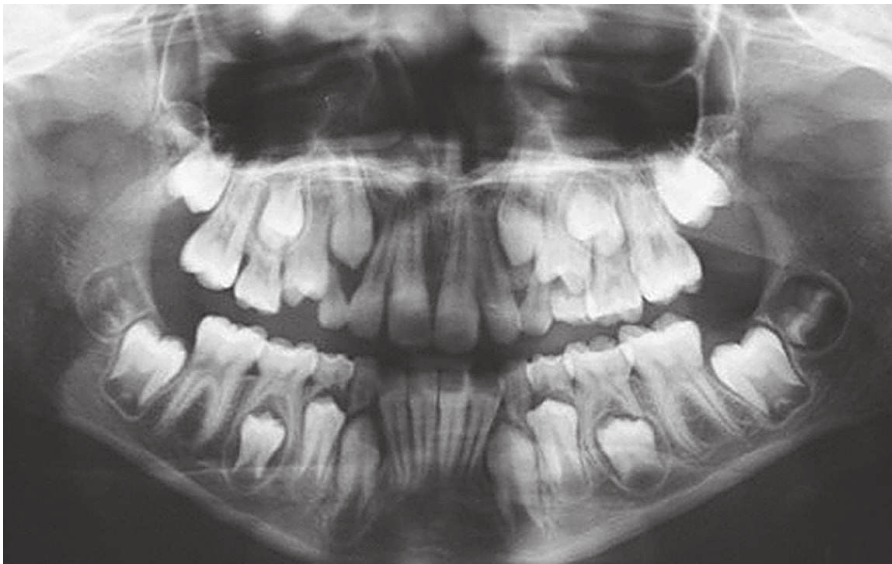

Figure 2. Second panoramic radiograph.

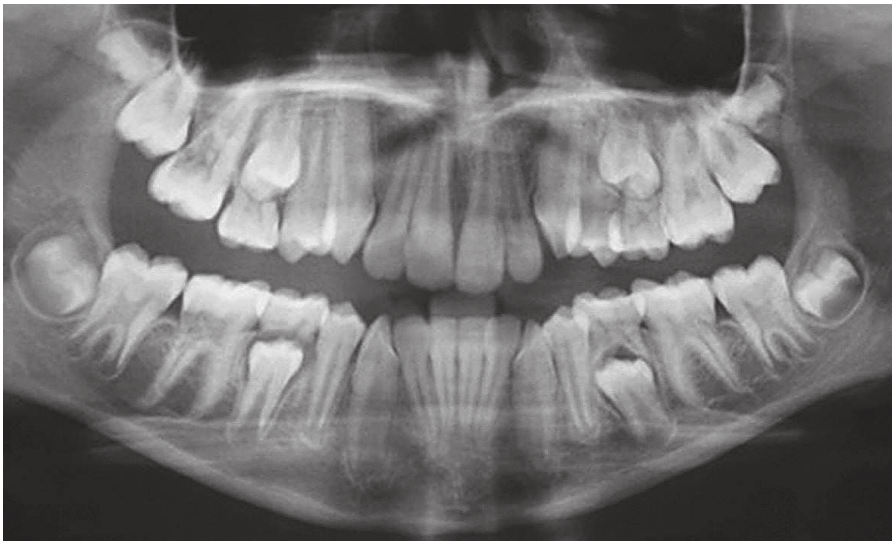


Figure 3. Third panoramic radiograph.

characteristics of lesions and to the fact that the patient clearly kept good oral hygiene habits. Upon clinical examination, root canal communication became evident. The patient's guardian was then informed that the latest radiograph revealed changes that had not been diagnosed in the previous images. Treatment choices were explained, and it was decided that the affected teeth should be extracted. In June 2010, the patient was referred to an oral and maxillofacial surgeon who extracted the teeth as planned. With the new orthodontic planning and as a result of the extraction of teeth #16, 36 and 46, the patient is current under treatment. Second molars are being tractioned to the space left by the first molars extracted, while third molars are being repositioned to the space left by the second molars, already tractioned.

Discussion

The etiology of ICR is poorly understood, although the characteristics of tooth anatomy (cemento-enamel junction, CEJ) have been accepted as predisposing factors for cervical resorption.¹² The relationships between the enamel and the cement in the CEJ may take three distinct shapes: The cement covers the enamel (Fig 4A); the cement contacts the enamel without covering it, so that the two tissues are end-to-end and the edges of both touch (Fig 4B); and the cervical edge of the cement is distant from the enamel, leaving a small area of dentin exposed to the gingival conjunctive tissue (Fig 4C). This space is known as gap.⁴

The precise reason behind this resorption pattern is unclear. It may be the result of a variety of inflammatory, traumatic or bacterial stimuli to the clastic cells in the periodontal ligament. This phenomenon has been observed after orthodontic treatment, orthognathic surgery, dentoalveolar surgery, root wear and smoothing, intracrown whitening, local trauma, bruxism and tooth fracture.¹¹ Pulp tissue does not play any etiological function in this pathology. When this tissue is not affected by the pathology, it may be treated without risks to pulp vitality.¹⁵

In early-stage lesions, fibrovascular tissue and clastic cells are found on the dentin surface. Histopathologically, ICR is similar to external inflammatory resorption, but the granulation tissue is inserted into the reabsorbed cavity. This aseptic process has no inflammatory cells, except in the cases when there is

invasion of microorganisms from the mouth to the reabsorbed region. Bacterial contamination may develop with the progression of the lesion, thereby inducing inflammatory response associated with the periodontal tissue.^{12,17} In terms of penetration of bacteria into the gingival sulcus, these microorganisms may move towards the crown or the apex in the tubular dentin, without entering the pulp space, but stimulating ICR.⁷ In more advanced stages, ectopic bone reposition may occur both inside the fibrovascular tissue and in the surface of the reabsorbed dentin.⁹

Classification

ICR is grouped into four classes (Fig 5), based on the extension of the lesion and on the damage caused to mineralized tissues.⁹

- » Class 1: Small invasive resorptive lesion near the cervical area with shallow penetration into the dentin.
- » Class 2: A well-defined invasive resorptive lesion that penetrates close to the coronal pulp chamber, but shows little or no extension into the root dentin.
- » Class 3: Deeper invasion of dentin by resorption that involves the coronal third of the root.
- » Class 4: Large invasive resorptive process that extends beyond the coronal third of the root canal.⁹

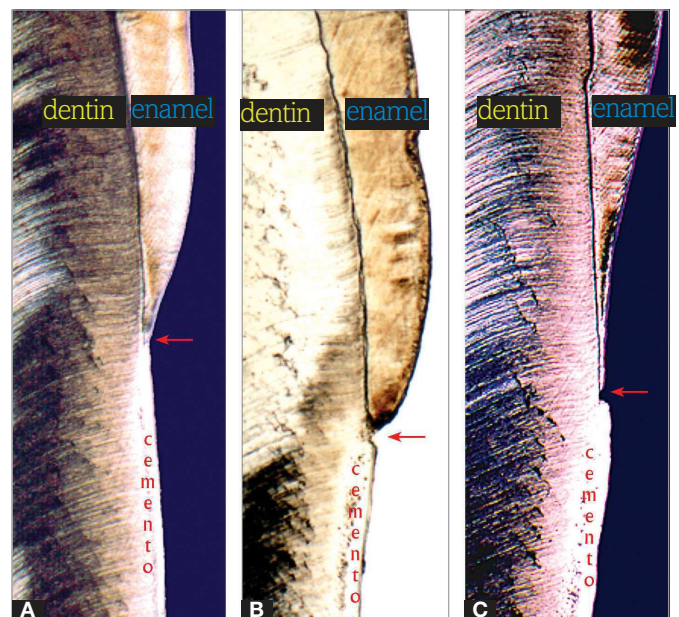


Figure 4. Anatomical relationships between the enamel and the cement in the cemento-enamel junction (Source: Consolaro, 2012⁴).

Diagnosis

ICR is usually an accidental finding diagnosed during routine clinical examination or radiographs.⁸ Clinically, the early stages of ICR are not evident upon examination. The condition is detected visually only when the granulation tissue increases in size and becomes perceptible based on the transparency of the tooth in the region affected, which is pinkish-reddish in color.

In radiographs, ICR is observed either as poorly (irregular edges that sometimes look like caries) or well-defined, obvious radiolucency. In early stages, lesions may be symmetrical, although larger ones that have evolved for a while tend to be asymmetrical.¹⁴ External resorption is typically characterized by loss of tooth structure, which looks like a “moth eaten” surface in which low radiolucency indicates the existence of differences in density.¹¹

Assessment of ICR lesions reveals that interproximal radiographs are a limited diagnosis tool. However, considering that these lesions are rare, this imaging method may be useful as a follow-up approach in patients with predisposing factors.¹⁶

Cone beam computed tomography (CBCT) is indicated to confirm diagnosis and obtain more accurate information on the extension of lesions as well as to define treatment options and prognosis in more advanced cases.^{4,12}

CBCT was introduced in Dentistry to improve visualization and handling of images of difficult areas in the neck and head. CBCT presents some advantages in Dentistry, namely: the possibility to examine specific regions in restricted fields of view; the speed to carry out exams and the possibility to reconstruct images easily. In addition, metallic artifacts, which affect image quality, can be reduced; it is less expensive to operate and the equipment is smaller when compared to the tomographs used in medicine.⁵

In ICR assessment, CBCT affords accurate views of the extension of resorption in three dimensions. The technique also allows assessing the depth of the lesion in the root canal, its actual lingual or palatal extent, and the possibilities to restore the affected tooth before any other treatment approach is started. When no diagnostic tool that enables three-dimensional visualization is available, treatment strategies or prognosis cannot be established before surgical exposure of ICR.⁵

Differential diagnosis

When ICR is considered a stage of external resorption¹¹ or as cervical external resorption,⁴ its prevalence increases; however, diagnosis is often inaccurate and differential diagnosis is required. Several cases of cervical external resorption are mistaken for cervical carious lesion or erosion, abrasion and even abfraction.

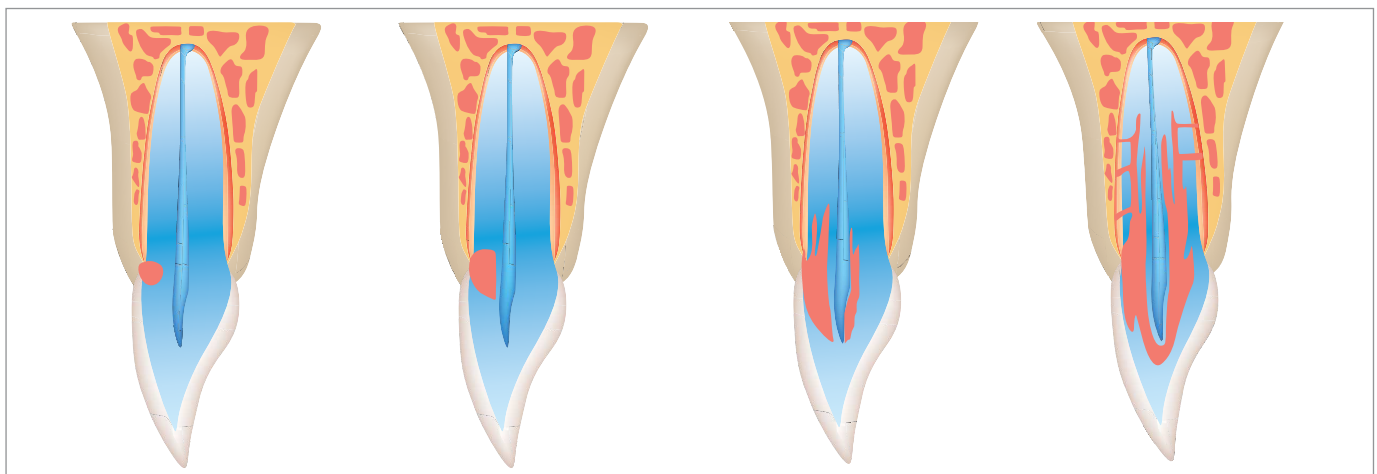


Figure 5. Classification of invasive cervical resorption (Source: Hethersay⁹, 1999).

The importance of differential diagnosis of ICR with caries should not be underestimated, especially based on imaging exams. The hypothesis of cervical caries is quickly considered in cases of deep cervical lesions due to the fact that this type of caries is highly prevalent and has been intensively studied.³

Misdiagnosis also occurs between ICR and coronal internal resorption, since the two conditions share the presence of pink spots or dots on the crown, under preserved enamel surface. Since the enamel is transparent, it may allow visualization of an underlying resorption process characterized by an inflammatory process associated with numerous dilated and congested blood vessels in both types of resorption.²

Whenever possible, image-based reports should be descriptive, since the types of tooth resorption vary considerably. The correct full name of the suspected type of tooth resorption has to be clearly stated, since it indicates the nature, etiology and location of the process. Image-based reports aim to render treatment planning easier and to prepare a clear prognosis. When these reports contain clarifying descriptions and observations, they represent a useful tool in clinical applications.³

Prognosis

Success in ICR treatment and prognosis relies on its early and accurate diagnosis associated with clear assessment of the extent of the resorption process.¹⁴

Considering the follow-up phase of treatments that include mechanical and chemical abrasion of resorption processes, Heithersay¹⁰ reported that cases of small, local lesions (class 1 or 2) yielded successful treatment results near 100%. Conversely, intermediate lesions (class 3) had a success rate of 77.8%, while extreme cases (class 4) did not yield successful treatment outcomes (12.5%).

Final considerations

ICR may be a casual finding in radiographic routine exams required by dentists. Therefore, knowledge of this condition and awareness of the slight changes observed in radiographs are important. Since early-stage ICR is not usually identified by clinical exams, radiographs become more important to obtain the correct diagnosis of the condition. Diagnosis of ICR should be confirmed after careful clinical and radiographic exam of the affected region, with differential analysis against cervical caries, coronal internal resorption and burnout. In-depth diagnosis of the lesion and the decision about the best treatment approach should be based on CBCT with restricted field of view. In addition to using a lower radiation dose, this exam enables assessment of the affected area in three dimensions, which precisely reveals the extent and location of the resorptive lesion and helps the clinician to choose the best treatment choice for the pathology.

References

1. Consolaro A. Reabsorções dentárias nas especialidades clínicas. 2ª ed. Maringá: Dental Press; 2005.
2. Consolaro A, Francischone L, Consolaro RB, Francischone CE. Reabsorção cervical externa versus reabsorção interna coronária: diagnóstico diferencial e implicações terapêuticas e estéticas. *Rev Dental Press Estét.* 2010;7(3):128-35.
3. Consolaro A, Francischone CE, Consolaro RB, Francischone LA. Reabsorção cervical externa e cárie de colo: diagnóstico diferencial e implicações clínicas. *Rev. Dental Press Estét.* 2011;8(4):124-34.
4. Consolaro A. Reabsorções dentárias nas especialidades clínicas. 3ª ed. Maringá: Dental Press; 2012.
5. Estevez R, Aranguren J, Escorial A, de Gregorio C, De La Torre F, Vera J, et al. Invasive cervical resorption class III in a maxillary central incisor: diagnosis and follow-up by means of cone-beam computed tomography. *J Endod.* 2010;36(12):2012-14.
6. Francischone TRCG. Reabsorção dentária: determinação de sua frequência em pacientes com endocrinopatias [tese]. Bauri (SP): Universidade de São Paulo; 2002.
7. Fuss Z, Tsesis I, Lin S. Root resorption: diagnosis, classification, and treatment choices based on simulation factors. *Dent Traumatol.* 2003;19(4):175-82.
8. Gulsahi A, Gulsahi K, Ungor M. Invasive cervical resorption: clinical and radiological diagnosis and treatment of 3 cases. *Oral Surg Oral Med Oral Pathol Oral Radiol Endod.* 2007;103(3):e65-72.
9. Heithersay GS. Radiologic and histopathologic features of invasive cervical resorption. *Quintessence Int.* 1999;30(1):27-37.
10. Heithersay GS. Invasive cervical resorption: an analysis of potential predisposing factors. *Quintessence Int.* 1999;30(2):83-95.
11. Neville BW, Damm DD. *Patologia oral e maxilofacial.* 3ª ed. Rio de Janeiro: Elsevier; 2009.
12. Patel S, Kanagasingam S, Pitt Ford T. External cervical resorption: a review. *J Endod.* 2009;35(5):616-25.
13. Patel S, Ricucci D, Durak C, Tay F. Internal root resorption: a review. *J Endod.* 2010;36(7):1107-21.
14. Schwartz RS, Robbins W, Rindler E. Management of invasive cervical resorption: observations from three private practices and a report of three cases. *J Endod.* 2010;36(10):1721-30.
15. Silva EJNL, Carvalho NK, Carvalho FR, Capelli Júnior J, Coutinho Filho TS. Abordagem endodôntica e visão ortodôntica da reabsorção cervical externa: relato de caso. *ROBRAC.* 2011;20(52):94-8.
16. Thönen A, Peltomäki T, Patcas R, Zehnder M. Occurrence of cervical root resorption in first and second molar teeth of orthodontic patients eight years after bracket removal. *J Endod.* 2013;39(1):27-30.
17. Trope M. Root resorption due to dental trauma. *Endod Topics.* 2002;1(1):79-100.