

# A new option for complete isolation in Endodontics

Sérgio Henrique Staut **BRUNINI**<sup>1</sup>  
Renan Lucas da Silva **PIMENTA**<sup>2</sup>  
Lucas Rafael Rodriguez de **SOUZA**<sup>2</sup>

## ABSTRACT

**Introduction:** Despite some professional resistance, absolute isolation remains indispensable in dental therapy, especially in Cosmetic Dentistry and Endodontics. Several types of rubber dam are available in the market, and all of them have different technical features. OptiDam<sup>®</sup> is a three-dimensional dam with reduced tension on the clamps, and due to being mounted near the mucosa, it widens the accessible oral area in a satisfactory way. **Objective:** The present study reports two clinical

cases with a view to discussing OptiDam<sup>®</sup> clinical application. **Results:** OptiDam<sup>®</sup> proved superior in terms of patient's comfort and easy application; however, it has disadvantages regarding cost and the moment of radiographic examination. **Conclusion:** OptiDam<sup>®</sup> proved clinically feasible despite a few drawbacks.

**Keywords:** Endodontics. Rubber dam. Root canal preparation.

**How to cite this article:** Brunini SHS, Pimenta RLS, Souza LRR. A new option for complete isolation in Endodontics. *Dental Press Endod.* 2014 May-Aug;4(2):83-7. DOI: <http://dx.doi.org/10.1590/2178-3713.4.2.083-087.oar>

» The authors report no commercial, proprietary or financial interest in the products or companies described in this article.

» Patients displayed in this article previously approved the use of their facial and intraoral photographs.

Submitted: November 12, 2013. Revised and accepted: December 19, 2013.

<sup>1</sup>Adjunct professor of Dentistry, UNIPAR.

<sup>2</sup>Undergraduate student of Dentistry, UNIPAR.

Contact address: Sérgio Henrique Staut Brunini  
Rua Bartira, 2745 – Jardim São Marcos – Umuarama/PR – Brazil  
CEP: 87.501-440 – Email: [brunini@unipar.br](mailto:brunini@unipar.br)

## Introduction

Procedures carried out in the oral cavity pose difficulties for the dental surgeon, namely: the presence of saliva as well as microorganisms and lack of control of patient's soft tissues and tongue. These factors might affect the quality of dental procedures. For this reason, there has been an ongoing search for means of controlling them, which would increase the chances of dental therapy success.<sup>1</sup>

In 1864, Sanford C. Barnum developed the concept of absolute isolation which enabled dental therapy to be carried out in a favorable environment. Conceição and Soares<sup>2</sup> report that isolation creates an aseptic oral environment free of humidity and prevents patients from swallowing material, which protects them and eases dental procedures. Absolute isolation consists in using a rubber dam attached to the teeth by a clamp and a frame that ensures the dam remains stretched out so as to allow only the teeth subjected to treatment to remain exposed. Nevertheless, using a rubber dam might be highly complex in some situations; for instance, in cases of teeth with significant loss of the crown due to caries or fracture and teeth prepared for porcelain-fused-to-metal restoration.<sup>3</sup>

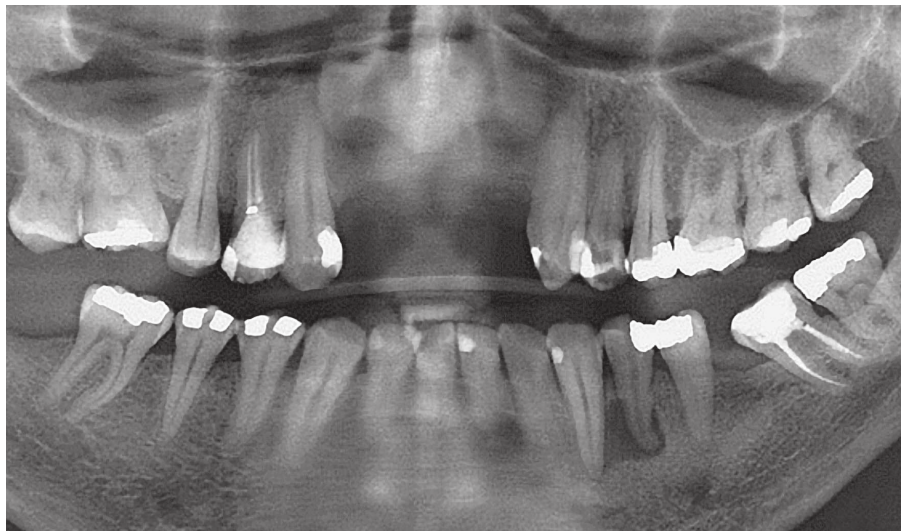In these cases, treatment effectiveness is hindered, which encourages the search for means that enable the

use of isolation. OptiDam<sup>®</sup> is a new material that fulfills such expectations. It is a three-dimensional dam that best fits to patient's mouth and exerts little tension over the clamp. In this context, the present study aims at reporting two clinical cases using OptiDam<sup>®</sup>, in addition to discussing the effectiveness of using this type of rubber dam.

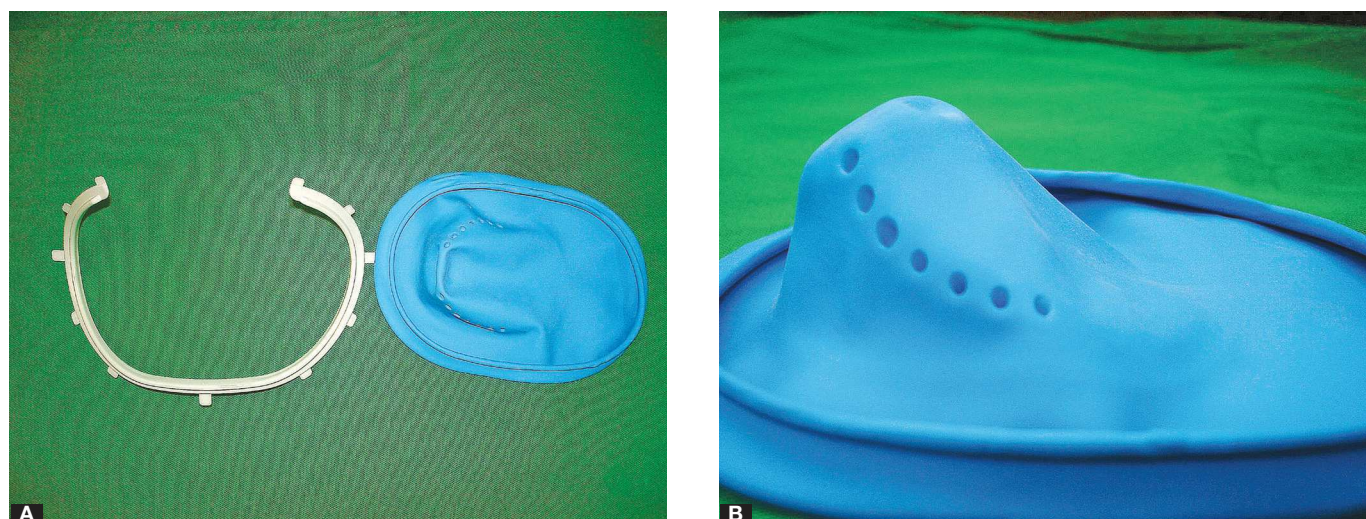
## Case report

### Case 1

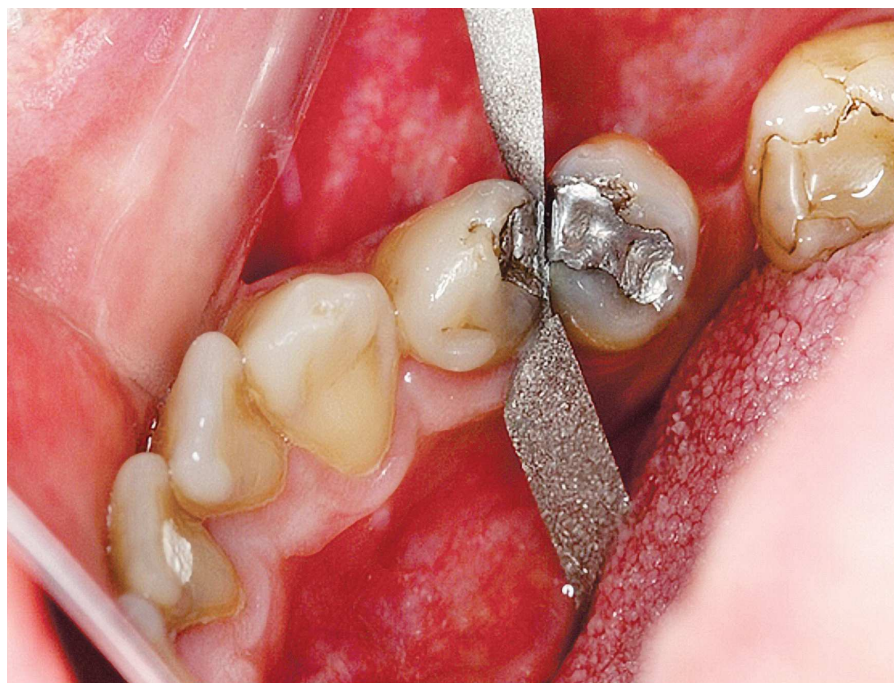A 41-year-old male patient attended the Dental Clinics at UNIPAR. He had no symptoms and was referred to the Supervised Internship in Multidisciplinary Clinics II. Treatment planning was based on data collected during the first interview as well as from clinical examination and panoramic radiograph revealing the presence of a radiolucent area with unclear contour associated with the apex of the left lower first premolar (#34) (Fig 1). Clinical examination revealed amalgam restoration on the occlusal and distal surfaces of #34 without biological width invasion. The tooth tested negative at vertical percussion and cold testing. Based on signs and symptoms, clinicians arrived at a diagnosis of pulp necrosis and, for this reason, recommended endodontic treatment. They opted to use Optidam<sup>®</sup> posterior for absolute isolation of the operating field (Fig 2).



**Figure 1.** Panoramic radiograph imaging.



**Figure 2.** A) OptiDam® absolute isolation consisting of a rubber dam and a frame. B) Tridimensional design of the rubber dam.




**Figure 3.** Steel file used through interdental spaces to favor rubber dam placement.

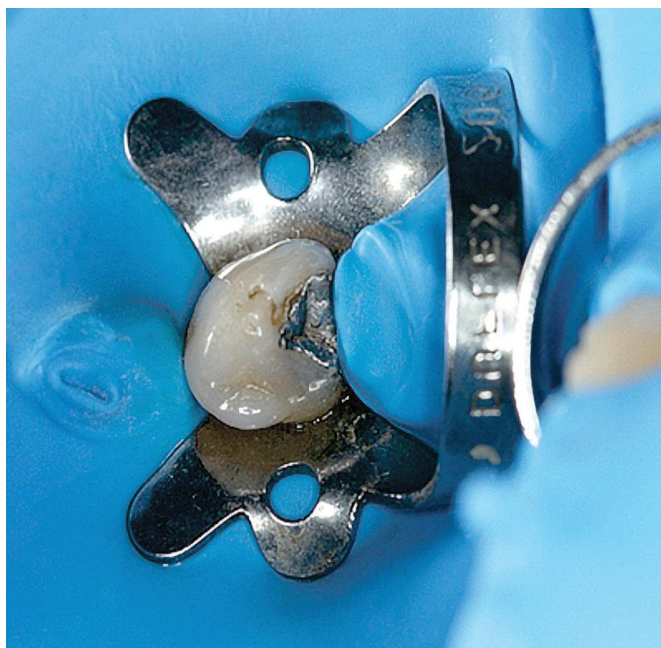
The operating field was previously prepared with a steel file used through interdental spaces to favor rubber dam placement (Fig 3).

The rubber dam was mounted on the frame and placed with the cavity turned towards the left. The rubber dam was stretched over the teeth and the nipples corresponding to

teeth to be isolated were cut off with sharp scissors near their base (Fig 4A). In order to assemble the frame/rubber dam complex, a clamp #206 was attached by its wing to the hole cut in the dam (Fig 4B), thereby allowing the entire complex to be placed over the teeth. As a result, the rubber dam was fixed without further difficulties (Fig 5).



**Figure 4.** A) Nipples are cut off over tooth #34. B) A clamp is attached to the hole cut in the rubber dam.



**Figure 5.** Absolute isolation with OptiDam®.

## Case report 2

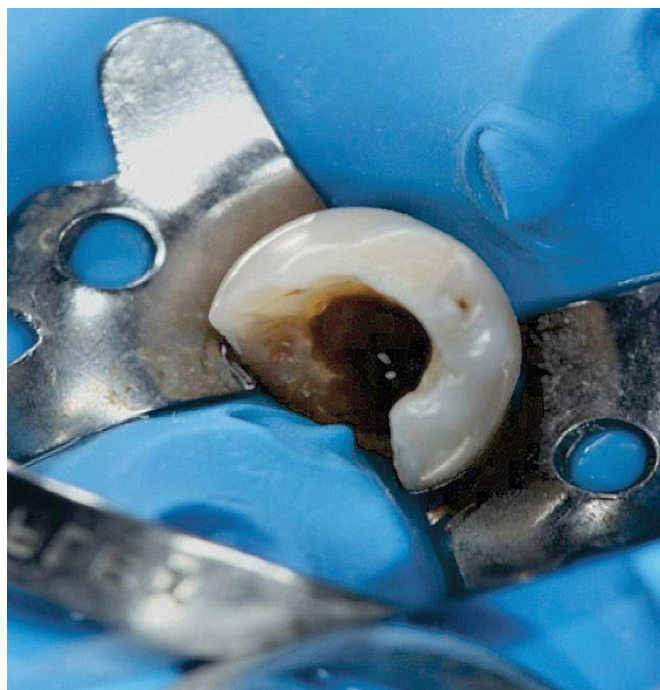
A 54-year-old male patient attended the Dental Clinics at UNIPAR seeking for treatment of tooth #44. He reported discomfort as a result of loss of temporary restoration prepared one year before

during previous therapy which the patient gave up for unknown reasons. Clinical examination revealed absence of fistula, but severe coronal destruction involving buccal, lingual, occlusal and distal surfaces. The latter was the most affected, as the end of the cavity was at gingival margin level, but without compromising the biological space. Tooth #44 tested negative for cold testing, percussion and palpation. Radiographic examination yielded normal results.

Treatment planning included the use of Optidam® posterior for absolute isolation of the operating field and to further assess the technique in the event of significant loss of structure. The sequence of steps used to mount the rubber dam was identical to the sequence described for case report 1. Importantly, the dam was highly adapted to the cervical portion of the crown and pushed through the gingival sulcus without the need of dental floss (Fig 6).

## Discussion

Even though the concept of absolute isolation was developed more than 140 years ago and despite its widely acknowledged benefits (systematically proved in the literature<sup>4</sup>), a number of clinicians refuse to use absolute isolation in routine endodontic practice.



**Figure 6.** Absolute isolation with OptiDam® pushed through the gingival sulcus.

Slaus and Bottenberg<sup>5</sup> report that 77.3% of a sample comprising Belgium dentists never use rubber dam, whereas 59% of American practitioners use it. As for dentists in the United Kingdom, 60 to 70% of them report never using any kind of isolation procedure. This fact might be explained by several reasons, namely: potential waste of time, patient's pain, extra costs, frustration, anger, lack of experience, habit and lack of confidence.<sup>4</sup>

With a view to improving clinicians' and patients' conditions, the absolute isolation technique has been modified over time. OptiDam® stands out among several isolation techniques. It consists of a three-dimensional dam of which structure adapts to patient's oral contour. It is designed as OptiDam® anterior and posterior. Additionally, it has a nipple design. Nipples on the dam indicate the tooth positions.

OptiDam® is used in endodontic treatment, restorations, cementation of indirect restoration, bleaching, fissure sealing, among others.

The cases reported herein allowed us to reach a practical opinion about how productive OptiDam® posterior is. The following is highlighted: Both cases evinced OptiDam® easy application after the clinician was familiarized with the technique.

The rubber dam can be easily applied by one clinician alone, as the rubber is consistent and can be stretched out without tearing apart. The tridimensional design of the rubber dam allows reduced tension over the clamp, and due to being mounted near the mucosa, it widens the accessible oral area in a satisfactory way.

Importantly, patients' subjected to endodontic treatment with OptiDam® report greater comfort and convenience in comparison to conventional absolute isolation techniques. Nevertheless, two major disadvantages are highlighted: The first is the cost of the material which cannot be purchased in Brazil. The second accounts for the difficulty of both cases in taking radiographic examinations due to stiffness of the rubber dam frame.

## Conclusion

In accordance with the cases reported herein, it is reasonable to conclude that absolute isolation by means of OptiDam® proved clinically feasible, of easy application and resistant to breakage; thereby providing patients with greater comfort. Nevertheless, it OptiDam® has two major disadvantages in terms of cost and radiographic examination taking.

## References

1. Baratieri LN. *Odontologia Restauradora: fundamentos e técnicas*. São Paulo: Ed. Santos; 2010. Cap. 4, p. 71-95.
2. Conceição EN, Soares CG. *Dentística saúde e estética*. Porto Alegre: Artmed; 2007. Cap. 6, p. 112-29.
3. Souza Neto MD. Isolamento absoluto do campo operatório com a ajuda de cianocrilato: casos clínicos. *Rev Bras Odontol*. 1996;53(6):36-7.
4. Saunders WP, Chestnutt IG, Saunders EM. Factors influencing the diagnosis and management of teeth with pulpal and periradicular disease by general dental practitioners. Part 2. *Br Dent J*. 1999;187(10):548-54.
5. Slaus G, Bottenberg PA. Survey of endodontic practice amongst Flemish dentists. *Int Endod J*. 2002;35(9):759-67.