

# Endodontic treatment of tooth with incomplete root formation: immediate technique

Paulo Edson Alves de **SOUZA JUNIOR**<sup>1</sup>

Joaquim Carlos Fest da **SILVEIRA**<sup>2</sup>

Luiz Felipe Gilson de Oliveira **RANGEL**<sup>3</sup>

doi: <http://dx.doi.org/10.14436/2178-3713.5.1.068-072.oar>

## ABSTRACT

**Introduction:** Dental trauma has currently increased the need for endodontic treatment in teeth with incomplete root formation and pulp necrosis. Treating these teeth is a challenge for endodontists, since the former have anatomical features and characteristics that hinder endodontic treatment.

**Objective:** This case report describes root canal treatment performed in a young patient with permanent maxillary left central incisor with incomplete root formation and dental pulp necrosis. **Methods:** At the first appointment, the following procedures were carried out: clinical examination, periapical radiograph, coronal opening, disinfectant

penetration and odontometry. After emptying the root canal, calcium hydroxide/camphorated paramonochlorophenol/glycerin (HPG) paste was used as intracanal dressing for root canal disinfection. At the second appointment, root canal filling was performed by means of immediate technique and mineral trioxide aggregate (MTA) was introduced so as to allow the formation of an apical plug and promote proper apical seal. **Conclusion:** Final radiograph revealed complete root canal filling.

**Keywords:** Apexification. Dental pulp necrosis. Root canal therapy.

**How to cite this article:** Souza Junior PEA, Silveira JCF, Rangel LFGO. Endodontic treatment of tooth with incomplete root formation: immediate technique. *Dental Press Endod.* 2015 Jan-Apr;5(1):68-72.  
DOI: <http://dx.doi.org/10.14436/2178-3713.5.1.068-072.oar>

» The authors report no commercial, proprietary or financial interest in the products or companies described in this article.

» Patients displayed in this article previously approved the use of their facial and intraoral photographs.

<sup>1</sup>Undergraduate in Dentistry, Universidade Severino Sombra (USS), Vassouras, Rio de Janeiro, Brazil.

<sup>2</sup>Assistant professor, Universidade Severino Sombra (USS), Vassouras, Rio de Janeiro, Brazil.

<sup>3</sup>Professor, Universidade Severino Sombra (USS), Vassouras, Rio de Janeiro, Brazil.

Submitted: November 14, 2014. Revised and accepted: January 30, 2015.

Contact address: Paulo Edson Alves de Souza Júnior  
E-mail: [pauloedsonj@yahoo.com.br](mailto:pauloedsonj@yahoo.com.br)

## Introduction

The increase in cases of dental trauma has currently boosted the need for root canal treatment in teeth with incomplete root formation and dental pulp necrosis. The difficulties encountered by the endodontist include wide root canal and foramen which, despite not being completely formed, also presents with an exaggerated diameter.

Whenever incomplete root formation is associated with dental pulp necrosis, it becomes even more complicated, as the process of root formation by deposition of dentin ceases. Both dental trauma affecting the pulp and tooth decay are the main etiological factors of necrosis.<sup>1</sup>

Due to these injuries, both of which lead to incomplete root formation, and lack of proper treatment, pulp necrosis is established, which constitutes a major challenge, since the anatomical features and characteristics of the case hinder endodontic treatment.<sup>2</sup>

The treatment of choice has been apexification which aims at creating an artificial barrier which, in turn, includes removing the necrotic pulp, followed by root canal debridement and introduction of antimicrobial medication.<sup>3</sup>

Calcium hydroxide, pure or combined with other substances, is the material presenting the greatest scientific support for endodontic treatment, particularly for root apex closure in teeth with full or partial pulp vitality, in which case treatment occurs by means of stimulating apical closure. Other material successfully used for endodontic treatment of teeth with incomplete root formation is MTA (mineral trioxide aggregate). It has antimicrobial activity, promotes proper sealing, is biocompatible, has no carcinogenic potential and stimulates dentin neoformation. In addition, it allows an apical mineralized barrier to be formed in order to restore the health of the tooth and prevent premature loss.<sup>1</sup>

MTA was developed by Torabinejad and his team, in 1990. It has been used in Endodontics with great success. The material has physical and chemical characteristics with a high degree of biocompatibility; however, it was only in 1999 that the sealer was patented and commercialized.<sup>4,5,6</sup>

In order to fill teeth with pulp necrosis and incomplete root formation, we used an apical plug associated with the immediate technique. The apical plug

consists in introducing a filling material, compatible with periapical tissues, into the apical segment of the root canal. The rest of the filling material is used in a conventional way (endodontic sealer and gutta-percha cone). Thus, the apical plug is used for mechanical as well as biological purposes. The former because it acts as a mechanical barrier that prevents gutta-percha and sealer overflow; and the latter because it favors biological repair of mineralized tissue adjacent to the apex.<sup>1</sup>

MTA is a type of biocompatible material with satisfactory antibacterial activity that promotes proper sealing, prevents microleakage, induces dentin neoformation and does not have a carcinogenic potential. It is little soluble and its pellet does not dilute in the presence of tissue fluids, which is an advantage over calcium hydroxide-based pastes and sealers.<sup>1</sup>

Ruiz et al<sup>7</sup> reported that MTA is a biocompatible material with osteoinductive properties which promotes proper marginal seal, thereby preventing leakage and antimicrobial effects. It is used in various clinical situations, such as root perforations seal, direct pulp capping, pulpotomy, apical plug in incomplete root formation, root canal filling, repair of root fracture and as temporary restorative material.

De Deus and Coutinho Filho<sup>8</sup> reported having used MTA as apical plug in a tooth with incomplete root formation and pulp necrosis. The authors performed clinical and radiographic follow-ups for one year and found the patient to be in adequate clinical function, without symptoms and signs of periapical bone rarefaction. This result led the authors to conclude that MTA is a satisfactory alternative to treat teeth with incomplete root formation and pulp necrosis.

Tonin<sup>9</sup> showed that MTA is the material of choice to treat teeth with pulp necrosis and incomplete root formation, with the advantage of allowing root canal treatment to be carried out in a single session, thereby reducing the likelihood of complications and treatment time.

A clinical study compared MTA with calcium hydroxide, both used as apical plugs in teeth with incomplete apex. Results revealed that the MTA apical plug was more effective than the calcium hydroxide plug, without overflow in either one of the cases. Nevertheless, calcium hydroxide apical plug ruptured in four cases.<sup>10</sup>

In the case reported herein, clinical apexification, which is the induction of a calcified barrier in the apical region of teeth with incomplete root formation and pulp necrosis, was carried out using MTA associated with the immediate technique. The latter consists in using a rolled cone, manufactured by attaching three major gutta-percha #80 cones, inserted into the root canal so as to form an apical artificial barrier. Root canal was filled with MTA within two sessions, only.

The objective of this study was to show the effectiveness of the immediate technique in a case of incomplete root formation and pulp necrosis, in which restorative MTA and endodontic sealer were used with a view to closing the root apex.

## Material and methods

A 16-year-old male patient attended the dental clinic of Universidade Severino Sombra (USS) (Vassouras, Rio de Janeiro, Brazil). During the first interview, the patient reported that, at the age of 8, he suffered trauma of tooth #21. Clinical and radiographic examinations revealed incomplete root formation and pulp necrosis associated with the presence of apical lesions. Diagnosis was followed by endodontic treatment onset.

At the first appointment, access surgery was carried out with the patient under rubber dam isolation. Subsequently, the procedure of emptying the root canal was carried out with a #80 K file under rotational movement so as to neutralize the septic-toxic content with 1% sodium hypochlorite solution. Odontometry was performed with #80 K file penetrating freely throughout the working length, established at 22 mm, with the distal incisal edge as reference. Shortly after this procedure, calcium hydroxide/camphorated paramonochlorophenol/glycerin (HPG) paste was used as intracanal dressing for root canal disinfection. It was applied with the aid of a #40 lentulo bur. Subsequently, coltosol was used as temporary sealer.

At the second appointment, instrumentation was carried out with #80 K file for neutralization of septic-toxic contents. Root canal filling was performed with MTA (mineral trioxide aggregate) associated with the immediate technique:<sup>1</sup> (1) First, a rolled cone is manufactured by attaching three major gutta-percha #80 cones. The cones are slightly heated and, with the aid of tweezers, inserted into the

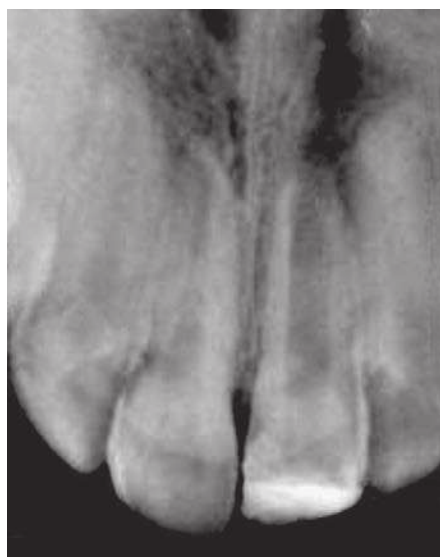root canal, shaping the root apex; (2) Subsequently, MTA is manipulated (powder and liquid) on a glass plate with a #24 spatula, inserted into the root canal with the aid of a Paiva plugger and compacted in the root apex with the aid of the main gutta-percha cone. Once MTA has settled and hardened in the root apex, radiographs are taken to assess its fitting (cone test); (3) The main gutta-percha cone is removed. A radiograph is taken to assess MTA forming a plug at the root apex while cement setting is achieved; (4) After radiograph taking, the main gutta-percha cone is re-inserted with filling cement and a spreader is used to take the accessory cones with filling cement to the MTA base in the root canal; (5) Another radiograph is taken to assess fitting of main/accessories cones (crest). Once this phase is complete, the crest is removed with a heated Paiva plugger, vertical compaction is carried out and a final radiograph is taken so as to assess final filling.

Once endodontic treatment was achieved by means of MTA associated with the immediate technique, a radiographic follow-up was performed every four months, over a year, in order to assess the action of MTA in the formation of an apical plug of mineralized tissue.

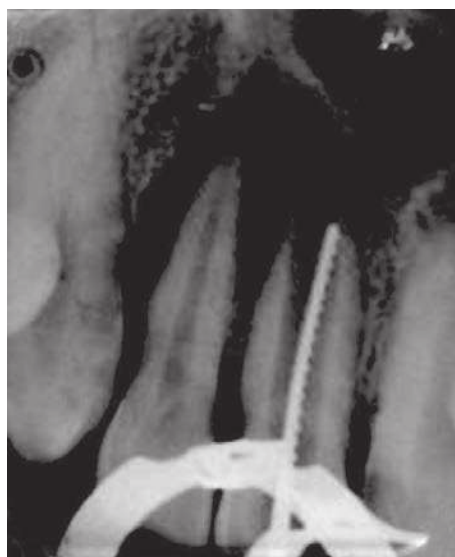
## Discussion

The endodontic literature offers several techniques and different types of filling material used to treat incomplete root formation associated with pulp necrosis; however, the authors argue that the best option is to stimulate apical closure. Thus, in the case presented herein, MTA was chosen over calcium hydroxide, since the former has been used with great success in endodontic practice due to being a biocompatible material with satisfactory antibacterial activity that promotes proper sealing, prevents microleakage, induces dentin neof ormation and does not have a carcinogenic potential. Nevertheless, not using calcium hydroxide to induce the formation of an apical barrier demonstrated that it weakens the dentin and entails a risk of overflow. Additionally, it needs to be changed periodically, thereby increasing the need for patient return. Conversely, with the use of MTA, root canal filling was achieved within two sessions only, thus reducing treatment time.<sup>1,11,12</sup>

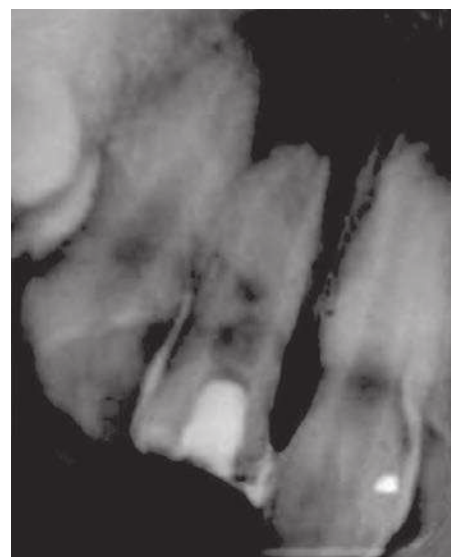
The immediate technique<sup>1</sup> was chosen because final filling was performed soon after the use of HPG as



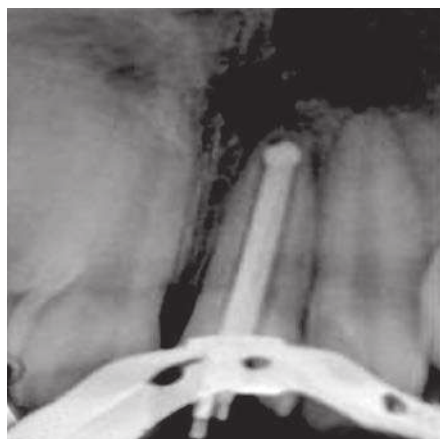
**Figure 1.** Initial radiograph.



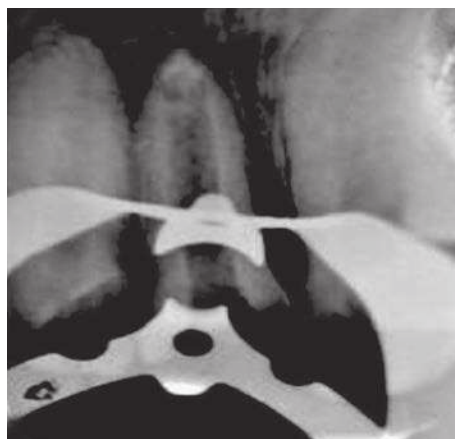
**Figure 2.** Odontometry.



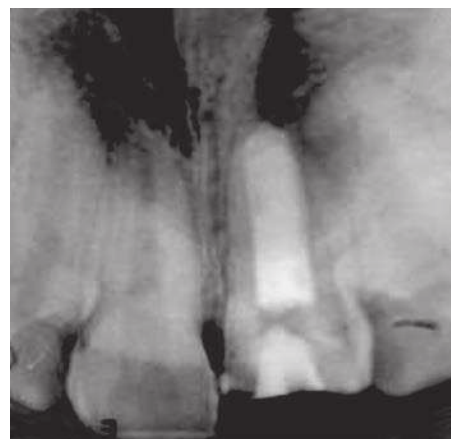
**Figure 3.** Root canal filled with HPG.



**Figure 4.** Apical plug made of MTA and fitting of the main cone.



**Figure 5.** Apical plug in place.



**Figure 6.** Final filling.

intra canal dressing, which reduced treatment time as well as the number of appointments and radiographs. In addition, the patient desperately needed urgent esthetic restoration, since the affected tooth was in the anterior region. Also, he was treated in a dental school clinic where control of patient's return is more difficult. For the aforementioned reasons, treatment was carried out within two sessions.

It is also worth noting that root canal disinfection was achieved with the use of HPG paste as intracanal medication in the treatment of teeth with incomplete root formation associated with pulp necrosis. Glycerine (a viscous water-soluble vehicle with slower dissociation when in contact with calcium hydroxide) was used because even though its initial bactericidal

effect is not as potent, it is more durable. Camphorated paramonochlorophenol has bactericidal activity and inactivation of enzyme. Calcium hydroxide has anti-inflammatory and antimicrobial activity, in addition to neutralization of endotoxin and induction of repair by means of mineralized tissue.<sup>13</sup>

Importantly, the conditions necessary to form a calcified apical barrier in teeth with incomplete root formation and pulp necrosis include procedures of emptying and instrumenting root canals aimed at removing debris and bacteria.<sup>3</sup> Instrumentation should be performed with caution because the root canal has a large volume of thin and brittle walls, which can result in root fracture during potential material changes.

The use of an irrigating solution is also important for root canal disinfection, which occurs as a result of its physicochemical properties.<sup>14</sup>

Although pulp necrosis hinders apical root development, it is important to emphasize that the apex should be understood as a dynamic tissue with its own ability to grow, develop and repair.<sup>15</sup> Studies on incomplete root formation disclose that apical foramen closure is related to four factors: stage of tooth root development, dental pulp and periapical tissues conditions at the time of intervention and the substance of choice.<sup>16</sup>

In the case reported herein, apexification was chosen due to incomplete root formation of the traumatized tooth and pulp necrosis. Importantly, dental pulp conditions was an important factor for the proper choice of endodontic treatment. When the pulp becomes necrotic before root growth is complete, dentin formation and root development cease.<sup>11</sup> MTA was used as an apical plug in order to form an artificial barrier. Final radiograph revealed an MTA apical plug compressed in the root apex. In addition,

it revealed that proper seal was achieved, thereby proving the immediate technique effective. Subsequently, root canal filling was also carried out with MTA-based sealer.<sup>1</sup>

After root canal instrumentation and the use of an MTA sealer, radiographic and clinical follow-ups were performed every four months, over a year, at Universidade Severino Sombra, in order to assess the action of MTA in the formation of an apical plug of mineralized tissue at the apex of the tooth with incomplete root formation. After endodontic procedures were carried out, the tooth was restored with a view to obtaining a biological seal and prevent contamination of the canal.

## Conclusion

Final radiograph revealed that treatment of young teeth with incomplete root formation and pulp necrosis, carried out by means of using MTA as filling material associated with immediate technique, proved effective.

## References

- Lopes HP, Siqueira Jr JF, Estrela C, Neves MAS. Tratamento Endodôntico em dentes com rizogênese incompleta. In: Lopes HP, Siqueira Jr JF. Endodontia: biologia e técnica. 3ª ed. Rio de Janeiro: Guanabara Koogan; 2010. p. 877-90.
- Seibel VM, Soares RG, Limongi O. Histomorfologia do reparo após tratamento endodôntico em dentes com rizogênese incompleta: revisão de literatura. RSBO. 2006;3(2):37-43.
- Holland GR, Trowbridge HO, Rafter M. Proteção pulpar, preservação do ápice. In: Torabinejad M, Walton RE. Endodontia: princípios e práticas. 4ª ed. Rio de Janeiro: Elsevier; 2010. p. 32.
- Gomes-Filho JE, Costa MMM, Cintra LT, Duarte PC, Takamiya AS, Lodi CS, et al. Evaluation of rat alveolar bone response to Angelus MTA or experimental light-cured mineral trioxide aggregate using fluorochromes. J Endod. 2011;37(2):250-4.
- Gonçalves JL, Viapiana R, Miranda CE, Borges AH, Cruz Filho AM. Evaluation of psycho-chemical properties of Portland cements and MTA. Braz Oral Res. 2010;24(3):277-83.
- Reis-Araújo C. Estudo etiológico comparativo entre MTA e o cimento de Portland. Rev Odontol Univ São Paulo. 2007;19(2):137-46.
- Ruiz PA, Souza AHF, Amorin FRB, Carvololalho A. Agregado de trióxido mineral (MTA): uma nova perspectiva em Endodontia. RBO. 2003;60(1):33-5.
- De Deus G, Coutinho-Filho T. The use White Portland cement as an apical plug in a tooth with a necrotic pulp and wide-open apex: a case report. Int Endod J. 2007;40(8):653-60.
- Tonin L. Apicificação [monografia]. Passo Fundo (RS): Uningá; 2008.
- Batista A, Sydney GB, Deonizio MD. A Análise "in vitro" da viabilidade do uso do MTA e do hidróxido de cálcio com plug apical em dentes com rizogênese incompleta. ROBRAC. 2007 [Acesso em: 2014 jul. 10];16(42). Disponível em: <http://www.robrac.org.br/seer/index.php/ROBRAC/article/viewFile/68/61>.
- Torabinejad M, McDonald NJ. Cirurgia perirradicular. In: Torabinejad M, Walton RE. Endodontia: princípios e práticas. 4ª ed. Rio de Janeiro: Elsevier; 2010. p. 357-75.
- Shabahang S, Torabinejad M. Treatment of teeth with open apices using mineral trioxide aggregate. Pract Periodontics Aesthet Dent. 2000;12(3):315-20; quiz 322.
- Siqueira Jr JF, Rôças IN, Lopes HP. Medicação Intracanal. In: Lopes HP, Siqueira Jr JF. Endodontia: biologia e técnica. 3ª ed. Rio de Janeiro: Guanabara Koogan; 2010. p. 573-611.
- Marchesan MA, Alfredo E, Sufredini AR, Matoso FB, Vansan LP, Souza Neto MD. Tratamento de dentes traumatizados com rizogênese incompleta: apicificação. RBSO. 2008;5(1):58-62.
- Moodnick RM. Clinical correlation of the development of the root apex and surrounding structures. Oral Surg. 1963;16(5):600-7.
- Holland R, Souza V, Mello W, Nery MJ, Bernabé PFE, Otoboni Filho JA. Manual de Endodontia. Faculdade de Odontologia de Araçatuba, UNESP. Araçatuba: Unesp; 1978-1979.