

# Evaluation of rat tissue response to Guedes-Pinto and calcium hydroxide pastes by morphological analysis of repair in rat's tooth socket

Karine **TAKAHASHI**<sup>1</sup>

Paulo **MALTEMPI FILHO**<sup>2</sup>

Robson Frederico **CUNHA**<sup>3</sup>

Eloi **DEZAN JUNIOR**<sup>4</sup>

DOI: <http://dx.doi.org/10.14436/2358-2545.5.2.026-032.oar>

## ABSTRACT

In order to evaluate late biological response of two types of filling material of deciduous teeth, calcium hydroxide and Guedes-Pinto pastes, the implantation technique in rat sockets was employed. For morphological analysis, carried out after 7 and 28 days, 48 rats had their maxillary right central incisor removed, and a polyethylene tube implant containing one of the pastes was placed into the socket. On the 7<sup>th</sup> day, calcium hydroxide paste caused greater edema than Guedes-Pinto paste, and both types of material showed connective tissue with fibroblasts and blood vessels, with macrophages and

lymphocytes. On the 28<sup>th</sup> day, calcium hydroxide paste had connective tissue with a large amount of macrophages and lymphocytes near the material, whereas in further areas, it had neofomed trabeculae. For the Guedes-Pinto paste, there were neoformed bone trabeculae nearby. The latter were found in larger amounts in areas further from the material surface. Guedes-Pinto paste caused less edema and provided less interference in the repair process.

**Keywords:** Deciduous tooth. Calcium hydroxide. Root canal therapy. Root canal filling material.

» The authors report no commercial, proprietary or financial interest in the products or companies described in this article.

<sup>1</sup>PhD professor of Pediatric Dentistry, Universidade do Oeste Paulista (UNOESTE), School of Dentistry, Presidente Prudente, São Paulo, Brazil.

<sup>2</sup>MSc in Animal Sciences, Universidade Estadual do Mato Grosso do Sul (UFMS), Aquidauana, Mato Grosso do Sul, Brazil.

<sup>3</sup>Professor of Pediatric Dentistry, Universidade do Oeste Paulista (UNOESTE), School of Dentistry, Araçatuba, São Paulo, Brazil.

<sup>4</sup>PhD professor of Endodontics, Universidade Estadual Paulista Júlio de Mesquita Filho (UNESP), School of Dentistry, Araçatuba, São Paulo, Brazil.

**How to cite this article:** Takahashi K, Maltempi Filho P, Cunha RF, Dezan Junior E. Evaluation of rat tissue response to Guedes-Pinto and calcium hydroxide pastes by morphological analysis of repair in rat's tooth socket. *Dental Press Endod.* 2015 May-Aug;5(2):26-32.

DOI: <http://dx.doi.org/10.14436/2358-2545.5.2.026-032.oar>

Submitted: July 25, 2015. Revised and accepted: August 05, 2015.

Contact address: Karine Takahashi  
Rua Francisco Scardazzi, 350, São Judas – CEP: 19.023-190  
Presidente Prudente/SP, Brazil – E-mail: [karine@unoeste.br](mailto:karine@unoeste.br)

## Introduction

Deciduous teeth are essential for the physical and functional development of a child, as they are involved in mastication, esthetics and function. For this reason, their maintenance in proper conditions until the moment of eruption of permanent teeth is the major objective of Pediatric Dentistry. Even with preventive measures in oral health being adopted, we still find nowadays decay affecting deciduous teeth, which most of the cases is irreversible.

A conservative therapy of which purpose is the maintenance of deciduous teeth with extensive carious lesions would be endodontic treatment. Although the indications and criteria for endodontic treatment success are the same for deciduous and permanent teeth, there are some differences in relation to endodontic treatment, such as: physiological resorption, nearness with the permanent germ, and morphology of the deciduous tooth.

The use of calcium hydroxide in obturation of root canals has yielded good results when applied in deciduous or permanent teeth. A large number of experimental articles available in the literature prove that calcium hydroxide is the material that leads to the highest percentage of biological sealing after obturation.<sup>16,24,26,27</sup> Its major biological properties result from its dissociation into  $\text{Ca}^{+2}$  and  $\text{OH}^-$  ions and its high pH, both of which produce antibacterial action, inductive of mineralization, as well as anti-inflammatory and hemostatic actions.<sup>15</sup> This material also fulfill the requirements of biocompatibility, since it does not harm periapical tissues, preserves the integrity of pulp stump and speeds hard tissue deposition up.<sup>11</sup> It is also resorbable and remains chemically active, until complete resorption at the periapical region.<sup>38</sup>

In the '80s, Guedes-Pinto et al<sup>15</sup> disclosed a new endodontic technique for treatment of deciduous teeth, with final irrigation with Tergentol-Furacin and filling with a paste composed of Rifocort, iodoform and camphorated paramonochlorophenol.

Kramer et al<sup>19</sup> and Brusco et al<sup>6</sup> stated that Guedes-Pinto paste is the material most widely used for deciduous teeth filling in Brazilian Dentistry Schools. As for indirect pulp capping of deciduous teeth, calcium hydroxide is the most widely used material.<sup>30</sup>

Magalhães et al<sup>20</sup> assessed the influence of this paste in rat socket repair. The group in which the paste was placed inside socket, after 30 days, results showed sped up socket repair in comparison to the control group. Faraco Junior<sup>10</sup> comparatively analyzed deciduous teeth filled with calcium hydroxide and Guedes-Pinto pastes by means of histological exams. It was verified that both techniques had great chances of success in the periapical region, but the first one had better results when the inflammation process was considered.

Thus, the objective of this paper was to analyze the late biological response of two root filling materials of deciduous teeth, Guedes-Pinto and calcium hydroxide pastes, by means of morphological analysis after implantation technique in rat sockets.

## MATERIAL AND METHODS

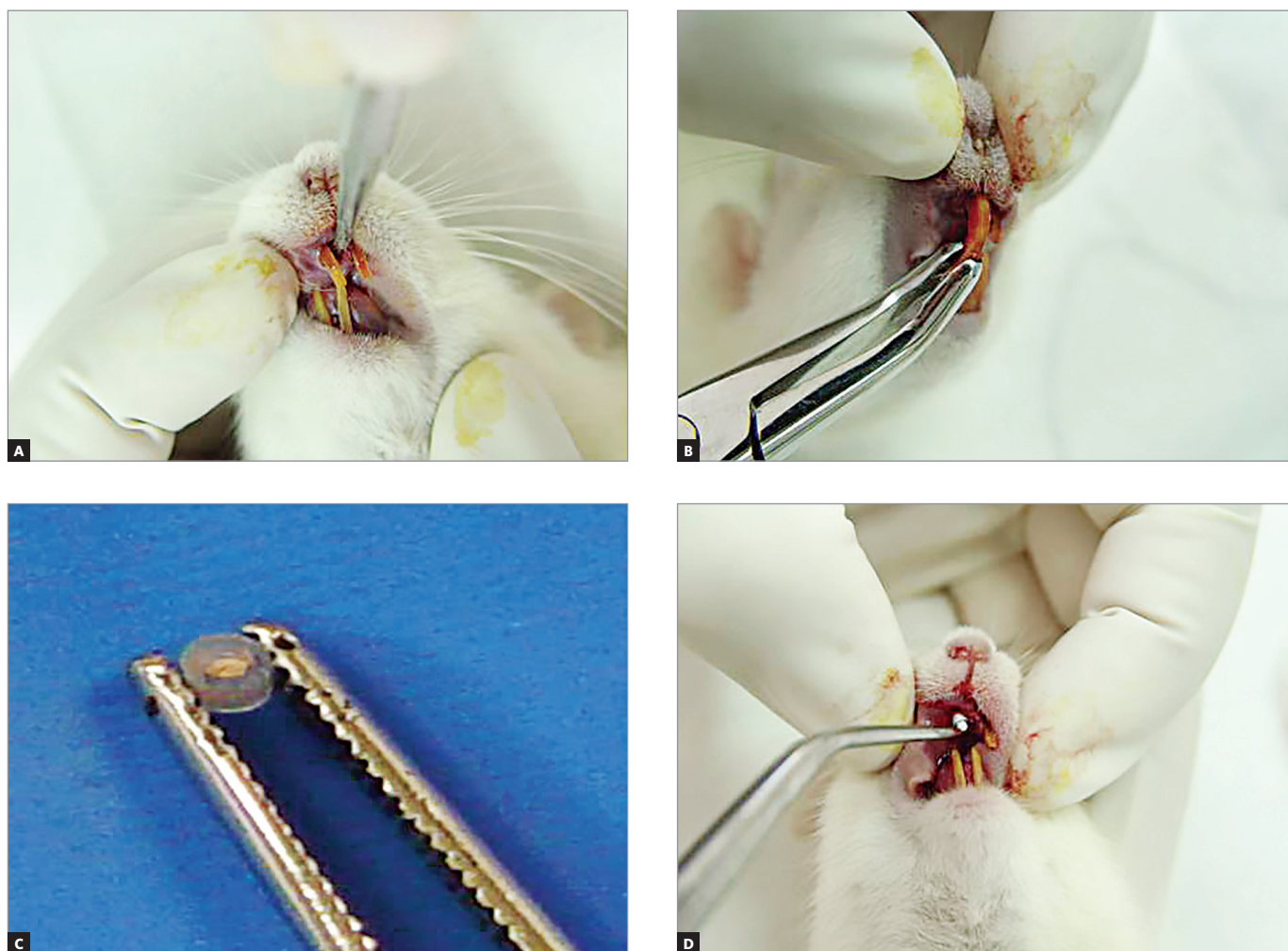
All procedures were guided by the Ethical Principles for Experiments on Animals and approved by the Ethics Committee on Animal Research (CEEAF-FOA) with protocol #48/03.

For this study, 48 male rats (*Rattus albinus*, Wistar), 250 g in weight, were retrieved from UNESP School of Dentistry laboratory. The animals were kept in collective cages and fed throughout the entire pre-experimental period with a solid diet and water *ad libitum*, except for the first 24 hours after intervention, during which feeding was suspended, and the following periods until the animals were killed.

The rats were divided into six groups, with eight animals each: control groups 7 and 28 days, in which empty tubes were implanted; Guedes-Pinto paste groups 7 and 28 days; and calcium hydroxide groups 7 and 28 days.

The animals were divided in groups comprising five animals each for the surgical intervals of 3 and 6 hours, and according to the material to be tested. Firstly, pre-anesthetic medication with xylazine was used in the ratio of 25mg/kg via intramuscular application. Subsequently, general anesthesia was applied with ketamine, in the ratio of 50mg/kg.

Extraction of maxillary right incisor was then carried out with the aid of utensils adapted from Okamoto and Russo.<sup>28</sup> After extraction and hemostasis, adapted polyethylene tubes were placed inside the socket, the containing materials to be tested (Fig 1).



**Figure 1.** Maxillary incisor extraction and implantation of polyethylene tubes with materials to be tested inside the tooth socket.

Tubes were cut with 1 mm of inner diameter and 1.8 mm of outer diameter, 3-mm in length. A total of 1 mm of the tube end was sealed with gutta-percha, and filled materials were placed into them.

The tubes were placed inside the socket immediately after extraction. The tube end containing the paste remained in contact with the apical portion of the socket, whereas the end sealed with gutta-percha faced the crown. A single implant was used for each animal. The tubes were taken to the apical portion of the sockets and the gingival mucosa was sutured.

Animals were sacrificed on the 7<sup>th</sup> and 28<sup>th</sup> day by inhalation of sulfuric ether inside a closed chamber. After the animals were sacrificed, right and left hemimaxilla were split out, and a cut was made tangentially on the distal surface of molars. After being removed, tissues were stored in a 10% formaldehyde solution for 48 hours and then washed under running water for 12 hours. Specimens were decalcified in 17% EDTA solution, dehydrated, diaphanized and immersed in paraffin, so as to allow histological sections of the sockets to be performed longitudinally. The sections were 6- $\mu$ m thick and were hematoxylin-and-eosin stained for histological analysis.

Results were obtained by description analysis of specimens under optical microscopy, by means of histopathological description of events relative to repair. They were described based on post-operative periods assessment of findings in the apical third of both experimental groups.

## Results

### Control 7 days (Fig 2)

Near the tube opening, an area occupied by neoformed connective tissue with a significant number of fibroblasts, macrophages and lymphocytes was found. In the apical area, neoformed connective tissue had a lower number of cells. Remaining clot with some macrophages was found at a few sites.

### Control 28 days (Fig 3)

Near the material surface, it was possible to see neoformed bone trabeculae occupying a few areas. Connective tissue nearby had a lower number of vessels and some fibroblasts among rare lymphocytes and macrophages. Going deeper into the socket, there was connective tissue with a larger number of

fibroblasts and neoformed bone trabeculae. Near the material surface, in other specimens, inflammatory infiltrate was found. Below it, connective tissue had a few vessels and some fibroblasts, macrophages and lymphocytes. A significant extension was found to be filled with thinner neoformed bone trabeculae.

### Calcium hydroxide - 7 days (Fig 4)

Near the tube opening, in some cases, extensive areas were occupied by neoformed connective tissue with some fibroblasts and vessels. Also there was a large number of macrophages and lymphocytes. In other specimens, in the same region, there was a high number of macrophages and lymphocytes among some fibroblasts and vessels. Areas distant from the surface, in most of the cases, showed the same characteristics of superficial areas, evincing macrophages and lymphocytes among some fibroblasts. In one animal, the areas near and distant from the material were occupied by a high number of polymorphonuclear neutrophils, most of which were degenerating.

### Guedes-Pinto paste - 7 days (Fig 5)

Near the tube opening, in all specimens, there were extensive areas occupied by connective tissue with a discrete number of fibroblasts and some vessels. Some macrophages and lymphocytes could be seen in the area. Deepest areas, in some cases, had the same characteristics found on the surface. In other cases, little neoformed bone trabeculae were found with osteoblasts on the edges.

### Calcium hydroxide - 28 days (Fig 6)

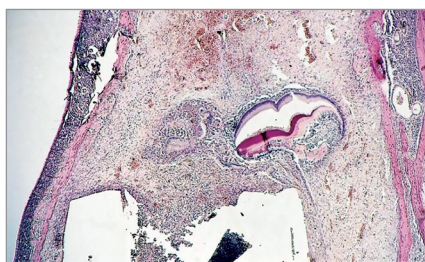
Near the tube opening, in some cases, there was connective tissue with a high number of macrophages and lymphocytes among rare fibroblasts. Some blood vessels were seen in the same region.

In other specimens, there was intense inflammatory infiltrate in restrict regions near the material surface, followed by connective tissue with a few fibroblasts and vessels. Far from the surface, there were thin neoformed bone trabeculae among differentiated connective tissue.

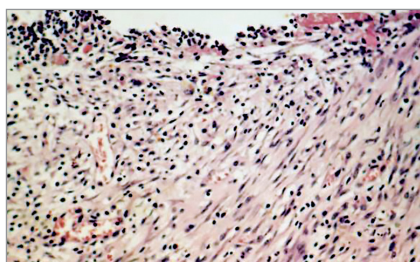
### Guedes-Pinto paste - 28 days (Fig 7)

In all specimens, we could see that near the material surface, there were little neoformed bone

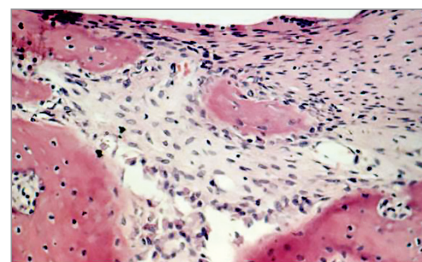




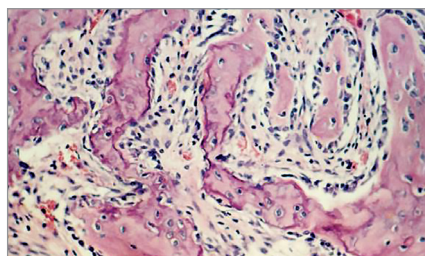
**Figure 2.** Control group after 7 days: empty tube.



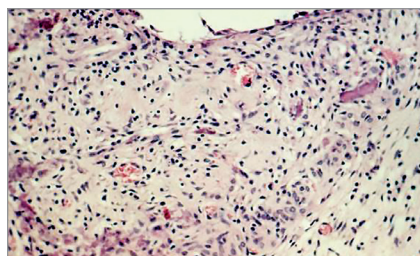
**Figure 4.** Calcium hydroxide group after 7 days: chronic inflammatory infiltrate.



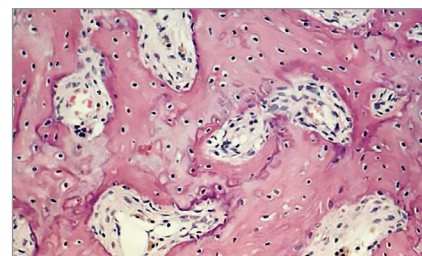
**Figure 6.** Calcium hydroxide group after 28 days: infiltrate and neoformed trabeculae.



**Figure 3.** Control group after 28 days: neoformed bone trabeculae.



**Figure 5.** Guedes-Pinto paste after 7 days: less intense infiltrate and some bone areas.



**Figure 7.** Guedes-Pinto paste after 28 days: neoformed bone trabeculae.

trabeculae besides differentiated connective tissue. In areas far from material surface, bone trabeculae were more developed. Connective tissue without differentiated bone was well developed, showing little vessels and a few fibroblasts.

## Discussion

Calcium hydroxide paste presents with clinical<sup>1,25</sup> as well as histological results well proved in the literature, by evaluating reactions in subcutaneous rat tissues,<sup>8,9,18,22,23,39</sup> or in dog's teeth, with formation of hard tissue barrier in cases of pulpotomy and deposition of hard tissue in the apical region.<sup>15,16,35</sup>

Guedes-Pinto<sup>14</sup> paste was introduced by Guedes-Pinto et al<sup>14</sup> to treat deciduous teeth sickened pulp. At present, it yields favorable clinical results.<sup>4,5</sup> According to Michel,<sup>21</sup> it is well tolerated by tissues and when implanted in rat subcutaneous tissues, shows total resorption within 90 days.

In this study, we found that Guedes-Pinto paste was more favorable to bone repair when compared to calcium hydroxide. Near the tube opening, after 28 days, there was neoformed bone trabeculae among well differentiated connective tissue. On the other

hand, with calcium hydroxide, chronic inflammatory infiltrate was found on the 28<sup>th</sup> day.

These results agreed with the ones found by Gallottini,<sup>12</sup> who used Guedes-Pinto paste as intra-alveolar medication and had the repair process enhanced. The author also suggests that this medication be used in immunosuppressed patients after extractions. Chedid<sup>7</sup> found, after pulpotomies in rats, that Guedes-Pinto paste caused an initial inflammatory reaction that decreased after 14 days. Total remission of inflammation and formation of hard tissue bridge were found on the 28<sup>th</sup> day.

Rifocort medication is composed of corticosteroid (prednisolone), antibiotics (rifamycin) and propilenglycol.<sup>13</sup> The use of corticosteroid reduces inflammatory response, which explains the best results yielded with Guedes-Pinto paste in edemogenic testing. Rifamycin has bacteriostatic action by inhibiting protein synthesis, and affects mainly gram-positive bacteria. Adding the aforementioned drugs decreases inflammatory response, avoiding exposing the socket to infectious agents when using intracanal medication, thus causing Guedes-Pinto paste to speed up the process of repair.

Iodoform and camphorated paramonochlorophenol have antiseptic action. The first one acts by releasing iodine slowly, and its antiseptic action is discrete but persistent, decreasing the probability of late socket contamination. The second, when associated with camphora, has its toxicity decreased and bacteriostatic action increased.

Tagger and Sarnat<sup>36</sup> assert that iodoform releases iodine in latent state, thus increasing bone repair in the region where it is applied, and preventing reinfection.

In this study, the calcium hydroxide group led to a delay in rat sockets repair, when compared to Guedes-Pinto paste group. These results are similar to the ones obtained by Gallottini,<sup>12</sup> Ranly and Garcia-Godoy.<sup>31</sup>

Biocompatibility tests of Guedes-Pinto paste show that it leads to intense migration of inflammatory cells, specially macrophages,<sup>7,21</sup> due to the presence of iodoform, which is easily resorbed, and the consistency of the paste, which does not hinder phagocytosis. It is known that this cells contribute to repair process, particularly as a result of phagocytosis and their ability to remove toxic products from an a damaged area. The use of corticosteroid combined with antibiotics decreases inflammatory response.<sup>21</sup>

Praetzel<sup>29</sup> found that Guedes-Pinto paste has bacteriostatic effect over some microorganisms: *Streptococcus mutans*, *Staphylococcus aureus* and *epidermidis*, *Escherichia coli* e *Enterococcus faecalis*.

Faraco Junior<sup>10</sup> found that there was no statistically

significant difference between Guedes-Pinto and calcium hydroxide pastes, in relation to acute inflammatory reaction. Guedes-Pinto paste showed more intensively chronic inflammation.

Barroso<sup>2</sup> compared results obtained with Guedes-Pinto paste and Calen paste, and found that Calen paste showed better histopathological results in all inflammatory response events. In some specimens treated with Guedes-Pinto paste, there was bone resorption, which the author affirms being due to camphorated paramonochlorophenol action.

Although both materials caused some inflammatory response until the period of 28 days (evaluated in this experiment), we believe that both are well indicated as filling materials of deciduous root canals, mainly because they are well tolerated, allow bone repair and do not interfere in resorption of deciduous roots.

## Conclusion

» On the 7<sup>th</sup> day, both materials had similar characteristics.

» On the 28<sup>th</sup> day, Guedes-Pinto groups had neoformed bone trabeculae along the material surface, and in greater number in areas far from the material surface.

» On the 28<sup>th</sup> day, calcium hydroxide paste groups had connective tissue rich in fibroblasts, vessels, macrophages and lymphocytes near the tibe opening, and neoformed bone trabeculae in distant areas.

» Guedes-Pinto paste had less interference in the repair process than calcium hydroxide paste.

## References

- Alves DF, Caldas Junior AF, Feitosa DA, Fontes GB, Sant'anna AO, Rodrigues VMS. Tratamento endodôntico utilizando hidróxido de cálcio em dentes decíduos com polpa necrosada e reação periapical. Rev Fac Odontol Pernambuco. 1994 Jan-Dez;13(1):45-7.
- Barroso DS. Avaliação histopatológica dos tecidos apicais e periapicais de dentes de cães, após biopulpectomia e obturação dos canais radiculares com diferentes materiais utilizados em Odontopediatria [dissertação]. Ribeirão Preto (SP): Universidade de São Paulo; 2003.
- Bazerque P. Farmacologia odontológica. Buenos Aires: Mundi; 1976.
- Bengtson AL, Bengtson NG. Nova conduta nas pulpotomias de dentes decíduos: avaliação clínica-radiográfica da pasta Guedes-Pinto. RGO. 1994 Jan-Fev;42(1):7-11.
- Bengtson AL, Bengtson NG, Guedes-Pinto AC. Pulpotomia em dentes decíduos com o emprego da pasta Guedes-Pinto: Observação clínica e radiográfica. Rev Odontopediatr. 1992 Jan-Mar;1(1):5-13.
- Brusco EH. C. Procedimentos e substâncias empregadas por faculdades de Odontologia brasileiras na terapia endodôntica de dentes decíduos pulpectomizados. J Bras Odontopediatr Odontol Bebê. 2002 Jan-Fev;5(23):35-46.
- Chedid RR. Estudo histopatológico da reação da polpa de ratos à ação de pastas e medicamentos utilizados na terapia pulpar de dentes decíduos [dissertação]. São Paulo (SP): Universidade de São Paulo; 1988.
- Colabone DA, Toledo OA. Reação do tecido subcutâneo do rato ao implante de materiais à base de hidróxido de cálcio (life e tubulidrox). Estudo histológico. ARS Cvrandi Odontol. 1993 Abr-Jun;9(2):5-16.
- Economides N, Kotsaki-Kovatsi VP, Pouloupoulos A, Kolokuris I, Rozos G, Shore R. Experimental study of the biocompatibility of four root canal sealers and their influence on the zinc and calcium content of several tissues. J Endod. 1995 Mar;21(3):122-7.

10. Faraco Junior IM. Estudo histopatológico da reação dos tecidos periapicais de cães submetidos à ação de duas técnicas utilizadas na terapia endodôntica de dentes decíduos com polpa necrosada [dissertação]. Araçatuba (SP): Universidade Estadual Paulista "Júlio de Mesquita Filho"; 1996.
11. Fava LR, Saunders WP. Calcium hydroxide pastes: classification and clinical indications. *Int Endod J*. 1999 Aug;32(4):257-82.
12. Gallotini MHC. Influência da pasta composta por Rifocort, iodoformio e paramonoclorofenol canforado na reparação alveolar: estudo morfológico em ratos [dissertação]. São Paulo (SP): Universidade de São Paulo; 1989.
13. Gould JM. Root canal therapy for infected primary molar teeth: preliminary report. *ASDC J Dent Child*. 1972 Jul-Aug;39(4):269-73.
14. Guedes-Pinto AC, Paiva JG, Bozzola JR. Tratamento endodôntico de dentes decíduos com polpa mortificada. *Rev Assoc Paul Cir Dent*. 1981;35(3):240-5.
15. Hendry JA, Jeanson BG, Dummett CO Jr, Burrell W. Comparison of calcium hydroxide and zinc oxide and eugenol pulpectomies in primary teeth of dogs. *Oral Surg Oral Med Oral Pathol*. 1982 Oct;54(4):445-51.
16. Holland R. Processo de reparo do coto pulpar e dos tecidos periapicais após biopulpectomia e obturação de canal com hidróxido de cálcio ou óxido de zinco e eugenol: estudo histológico em dentes de cães [tese]. Araçatuba (SP): Universidade Estadual Paulista; 1975.
17. Holland R, de Mello W, Nery MJ, Bernabe PF, de Souza V. Reaction of human periapical tissue to pulp extirpation and immediate root canal filling with calcium hydroxide. *J Endod*. 1977 Feb;3(2):63-7.
18. Kawakami T, Nakamura C, Hasegawa H, Akahane S, ES. Ultrastructural study of initial calcification in the rat subcutaneous tissues elicited by a root canal filling material. *Oral Surg Oral Med Oral Pathol*. 1987 Mar;63(3):360-5.
19. Kramer PF, Faraco Junior IM, Feldens CA. Estado atual da terapia pulpar nas Universidades Brasileiras: pulpotomia e pulpectomia em dentes decíduos. *J Bras Odontop Odontol Bebê*. 2000;3(13):222-30.
20. Magalhães MHCG, Jaeger RG. Influência da pasta composta por rifocort, iodoformio e paramonoclorofenol canforado na reparação dentoalveolar: estudo morfológico em ratos. *Rev Fac Odontol FLZ*. 1991;3(1):7-15.
21. Michel JA. Estudo histopatológico da reação do subcutâneo de camundongos submetidos à ação de pasta obturadora utilizada na terapia endodôntica de dentes decíduos com polpa mortificada [dissertação]. São Paulo (SP): Universidade de São Paulo; 1984.
22. Mittal M, Chandra S, Chandra S. Comparative tissue toxicity evaluation of four endodontic sealers. *J Endod*. 1995 Dec;21(12):622-4.
23. Motta AG, Apfel MIR, Motta Junior AR. Reação do tecido conjuntivo subcutâneo de implantes contendo Apexit, Calen e L&C. *Rev Bras Odontol*. 1997 Jan-Fev;54(1):29-33.
24. Murata SS. Análise histomorfológica de dentes decíduos de cães após biopulpectomia e obturação de canais com diferentes materiais [dissertação]. Araçatuba (SP): Universidade Estadual Paulista "Júlio de Mesquita Filho"; 2002.
25. Nelson Filho P, Silva LA, Leonardo MR, Utrilla LS, Figueiredo F. Connective tissue responses to calcium hydroxide-based root canal medicaments. *Int Endod J*. 1999 Aug;32(4):303-11.
26. Nery RS. Avaliação do comportamento histomorfológico de dentes decíduos de cães, após biopulpectomia e obturação dos canais radiculares com diferentes materiais [dissertação]. Araçatuba (SP): Universidade Estadual Paulista "Júlio de Mesquita Filho"; 1999.
27. Nery RS. Comportamento dos tecidos apicais e periapicais de dentes decíduos de cães após biopulpectomia e obturação dos canais radiculares com Sealapex, Sealer Plus e MTA [tese]. Araçatuba (SP): Universidade Estadual Paulista "Júlio de Mesquita Filho"; 2000.
28. Okamoto T, Russo MC. Wound healing following tooth extraction: histochemical study in rats. *Rev Fac Odontol*. 1973;2(2):153-69.
29. Praetzel JR. Atividade antimicrobiana da Pasta Guedes Pinto imediata e armazenada em condições diversas, por diferentes períodos de tempo [tese]. São Paulo (SP): Universidade de São Paulo; 2003.
30. Piva F, Faraco Junior IM, Kramer PF, Silva MBR. Avaliação da utilização das técnicas de capeamento pulpar indireto e direto em dentes decíduos nas Faculdades de Odontologia do Brasil. *Rev Fac Odontol Univ Passo Fundo*. 2004;9(2):60-7.
31. Ranly DM, Garcia-Godoy F. Reviewing pulp treatment for primary teeth. *J Am Dent Assoc*. 1991 Sep;122(9):83-5.
32. Russo MC, Holland R, Nery RS. Periapical tissue reactions of deciduous teeth to some root canal filling materials. *Rev Fac Odontol Araçatuba*. 1976;5(1-2):163-77.
33. Santos EM. Análise da citotoxicidade in vitro de fármacos utilizados na terapia endodôntica de dentes decíduos: estudo comparativo da ação da pasta Guedes-Pinto, formocresol, glutaraldeído e ácido fosfórico sobre cultura de fibroblastos [dissertação]. São Paulo (SP): Universidade de São Paulo; 1998.
34. Santos EM. Ação da pasta Guedes-Pinto e do hidróxido de cálcio: avaliação histopatológica da reação do subcutâneo de ratos e da atividade quimiotática in vitro de macrófagos [tese]. São Paulo (SP): Universidade de São Paulo; 2002.
35. Sonat B, Dalat D, Gunhan O. Periapical tissue reaction to root fillings with Sealapex. *Int Endod J*. 1990 Jan;23(1):46-52.
36. Tagger E, Sarnat H. Root canal therapy of infected primary teeth. *Acta Odontol Pediatr*. 1984;5(2):63-6.
37. Taveira LAA. Estudo do poder flogógeno da placa dental íntegra e tratada com diferentes soluções extratoras [dissertação]. Bauru (SP): Universidade de São Paulo; 1988.
38. Thomas AM, Chandra S, Chandra S, Pandey RK. Elimination of infection in pulpectomized deciduous teeth: a short-term study using iodoform paste. *J Endod*. 1994 May;20(5):233-5.
39. Molloy D, Goldman M, White RR, Kabani S. Comparative tissue tolerance of a new endodontic sealer. *Oral Surg Oral Med Oral Pathol*. 1992;73(4):490-3.