

# Touched or perforated tooth root: what now?

## Accidents on installing screws, mini-implants and miniplates

Alberto **CONSOLARO**<sup>1</sup>

DOI: <http://dx.doi.org/10.14436/2358-2545.5.2.007-011.end>

### ABSTRACT

Tooth root gliding, with or without perforation of the pulp space, might pose some doubt on the protocols to be adopted in order to face this occasional accident, particularly when installing screws, mini-implants and dental implants. In cases with undamaged pulp space, the most adequate protocol is clinical and imagiologic control for a few months. Should the pulp space be perforated, and

perforation be accurately diagnosed by imaging examination, the potential for Calcific Metamorphosis of the Pulp or Aseptic Pulp Necrosis suggests the need for endodontic treatment, so as to prevent future complications. Provided that they are well conducted, these cases have an excellent prognosis.

**Keywords:** Pulp perforation. Screws. Mini-implants. Miniplates.

**How to cite this article:** Consolaro A. Touched or perforated tooth root: what now? Accidents on installing screws, mini-implants and miniplates. Dental Press Endod. 2015 May-Aug;5(2):7-11.  
DOI: <http://dx.doi.org/10.14436/2358-2545.5.2.007-011.oar>

<sup>1</sup> Full professor of Pathology, Universidade de São Paulo (USP), School of Dentistry, Undergraduate and Graduate Programs, Bauru and Ribeirão Preto, São Paulo, Brazil.

» The author reports no commercial, proprietary or financial interest in the products or companies described in this article.

Submitted: September 16, 2015. Revised and accepted: September 23, 2015.

Contact address: Alberto Consolaro  
E-mail: [consolaro@uol.com.br](mailto:consolaro@uol.com.br)

In their advent, mini-implants used to be installed after drilling of the jaws. Accidentally and occasionally, perforation or gliding of the rotary instrument and/or the mini-implant would occur and affect the root structure.

With the evolution of mini-implants, a specific design — which prevails nowadays — was created, causing mini-implants to bypass the root whenever meeting it, gliding over the surface and damaging periodontal structures locally, but without perforating the mineralized tooth structure.

Some fixing screws installed into the jaws, or even some dental implants, might also accidentally and occasionally glide or perforate the tooth root in cases requiring previous drilling.

Likewise, whenever securing miniplates into the bone surfaces of choice, for orthodontic/orthopedic purposes, screws are required. The latter might also glide or perforate tooth roots, since, in those cases, previous drilling is generally required.

Should accidents occur, the practitioner most likely to be sought for advice, diagnosis and treatment protocol to be adopted, as regards the affected tooth, is the Endodontics dentist.

### What are the lesions most likely to occur?

In those cases, three periodontal lesions might occur, with variations according to the severity of the case:

#### 1. Gliding without mineralized structure loss

Whenever the screw glides over the tooth root, cementoblasts are mechanically removed from the root surface, and so are the most superficial layers of cementum, partially or in their entirety, since the cementum is very friable (50% of its structure consists of inorganic matter) and little dense. Cementoblasts protect the roots against root resorption, as they are cells without membrane receptors for bone remodeling mediators. The affected tooth will test positive for pulp vitality and sensibility.

Within a few days, inflammation will arise but evolve to repair as soon as the screw is removed, as the area becomes contamination-free. The inflammatory process is local and brief, as the offending agent is quickly removed. Exudate and infiltrate will soon evolve to repair processes. Within this short

period without cementoblasts and with discreet, transient inflammation, resorption occurs to a minor degree, affecting the cementum only. Should it affect the dentin, it will be extremely superficial.

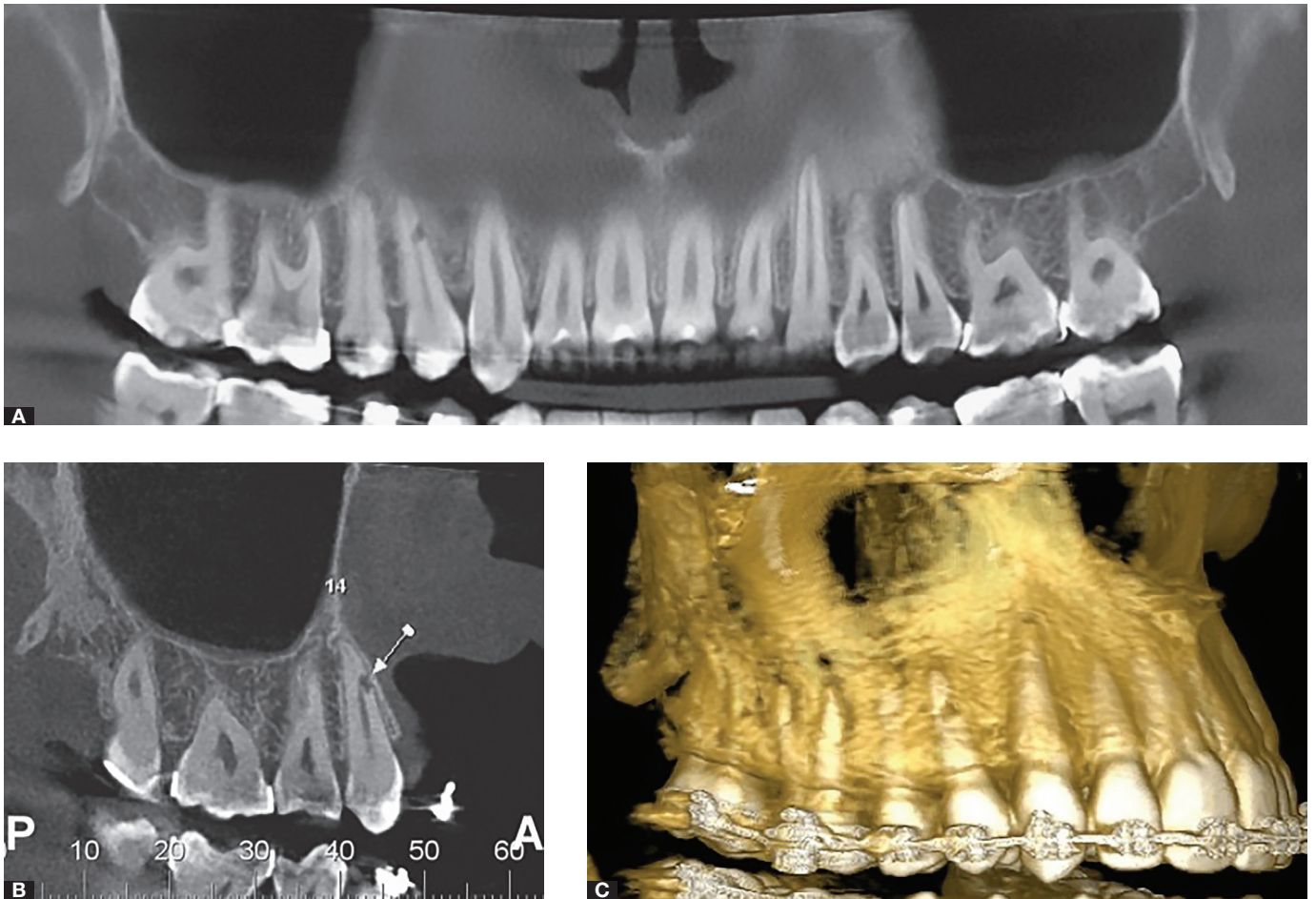
As inflammation recedes over the hours, neighboring cementoblasts and periodontal ligament reserve cells form a new layer of cementoblasts which covers the surface and starts to form a new cementum with reinsertion of periodontal fibers, thus restoring the physiology at the site.<sup>1,4</sup> This cementum might resemble, more or less, the original one and might be occasionally referred to as osteocementum or cementoid tissue.

Within a few weeks or months, imagiologic signs will remain at the site, although very subtle or even absent. Whenever present, they are represented by a small, wide open cavity, which resembles a shallow spoon, with regular root surface. The same applies to the periodontal space and lamina dura at the site.

#### 2. Gliding with loss of mineralized structure without damage to the pulp

Whenever the screw touches the root, gliding over it strongly, the mechanically induced lesion exposures the dentin to ligament tissues (Fig 1). The affected tooth will test positive for pulp vitality and sensibility. Free of contamination and without the offending agent represented by the screw, periodontal ligament cells, including clasts, will rapidly colonize the site, thus promoting resorption at the dentin surface within a few days. While stimuli provided by inflammatory mediators at the exudate remain at site, resorption will persist. Within a few hours, inflammatory substances and cells trigger the process of repair, due to absence of offending agents at the site. This is because those substances and cells understand that the site will hardly be contaminated by microorganisms.

Neighboring cementoblasts and reserve periodontal ligament cells, including pre-cementoblasts, form a new layer of cementoblasts at the site, from the periphery to the center. As the new layer of cementoblasts is formed, both the process of production of a new cementum and the reinsertion of periodontal fibers start, thus simultaneously recovering periodontal physiology at the site. Repair cementum might or might not have less regular cells



**Figure 1.** Accidental root perforation during maxillary premolar mini-implant placement. Note the proximity between the lesion and the pulp space. Clinical and imagiologic control must be performed on a monthly basis: should the tooth test negative or low for pulp vitality and sensibility, endodontic treatment must be carried out.

and structure than the original cementum; however, it fully performs the function of hiding the dentin and reinserting periodontal fibers.<sup>1-4</sup>

Imaging examinations will reveal a cavity surrounding the root contour. It might persist for a few months or even definitively. The patient should be made aware of it, as it might lead other professionals performing future examinations to cast some doubt or reach a wrong diagnosis. Those professionals will only be aware of the cavity upon patient's report. Those half-moon like defects usually present with a regular root surface, as well as continuous and regular periodontal space and lamina dura.

### 3. Root perforation with damaged pulp

The mechanical action of the drill over pulp tissues disorganizes and breaks up vessels and nerves at the affected site, in addition to inducing cell necrosis and disrupting periodontal fibers. The magnitude of the blood clot and the degree to which the tissue disrupts cannot be safely and accurately assessed by imaging examination.

In different slices and takes of imaging examinations, the perforation will appear as a well circumscribed radiolucent area, thus revealing the damaged pulp space. Special care should be taken for not being deceived by image superimposition, and remembering that thin preserved dentin may not be revealed by CT scans or radiographs (Fig 1).

Biologically speaking, if the pulp is only superficially damaged, the lesion could evolve to repair, similarly to what occurs in cases of accidental pulp exposure during crown preparation. However, it is impossible to accurately anticipate the magnitude of damage. Should the tooth test positive to pulp vitality, it might be only for a short period of time.

The pulp might evolve to two conditions:

a) The first possible condition is **Pulp Calcific Metamorphosis** or Pulp Metaplasia, followed by obliteration of the pulp space. Partial lesions affecting pulp blood supply might lead to a reactional/adaptive transformation of most pulp cells into odontoblast-like cells which will randomly lead to the production of dysplastic dentin, thus obliterating the canal and/or the pulp chamber while causing pulp limits to become unclear.

Over time, usually within a period ranging from 4 to 22 years, the condition might evolve to pulp

necrosis with chronic periapical lesion. Asymptomatic, the condition might last and remain uncontrolled by the clinician and the patient. As time goes by, this tooth might present with a darkened crown resulting from the above described process.

b) The second possible condition is **Aseptic Pulp Necrosis**, if pulp blood supply is completely interrupted. Asymptomatic, aseptic pulp necrosis might evolve to tooth-crown darkening and chronic periapical lesion over the years, remaining uncontrolled by the clinician and the patient. Those lesions might be followed by **anachoresis** which, over time, might cause the process to relapse with the formation of fistula by bacterial contamination by hematogenic route.

Based on the possibility of having those two conditions evolving from accidental root perforation by screws and mini-implants, the safest protocol to be adopted is endodontic treatment — particularly in cases in which pulp space perforation is accurately diagnosed by clear imaging examination.

### Would ankylosis and posterior replacement tooth resorption be possible?

The region of affected periodontal tissues is very small and limited. At site, epithelial rests of Malassez will rapidly regenerate, thus restoring and protecting the periodontal space. In cases of dental trauma leading to ankylosis and replacement resorption, periodontal tissue lesion is extensive and does not provide enough time for the epithelial rests of Malassez to regenerate. Before that, the bone occupies the periodontal space, connects to the root surface and evolves to replacement tooth resorption.<sup>2,3</sup>

### Why are pus, fistula and painful symptoms absent in those cases?

Pus formation results from the interaction between neutrophils, which indistinctly and copiously reach any inflammatory process, with bacteria, especially *staphylococcus* and *streptococcus*.<sup>3</sup> In cases of accidental gliding and perforation by screws, mini-implants and implants, microbial contamination is nonexistent. Thus, neutrophils migrate to other areas as soon the absence of bacteria is detected, giving way to other cells, especially macrophages, which will trigger a process of cleaning cell and tissue debris and promote periodontal tissue repair.

## Why is resorption discontinuous in those cases?

For a resorption process to remain continuous, the uninterrupted presence of mediators is required, especially as a result of cell stress and inflammation.<sup>2</sup> In cases of gliding and perforation by screws and mini-implants over tooth roots, the offending agent is represented by the devices' physical action which ceases as soon as they are removed. Mediators build up within 24 to 48 hours, and the repair process will soon prevail at site. Resorption of the exposed root surface will last for a short period of time, probably for a few days. Without inflammation at the site, mediators will gradually decrease until the resorption process ceases completely.

## Final considerations

Root gliding and perforation by screws, mini-implants or dental implants do not necessarily require endodontic intervention. The protocol requires thorough clinical and imagiologic analysis. In cases of gliding and damage to the mineralized root structure, without perforation of the pulp space, endodontic treatment is not required. An analysis carried out for control purposes for a few months should be enough. Generally, periodontal repair is established at the site without damage to the pulp. However, should the pulp space be perforated, with the potential for Calcific Metamorphosis of the Pulp or Aseptic Pulp Necrosis, there is a need for endodontic treatment, so as to prevent future complications.

## References

1. Asscherickx K, Vannet BV, Wehrbein H, Sabzevar MM. Root repair after injury from mini-screw. *Clin Oral Implants Res*. 2005 Oct;16(5):575-8.
2. Consolaro A. Reabsorções dentárias nas especialidades clínicas. 3a ed. Maringá: Dental Press; 2012.
3. Consolaro A. Inflamação e reparo: um sílabo para a compreensão clínica e implicações terapêuticas. 2a ed. Maringá: Dental Press; 2015.
4. Consolaro A, Sant'Ana E, Francischone Júnior CS, Consolaro MFMO, Barbosa BA. Uso clínico dos mini-implantes: pontos consensuais e questionamentos. In: Consolaro A, Consolaro MFMO. *Controvérsias na Ortodontia*. Maringá: Dental Press; 2008. p. 157-70.