

Avulsion and intrusive luxation in deciduous teeth: a case report

Jéssica Behrens **CRISPIM**¹
 Nair Narumi Orita **PAVAN**²
 Carlos Alberto Herrero de **MORAIS**²
 Maria Gisette Arias **PROVENZANO**³
 Marcos Sergio **ENDO**²

DOI: <http://dx.doi.org/10.14436/2358-2545.6.1.056-061.cre>

ABSTRACT

Introduction: The occurrence of tooth injuries during childhood is common, about a third of children in primary dentition suffer from dental trauma. Proper treatment of dental trauma in primary dentition prevents pain and the successor tooth germ from being affected. **Objective and case report:** The objective of this report was to describe the case of a 5-year-old child who sought treatment at the Specialized Trauma Center in Dentistry of Maringá, Universidade Estadual de Maringá (UEM),

three days after traumatic injury that caused severe intrusion of tooth #62 and avulsion of tooth #61. After four months, we observed complete spontaneous eruption of the intruded tooth. As for avulsion of tooth #61, it was decided not to replant it, so as not to injure the permanent tooth germ, and wait for its eruption. As regards tooth #62, it was decided to wait for spontaneous eruption, monitoring it periodically through clinical and radiographic examination until it fully erupted.

Keywords: Avulsion. Deciduous tooth. Endodontics.

How to cite this article: Crispim JB, Pavan NNO, Moraes CAH, Provenzano MGA, Endo MS. Avulsion and intrusive luxation in deciduous teeth: a case report. *Dental Press Endod.* 2016 Jan-Apr;6(1):56-61.
 DOI: <http://dx.doi.org/10.14436/2358-2545.6.1.056-061.cre>

» The authors report no commercial, proprietary or financial interest in the products or companies described in this article.

» Patients displayed in this article previously approved the use of their facial and intraoral photographs.

¹Undergraduate student of Dentistry, Universidade Estadual de Maringá (UEM), Maringá, Paraná, Brazil.

²Adjunct professor of Endodontics, Universidade Estadual de Maringá (UEM), Maringá, Paraná, Brazil.

³Adjunct professor of Pediatric Dentistry, Universidade Estadual de Maringá (UEM), Maringá, Paraná, Brazil.

Submitted: 26/01/2016. Revised and accepted: 16/03/2016.

Contact address: Marcos Sergio Endo
 Departamento de Odontologia (UEM).
 Av. Mandacarú, 1550, bloco S08 – Maringá/PR, Brazil – CEP: 87.083-170
 E-mail: marcossendo@gmail.com

Introduction

Dental trauma frequently occurs during childhood, resulting in functional and esthetic damage and promoting major emotional and psychological impact on both the child and the parents. Retrospective and prospective studies have shown that the prevalence of traumatic injuries in the deciduous dentition varies between 4% and 33%.^{1,2,3} Approximately one third of children in primary dentition suffer from traumatic injuries in the oral region.⁴

Given the poor motor coordination of children, childhood has the greatest risk of oral traumatic injuries occurrence.¹⁻⁵ With advancing age, participation in games and sports becomes common. Thus, the occurrence of accidents or falls and, consequently, oral traumatic injury is common both during childhood and adolescence.^{6,7}

Dental trauma affects both deciduous and permanent teeth and may leave after-effects that often accompany the individual throughout life. The main objectives of diagnosis and treatment of trauma affecting the primary dentition in children are pain control and prevention of damages to the permanent tooth germ.^{1,2,3,8,9,10} The consequences of trauma in primary dentition include color change, pulp necrosis, obliteration of the root canal, gingival recession, tooth displacement, root resorption and premature loss of deciduous tooth.^{1-4,11} Furthermore, due to proximity of the germ with the root of the predecessor deciduous tooth, there is a risk of changes occurring in the successor tooth after trauma in the first dentition.^{8,9,10}

Intrusive luxation and avulsion of deciduous teeth are highly associated with developmental disorders in successor teeth,^{12,13,14} and the child's age at the time of injury, as well as direction and severity of intrusion, are important variables for the development of these sequelae.¹⁴ Ravn¹² analyzed sequelae after avulsion of deciduous teeth and found a frequency of 74.1%, which was higher in children aged 0 to 2 years old and lower in children older than 5 years of age. Another study investigated developmental disorders after intrusion of deciduous teeth and observed an incidence of 54% after-effects, highlighting the most common one: enamel hypomineralization.¹³

Objective

The objective of the present study was to describe the clinical approach and follow-up employed

after avulsion and intrusion of patient's deciduous teeth (#61 and #62, respectively).

Case report

A 5-year-old girl came to C.E.M. Trau-Odonto Extension Project (Specialized Trauma Center in Dentistry of Maringá), Dental Clinic of Universidade Estadual de Maringá (UEM), three days after suffering from a dental injury caused by a bicycle fall. The patient came accompanied by her mother who provided the information. The patient was vaccinated with the first dose of tetanus vaccine, presented with good general health, without neurological deficits, and was taking anti-inflammatory drugs prescribed by a doctor at Primary Care Unit immediately after trauma.

Upon extraoral examination, it was observed laceration and upper lip swelling. Intraoral examination revealed absence of teeth #61 and #62, with swelling and redness in this region (Fig 1A). Palpation associated with radiographic examination did not detect alveolar bone fracture. Occlusal radiograph indicated avulsion of tooth #61 and complete intrusion of the crown (type III) in tooth #62. There was no close contact with the permanent tooth germ, as revealed by X-ray analysis (Fig 2).

Treatment protocol consisted of keeping tooth #62 and monitoring its spontaneous eruption. The patient's mother was instructed to perform good cleaning, provide her with pasty food for two weeks, and avoid the use of pacifiers and bottles. At this time, the patient was prescribed mouthwash with 0.12% chlorhexidine twice a day, totaling seven days.

After a week, the patient returned for the first control visit and to check for proper healing. Swelling of the upper lip had subsided and lacerations were healed. Swelling at the gingival area of teeth #61 and #62 had reduced and the color was close to normal (Fig 1B).

After 30 days, the patient returned and tooth #62 had entered the process of eruption (Fig 1C). Three months after trauma, the tooth was almost completely erupted. Four months after trauma, tooth #62 had erupted, without color change, symptoms, mobility and sinus tract; but buccally-oriented (Fig 1D).

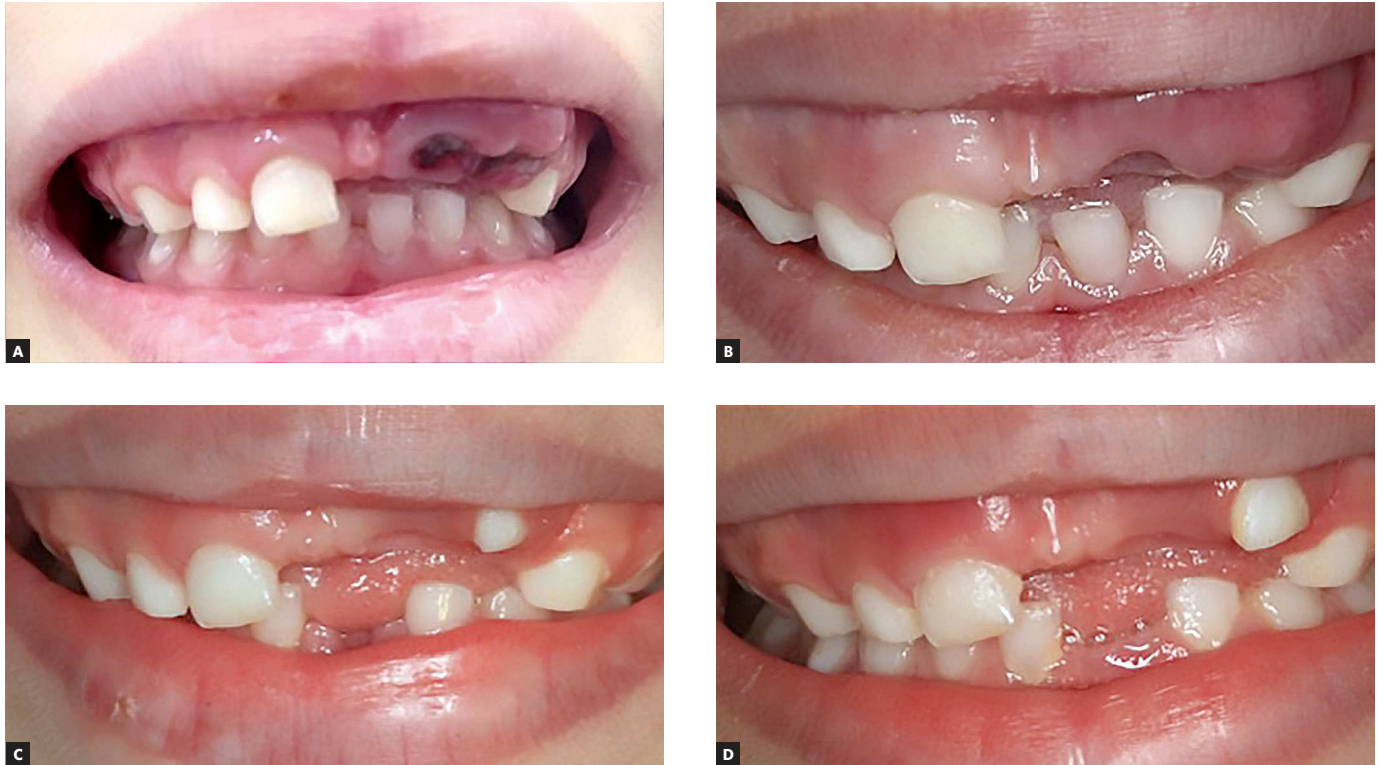

Figure 1. A) First session intraoral examination revealing absence of teeth #61 and #62 with swelling and redness in this region. B) After one week, swelling in the upper lip and the gingival region of teeth #61 and #62 subsided with healing of laceration. C) After 30 days, there was spontaneous eruption of tooth #62. D) After four months, tooth #62 had erupted buccally without changes of color and fistula.

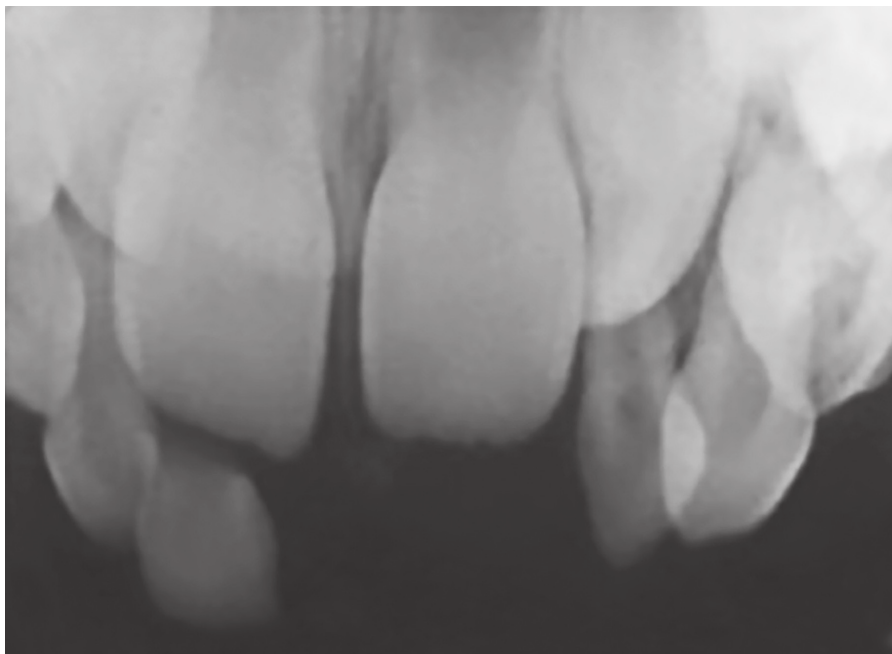


Figure 2. Absence of tooth #61 and total intrusion of tooth #62 crown. No close contact with the permanent tooth germ was observed.

The oral mucosa had an appearance of normality. Radiographs revealed no signs of periapical lesion or pathological root resorption. When comparing it with its contralateral tooth, occlusal radiograph indicated delay on root resorption.

Discussion

At patient's first visit, a detailed questionnaire collected information related to dental trauma characteristics: there was no loss of consciousness, vomiting, or pain response to thermal stimuli; the patient had no difficulty chewing and had tetanus vaccine updated, corroborating the care evaluated by Gupta.¹⁵ Intraoral examination inspected soft and dental tissues of the affected area. Additional examination was also required, so as to locate foreign bodies; and occlusal incidence, so as to verify absence of primary tooth #61 and the relationship of tooth #62 with the permanent tooth germ. Parents found the avulsed tooth, ensuring that the child did not swallow or inhaled it. Cases in which there is complaint of cough, breathlessness and fever should have the possibility of foreign body inhalation investigated and a thorax radiograph is required to confirm it.¹⁶

Studies found in the literature^{11,17-20} corroborate the present study regarding the most often injured primary teeth, maxillary incisors, ranging from 63% to 92%. The main cause of dental trauma in young patients is fall.²¹ Luxation usually occurs more often than fracture because the bone structure of deciduous teeth is less dense and mineralized.^{4,9,20,22}

Due to proximity of the permanent tooth germ with the root of the deciduous tooth, the occurrence of changes is commonly found in the successor tooth after injury in the first dentition. Intrusive luxation and avulsion represent the most worrying injuries.^{12,13,14} The type of trauma in deciduous teeth that caused more sequelae in the developing permanent tooth was intrusive luxation, followed by avulsion, which is consistent with other authors.^{23,24} Thus, the dentist must monitor the eruption of the permanent tooth to check for any sequelae.

Depending on the direction and intensity of force exerted over primary teeth, there might also be interference with the development and eruption of the permanent successor tooth germ,²⁵ thereby resulting in enamel hypomineralization^{18,25} and even more

serious disorders, such as dilaceration of the crown or root¹⁸ and disruption of root development.²⁶ Pulp necrosis, periapical inflammation, external root resorption, ankylosis and root canal obliteration are sequelae possibly detected in cases of intrusion.^{22,27} There was no need to perform endodontic treatment in the primary tooth due to its favorable clinical findings, which showed no pain, color change, sinus tract or mobility. Additionally, the mucosa had an appearance of normality.²⁸

In cases of intruded primary teeth, dental apex is usually buccally displaced.²⁹ In periapical radiograph, if the apex is displaced towards or through the buccal bone plate, the tooth will appear shorter in contralateral relationship. In such cases, the tooth should be kept for spontaneous eruption;^{4,9,14,29} corroborating the clinical approach. If the apex was displaced towards the permanent tooth germ, the protocol should be extraction.^{4,14,21,29,30}

Spontaneous eruption is expected when intrusion is mild (type I). In moderate or severe intrusion (types II or III), the tooth rarely erupts and may become necrotic, indicating the need for extraction.³⁰ Contrary to these findings, in the present study, the monitored deciduous tooth (type III) erupted spontaneously. Without clear signs of spontaneous eruption after 4-8 weeks, one may suspect of ankylosis, and extraction can also be considered.^{11,31}

Ectopic position of the erupted tooth after intrusion is a frequent finding,²⁹ and in this case, we observed the spontaneous buccal eruption of the crown. Although the intruded tooth showed no color change in the crown, it is important to highlight that the grayish color may be due to intrapulpal bleeding and not always to necrosis.³² Furthermore, detection of sinus tract in cases of pulp necrosis has been observed between 91-180 days after injury.³³

The avulsed deciduous tooth was not replanted because of the potential damage it would cause to the permanent tooth germ.³⁴ Avulsed deciduous teeth should not be replanted, given the risk of infection, ankylosis and trauma to permanent teeth.³⁵ Loss of anterior teeth at a very early age results in difficulty in speech development, especially in children.³⁶ It can also lead to the development of harmful habits of the tongue. In such patients, the use of space maintainers is indicated. However, in

the present report, this protocol was not employed due to patient's favorable age for eruption of the permanent tooth, which was confirmed by radiographic examination. Subsequently, the patient should be assisted by clinical and periodic radiographic control until the tooth complete eruption.

The first control was performed after one week by clinical and radiographic examinations in order to assess healing, oral hygiene and infection, thus confirming the findings by Gupta¹⁵. In the case reported, complete eruption was observed after four months, whilst in the literature, it was observed between one and six months.^{11,31,35} Altun et al³⁷ detected, after intrusive luxation and in 138 deciduous incisors, teeth that had erupted completely (78%), partially erupted (15%) and remained impacted (7%).

In the present study, follow-up was based on the possibility of the patient to attend the service hours, and according to the guidelines of the International Association of Dental Traumatology,³⁸ in which monitoring of deciduous teeth is recommended after one week, three to four weeks, six to eight weeks, six months and one year. It is worth recalling that intruded deciduous teeth require follow-up until exfoliation.

Conclusion

Knowledge of the clinical approach adopted for deciduous teeth subjected to highly complex trauma is essential to the appropriate choice of treatment and to prevent potential sequelae in the permanent tooth germ.

References

- Ferguson FS, Ripa LW. Prevalence and type of traumatic injuries to the anterior teeth of preschool children. *J Pedod.* 1979 Fall;4(1):3-8.
- Mestrinho HD, Bezerra AC, Carvalho JC. Traumatic dental injuries in Brazilian pre-school children. *Braz Dent J.* 1998;9(2):101-4.
- Cunha RF, Pugliesi DM, Vieira AEM. Oral trauma in Brazilian patients aged 0-3 years. *Dent Traumatol.* 2001 Oct;17(5):210-2.
- Andreasen JO, Andreasen FM. Textbook and color atlas of traumatic injuries to the teeth. 3rd ed. Copenhagen: Munksgaard; 1994.
- Harrington MS, Eberhart AB, Knapp JF. Dentofacial trauma in children. *ASDC J Dent Child.* 1988 Sept-Oct;55(5):334-8.
- Perez R, Berkowitz R, McIlveen L, Forrester D. Dental trauma in children: a survey. *Endod Dent Traumatol.* 1991 Oct;7(5):212-3.
- Glendor U, Halling A, Andersson L, Eilert-Petersson E. Incidence of traumatic tooth injuries in children and adolescents in the county of Västmanland, Sweden. *Swed Dent J.* 1996;20(1-2):15-28.
- Flores MT. Traumatic injuries in the primary dentition. *Dent Traumatol.* 2002 Dec;18(6):287-98.
- Holan G, Ram D, Fuks AB. The diagnostic value of lateral extraoral radiography for intruded maxillary primary incisors. *Pediatr Dent.* 2002 Jan-Feb;24(1):38-42.
- Torriani DD, Percinoto C, Cunha RF, Guimarães I. Histological evaluation of dog permanent teeth after traumatic intrusion of their primary predecessors. *Dent Traumatol.* 2006;22(4):198-204.
- Borum MK, Andreasen JO. Sequelae of trauma to primary maxillary incisors. I. Complications in the primary dentition. *Endod Dent Traumatol.* 1998 Feb;14(1):31-44.
- Ravn JJ. Developmental disturbances in permanent teeth after exarticulation of their primary predecessors. *Scand J Dent Res.* 1975 May;83(3):131-4.
- Ravn JJ. Developmental disturbances in permanent teeth after intrusion of their primary predecessors. *Scand J Dent Res.* 1976 May;84(3):137-41.
- Diab M, elBadrawy HE. Intrusion injuries of primary incisors. Part III: Effects on the permanent successors. *Quintessence Int.* 2000 Jun;31(6):377-84.
- Gupta M. Intrusive luxation in primary teeth: review of literature and report of a case. *Saudi Dent J.* 2011 Oct;23(4):167-76.
- Mendoza-Mendoza A, González-Mallea E, Iglesias-Linares A. Intrusive luxation in primary teeth: a case report. *J Clin Pediatr Dent.* 2015;39(3):215-8.
- Andreasen JO, Ravn JJ. Epidemiology of traumatic dental injuries to primary and permanent teeth in a Danish population sample. *Int J Oral Surg.* 1972;1(5):235-9.
- Bijella MF, Yared FN, Bijella VT, Lopes ES. Occurrence of primary incisor traumatism in Brazilian children: a house-by-house survey. *ASDC J Dent Child.* 1990 Nov-Dec;57(6):424-7.
- Gondim JO, Moreira Neto JJ. Evaluation of intruded primary incisors. *Dent Traumatol.* 2005 Jun;21(3):131-3.
- Andreasen JO, Bakland LK, Matras RC, Andreasen FM. Traumatic intrusion of permanent teeth. Part 1. An epidemiological study of 216 intruded permanent teeth. *Dent Traumatol.* 2006 Apr;22(2):83-9.
- Andreasen JO, Andreasen FM, Andreasen L. Textbook and color atlas of traumatic injuries to the teeth. 4th ed. Oxford: Blackwell Munksgaard; 2007.
- Crespi PV. Intrusive injuries to the dentition. *NY State Dent J.* 1992;58(2):35-8.
- Brin I, Fuks A, Ben-Bassat Y, Zilberman Y. Trauma to the primary incisors and its effect on the permanent successors. *Pediatr Dent.* 1984;6(2):78-82.
- Ben Bassat Y, Fuks A, Brin I, Zilberman Y. Effect of trauma to primary incisors on root development of their permanent successors. *Pediatr Dent.* 1985;7(1):37-40.
- von Arx T. Developmental disturbances of permanent teeth following trauma to the primary dentition. *Aust Dent J.* 1993 Feb;38(1):1-10.
- Zilberman Y, Fuks A, Ben Bassat Y, Brin I, Lustmann J. Effect of trauma to primary incisors on root development of their permanent successors. *Pediatr Dent.* 1986;8(4):289-93.
- Amorim LF, Costa LR, Estrela C. Retrospective study of traumatic dental injuries in primary teeth in a Brazilian specialized pediatric practice. *Dent Traumatol.* 2011 Oct;27(5):368-73.
- Holan G. Long-term effect of different treatment modalities for traumatized primary incisors presenting dark coronal discoloration with no other signs of injury. *Dent Traumatol.* 2006 Feb;22(1):14-7.
- Holan G, Ram D. Sequelae and prognosis of intruded primary incisors: a retrospective study. *Pediatr Dent.* 1999 Jul-Aug;21(4):242-7.
- Wilson CF. Management of trauma to primary and developing teeth. *Dent Clin North Am.* 1995 Jan;39(1):133-67.
- Harding AM, Camp JH. Traumatic injuries in the preschool child. *Dent Clin North Am.* 1995;39(4):817-35.
- Cardoso M, Rocha MJ. Federal University of Santa Catarina follow-up management routine for traumatized primary teeth – part 1. *Dent Traumatol.* 2004 Dec;20(6):307-13.
- Qassem A, Martins N da M, Costa VP, Torriani DD, Pappen FG. Long-term clinical and radiographic follow up of subluxated and intruded maxillary primary anterior teeth. *Dent Traumatol.* 2015 Feb;31(1):57-61.
- García-Godoy F, Pulver F. Treatment of trauma to the primary and young permanent dentitions. *Dent Clin North Am.* 2000 Jul;44(3):597-632.
- Fried I, Erickson P. Anterior tooth trauma in the primary dentition: incidence, classification, treatment methods, and sequelae: a review of the literature. *ASDC J Dent Child.* 1995 Jul-Aug;62(4):256-61.
- Riekman GA, el Badrawy HE. Effect of premature loss of primary maxillary incisors on speech. *Pediatr Dent.* 1985 Jun;7(2):119-22.
- Altun C, Cehreli ZC, Güven G, Acikel C. Traumatic intrusion of primary teeth and its effects on the permanent successors: a clinical follow-up study. *Oral Surg Oral Med Oral Pathol Oral Radiol Endod.* 2009 Apr;107(4):493-8.
- Malmgren B, Andreasen JO, Flores MT, Robertson A, DiAngelis AJ, Andersson L, Cavalleri G, et al. International Association of Dental Traumatology guidelines for the management of traumatic dental injuries: 3. Injuries in the primary dentition. *Dent Traumatol.* 2012 Jun;28(3):174-82.